EPAT Emergency Physicians Association of Turkey

WACEM

ATUDER Acil Tıp Uzmanları Derneği

23-26 April 2026

Royal Seginus Hotel, Lara / Antalya

13th INTERCONTINENTAL EMERGENCY MEDICINE CONGRESS

&

13th INTERNATIONAL CRITICAL CARE AND EMERGENCY MEDICINE CONGRESS

IN CONJUNCTION WITH

22nd NATIONAL EMERGENCY MEDICINE CONGRESS

&

2026 WACEM SUMMER LEADERSHIP SUMMIT

EPAT ATUDER 27 YEARS Silver Jubilee 1999-2026



ABSTRACT BOOK



13th INTERCONTINENTAL EMERGENCY MEDICINE CONGRESS

ORGANIZING COMMITTEE

PRESIDENT

Başar CANDER
Sagar GALWANKAR

SECRETARY GENERAL

Kaoutar AZIJLI-ABDELLAOUI
Ayman EL-MENYAR
Bahadır TAŞLIDERE
M.İkbal ŞAŞMAZ
Serhat ÖRÜN
Yasin YILDIZ

COMMITTEE MEMBERS

Hassan AL THANI
Saud AL TURKI
Khikmat ANVAROV
Abdullah BAHMED
Egor BORISOV
Pia DANIEL
Roger DICKERSON
Salvatore DI SOMMA
Nazmine GÜLER
Ali GÜR
Amin Antoine KAZZI
Haitham KHALIFA
Fatimah LATEEF
O John MA
Bruno MEGARBANE
Lisa MORENO-WALTON
Prabath NANAYAKKARA
Daniel O'BRIEN
Lukasz SZARPAK
Santosh SOANS
Erdal TEKİN
Fatma TORTUM
Maartje VAN HAPEREN
Zoltan VAMOS



13th INTERNATIONAL CRITICAL CARE AND EMERGENCY MEDICINE CONGRESS

ORGANIZING COMMITTEE

PRESIDENT

Başar CANDER
Lukasz SZARPAK

SECRETARY GENERAL

Khikmat ANVAROV
Mehmet KOŞARGELİR
Francisco MOYA
Serhat ÖRÜN

COMMITTEE MEMBERS

Behçet AL
Nabil Muhammad AL KUDDOOS
Majed ALTHAGAFI
Kaoutar AZIJLI-ABDELLAOUI
Khalid A. ATEYYAH
Miguel BARRIOS
Ayman EL MENYAR
Sagar GALWANKAR
Carlos GARCIA A ROSAS
Rose Valentine A GONCALVES
Alaa Eldin KHALIL AHMED
Monalisa MUCHATUTA
Lisa MORENO-WALTON
Prabath NANNAYAKKARA
Gabriella PLOMER
Varsha REDDY JAYAR
Devendra RICHHARIYA
Karima R SAJADI-ERNAZAROVA
Askhat SAPAROV
Samir M. SMISIM
Santosh SOANS
Syed Jamal Fikri bin SYED YUSOFF FADZIL
M.İkbal ŞAŞMAZ
Wasim ZAKARIA



22nd NATIONAL EMERGENCY MEDICINE CONGRESS

PRESIDENT

Prof. Dr. Başar CANDER
Prof. Dr. Zeynep G. ÇAKIR
Prof. Dr. Mehmet GÜL

SECRETARY GENERAL

Doç. Dr. Cüneyt ARIKAN
Doç. Dr. Muhammed EKMEKYAPAR
Uzm. Dr. Mine KAYACI YILDIZ
Uzm. Dr. Ayla MOLLAOĞLU
Uzm. Dr. Havva SERİN YİĞİT
Doç. Dr. Abdussamed VURAL
Prof. Dr. Atakan YILMAZ

SCIENTIFIC COMMITTEE

Doç. Dr. Mehmet Oğuzhan AY
Prof. Dr. Nurşah BAŞOL
Doç. Dr. Hacı Mehmet ÇALIŞKAN
Doç. Dr. Kaan ÇELİK
Prof. Dr. Umut GÜLAÇTI
Doç. Dr. İlker KAÇER
Doç.Dr. Arif KARAGÖZ
Doç. Dr. Burak KATİPOĞLU
Doç. Dr. Mustafa KEŞAPLI
Prof. Dr. İsa KILIÇASLAN
Prof. Dr. İlhan KORKMAZ
Dr. Öğr. Üyesi Mehmet KOŞARGELİR
Prof. Dr. Tarık OCAK
Prof. Dr. Şerife ÖZDİNÇ
Doç. Dr. Murat SEYİT
Prof. Dr. Ertan SÖNMEZ
Prof. Dr. Kasım TURGUT
Prof. Dr. Muhammed Gökhan TURTAY
Prof. Dr. İbrahim TÜRKÇÜER
Prof. Dr. Kenan Ahmet TÜRKDOĞAN
Prof. Dr. Suat ZENGİN

ORGANIZING COMMITTEE

Doç. Dr. Sultan Tuna AKGÖL GÜR
Uzm. Dr. Mustafa ALPASLAN
Uzm. Dr. Bilal ARAÇ
Uzm. Dr. İsmail ATAŞ
Uzm. Dr. Sema AYTEN
Dr. Öğr. Üyesi Büşra BİLDİK
Dr. Öğr. Üyesi Adnan BİLGE
Dr. Öğr. Üyesi Oğuzhan BOL
Doç. Dr. Emre BÜLBÜL
Uzm. Dr. Cemal İlker CANDER
Dr. Öğr. Üyesi Mustafa Oğuz CUMAOĞLU
Doç. Dr. Fatma ÇAKMAK
Dr. Öğr. Üyesi Ayça ÇALBAY
Uzm. Dr. Şeyma Nur ÇALIŞIR
Doç. Dr. Hacı Mehmet ÇALIŞKAN
Uzm. Dr. Asiye Müminat ÇAP
Doç. Dr. Bilgehan DEMİR
Doç. Dr. Osman Lütfi DEMİRCİ
Prof. Dr. Mehmet DOKUR
Doç. Dr. Turgut DOLANBAY
Uzm. Dr. Zamir Kemal ERTÜRK
Uzm. Dr. Mustafa Önder GÖNEN
Doç. Dr. Abdullah Cüneyt HOCAGİL
Prof. Dr. Ali KARAKUŞ
Uzm. Dr. Fulya KÖSE
Dr. Öğr. Üyesi Süleyman NOGAY
Doç. Dr. Mert ÖZEN
Doç. Dr. İbrahim ÖZLÜ
Uzm. Dr. Yasemin PİŞĞİN
Doç. Dr. Ekim SAĞLAM GÜRMEN
Uzm. Dr. Sümeyye Tuğba SARKI CANDER
Dr. Öğr. Üyesi Ahmet Melih SAVAŞ
Doç. Dr. Murat SEYİT
Dr. Öğr. Üyesi Mehmet SOYUGÜZEL
Prof. Dr. Ertan SÖNMEZ
Doç. Dr. Levent ŞAHİN
Doç. Dr. Erdal TEKİN
Uzm. Dr. Fatih Cemal TEKİN
Doç. Dr. Fatma TORTUM
Doç. Dr. Emin Fatih VİŞNECİ
Dr. Öğr. Üyesi Harun YILDIRIM
Dr. Öğr. Üyesi Abdurrahman YILMAZ

ORAL PRESENTATIONS

Ref No: 1017

A Deceptive Nail Gun Injury: Deep Patellar Penetration with Normal Physical Findings

Selva Poçan[1], Mine Kayacı Yıldız[1], Mehmet Akif Ersoy[1], Ayla Mollaoğlu[1], Mehmet Gül[1]

[1]Emergency Medicine Department, Konya City Hospital, Türkiye

Introduction and Purpose: Nail gun injuries are penetrating traumas frequently resulting from occupational accidents that can lead to severe complications. In such cases, the external clinical appearance can be deceptive, potentially masking significant underlying tissue damage. This case aims to emphasize the importance of early radiological imaging in suspicious cases and to discuss the subsequent treatment approach.

Materials and Methods: A 26-year-old male presented to the emergency department following a nail gun injury to the anterior aspect of his right knee. Upon arrival, the patient's general condition was stable, vital signs were within normal limits, and physical examination findings were unremarkable, showing only a minimal entry wound. Following clinical protocols, tetanus prophylaxis was administered, and broad-spectrum intravenous antibiotic treatment was initiated. Right knee radiography revealed a metallic foreign body deeply embedded at the patellar level. After consultation with the Orthopedics and Traumatology department, the patient was admitted and taken to the operating room, where the foreign body was successfully removed via surgical intervention.

Results and Conclusion: Although nail gun injuries are often classified as low-velocity penetrating traumas, they carry a high risk of significant complications. Involvement of bone and joint structures specifically increases the risk of infection, osteomyelitis, and long-term functional loss. While conventional radiography is typically sufficient for initial diagnosis, advanced imaging may be necessary in more complex presentations. This case demonstrates that minimal-looking external wounds can hide deep-seated injuries; therefore, prompt imaging, appropriate prophylaxis, and early surgical intervention are vital for optimal outcomes.

Keywords: Nail gun, penetrating trauma, patella

Ref No: 1026

Syncope due to lithium intoxication: A case report

Muhammed Feyizoğlu[1], Betül Babagil[1], Muhammet Gökhan Turtay[1], Ahmet Çağlar[1], Birsen Ertekin[1], Şükran Rabia Yılmaz[1]

[1]University of Health Sciences, Beyhekim Training and Research Hospital, Clinic of Emergency Medicine, Konya, Türkiye.

Muhammet Gökhan Turtay / University of Health Sciences, Beyhekim Training and Research Hospital, Clinic of Emergency Medicine, Konya, Türkiye.

Introduction and Purpose: In this report, we emphasise the importance of haemodialysis and a multidisciplinary approach in the management of lithium intoxication with cardiac involvement.

Materials and Methods: A 67-year-old woman with a history of bipolar disorder and epilepsy was referred to our emergency department in an intubated and unconscious state. During the initial assessment, her Glasgow Coma Scale score was 3, and her pupils were mydriatic. Her medical history revealed that she had experienced chills, tremor, nausea, and fatigue for the preceding two to three days. During this period, she had received antibiotics and non-steroidal anti-inflammatory drugs prescribed at another medical centre. Syncope developed following severe nausea and vomiting, which led to endotracheal intubation. On physical examination, bilateral rales were detected on auscultation, and chest radiography demonstrated a consolidation in the apex of the right lung. Thoracic computed tomography revealed an area of infiltration in the right upper lobe consistent with pneumonia. Given her history of lithium use, serum lithium levels were measured. A nephrology consultation was requested, and the patient was admitted to the intensive care unit for emergency haemodialysis. Emergency haemodialysis was performed for three hours within the first twenty-four hours. Following treatment, the serum lithium level decreased to 1.75 mmol/L. Renal function normalised during follow-up, and the initial consolidation observed on chest radiography was found to have completely regressed. The patient was discharged without sequelae on the twenty-sixth day of hospitalisation.

Results and Conclusion: Lithium intoxication should be considered in the differential diagnosis of patients presenting with syncope and unexplained altered consciousness, particularly in those with a history of bipolar disorder.

Keywords: Haemodialysis, Lithium toxicity, Syncope

Ref No: 1056

An Overlooked Cause of Cardiovascular Collapse in the Unconscious Patient: Tricyclic Antidepressant Toxicity

CUMA ÖNDER YEŞİLDAĞ[1]

[1]Şanlıurfa Training and Research Hospital

CUMA ÖNDER YEŞİLDAĞ / Şanlıurfa Training and Research Hospital

Introduction and Purpose: Tricyclic antidepressant (TCA) intoxications are high-mortality emergencies that can mimic acute coronary syndrome (ACS) with wide QRS complexes, cardiovascular collapse, and refractory dysrhythmias. This report aims to present a case brought to the emergency department (ED) in cardiac arrest, initially evaluated as ACS but definitively diagnosed with TCA intoxication during the clinical course.

Materials and Methods: A 56-year-old male was found unconscious on the street and brought to the ED by emergency medical services. The patient suffered cardiac arrest during the final minute of transport; resuscitation was initiated in the red zone, and blood samples were obtained. The patient had bilateral 8 mm (mydriatic) pupils unresponsive to direct and indirect light, with a capillary blood glucose of 178 mg/dL. At the sixth minute of resuscitation, a shockable rhythm was detected; he was defibrillated, achieving return of spontaneous circulation (ROSC). Post-ROSC, his heart rate was 123 beats/min and blood pressure was 64/33 mmHg; norepinephrine infusion was initiated alongside fluid resuscitation. Blood gas analysis revealed mixed acidosis (pH: 7.02, pCO2: 76 mmHg, HCO3: 13 mmol/L, base excess: -12 mmol/L, K: 5.34 mmol/L, Na: 142 mmol/L). Presenting with a wide QRS on electrocardiography (Figure 1) and global myocardial hypokinesia with an ejection fraction of 30% on bedside echocardiography, the unidentified patient was primarily managed for ACS. Following cardiology consultation, emergency coronary angiography revealed no critical stenosis. Concurrently, contact with his wife revealed an 8-year history of psychiatric treatment and the use of amitriptyline, a TCA. Readmitted to the ED, sodium bicarbonate infusion was initiated for suspected TCA toxicity. With normalizing QRS durations (Figure 2) and decreasing vasopressor requirements, he was admitted to the intensive care unit (ICU). A comprehensive toxicology panel was positive for TCA. The patient expired at the 68th hour of hospitalization.

Figure 1

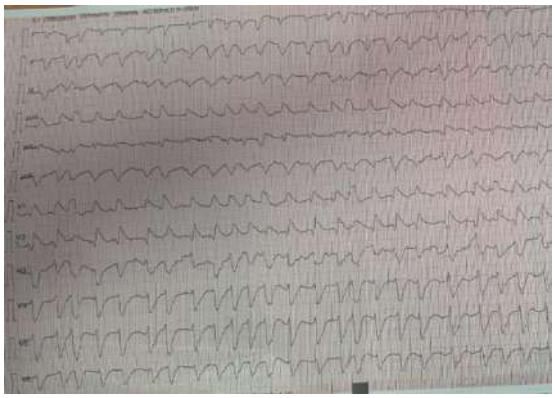

Electrocardiogram obtained after return of spontaneous circulation (ROSC) demonstrating a wide QRS complex

Figure 2

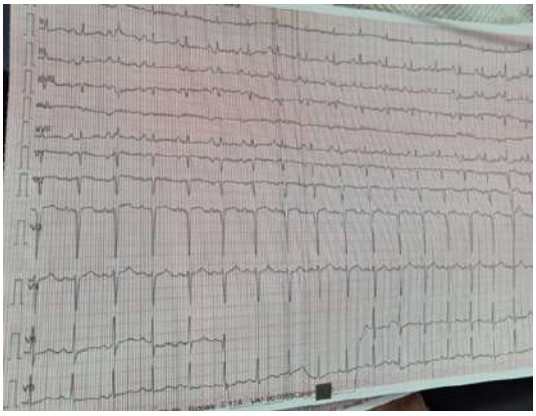

ECG showing narrowed QRS complexes following sodium bicarbonate administration

Results and Conclusion: Toxicological etiologies must be considered in the differential diagnosis of unconscious patients with an unobtainable history presenting with cardiovascular collapse, especially when accompanied by a wide QRS complex. While early sodium bicarbonate therapy improved ECG and hemodynamic parameters, severe TCA poisonings still carry high mortality rates.

Keywords: Tricyclic Antidepressant Poisoning, Cardiac Arrest

Ref No: 1117

Recurrent Emergency Department Visits Within 72 Hours: Clinical Characteristics and Sequential Analysis

Muhammed Eyyüb Polat[1]

[1]Malatya Turgut Ozal University, Malatya/Türkiye

Muhammed Eyyüb Polat / Malatya Turgut Ozal University, Malatya/Türkiye

Introduction and Purpose: Background:Repeated emergency department (ED) visits within 72 hours are an important indicator of healthcare utilization, patient safety, and quality of care. These visits are often associated with low-acuity conditions and may reflect factors beyond clinical necessity. However, most studies evaluate revisit frequency cumulatively, and data analyzing sequential visits (second, third, and fourth) separately are limited.

Materials and Methods: Methods:This retrospective observational study evaluated 5,280 ED visits within a 72-hour period. Among these, 235 patients with recurrent presentations were included. Repeated visits were categorized as second, third, and fourth presentations and analyzed as separate clinical episodes. Demographic characteristics, triage categories, diagnoses, treatments, additional diagnostic testing, consultation rates, and hospitalization outcomes were recorded. Statistical analyses were performed using SPSS 27, with normality assessed by the Kolmogorov–Smirnov test. Appropriate parametric and non-parametric tests were applied.

Results and Conclusion: Results:The median age of patients with recurrent visits was 42 years (IQR: 28-57). Most patients presented twice (91.5%), while three (7.7%) and four (0.9%) visits were rare . The majority of patients were evaluated in the green triage category, with a very low hospitalization rate. The most common diagnoses were upper respiratory tract infections (36.6%) and myalgia (23.4%). Additional diagnostic testing was required in 32.3% of second visits. Although older patients had significantly higher rates of diagnostic testing, consultations, and higher triage acuity, no significant association was found between age and hospitalization. Third and fourth visits were predominantly associated with low-acuity conditions, and patients with four visits had underlying psychiatric disorders without requiring additional interventions.Conclusion:Most recurrent ED visits within 72 hours are related to low-acuity, self-limiting conditions and are rarely associated with adverse outcomes. Sequential analysis suggests that repeated visits are influenced more by symptom perception, patient expectations, and psychosocial factors than by clinical severity. Improving patient education, symptom management, and appropriate healthcare guidance may reduce unnecessary ED utilization.

Table 1. Distribution of Diagnosis Categories Among Patients (n = 235)

Table 1. Distribution of Diagnosis Categories Among Patients (n = 235)		
Diagnosis Category	**Number of Patients (n)**	**Percentage (%)**
Upper Respiratory Tract Infection (URTI)	86	36,6
Myalgia	55	23,4
General Medical Examination	21	8,9
Headache	10	4,3
Urinary Tract Infection (UTI)	9	3,8
Acute Gastroenteritis (AGE)	9	3,8
Abdominal Pain	7	3
Urticaria	6	2,6
Eye Diseases	3	1,3
Dizziness (Vertigo)	2	0,9
Nausea	2	0,9
Other	25	1,6
Total	**235**	**100**

Table 2. Distribution of Diagnosis Categories Among Patients (n = 18)

Table 2. Distribution of Diagnosis Categories Among Patients (n = 18)		
Diagnosis Category	**Number of Patients (n)**	**Percentage (%)**
Myalgia	7	38.9
Upper Respiratory Tract	5	27.8

Infection (URTI)		
General Medical Examination	1	5.6
Nausea	1	5.6
Other	4	22.2
Total	**18**	**100.0**

Keywords: Emergency department, recurrent visits, triage

Ref No: 1151

Dissection or Occlusion?

Bilge Ayyıldız[1], Yeşim Işler[1], Halil Kaya[1], Melih Yüksel[1], Mehmet Oğuzhan Ay[1], Umut Ocak[1]

[1]University of Health Science, Bursa Yuksek Ihtısas Training and Research Hospital, Department of Emergency Medicine, Bursa/Türkiye

Bilge Ayyıldız / University of Health Science, Bursa Yuksek Ihtısas Training and Research Hospital, Department of Emergency Medicine, Bursa/Türkiye

Introduction and Purpose: Arterial occlusions can present to the emergency department not only with impaired tissue perfusion but also with symptoms mimicking myalgia. Following physical examination, Doppler ultrasonography is the first choice; CT angiography is the gold standard for definitive diagnosis. In this case, we address the clinical management of a single-kidney patient who presented to the emergency department with sudden onset back pain radiating to the left arm. The diagnostic approach, imaging strategy, and treatment decision-making process are reviewed in the emergency care.

Materials and Methods: A 65-year-old male patient presented to the emergency department with sudden onset, tearing back pain radiating to the left arm, which had started three hours prior. His medical history included congenital renal agenesis. On physical examination, extremity muscle strength was 5/5 on both sides. Extremity temperature, color, and capillary refill were equal and normal. However, the left radial and ulnar pulses were not palpable. Blood pressure: 80/40 mmHg in the left arm and 130/80 mmHg in the right arm. Given the patient's known history of congenital renal agenesis, initial imaging with Doppler ultrasonography was planned. Doppler US showed detectable arterial flow. However, on repeated examinations,

despite detectable flow with Doppler, the left radial and ulnar pulses were not palpable. Therefore, the patient was assessed as clinically unstable, and emergency CT angiography was performed without waiting for biochemical results. CT angiography revealed complete occlusion of the left subclavian artery. Cardiovascular surgery consultation was performed, and endovascular intervention was planned for the patient.

Figure1: Arterial occlusions

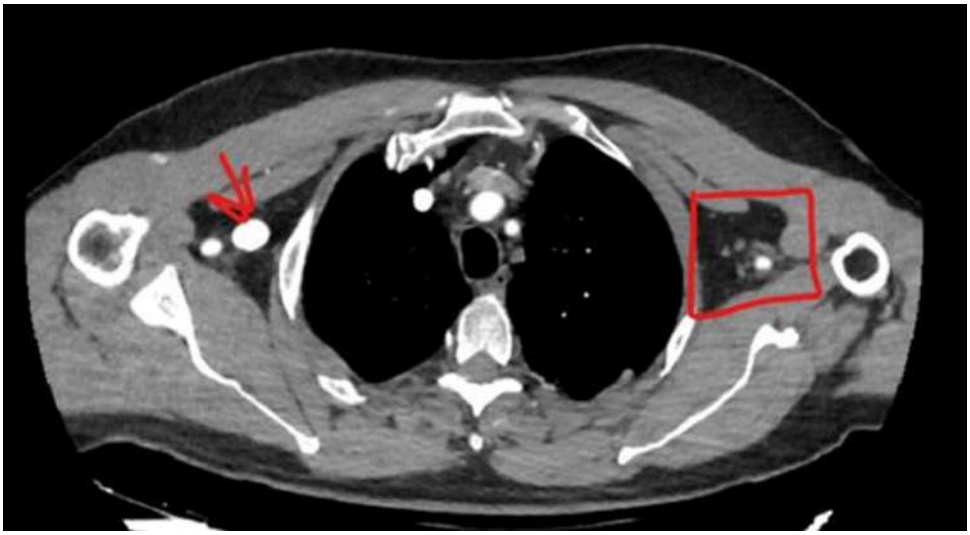

Results and Conclusion: In patients presenting to the emergency department with non-traumatic extremity pain, myalgia is frequently among the preliminary diagnoses. However, life-threatening vascular pathologies with high mortality rates, such as aortic dissection and acute arterial occlusion, should also be considered in the differential diagnosis. Even if skin findings appear normal during extremity examination, pulse assessment is essential. If clinical suspicion persists, bilateral blood pressure measurement and further diagnostic evaluation should be performed. In emergency situations, especially in patients describing sudden onset tearing pain, it is vital to consider not only dissection but also vascular conditions with high mortality rates, such as arterial occlusion.

Keywords: pulse, blood pressure, CT angiography

Ref No: 1165

Preeclampsia in Prehospital Emergency Care: Awareness Levels and the Role of Training

Mustafa Ekici[1], İbrahim Gökçe[1]
[1]Mersin İl Sağlık Müdürlüğü

Mustafa Ekici / Mersin İl Sağlık Müdürlüğü

Introduction and Purpose: Preeclampsia is a pregnancy-specific hypertensive disorder that significantly increases maternal and fetal mortality. Early recognition, appropriate intervention, and timely transfer to an appropriate healthcare facility are critical in prehospital management. This study aimed to determine the level of awareness of preeclampsia among healthcare professionals working in units affiliated with the Provincial Ambulance Service Chief Physician and to evaluate the effect of Prehospital Obstetric Emergencies Training on this awareness.

Materials and Methods: This descriptive study was conducted among emergency medical technicians (EMTs), paramedics, and physicians working within the Provincial Ambulance Service. The required sample size was calculated as 273 with a 95% confidence level and a 5% margin of error; a total of 295 participants were included. Data were collected between March 1 and March 15, 2026, using an 8-item questionnaire administered via Google Forms. Data were analyzed using SPSS version 21, employing descriptive statistics, chi-square tests, and appropriate statistical methods.

Results and Conclusion: Of the participants, 49.8% were paramedics, 47.5% were EMTs, and 2.7% were physicians, with 67.5% being female. Among all participants, 63.4% had received obstetric emergency training. The proportion of participants who correctly defined preeclampsia was 45.4%. While 84.4% correctly identified the medications used in treatment, only 11 participants correctly identified all clinical signs of preeclampsia among 16 listed findings, which included both related and unrelated symptoms. No statistically significant association was found between receiving Prehospital Obstetric Emergencies Training and correctly defining preeclampsia, knowledge of medications, or accurate identification of symptoms ($p > 0.05$).These findings indicate that the level of knowledge regarding preeclampsia among prehospital healthcare professionals is limited. Awareness of preeclampsia among personnel working in prehospital emergency medical services should be improved. The lack of a significant increase in awareness despite prior training suggests that current training programs need to be improved in terms of content, duration, and practical components. Existing training programs appear to have limited effectiveness, and the development of repetitive, practice-oriented training programs is recommended.

Keywords: Awareness, Preeclampsia, Prehospital emergency care

Ref No: 1182

The Relationship Between Lactate and Length of Hospital Stay in Isolated Extremity Gunshot Wounds in the Emergency Department

Ahmet Hakan Taş[1]

[1]Malatya Turgut Özal University, Faculty of Medicine, Department of Emergency Medicine

Ahmet Hakan Taş / Malatya Turgut Özal University, Faculty of Medicine, Department of Emergency Medicine

Introduction and Purpose: Firearm injuries are a significant cause of morbidity and mortality worldwide. In recent years, an increase has been reported, particularly in non-fatal cases. A large proportion involves extremity injuries, and most patients present to the emergency department in a hemodynamically stable condition. Although isolated extremity firearm injuries are generally not life-threatening, they may cause serious morbidity due to vascular, nerve, and soft tissue damage. Additionally, even in low-energy civilian injuries, unpredictable tissue damage related to bullet ballistics can complicate diagnosis and management.Although considered relatively low risk, predicting the clinical course of isolated extremity gunshot wounds remains challenging. This study aimed to evaluate the relationship between routinely measured laboratory parameters and the length of hospital stay.

Materials and Methods: This retrospective study included patients presenting with isolated extremity gunshot wounds between September 2025 and February 2026. Patients with abdominal, thoracic, or cranial injuries were excluded. Demographic data and laboratory parameters, including albumin, C-reactive protein (CRP), platelet count, hemoglobin, neutrophils, monocytes, lymphocytes, pH, and lactate levels, were analyzed. Statistical analyses were performed using SPSS version 27, and relationships were evaluated using Spearman correlation analysis.

Results and Conclusion: A total of 37 patients were included, 94.6% of whom were male. The mean age was 30.84 ± 10.05 years, and the mortality rate was 2.7%. Most patients had normal laboratory values and a stable course. Median lactate level was 2.3 mmol/L, and median hospital stay was 1 day. Lactate showed a moderate positive correlation with hospital stay ($r=0.517$, $p=0.003$). Weak positive correlations were found for CRP ($r=0.355$, $p=0.036$) and age ($r=0.337$, $p=0.042$), while other parameters were not significant.Lactate was the most prominent parameter associated with hospital stay and may serve as a simple biomarker for early risk stratification.

Keywords: Gunshot wound, extremity injury, lactate

Ref No: 1184

Acute Pulmonary Edema Following Hypertonic Saline Administration for the Treatment of Symptomatic Hyponatremia: A Case Report

İSMAİL AKTAŞ[1], HAVVA SERİN YİĞİT[1]
[1]KONYA MERAM STATE HOSPITAL
HAVVA SERİN YİĞİT / KONYA MERAM STATE HOSPITAL

Introduction and Purpose: Hypertonic saline is a frequently used and generally safe therapeutic agent for symptomatic hyponatremia. However, it can lead to serious, albeit rare, complications. In this report, we present the case of a patient who developed acute pulmonary edema following treatment with hypertonic saline.

Materials and Methods: A 72-year-old female patient with a medical history of hypertension and chronic kidney disease presented with nausea and vomiting. On admission, she was lethargic with a blood pressure of 110/70 mmHg. Laboratory results revealed a serum sodium level of 125 mEq/L. Following the diagnosis of symptomatic hyponatremia, treatment with 3% hypertonic saline was initiated.Around the third hour of the infusion, she developed sudden, severe dyspnea and abdominal breathing. Her clinical status rapidly deteriorated; her arterial blood pressure rose to 200/110 mmHg, and her oxygen saturation dropped to 68%. Physical examination revealed rales in the bilateral lung bases, and a chest radiograph showed bilateral diffuse infiltrates, confirming a diagnosis of acute pulmonary edema. The patient was managed emergently with oxygen support, intravenous diuretics, a glyceryl trinitrate infusion, and non-invasive mechanical ventilation (NIV). Her respiratory distress gradually resolved with this comprehensive treatment.

Results and Conclusion: DiscussionSymptomatic hyponatremia necessitates urgent intervention, and controlled correction with hypertonic saline is the recommended approach. However, this therapy demands continuous clinical monitoring, as rapid or high-volume infusions significantly increase the risk of iatrogenic volume overload. This risk is particularly pronounced in vulnerable populations, such as the elderly or those with pre-existing cardiac or renal disease, where an abrupt increase in intravascular volume can elevate pulmonary capillary pressure and trigger pulmonary edema. The literature confirms that pulmonary complications, while infrequent, are a documented risk of hyponatremia treatment. Cases of pulmonary edema have been reported following hypertonic saline administration, highlighting the solution's potential to cause fluid shifts into the lungs.ConclusionThis case illustrates the critical need for close monitoring of vital signs and overall clinical status 'not just serum sodium level' during hypertonic saline therapy. It serves as a reminder of the potent hemodynamic effects and potential pulmonary complications of this life-saving treatment.

before treatment



after treatment

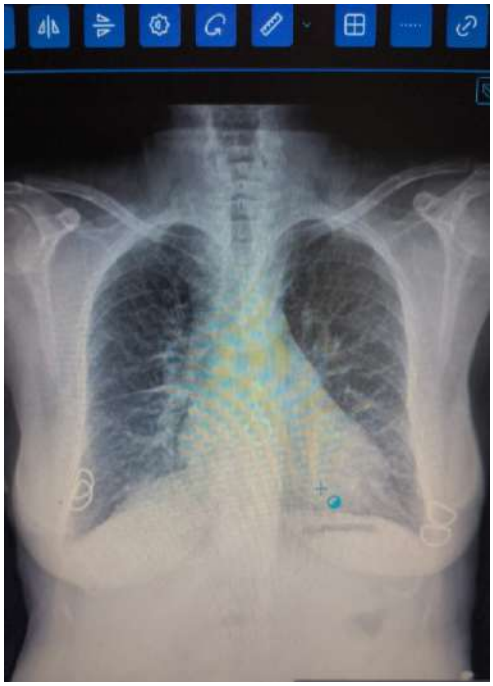

Keywords: Hyponatremia, hypertonic saline, pulmonary edema

Ref No: 1231

The Relationship Between the C-Reactive Protein/Albumin Ratio and Length of Hospital Stay in Patients with Acute Cholecystitis

SEMİH KAYA[1]

[1]MALATYA TURGUT ÖZAL ÜNİVERSİTESİ

SEMİH KAYA / MALATYA TURGUT ÖZAL ÜNİVERSİTESİ

Introduction and Purpose: Acute cholecystitis is one of the most commonly encountered inflammatory hepatobiliary diseases in the emergency department. In recent years, biomarkers reflecting both inflammation and physiological reserve have attracted attention in predicting clinical outcomes. This study aimed to evaluate the relationship between the C-reactive protein/albumin ratio (CAR) and the length of hospital stay in patients with acute cholecystitis

Materials and Methods: A total of 27 patients who presented to the emergency department between February 15, 2026, and March 15, 2026, and were diagnosed with acute cholecystitis were retrospectively analyzed. Demographic data and laboratory parameters were recorded. Variables with normal distribution were expressed as mean ± standard deviation, while non-normally distributed variables were presented as median and interquartile range (IQR). The relationships between length of hospital stay and laboratory parameters were evaluated using Spearman correlation analysis.

Results and Conclusion: Of the 27 patients included in the study, 15 (55.6%) were male and 12 (44.4%) were female. The mean age of the patients was 52.9 ± 14.2 years. The median CRP level was 9.6 mg/L (IQR: 3.4–157), platelet count was 253 ×10⁹/L (IQR: 223–303), and CAR was 0.29 (IQR: 0.11–4.22).Correlation analysis revealed a statistically significant positive relationship between CAR and length of hospital stay ($r = 0.455$, $p = 0.017$). Additionally, a positive correlation was found between CRP and length of hospital stay ($r = 0.465$, $p = 0.014$), while a negative correlation was observed between amylase levels and length of hospital stay ($r = -0.480$, $p = 0.011$).Conclusion:A significant relationship was found between the C-reactive protein/albumin ratio (CAR) and length of hospital stay in patients with acute cholecystitis. CAR may serve as a practical and easily calculable biomarker for assessing the clinical course in patients with acute cholecystitis.

Table 1. Demographic and Laboratory Characteristics of the Study Group

Variables

n
p value
Mean
SD
Median
IQR
25%
75%
age(years)
27
0.935
52,8
14,2
crp (mg/L)
27
<0.001
9,6
3,4
157
albumin (g/L)

27
0.302
37,8
8,09
neutrophile (×10⁹/L)
27
0.262
6,84
2,84
amylase(U/L)
27
0.009
45
31
63
lymphocites(×10⁹/L)
27
0.057
2,61
1,24

plt (×10⁹/L)
27
0.01
253
223
303
hgb (g/dL)
27
0.9
13,6
1,82
monocytes(×10⁹/L)
27
0.417
0,77
0,26
0,76
0,58
0,92

Keywords: Acute cholecystitis, C-reactive protein/albumin ratio, CAR

Ref No: 1244

Clinical Profile, Resource Utilization, and Outcomes in Patients Brought to the Emergency Department by 112 Ambulance Services: A Retrospective

Emine Avlar[1], Bahadir Taslidere[1]

[1]Bezmialem Vakıf University Hospital

Emine Avlar / [1]Bezmialem Vakıf University Hospital

Introduction and Purpose: Patients brought to the emergency department via the 112 ambulance system constitute one of the most significant components of the emergency department workload due to their high clinical severity, increased need for diagnostic procedures, and risk of poor outcomes. This study aimed to evaluate the demographic characteristics, reasons for admission, examination and consultation requirements, and clinical outcomes of patients brought to the emergency department via 112 ambulances over a one-month period.

Materials and Methods: This retrospective observational study included all patients brought to the emergency department by 112 ambulance within a one-month period. Patient data, including age, gender, triage category, reason for admission, laboratory and imaging results, need for consultation, and outcome, were analyzed using the hospital's record system. Descriptive statistics were used to evaluate the collected data.

Findings: A total of 744 patients were included in the study. The mean age of the patients was 58.2±20.1 years, with 377 (50.7%) being male and 367 (49.3%) being female. 477 (64.2%) of the cases were in the yellow zone, 216 (29.0%) in the trauma zone, and 44 (5.9%) in the red zone. The most frequent reasons for presentation were cardiopulmonary causes (n=225, 30.2%) and trauma (n=216, 29.0%), followed by other causes (n=186, 25.0%) and neurological causes (n=113, 15.2%). Laboratory investigations were performed on 659 patients (88.0%), computed tomography on 389 patients (52.0%), and at least one specialist consultation was requested for 317 patients (42.3%). In terms of clinical outcomes, 472 patients (63.0%) were discharged, 121 patients (16.2%) were hospitalized, 26 patients (3.5%) died in the emergency department, and 109 patients (14.6%) refused treatment.

Conclusion: Patients brought to the emergency department by 112 ambulances predominantly constitute a patient group with moderate to severe clinical conditions, requiring intensive diagnostic evaluation and a multidisciplinary approach. The high use of computed tomography, frequent need for consultations, and significant hospitalization rates clearly highlight the clinical complexity of this population. The particularly high rate of treatment refusal is a significant

finding that warrants further investigation, not only from the perspective of patient management but also in terms of the effectiveness of emergency medical services and patient-physician communication.

Keywords: Emergency Department,EMS Ambulance / 112 Ambulance Service,Consultation

---

Ref No: 1252

Bibliometric and conceptual analysis of the cardiopulmonary resuscitation literature in Türkiye

Bora CEKMEN[1], Bahri Ogulcan TABAK[1], Alican UNAL[1], Buse Betul KUCUKKAYA GUNDOGDU[1], Busra BILDIK[1]

[1]Karabuk University, Faculty of Medicine, Department of Emergency Medicine

Alican UNAL / Karabuk University, Faculty of Medicine, Department of Emergency Medicine

Introduction and Purpose: Cardiopulmonary resuscitation (CPR) is a key intervention in sudden cardiac arrest, directly influencing mortality and neurological outcomes. Assessing the scientific output in this field is important for defining the structure of the literature and identifying research priorities. This study aimed to analyze the bibliometric characteristics, research trends, and conceptual structure of CPR-related publications from Türkiye with Turkish corresponding authors.

Materials and Methods: This descriptive bibliometric study searched PubMed using the terms “cardiopulmonary resuscitation,” “advanced cardiac life support,” and “basic cardiac life support.” Duplicates, case reports, letters/editorials, studies not directly related to CPR, and articles with non-Turkish corresponding authors were excluded. Eligible publications were analyzed by publication year, study design, topic, and journal Scientific Journal Rankings (SJR) quartile. Keyword co-occurrence analysis was performed with VOSviewer to assess thematic clustering and temporal trends.

Results and Conclusion: A total of 135 CPR-related publications were identified. A marked increase in scientific output was observed particularly after 2020; 26.7% of the publications were published between 2020 and 2022, and 27.4% between 2023 and 2026. Most studies had an observational design (64.4%), whereas experimental studies and reviews accounted for 28.9% and 6.7%, respectively. The most frequently investigated areas were education/education-simulation (27.4%), CPR quality/techniques/devices (16.3%), and cardiac arrest

outcomes/epidemiology/systems (15.6%). In contrast, extracorporeal cardiopulmonary resuscitation (ECPR)/extracorporeal membrane oxygenation (ECMO) (3.7%) and ethical-legal issues were underrepresented (Table 1). The fact that 76.3% of the publications appeared in Q1-Q2 journals suggests increasing international visibility in this field. In the VOSviewer analysis, the keywords "cardiopulmonary resuscitation" and "observational" were located at the center of the network. The most dominant clusters were organized around education and simulation, clinical outcomes/survival, and CPR quality and technical aspects. Overlay visualization demonstrated that earlier publications focused mainly on survival and epidemiology, whereas more recent studies shifted toward education, simulation, digital media, artificial intelligence, and bibliometric approaches (Figure 1). These findings indicate that the CPR literature in Türkiye has advanced in both quantity and visibility, yet remains an area with substantial room for further development. They also underscore the need for greater emphasis on advanced resuscitation strategies and for increased support of multicenter, outcome-oriented clinical research as priority areas for future investigation.

Figure 1: Keyword Co-occurrence Analysis (VOSviewer)

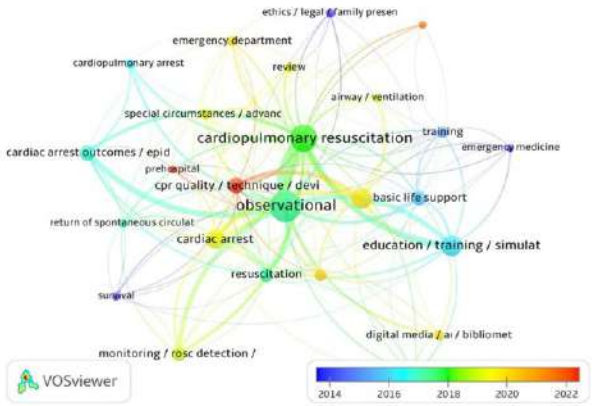

Keyword co-occurrence network of CPR-related publications from Türkiye. Node size reflects the frequency of keyword occurrence, while link thickness represents the strength of co-occurrence between keywords. Colors indicate the average publication year, with warmer colors representing more recent topics.

Table 1: Study Characteristics

Characteristic	n (%)
Publication year	
2003-2010	22 (16.3%)
2011-2015	15 (11.1%)
2016-2019	25 (18.5%)
2020-2022	36 (26.7%)
2023-2026	37 (27.4%)
Study design	
Observational	87 (64.4%)
Experimental	39 (28.9%)
Review	9 (6.7%)
Topic	
Education / Training / Simulation	37 (27.4%)
CPR Quality / Technique / Devices	22 (16.3%)
Cardiac Arrest Outcomes / Epidemiology / Systems	21 (15.6%)
Monitoring / ROSC Detection / Prognostication	17 (12.6%)
Special Circumstances / Advanced Resuscitation	10 (7.4%)
Digital Media / AI / Bibliometrics	9 (6.7%)
Airway / Ventilation	7 (5.2%)
Ethics / Legal / Family Presence / Termination	7 (5.2%)
ECPR / ECMO	5 (3.7%)
Journal SJR quartile	
Q1	54 (40.0%)
Q2	49 (36.3%)
Q3	28 (20.7%)
Q4	3 (2.2%)

Keywords: Cardiopulmonary resuscitation, Bibliometric analysis, Türkiye

Ref No: 1268

Acute mesenteric ischemia presenting with disproportionate abdominal pain

Mehmet Yaşar[1], Fatma Tortum[1]

[1]Ataturk University

Mehmet Yaşar / Ataturk University

Introduction and Purpose: Acute mesenteric ischemia (AMI) is a life-threatening condition characterized by reduced intestinal blood flow, leading to bowel necrosis if not diagnosed early. It often presents with nonspecific symptoms, making early recognition in the emergency department challenging. This case aims to highlight the importance of considering AMI in patients with abdominal pain disproportionate to physical examination findings.

Materials and Methods: A 68-year-old male presented to the emergency department with sudden-onset diffuse abdominal pain. Physical examination revealed minimal abdominal tenderness despite severe pain. Vital signs were stable. Laboratory tests showed mild leukocytosis and elevated lactate levels (3.2 mmol/L). The patient had a known history of atrial fibrillation (AF) without anticoagulation therapy. Contrast-enhanced computed tomography (CT) angiography was performed.

Results and Conclusion: CT angiography revealed superior mesenteric artery thrombosis. The patient was referred for urgent vascular intervention. AMI should be suspected in patients presenting with severe abdominal pain disproportionate to examination findings. Early imaging and prompt management are crucial to reduce morbidity and mortality.

Keywords: Mesenteric ischemia, Abdominal Pain

Ref No: 1311

Perforated strangulated umbilical hernia: a case report.

Sebahattin Akyol[1], Şerife Özdinç[1]

[1]Afyonkarahisar Health Sciences University Faculty of Medicine Department of Emergency Medicine
Sebahattin Akyol / Afyonkarahisar Health Sciences University Faculty of Medicine Department of Emergency Medicine

Introduction and Purpose: Perforated strangulated hernia, although rare, is a life-threatening condition requiring rapid diagnosis and urgent surgical intervention. The aim of this case presentation is to evaluate the clinical findings, treatment methods of patients presenting to the emergency department (ED) with perforated strangulated hernia, in light of the literature.

Materials and Methods: Case Presentation:A 73-year-old female patient presented to the ED with complaints of abdominal pain, nausea, and vomiting that had been ongoing for 3 days. Her vital signs at admission were; blood pressure 130/90 mmHg, pulse 108/min, respiratory rate 22/min, and temperature 36.7°C. Her medical history included diabetes mellitus (DM) and hypertension (HT). She was conscious, and her GCS was assessed as 15. Physical examination revealed a red, swollen, and ecchymotic area approximately 5x5 cm around the navel, and widespread tenderness in the abdomen; no other abnormalities were found in other system examinations. The patient, who underwent ABCD assessment, was hydrated intravenously and oral was stopped. Laboratory findings showed a significant increase in acute phase reactants. Computed abdominal imaging revealed air-fluid levels consistent with widespread ileus in the small bowel loops. A defect of approximately 3 cm in the midline of the abdomen contained intra-abdominal fatty tissue and a hernia of the bowel loops, measuring approximately 8x5.5 cm. Widespread free air was detected in the adjacent subcutaneous fatty tissue within the hernia sac, interpreted as perforation (Figure 1, 2). The patient was consulted with the general surgery clinic. The patient was quickly transferred to the operating room for emergency laparotomy. During the operation, it was learned that in addition to perforation within the hernia sac, ischemic changes were observed in the bowel loops. The patient was discharged on the 15th postoperative day with full recovery. **Figure 1, 2**

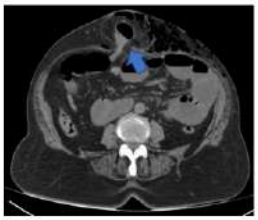

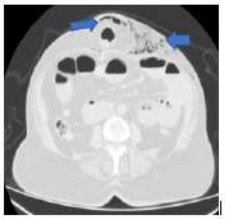

Figure 1: Abdominal CT axial section showed umbilical hernia; 2: in abdominal CT axial sections showed free air in subcutaneous fatty tissue.

Results and Conclusion: No similar cases have been found in the literature. Emergency physicians should also consider the possibility of life-threatening perforation in strangulated umbilical hernias. This case demonstrates that emergency diagnosis and rapid surgical management of perforated strangulated hernias are life-saving.

Keywords: Perforation, hernia, strangulation

Ref No: 1315

Urinary Bladder Herniation into the Inguinal Canal Presenting with Lower Urinary Tract Symptoms: A Case Report

Nevzat HERGÜL1, MEHMET REŞİT ÖNCÜ1, FEDAİ İÇEN1

1Van Yüzüncü Yıl University, Faculty of Medicine

FEDAİ İÇEN / Van Yüzüncü Yıl University, Faculty of Medicine

Introduction and Purpose: Inguinal bladder herniation is a rare condition in which a portion of the urinary bladder protrudes through the inguinal canal. It is often asymptomatic and usually detected incidentally during imaging or surgery. However, in some cases it may present with lower urinary tract symptoms. We present a case of urinary bladder herniation into the inguinal canal extending to the scrotum, presenting with urinary frequency and a fluctuating inguinal swelling.

Materials and Methods: A 60-year-old male presented to the emergency department with a progressively enlarging swelling in the right inguinal region that had been present for approximately three to four weeks. The patient also reported urinary frequency, a persistent sensation of urinary urgency, and right-sided inguinal fullness. He noted that the swelling occasionally decreased after urination but reappeared shortly afterward.On physical examination, a soft, non-tender swelling was observed in the right inguinal region. The mass became less prominent following voiding. Laboratory test results obtained in the emergency department are presented in Table 1.To evaluate the inguinal swelling, a non-contrast abdominal computed tomography (CT) scan was performed. Imaging revealed herniation of the urinary bladder through the right inguinal canal extending into the scrotum (Figure 1-2). No signs of bowel

obstruction or intra-abdominal injury were detectedThe patient was consulted with the general surgery and urology departments for further management and surgical evaluation

Figure 1.



Axial CT image showing right inguinal bladder herniation.

Figure 2



Caudal section demonstrating extension into the scrotum.

table 1

Parameter	**Result**	**Reference Range**
Hematological Parameters		

White Blood Cell (WBC)	7.8	4.0–10.0 ×10³/µL
Hemoglobin	14.2 g/dL	13.0–17.0 g/dL
Platelet	245 ×10³/µL	150–400 ×10³/µL
Biochemical Parameters		
Blood Urea Nitrogen (BUN)	18 mg/dL	7–20 mg/dL
Creatinine	0.9 mg/dL	0.7–1.3 mg/dL
C-Reactive Protein (CRP)	3 mg/L	0–5 mg/L
Urinalysis		
Appearance	Clear	Clear
pH	6.0	5.0–8.0
Red Blood Cells	2 /HPF	0–3 /HPF
White Blood Cells	3 /HPF	0–5 /HPF
Leukocyte Esterase	Negative	Negative
Nitrite	Negative	Negative
Ketone	Negative	Negative

Results and Conclusion: Inguinal bladder hernias are uncommon, accounting for approximately 1–4% of all inguinal hernias. They are more frequently observed in elderly males and may be associated with bladder outlet obstruction, obesity, or weakened abdominal wall musculature. Patients may present with lower urinary tract symptoms, inguinal swelling, or the characteristic finding of swelling that decreases after voiding.Computed tomography plays a crucial role in diagnosis, particularly in atypical presentations. Early recognition is important to prevent complications and to avoid inadvertent bladder injury during hernia repair.Bladder herniation

should be considered in elderly male patients presenting with inguinal swelling accompanied by urinary symptoms. CT imaging is highly useful for confirming the diagnosis and guiding appropriate surgical management.

Keywords: Inguinal bladder hernia, Inguinoscrotal swelling, Inguinal canal

---

Ref No: 1318

Association of Endothelial Activation and Stress Index (EASIX) score with the need for intensive care unit (ICU) admission and proximal thrombus location in patients with pulmonary embolism (PE)

Rabia Hande Avcı[2], Nurbanu Akdoğan[1], Efemert Öztürk[1], Lütfi Anıl Güdek[1], Büşra Bildik[1], Bora Çekmen[1]

[1]Karabuk University, Faculty of Medicine, Department of Emergency Medicine
[2]Karabuk University, Faculty of Medicine, Department of Pulmonology

Lütfi Anıl Güdek / Karabuk University, Faculty of Medicine, Department of Emergency Medicine

Introduction and Purpose: EASIX (Endothelial Activation and Stress Index) is considered to be a prognostic marker of systemic inflammation and endothelial damage. The aim of this study is to investigate the association of the EASIX score with prognostic factors and thrombus localization in patients with PE (pulmonary embolism) admitted to the emergency department.

Materials and Methods: Patients who were diagnosed with PE via CTPA (computed tomography pulmonary angiography) in the emergency department were included in the study. Demographic data, laboratory parameters, length of hospital stay, and mortality status of the patients were retrospectively screened. Based on their clinical outcomes, the patients were divided into two groups: those requiring ICU admission and those who did not. Furthermore, the patients were classified according to radiological thrombus localization as proximal (saddle and lobar) and distal (segmental and subsegmental). Logistic regression analysis was utilized to identify the independent predictors of proximal PE.

Results and Conclusion: The EASIX score, LDH (lactate dehydrogenase) levels, neutrophil counts, length of hospital stay, and mortality rates of the patients admitted to the ICU were found to be significantly higher compared to those who were not admitted to the ICU. When thrombus localization was evaluated, the EASIX score was found to be significantly higher in patients with

saddle and lobar (proximal) locations compared to those with segmental and subsegmental (distal) locations (1.62 and 1.16 vs. 0.82 and 0.63, respectively; $p < 0.001$). ICU admission rates were also observed to be significantly higher in patients with proximal thrombi (83.3% for saddle, 5.9% for subsegmental, $p < 0.001$). The EASIX score was demonstrated to be an independent and significant predictor of proximal PE.Our study indicates that an elevated EASIX score in PE patients is associated with ICU requirement, increased mortality, and proximal thrombus location. Calculating the EASIX score in the emergency department can be a practical parameter for the early recognition of high-risk patients and for risk stratification.

Keywords: Pulmonary embolism, EASIX score, mortality

Ref No: 1331

Sleep quality and associated factors among undergraduate medical students in Mogadishu, Somalia

Yahye Abdullahi[1]

[1]Benadir Universiry

Yahye Abdullahi / Benadir Universiry

Introduction and Purpose: Poor sleep quality is associated with impaired cognitive performance, emotional imbalance, and reduced academic achievement. However, its burden among Somali medical students remains underexplored. This study aimed to assess sleep quality and its associated factors among undergraduate medical students in Mogadishu, Somalia.

Materials and Methods: A descriptive cross-sectional study was conducted among 382 undergraduate medical students using a structured questionnaire. Sleep quality was assessed using the Pittsburgh Sleep Quality Index (PSQI). Data were analyzed using SPSS version 25. Bivariate and multivariable logistic regression analyses were performed to identify predictors of poor sleep quality.

Results and Conclusion: The prevalence of poor sleep quality was 59.2%. Factors significantly associated with poor sleep included being in the second year (aOR = 3.32; 95% CI: 1.47–7.76), third year (aOR = 2.95; 95% CI: 1.26–6.91), being single (aOR = 2.94; 95% CI: 1.32–6.58), spending more than seven hours per day on screens (aOR = 4.37; 95% CI: 1.90–10.08), anxiety (aOR = 1.81; 95% CI: 1.07–3.05), depression (aOR = 1.79; 95% CI: 1.06–3.00), and inadequate sleep darkness (aOR = 0.36; 95% CI: 0.17–0.79). Poor sleep quality is common among medical

students. Interventions targeting screen use, mental health, and sleep environment are recommended.

Marital Status and Academic level of medical students

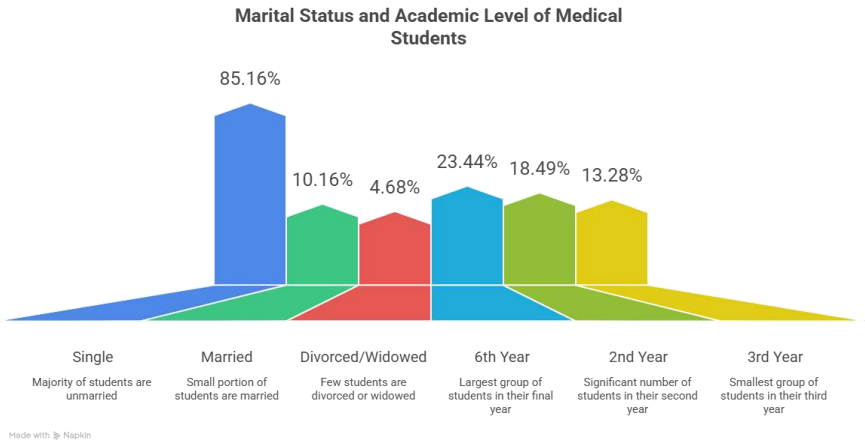

Regarding marital status, most students were single (85.16%), whereas (10.16%) were married and (4.68%) were divorced or widowed. In terms of academic level, students were distributed across different years of study, with the largest proportion in their 6th year (23.44%), followed by the 2nd year (18.49%), while the 3rd year had the lowest representation (13.28%).

Keywords: Academic performance, Medical students, Sleep quality

---

Ref No: 1342

Traumatic diaphragmatic rupture associated with silent skeletal injuries: the importance of systematic imaging in multi-trauma

Muhammed Sadettin İpek[1], Mustafa Polat[1], Emre Gök[1], Cumali Deligöz[1], Mehmet Gül[1]
[1]Emergency Medicine Department, Konya City Hospital, Türkiye
Emre Gök / Emergency Medicine Department, Konya City Hospital, Türkiye

Introduction and Purpose: As frequently emphasized in emergency medicine practice and multitravma literature, high-energy blunt trauma is a significant cause of morbidity and mortality. Traumatic diaphragmatic rupture (TDR) is a major indicator of severe trauma; however, it may remain clinically silent and can be overlooked during initial imaging.

Materials and Methods: A male patient who fell from the second floor was referred to our emergency department for further investigation and treatment after being evaluated at an external center, where his oxygen saturation was measured at 80% and a posteroanterior (PA) chest X-ray revealed left hemidiaphragm elevation and rib fractures. Upon arrival at the resuscitation room, the patient's general condition was stable with a Glasgow Coma Scale (GCS) score of 15. The patient reported significant pain in the left shoulder and back. Under oxygenation via a reservoir mask, his saturation was 98%, blood pressure was 130/80 mmHg, and heart rate was 67 bpm. Other extremity examinations were unremarkable; there was no pelvic tenderness. The left lower extremity showed full range of motion, neurovascular examination was intact, peripheral pulses were palpable, sensory examination was normal, and muscle strength was 5/5. Thoracoabdominal CT imaging revealed elevation of the stomach and spleen secondary to a left diaphragmatic rupture, non-displaced fractures of the 2nd and 3rd ribs, and displaced fractures of the 4th, 5th, 6th, and 7th ribs on the left side. Additionally, a fracture line in the right anterior pubis, a linear fracture line in the left sacrum, and a left femoral neck fracture were identified. L1 and L2 transverse process fractures were also detected in the lumbar region. The patient's life-threatening condition was detailed to his relatives, and emergency surgical repair and a follow-up plan were initiated

Results and Conclusion: In multi-trauma patients, dominant pain foci may mask life-threatening silent skeletal and visceral injuries. A systematic radiological imaging approach involving whole-body scanning, rather than a complaint-oriented assessment, combined with emergency multidisciplinary evaluation is the most critical step in preventing mortality associated with missed diagnoses.

Keywords: Traumatic diaphragmatic rupture, silent skeletal injuries, emergency department

---

Ref No: 1367

A Rare Cause of SCIWORA: Ischemıc Stroke

Cem Doğan[1], Muhammet Onur Yurten[1], Pelin Kaya[1], Tuba Ekmekyapar[2], Nurettin Aktaş[1], Muhammed Ekmekyapar[1]

[1]Department of Emergency Medicine, Elazığ Fethi Sekin City Hospital, Elazığ, Türkiye
[2]Department of Neurology, Elazığ Fethi Sekin City Hospital, Elazığ, Türkiye

Muhammed Ekmekyapar / Department of Emergency Medicine, Elazığ Fethi Sekin City Hospital, Elazığ, Türkiye

Introduction and Purpose: Spinal Cord Injury Without Radiographic Abnormality (SCIWORA) is a term used for cases showing clinical signs of spinal cord injury but without radiographic evidence after trauma. It is commonly seen after flexion-extension injuries. The diagnosis of SCIWORA is based on physical examination and MRI findings. This condition, which is quite rare in adults, should be considered in all patients presenting with post-traumatic neurological deficits but without any pathology seen on conventional radiography or computed tomography (CT).

Materials and Methods: A 59-year-old female patient fell to the ground following vision loss in her left eye and presented to the emergency department with numbness and weakness in all four limbs, more pronounced in the lower limbs, following the fall. Radiological imaging was ordered for the patient. The brain CT was normal, and there was no fracture or subluxation on cercival CT. Diffusion-weighted magnetic resonance imaging (MRI) was planned for the patient, who was suspected of having an ischemic stroke, and diffusion restriction was observed in the right occipital region. Neurology and neurosurgery consulted were placed for the patient. Since the patient's clinical condition could not be explained by the existing radiological images, cervical and thoracic MRI scans were performed on the patient. The patient's cervical MRI showed significant anterior compression of the spinal cord at the C4-C5 levels. The patient was hospitalized by the neurosurgery clinic.



Figure-1: Cervical CT image

Figure-2: Diffusion restriction in the right occipital region on brain diffusion MRI

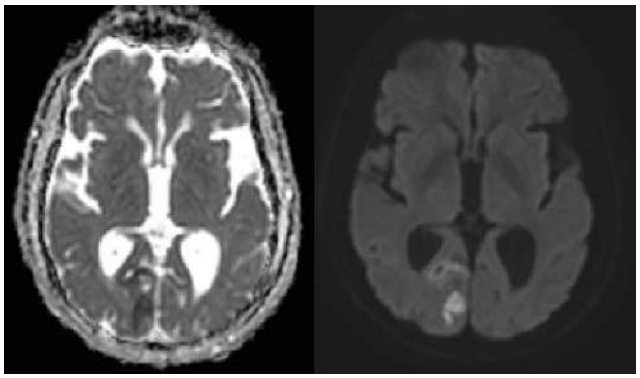

Figure-3: Significant anterior compression of the spinal cord at the C4-C5 levels on cervical MRI

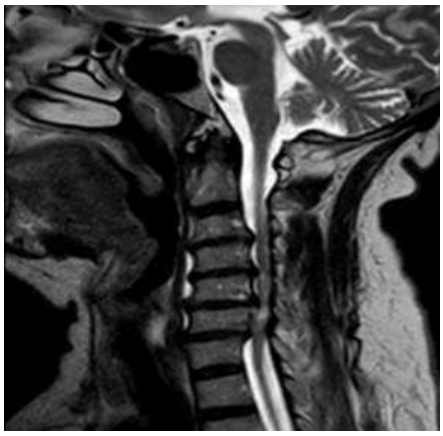

Results and Conclusion: The diagnosis of SCIWORA is made based on physical examination and MRI. A careful neurological examination is crucial for assessing neurological deficits that may appear even several days after the injury. MRI can identify pathologies of nerve tissues, including intervertebral discs, the spinal cord, and nerve roots; therefore, it has become the gold standard imaging modality in patients with suspected spinal cord injury. Considering the neurological deficits that occur in these patients, SCIWORA should be included among the differential diagnoses, and spinal MRI should be considered.

Keywords: Ischemic stroke, SCIWORA, spinal MRI

Ref No: 1389

Retrospective and Pharmacotherapeutic Evaluation of Narcotic Analgesic Use in the Emergency Department

Betül ALTAN[1], Sultan Tuna AKGÖL GÜR[2], Yusuf Burak EKER[2]

[1]Atatürk University, Faculty of Pharmacy, Department of Clinical Pharmacy
[2]Atatürk University, Department of Emergency Medicine

Yusuf Burak EKER / Atatürk University, Department of Emergency Medicine

Introduction and Purpose: Pain is one of the most common reasons for presentation to emergency departments worldwide and, when inadequately managed, may impair functional capacity and quality of life. Effective pain control is therefore a key component of emergency medical care.Acute pain management in the emergency department aims to reduce pain intensity and improve patient comfort using appropriate pharmacological interventions. Narcotic analgesics, particularly opioid derivatives, are effective in treating moderate to severe acute pain but are associated with dose-dependent adverse effects, including respiratory and central nervous system depression, as well as risks of tolerance, dependence, and misuse. In the context of the global opioid crisis, the rational and safe use of opioids in emergency settings is essential.The aim of this oral presentation is to retrospectively evaluate the use of narcotic (opioid) analgesics in the emergency department and assess their appropriateness regarding dosage, indication, and route of administration.

Materials and Methods: This retrospective study was conducted in the emergency department of Iğdır Dr. Nevruz Erez State Hospital and included 29 patients who received narcotic analgesics between 17 November 2025 and 23 November 2025. Patient data were retrospectively reviewed using electronic medical records. Evaluated variables included demographic characteristics, administered analgesics, routes of administration, vital signs, changes in oxygen saturation, electrocardiographic findings, and the occurrence of drug-related adverse events.

Results and Conclusion: Of the 29 patients included, 14 were female and 15 were male, with a mean age of 49.79 years. Ramadex was administered to the majority of patients, while a small number received combination therapy with fentanyl or ketamine. Routes of administration were selected according to clinical indications. Low oxygen saturation at presentation was observed in three patients; persistent desaturation following analgesic administration occurred in only one patient. No clinically significant drug-related adverse effects were reported. Electrocardiographic monitoring demonstrated normal rhythm and conduction parameters when performed. The demographic characteristics of the patients and the reasons for emergency department admission are summarized in Table 1.Overall, the findings indicate that narcotic analgesics were used safely and appropriately in the emergency department. Tramadol emerged as a frequently preferred and well-tolerated agent, highlighting the importance of rational pharmacotherapy in emergency pain management.

Table 1. Distribution of Reasons for Emergency Department Admission Among Included Patients (n = 29)

Reason for Admission	Number of Patients (n)	Percentage (%)
Acute Pain	7	24.1

Reason for Admission	Number of Patients (n)	Percentage (%)
Abdominal Pain	5	17.2
Cancer-Related Pain	4	13.8
Trauma	3	10.3
Low Back / Neck Pain	3	10.3
Renal Colic	2	6.9
Syncope	1	3.4
Acute Cystitis	1	3.4
Allergy	1	3.4
Migraine	1	3.4
Postoperative Pain	1	3.4
Total	**29**	**100.0**

Keywords: Emergency department, Pain management, Opioids

Ref No: 1438

To investigate the clinical significance of the HALP score in pediatric patients with acute appendicitis

Ömer Faruk Öngenli[1]

[1]Malatya Turgut Özal Üniversitesi

Ömer Faruk Öngenli / Malatya Turgut Özal Üniversitesi

Introduction and Purpose: To evaluate the relationship between the HALP score (hemoglobin, albumin, lymphocyte, platelet) and length of hospital stay in pediatric patients with acute appendicitis and to investigate the potential use of this score in predicting clinical course.

Demographic and laboratory data of pediatric acute appendicitis patients

DEĞİŞKENLER	N	p değeri	Anlam	SD	medyan	IQR %25	IQR %75
Yaş (yıl)		0,231	11,9	0,7			
WBC(×10³/µL)		<0,001			14,6	11,3	21,3
Hemoglobin (g/dL)		0,315	13,1	0,2			
Nötrofil (×10³/µL)		<0,001			12,3	9,4	18
Lenfosit (×10³/µL)		0,137	1,3	0,1			
YARDIM		0,032			0,2	0,1	0,2
Üre (mg/dL)	26	0,298	27,2	1,3			
Kreatinin (mg/dL)		0,006			0,6	0,5	0,6
Albumin (g/dL)		0,001			4,3	3,8	4,6
Trombositler (×10³/µL)		0,086	313	11			
CRP (mg/L)		<0,001			2,2	0,3	5,5
Potasyum (mmol/L)		0,026			4	3,8	4,3
MİSAFİRLİK (gündüz)		0,203	3,7	0,3			

Materials and Methods: This retrospective study includes pediatric patients with acute appendicitis who presented to the emergency department of Malatya Training and Research Hospital between September 15, 2025 and March 15, 2026. A total of 26 patients with sufficient clinical and laboratory data were included in the study. Demographic data, laboratory parameters (WBC, hemoglobin, albumin, neutrophil, lymphocyte, platelet, CRP, creatinine, urea, potassium), and length of hospital stay were obtained from the hospital record system. In statistical analysis, variables with normal distribution were presented as mean ± standard

deviation, and non-normally distributed variables were presented as median and IQR. The relationship between HALP score and length of hospital stay was evaluated using Spearman correlation test; $p < 0.05$ was considered statistically significant.

Results and Conclusion: Results:The study population consisted of 26 patients, and the mean age was determined as 11.9 ± 0.7 years. A significant negative correlation was found between HALP score and length of hospital stay ($r = -0.42$, $p = 0.032$). Although no significant relationship was found when the components of the HALP score were evaluated individually, the composite score was observed to be associated with clinical outcomes. Additionally, a negative correlation was detected between hemoglobin level and length of hospital stay. These findings support that the HALP score has a stronger prognostic potential than single parameters, as it simultaneously reflects inflammation and nutritional status.Conclusion:A significant negative relationship was found between HALP score and length of hospital stay in pediatric patients with acute appendicitis. The HALP score may be considered as a simple, inexpensive, and easily applicable biomarker in predicting the clinical course of the disease. However, larger sample-sized, multicenter, and prospective studies are needed to confirm these findings

Keywords: Pediatric acute appendicitis, HALP score, Length of hospital stay

---

Ref No: 1442 **Sudden Visual Loss Due to Methanol Inhalation: A Case Report**

İsa Yıldırım[1], Mehmet Ali Çağatay[1], Ozan Deniz Keleş[1], Ahmet Melih Savaş[1], Selçuk Eren Çanakçı[1]

[1]Department of Emergency Medicine, Faculty of Medicine, Aydın Adnan Menderes University, Aydın, Turkey

İsa Yıldırım / Department of Emergency Medicine, Faculty of Medicine, Aydın Adnan Menderes University, Aydın, Turkey

Introduction and Purpose: Methanol toxicity is a severe clinical condition typically observed following the consumption of counterfeit or illicit alcohol. In the liver, methanol is metabolized by the enzyme alcohol dehydrogenase into formaldehyde and subsequently into formic acid. Formic acid inhibits the cytochrome oxidase enzyme, thereby preventing oxidative phosphorylation and leading to cellular hypoxia. The most characteristic findings of methanol poisoning include high anion gap metabolic acidosis, an increased osmolar gap, and visual disturbances. The optic nerve and retinal tissue are highly sensitive to the toxic effects of formic acid. Consequently, patients may develop blurred vision, photophobia, papilledema, and permanent blindness. Although methanol exposure usually occurs via ingestion, toxicity can rarely develop following the inhalation of industrial solvents and paint products.

Materials and Methods: A 65-year-old male presented to the emergency department with a sudden onset of bilateral visual loss. The patient also reported experiencing occasional light flashes (photopsia). While he had no history of alcohol consumption, it was noted that he worked as a painter. Physical examination revealed the patient was conscious, oriented, and cooperative. Pupils were isochoric and midline; however, neither direct nor indirect light reflexes could be elicited. Other systemic examinations were unremarkable. Brain CT and diffusion-weighted MRI were performed to rule out central nervous system pathologies and appeared normal. Blood gas analysis revealed metabolic acidosis with an increased anion gap and an elevated osmolar gap. Based on the clinical presentation and occupational history, methanol intoxication due to inhalation was diagnosed. Emergency dialysis and ethanol therapy were initiated. Following treatment, the patient's acidosis significantly improved, though no substantial recovery in visual loss was observed.

Results and Conclusion: Methanol toxicity can result from occupational inhalation exposure, not just oral ingestion. In patients presenting with sudden visual loss and metabolic acidosis, occupational history must be carefully scrutinized. Early diagnosis and appropriate treatment can reduce the risk of mortality and permanent vision loss

Keywords: visual loss, inhalation, methanol

Ref No: 1477

Rapid Diagnosis of Sudden Onset Chest Pain with bedside ultrasonography: A Case Report

Ali Tayyip Kömürcü[1], Gökhan Yılmaz[1], Muhammet Gökhan Turtay[1], Nezime Beyza Yıldırım[1], Ceren Efsane Kellecioğlu[1], Ahmet Muhammet Şahingeri[1]

[1]University of Health Sciences, Beyhekim Training and Research Hospital, Emergency Medicine Clinic, Konya, Türkiye.

Muhammet Gökhan Turtay / University of Health Sciences, Beyhekim Training and Research Hospital, Emergency Medicine Clinic, Konya, Türkiye.

Introduction and Purpose: In our case, we presented a 47-year-old male patient with a hyperacute aortic dissection. We evaluated the role of bedside ultrasonography in the diagnosis of dissection and the diagnosis and treatment processes of these patients.

Materials and Methods: The 47-year-old male patient, who was brought to the emergency department by emergency medical services (112) with sudden-onset back and chest pain. The patient stated that after eating, he suddenly felt as if a bomb had exploded in his epigastric region, followed by back and chest pain, which then radiated to his entire body. He noted that the pain decreased upon standing and increased when lying down. He had no medical history other than gastritis and was not on any regular medication. On physical examination, his abdomen was relaxed, breath sounds were normal, and the neurological examination was unremarkable. The patient expressed that when he turned prone during the examination, the pain radiated to his chest. The patient's electrocardiogram showed a normal sinus rhythm, and on bedside ultrasonography, the aortic valve was measured at 60.4 mm at the valve level, and a bicuspid aortic valve with surrounding thrombus was observed. The patient's contrast-enhanced computed tomography revealed a dissection flap in the ascending aorta, aortic arch, descending thoracic aorta, abdominal aorta, and both main iliac arteries. The patient was consulted for cardiovascular surgery. The patient died during the intensive care unit follow-up after the aortic operation.

Figure 1

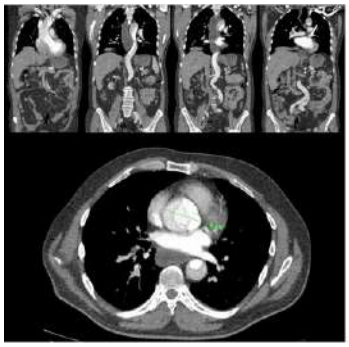

Figure 2



Figure 1. Thrombus appearance at the aortic valve level with TTE.

Figure 2. Dissection flap extending from the ascending aorta to the iliac arteries on contrast-enhanced CT.

Results and Conclusion: Aortic dissection is a critical diagnosis in patients presenting with chest pain, carrying a high risk of death, and bedside ultrasonography is crucial for rapid diagnosis.

Keywords: Aortic dissection, Chest pain, Ultrasonography

Ref No: 1508

New-Onset Seizure Complicated by Aspiration and Cardiac Arrest in Suspected Encephalitis

Mehmet ÇABUK[1], Nevzat HERGÜL[1], Sevdegül KARADAŞ[1]

[1]Yuzuncu Yil University, Medical School Hospital, Van, Türkiye

Mehmet ÇABUK / Yuzuncu Yil University, Medical School Hospital, Van, Türkiye

Introduction and Purpose: New-onset seizures in elderly patients require careful evaluation because they may indicate serious underlying neurological disease. Encephalitis is an important consideration in this setting and may present with seizures, altered mental status, and nonspecific neurological findings. Although seizures are a known manifestation of encephalitis, aspiration followed by cardiac arrest is an uncommon and life-threatening complication. We present an elderly patient with new-onset seizures complicated by aspiration and cardiac arrest, in whom cerebrospinal fluid findings suggested encephalitis.

Materials and Methods: A 78-year-old woman with no known chronic disease and no history of epilepsy experienced a generalized tonic-clonic seizure at home during the night. According to relatives, the episode was accompanied by involuntary movements and foaming at the mouth. During transportation to the hospital, she developed another generalized seizure in the ambulance, aspirated gastric contents, and subsequently developed cardiac arrest. Cardiopulmonary resuscitation was initiated immediately, and return of spontaneous circulation was achieved after approximately two minutes. The patient was intubated and transferred to the emergency department. On arrival, blood pressure was 120/70 mmHg, oxygen saturation was 95%, and body temperature was 36°C. Neurological examination revealed a Glasgow Coma Scale score of 3. Pupillary examination showed anisocoria. Electrocardiography demonstrated normal sinus rhythm. Brain computed tomography, diffusion-weighted magnetic resonance imaging, pulmonary CT angiography, and thoracoabdominal CT angiography revealed no acute pathology. Laboratory findings are presented in Table 1. Because of unexplained new-onset seizures, lumbar puncture was performed. Cerebrospinal fluid analysis demonstrated lymphocytic pleocytosis and elevated protein levels. Cerebrospinal fluid findings are shown in Table 2. The patient was admitted to the neurology intensive care unit with suspected encephalitis.

Table 1

Parameter	Result	Reference Range
White blood cell (WBC)	11.6 ×10⁹/L	4.0–10.0
Hemoglobin (Hb)	10.9 g/dL	12-17
C-reactive protein (CRP)	2 mg/L	<5
Sodium (Na)	139 mmol/L	135–145
Potassium (K)	3.5 mmol/L	3.5–5.1
Lactate	5.79 mmol/L	0.5–2.0
Glucose	130 mg/dL	70-110

Laboratory findings of the patient on admission

Table 2

Parameter	Result	Reference Range
CSF(cerebrospinal fluid)cell count	75 cells/mm³	0–5
Lymphocyte ratio	90%	–
Protein	68 mg/dL	15–45
CSF/Serum glucose ratio	0.7	>0.6

Cerebrospinal fluid findings

Results and Conclusion: Aspiration is a serious complication of seizures and may lead to respiratory failure or cardiac arrest. In elderly patients presenting with new-onset seizures, secondary causes such as central nervous system infection should be considered. In this case, imaging studies did not reveal acute structural pathology, whereas cerebrospinal fluid analysis supported an inflammatory process consistent with encephalitis. This case highlights the importance of lumbar puncture when imaging is inconclusive and emphasizes that early recognition of the underlying neurological cause may be critical for timely management

Keywords: Seizure, aspiration, encephalitis

Ref No: 1544

Myopericarditis in the emergency department: navigating the spectrum between pericarditis and myocarditis

Feriza Nur Babayiğit[1], Nazlı Karakuş Kenan[1], Esra Elif Turgut[1], Demet Acar[1], Mehmet Gül[1]

[1]Emergency Medicine Department, Konya City Hospital, Turkiye

Feriza Nur Babayiğit / Emergency Medicine Department, Konya City Hospital, Turkiye

Introduction and Purpose: Acute pericarditis is a disease characterized by inflammation of the pericardium, often developing after viral infections. The change in chest pain with position and electrocardiographic findings play an important role in diagnosis. When myocardial involvement accompanies it, the condition is referred to as myopericarditis.

Materials and Methods: A 28-year-old male patient presented while receiving symptomatic treatment due to a sore throat, nighttime fever, and widespread joint pain that had been ongoing for approximately one week. He described chest pain that began the night before admission and lasted about 3 hours. The pain was stabbing in nature, decreased when leaning forward, worsened when lying down, and was relieved by sitting.Based on the current clinical, electrocardiographic, and biochemical findings, the patient was admitted to the cardiology service with a preliminary diagnosis of myopericarditis. As treatment, a nonsteroidal anti-inflammatory drug and colchicine were initiated; in addition, physical activity restriction and rest were recommended. During the follow-up period, the patient's clinical condition remained stable, and they were discharged after 2 days.

Results and Conclusion: Acute pericarditis and myopericarditis are among the important causes of chest pain, especially in young patients, and they often develop after viral infections. A history

of upper respiratory tract infection is an important clinical clue in this regard. Electrocardiographically, diffuse ST segment elevations can be observed in pericarditis, while in some cases the changes may be limited. In this patient, minimal ST elevation in the lateral leads was evaluated together with the clinical findings. Elevated troponin is an indicator of myocardial involvement, and this condition is defined as myopericarditis. Acute coronary syndrome must definitely be excluded in the differential diagnosis. Nonsteroidal anti-inflammatory drugs and colchicine constitute the main approach in treatment. In the emergency department, when positional chest pain and elevated troponin are evaluated together, the diagnosis of myopericarditis should be considered. With early diagnosis and appropriate treatment, the prognosis is generally good.

Keywords: pericarditis, chest pain, myopericarditis

Ref No: 1554

An Unexpected Peril in Treatment-Resistant Schizophrenia: Management of Late-Onset Clozapine-Induced Agranulocytosis and Septic Shock

Ahmet Celal ÖZSOY[1]

[1]University of Health Sciences, Sanliurfa Mehmet Akif Inan Training and Research Hospital, Department of Emergency Medicine

Ahmet Celal ÖZSOY / University of Health Sciences, Sanliurfa Mehmet Akif Inan Training and Research Hospital, Department of Emergency Medicine

Introduction and Purpose: ABSTRACTIntroduction: Clozapine is a second-generation antipsychotic and the only approved medication for treatment-resistant schizophrenia, known for significantly reducing mortality and suicide risk. However, its use is strictly regulated due to life-threatening side effects, most notably idiosyncratic clozapine-induced agranulocytosis (CIA). While the majority of cases occur within the first eighteen weeks of treatment, the risk of late-onset agranulocytosis persists indefinitely.

Materials and Methods: Case Presentation: A 45-year-old male with schizophrenia, who had been on clozapine therapy for eight months, presented to the emergency department with a three-day history of worsening fever, malaise, and sore throat. The patient had neglected his routine hematological monitoring for the preceding two months. Upon examination, he exhibited signs of septic shock, including a temperature of 39.4°C, hypotension (84/52 mmHg), and tachycardia.

Laboratory findings confirmed severe agranulocytosis with an absolute neutrophil count (ANC) of 80/mm³ and elevated inflammatory markers.

Figure-1: Thoracic CT imaging: Bilateral infiltrates consistent with neutropenic infection

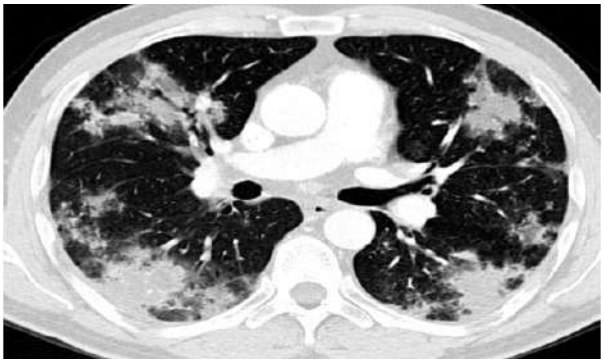

Figure-1: Thoracic CT imaging: Bilateral infiltrates consistent with neutropenic infection

Results and Conclusion: Management and Outcome: Clozapine was immediately and permanently discontinued. The patient was admitted to the intensive care unit and treated with aggressive fluid resuscitation, broad-spectrum antibiotics (carbapenem and vancomycin), and granulocyte colony-stimulating factor (G-CSF). Following 16 days of intensive therapy, the patient showed significant clinical and laboratory improvement and was discharged in stable condition.Conclusion: This case highlights the unpredictability of late-onset clozapine-induced agranulocytosis. It underscores the vital necessity for strict, long-term hematological surveillance and the life-saving role of early diagnosis, drug discontinuation, and rapid administration of G-CSF and antimicrobial therapy.

Keywords: Clozapine-induced agranulocytosis, Septic shock, Granulocyte colony-stimulating factor (G-CSF)

Ref No: 1558

A Silent but Dangerous Complication: Retroperitoneal Hemorrhage After Bone Marrow Biopsy

Furkan Öztürk[1], Berat Yıldız[1], Cüneyt Arıkan[1]

[1]Dokuz Eylül University Faculty of Medicine, Department of Emergency Medicine, Izmir, Türkiye

Berat Yıldız / Dokuz Eylül University Faculty of Medicine, Department of Emergency Medicine, Izmir, Türkiye

Introduction and Purpose: Bone marrow aspiration and biopsy are widely used invasive procedures for the diagnosis and follow-up of hematological disorders. Although generally considered safe, they carry a low but significant risk of complications, with an incidence of approximately 0.05–0.12%. While most complications are minor, such as local pain or small hematomas, rare vascular injuries may result in life-threatening hemorrhage. Retroperitoneal bleeding due to pelvic vessel injury is an uncommon but critical complication that requires prompt recognition and intervention.

Materials and Methods: A 69-year-old female presented to the emergency department with sudden onset groin pain and near-syncope following a bone marrow biopsy performed earlier the same day. On admission, she was somnolent but responsive (GCS 14), with hypotension (90/56 mmHg) and bradycardia (45 bpm). Physical examination revealed lower abdominal and right iliac tenderness, with prolonged capillary refill. Her medical history included hypertension, atrial fibrillation and she was receiving rivaroxaban therapy.Initial laboratory findings showed a hemoglobin level of 13.5 g/dL, which dropped to 9.9 g/dL on repeat testing. Bedside ultrasonography demonstrated free intraperitoneal fluid. Computed tomography angiography revealed a large retroperitoneal hematoma involving the right iliopsoas region with active contrast extravasation from distal branches of the internal iliac artery. A non-displaced fracture line in the posterior iliac bone was also observed. Multidisciplinary consultation was performed, and bleeding was successfully controlled via selective arterial embolization by interventional radiology. The patient stabilized hemodynamically and was discharged without complications after follow-up.



Retroperitoneal Hematoma -1 Retroperitoneal Hematoma -2

Arterial extravasation

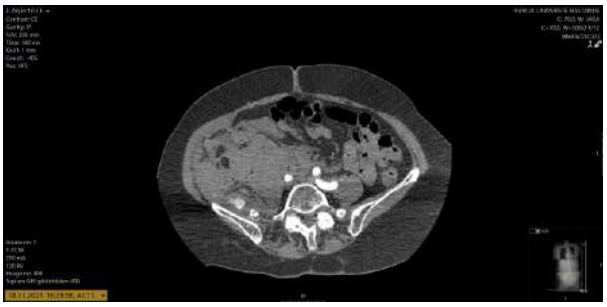

Fracture-1 Fracture-2



Results and Conclusion: Retroperitoneal hemorrhage following bone marrow biopsy is rare but potentially fatal. Clinical presentation may be nonspecific, including groin pain, syncope, or hypotension, which can delay diagnosis. In patients using anticoagulants or beta-blockers, typical compensatory responses may be masked, further complicating recognition. While bedside ultrasonography is useful for initial evaluation, computed tomography angiography remains the gold standard for diagnosis. Endovascular embolization is an effective and minimally invasive treatment option in stable or stabilized patients.Clinicians should maintain a high index of suspicion for retroperitoneal hemorrhage in patients presenting with unexplained hypotension, hemoglobin drop, or pelvic pain after bone marrow biopsy. Early diagnosis, appropriate imaging, and timely multidisciplinary intervention are essential to reduce morbidity and mortality.

Keywords: Bone Marrow Biopsy, Retroperitoneal Hemorrhage, Arterial Embolization

Ref No: 1575

Metoclopramide-Induced Reversible Splenial Lesion Syndrome (RESLES): A Case Report

Abdussamed VURAL[1], Recep Kemal SOYLU[1]

[1]Department of Emergency Medicine, Niğde Ömer Halisdemir University Faculty of Medicine, Niğde, Türkiye

Abdussamed VURAL / Department of Emergency Medicine, Niğde Ömer Halisdemir University Faculty of Medicine, Niğde, Türkiye

Introduction and Purpose: Metoclopramide is a dopamine receptor antagonist widely used as a prokinetic and antiemetic agent.Extrapyramidal reactions including acute dystonia, tardive dyskinesia, parkinsonism, akathisia, and neuroleptic malignant syndrome are well-recognized adverse effects, with an estimated incidence of approximately 0.2%. Reversible splenial lesion syndrome (RESLES) is a rare clinicoradiological entity characterized by transient diffusion restriction in the splenium of the corpus callosum and has been associated with infectious, metabolic, toxic, and drug-related etiologies.Although drug-induced RESLES has been reported in the context of supratherapeutic exposure or polypharmacy, isolated splenial diffusion restriction following a single therapeutic dose of metoclopramide has not been previously described. Given its potential to mimic acute ischemic stroke, failure to recognize this entity may lead to misdiagnosis and unnecessary interventions. Herein, we report a unique case of metoclopramide-induced RESLES following therapeutic dose.

Materials and Methods: Case Report:A 22-year-old woman with no significant past medical history presented to the emergency department with acute cervical muscle spasm.She reported a three-day history of cough, sputum production, chills, nausea, vomiting, and diarrhea, and had self-administered two 10 mg tablets of metoclopramide (total dose: 20 mg). Acute drug-induced dystonia was diagnosed, and intramuscular biperiden (5 mg) was administered, resulting in rapid resolution of symptoms. Subsequently, the patient developed a severe headache. Vital signs and physical examination were unremarkable. Neurological examination revealed no focal deficits or meningeal signs, and the patient was fully alert and oriented. Laboratory investigations were within normal limits, and non-contrast cranial computed tomography showed no abnormalities. Diffusion-weighted brain magnetic resonance imaging (MRI), performed eight hours after presentation, demonstrated restricted diffusion in the splenium of the corpus callosum. The patient was admitted following neurology consultation.Cerebrospinal fluid analysis and additional serological tests were unremarkable. Contrast-enhanced MRI revealed no additional pathology.The patient was discharged on hospital day three without complications. A follow-up MRI performed three months later demonstrated complete resolution of the lesion, with no residual neurological deficits.

Figure 1. A-B

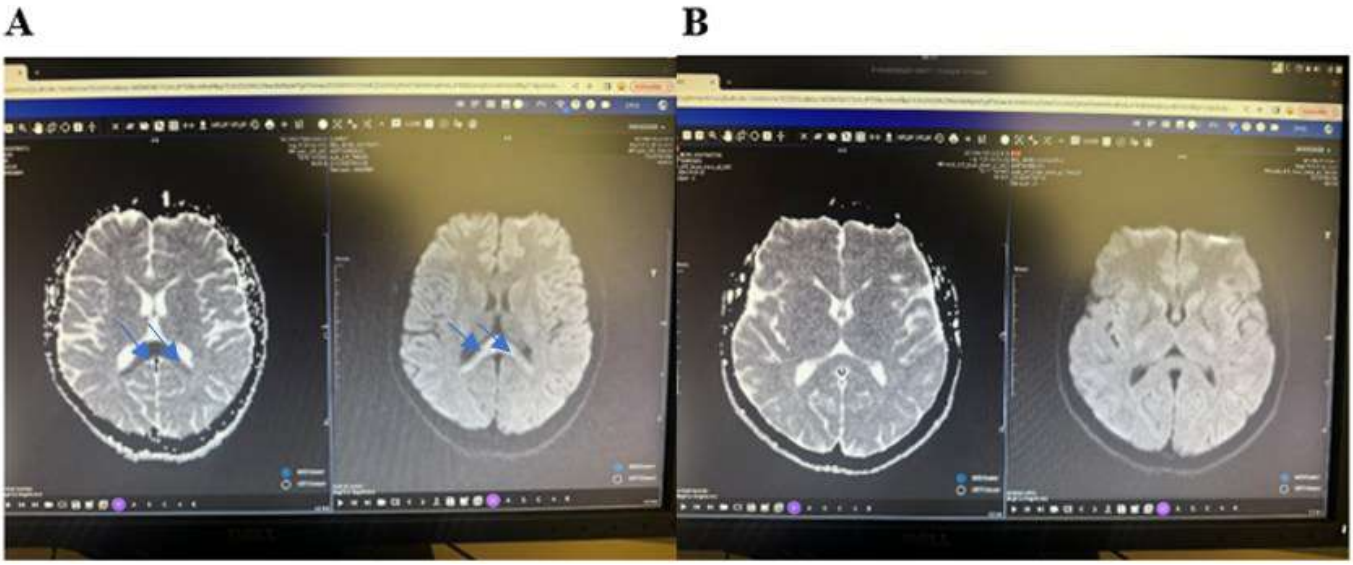

Figure 1. A) Brain diffusion MRI image acquired 8 hours after symptom onset. Acute diffusion restriction is observed in the splenium of the corpus callosum on the DWI sequence (arrow). The corresponding hypointense signal on the ADC map confirms the actual restriction. B) Brain diffusion MRI image taken 3 months later shows no abnormalities.

Results and Conclusion: Metoclopramide may lead not only to extrapyramidal adverse effects but also to rare central nervous system manifestations such as RESLES. Recognition of this entity is crucial, as it may mimic acute ischemic stroke and lead to unnecessary diagnostic or therapeutic interventions.

Keywords: Metoclopramide-induced reversible splenial lesion syndrome (RESLES), Corpus Callosum; Diffusion-Weighted MRI; Adverse Drug Reaction, Metoclopramide; Dystonia

Ref No: 1587

Massive pulmonary embolism mimicking supraventricular tachycardia: a case presenting with syncope

Fırat Okta[1], Alten Oskay[1], Mert Özen[1], Murat Seyit[1], Atakan Yılmaz[1]

[1]Pamukkale University, Faculty of Medicine, Department of Emergency Medicine

Alten Oskay / Pamukkale University, Faculty of Medicine, Department of Emergency Medicine

Introduction and Purpose: Syncope is defined as a transient loss of consciousness characterized by loss of postural tone, short duration, and spontaneous complete recovery, and it is among the clinical conditions frequently encountered in emergency department practice. Cardiac causes constitute an important part of the etiology of syncope, including both rhythm disorders and pathologies such as myocardial infarction or pulmonary embolism, as well as structural heart diseases or conditions that impair circulatory outflow and lead to hemodynamic instability. In addition to causing syncope, pulmonary embolism may also present on electrocardiography (ECG) with various tachyarrhythmias and atrial rhythm disorders, most notably sinus tachycardia. This case report aims to draw attention to the possibility that the underlying etiology in a patient with syncope presenting with a rhythm disorder may, in fact, be pulmonary embolism.

Materials and Methods: A 26-year-old man referred from an outside center with presumed supraventricular tachycardia refractory to rate control was evaluated in the emergency department. He had experienced syncope at home and presented to a district hospital. Detailed history revealed one week of progressively worsening dyspnea, reduced exercise capacity, shorter walking distance, and easy fatigability. Vital signs are shown in Table 1, and the initial electrocardiography (ECG) is presented in Figure 1. After sinus tachycardia was identified, bedside echocardiography demonstrated a D-sign suggesting right ventricular strain and raising suspicion for pulmonary embolism. Emergent pulmonary computed tomography angiography (CT angiography) showed extensive filling defects in both main pulmonary arteries extending into lobar and segmental branches, consistent with massive pulmonary embolism. The patient received thrombolytic therapy and was admitted to the pulmonary intensive care unit.

Figure 1. Electrocardiogram (ECG) on presentation

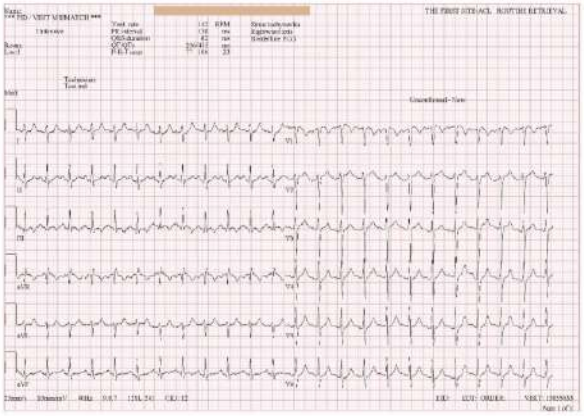

Figure 2. Computed tomography pulmonary angiography (CTPA)



Table 1. The patient's documented vital signs on arrival

Blood Pressure	Heart Rate	Body Temperature	Fingertip Oxygen Saturation	Respiratory Rate
168/83 mmHg	135 beats/min	36.1 °C	99 %	24 breaths/min

Results and Conclusion: This case demonstrates that different and life-threatening etiologies may be present in patients presenting to the emergency department with similar symptoms and findings. In the evaluation of nonspecific clinical presentations such as syncope, tachycardia, and dyspnea in particular, the differential diagnosis should be kept broad, and the focus should not be limited solely to the initially suspected diagnosis. In conclusion, a systematic approach supported by detailed history taking, careful physical examination, and appropriate imaging modalities is of critical importance for reaching the correct diagnosis in a timely manner.

Keywords: Syncope, Pulmonary embolism, Sinus tachycardia

Ref No: 1670

Rectus Sheath Hematoma Mimicking Acute Abdomen in an Elderly Anticoagulated Patient: A Case Report

AHMET DURSUN DEMİR[1], YAVUZ ALPEREN SAYAR[1], HIZIR UFUK AKDEMİR[1]

[1]Department of Emergency Medicine, Ondokuz Mayıs University Faculty of Medicine, Samsun, Türkiye

YAVUZ ALPEREN SAYAR / Department of Emergency Medicine, Ondokuz Mayıs University Faculty of Medicine, Samsun, Türkiye

Introduction and Purpose: Rectus sheath hematoma (RSH) is a rare but clinically significant condition caused by bleeding into the rectus abdominis muscle or its sheath. Although uncommon, it is an important differential diagnosis in patients presenting with acute abdominal pain, as misdiagnosis may lead to unnecessary surgical interventions. It predominantly occurs in elderly patients on anticoagulant therapy and may closely mimic surgical emergencies such as acute appendicitis, diverticulitis, or ruptured abdominal aortic aneurysm.

Materials and Methods: An 80-year-old woman presented to the emergency department with progressive right-sided abdominal pain of one-week duration. Her medical history included hypertension, atrial fibrillation, vertigo, and prior cerebrovascular accident. She was on regular rivaroxaban therapy for atrial fibrillation. Vital signs were stable. Physical examination revealed localized tenderness in the right upper and middle quadrants with a positive Carnett sign; no peritoneal irritation signs were detected. Laboratory findings showed a hemoglobin level of 10.9 g/dL without significant decline on serial measurements. Contrast-enhanced abdominal computed tomography (CT) demonstrated a large heterogeneous hematoma measuring 74×110×166 mm within the right rectus abdominis muscle, extending from the hepatic vein level to the pelvis, with an additional hematoma of 74×38×95 mm in the right internal oblique muscle. Active contrast extravasation was noted. Findings were consistent with Berna Type II rectus sheath hematoma. The patient was managed conservatively following multidisciplinary consultation with general surgery, cardiology, and neurology.

CT 1



CT 2



CT 3



CT 4



Results and Conclusion: RSH remains underdiagnosed in emergency settings due to its ability to mimic intraabdominal pathology. Approximately 60–70% of RSH cases occur in patients receiving anticoagulant therapy. A positive Carnett sign is a valuable clinical clue suggesting an abdominal wall origin. Contrast-enhanced CT is the gold standard for diagnosis, enabling precise assessment of hematoma extent and active bleeding. Conservative management is appropriate in hemodynamically stable patients, while interventional radiology or surgery may be required in unstable cases. Early recognition of RSH in elderly anticoagulated patients presenting with abdominal pain is essential to avoid unnecessary surgical procedures.

Keywords: Rectus sheath hematoma, Acute abdomen, Anticoagulant therapy

Ref No: 1687

Palatal Necrosis as an Early Clinical Clue of Rhino-Orbito-Palatal Mucormycosis in Uncontrolled Diabetes: A Case Report

AHMET DURSUN DEMİR[1], LATİF DURAN[1]

[1]Department of Emergency Medicine, Ondokuz Mayıs University Faculty of Medicine, Samsun, Türkiye

AHMET DURSUN DEMİR / Department of Emergency Medicine, Ondokuz Mayıs University Faculty of Medicine, Samsun, Türkiye

Introduction and Purpose: Mucormycosis is a rapidly progressive and potentially fatal angioinvasive fungal infection that predominantly affects immunocompromised individuals, particularly those with poorly controlled diabetes mellitus. Delayed diagnosis is common due to nonspecific early symptoms; however, certain clinical findings such as palatal necrosis, cranial neuropathy, and orbital involvement may serve as critical early warning signs of invasive disease.

Materials and Methods: A 51-year-old female with a 10-year history of poorly controlled type 2 diabetes mellitus (HbA1c 15.7%) presented to the emergency department with a two-week history of progressive right-sided facial pain and swelling, accompanied by a painful ulcerative lesion on the hard palate. In the days preceding admission, she developed ptosis, visual impairment, and worsening facial numbness. She had previously received irregular antibiotic therapy for a presumed dental abscess without clinical improvement.On physical examination, the patient was hemodynamically stable but had a necrotic ulcerative lesion involving the hard palate, extending toward the soft palate junction, along with right hemifacial hypoesthesia. Ophthalmologic evaluation revealed ptosis, proptosis, a fixed and dilated pupil, and severe ophthalmoplegia, consistent with orbital apex involvement. Laboratory findings showed significant hyperglycemia (387 mg/dL), ketonuria (> 160), leukocytosis (16.2 $\times 10^3/mm^3$), and thrombocytosis (451 $\times 10^3/mm^3$).Contrast-enhanced maxillofacial and orbital computed tomography demonstrated invasive soft tissue involvement extending from the nasal cavity and maxillary sinus into the medial extraconal orbital fat, consistent with invasive fungal rhinosinusitis. Histopathological examination of palatal and nasal biopsy specimens revealed broad, non-septate fungal hyphae on PAS and GMS staining, confirming mucormycosis.Prompt initiation of liposomal amphotericin B and metabolic stabilization with insulin therapy were achieved, and the patient was referred to a tertiary care center for further surgical management.

PICTURE 1



PICTURE 2



CT 1

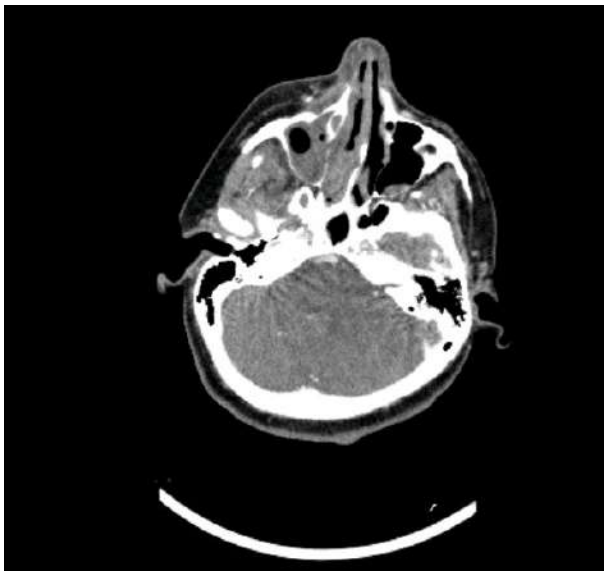

CT 2



Results and Conclusion: Palatal necrosis in conjunction with cranial neuropathy and ophthalmoplegia should strongly raise suspicion for invasive mucormycosis in patients with uncontrolled diabetes. Early clinical recognition, rapid imaging, histopathological confirmation, and immediate antifungal therapy are critical to improving outcomes in this life-threatening condition.

Keywords: Mucormycosis, Palatal necrosis, Rhino-orbital infection

Ref No: 1770

A Rare Cause of Chest Pain-Case Report

Emre BÜLBÜL[1], Mehmet Doğan[2]

[1]Department of Emergency Medicine, Faculty of Medicine, Erciyes University, Kayseri, Türkiye
[2]Public Health, Health Services Vocational School, Erciyes University, Kayseri, Türkiye

Emre BÜLBÜL / Department of Emergency Medicine, Faculty of Medicine, Erciyes University, Kayseri, Türkiye

Introduction and Purpose: Chest pain is an important reason for admission to the emergency room. The cause of chest pain may be due to coronary ischemia, or it may be due to diseases of other interthoracic organs such as lungs and esophagus.

Materials and Methods: In this case report, a 79-year-old male patient was admitted to the emergency room with chest pain. The patient's vital signs and physical examination were unremarkable. The patient's blood tests, including troponin and D-Dimer, were normal. Since free air was observed under the diaphragm in the chest X-ray, a computed tomography was performed and he was admitted to the general surgery service.

Picture-2:



Picture-2: Abdominal Tomography Image (red arrow: free air in the abdomen)

Picture-1:

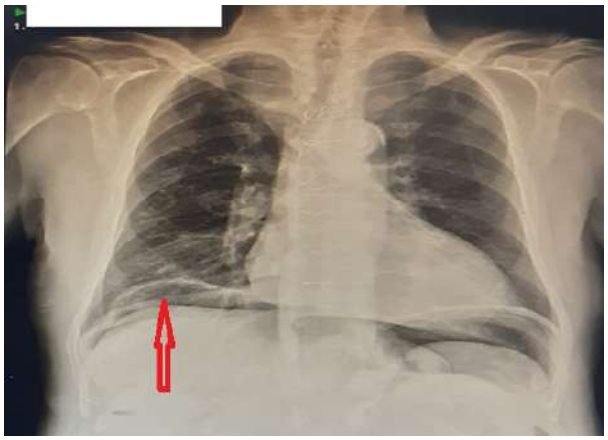

Picture-1: Free air under the diaphragm in the chest x-ray (red arrow)

Results and Conclusion: Other important diseases such as pulmonary embolism, aortic dissection, pneumothorax, esophageal rupture, cardiac tamponade and pericarditis should be kept in mind in patients presenting to the emergency department with chest pain. One of these diseases is colon perforation, as in this case report. Every physician working in the emergency department must have a good approach to chest pain and differential diagnosis.

Keywords: Chest pain, differential diagnosis, perforation

Ref No: 1813

Diagnostic pitfalls in the emergency department: recognizing severe pyelonephritis in the absence of flank pain

Hilal Türk[1], Vahdet Işıkoğlu[1], Mehmet Okay[1], Burak Polat[1], Mehmet Gül[1]
[1]Emergency Medicine Department, Konya City Hospital, Türkiye

Mehmet Okay / Emergency Medicine Department, Konya City Hospital, Türkiye

Introduction and Purpose: Acute pyelonephritis is a bacterial infection of the renal parenchyma and pelvis, typically presenting with fever, flank pain, dysuria, and systemic signs of infection. However, in some patients, symptoms may be subtle, presenting only with non-specific complaints. This case report aims to present a patient who presented solely with malaise and was diagnosed with calculous pyelonephritis upon further investigation.

Materials and Methods: A 63-year-old female patient with no known chronic medical history presented to the emergency department with a several-day history of generalized malaise. Initial clinical assessment revealed a body temperature of 37.5 °C, a heart rate of 99 beats per minute, blood pressure of 120/80 mmHg, and oxygen saturation of 99% on room air. The systemic physical examination was unremarkable. Laboratory investigations were significant for marked leukocytosis (WBC: 46,000/mm³) and a severely elevated C-reactive protein (CRP) level of 245 mg/L. The procalcitonin level was measured at 100 ng/mL. Microscopic urinalysis demonstrated 3+ bacteriuria and pyuria. Diagnostic imaging, including chest and abdominal radiography followed by contrast-enhanced computed tomography (CT) of the thorax, abdomen, and pelvis, was performed. The abdominal CT revealed a hyperdense calculus, approximately 16 mm in diameter, in the lower pole of the left kidney, accompanied by left-sided renal enlargement, contour irregularity, and heterogeneity of the perirenal fat. These findings were interpreted as consistent with acute pyelonephritis. Following consultations with the Urology and Infectious Diseases departments, the patient was admitted to the tertiary intensive care unit under the urology service, and intravenous antibiotic therapy was promptly initiated.

Results and Conclusion: While acute pyelonephritis typically presents with classic urinary symptoms, it may manifest with only non-specific complaints in certain patients. Particularly in elderly patients, symptoms such as malaise may be the sole presenting feature, which can lead to a delay in diagnosis. This case demonstrates that even in patients presenting with non-specific symptoms like fatigue, severe foci of infection may be present. Therefore, a broad diagnostic approach in the emergency department is of vital importance.

Keywords: Pyelonephritis, emergency department, renal stone

Ref No: 1837

Evaluation Of Chatgpt-Generated Forensic Reports İn Pediatric İnjury Scenarios: A Dual-Expert Pilot Study

Emine Ozdemir Kacer[1], Pelin Erol[2]

[1]Aksaray University, Faculty of Medicine, Department of Pediatrics, Division of Child Health and Diseases, Aksaray, Türkiye
[2]Aksaray University, Faculty of Medicine, Department of Forensic Medicine, Aksaray, Türkiye

Emine Ozdemir Kacer / Aksaray University, Faculty of Medicine, Department of Pediatrics, Division of Child Health and Diseases, Aksaray, Türkiye

Introduction and Purpose: Accurate forensic reporting in pediatric injury cases is essential for both clinical decision-making and legal processes. Large language models (LLMs), such as ChatGPT, are increasingly being integrated into medical documentation; however, their reliability in forensic applications remains uncertain. In addition, the use of artificial intelligence in high-stakes clinical domains raises important concerns regarding accuracy, completeness, and the potential for misinformation. Pediatric forensic reports require a high level of clinical precision due to their direct legal consequences. Therefore, evaluating the quality, consistency, and safety of LLM-generated forensic outputs is crucial before any potential clinical implementation. This pilot study aimed to evaluate the quality of ChatGPT-generated forensic reports in pediatric injury scenarios and to assess agreement between pediatric and forensic medicine experts.

Materials and Methods: This scenario-based descriptive pilot study included five pediatric injury cases: immersion burns, facial laceration, medical neglect, multiple ecchymoses, and suspected drug ingestion. Forensic reports were generated using ChatGPT (version 5.2) based on Turkish Penal Code forensic evaluation guidelines. A pediatrician and a forensic medicine specialist independently evaluated the reports using a 5-point Likert scale assessing medical accuracy, case completeness, and clarity/organization. Global Quality Score (GQS), presence of critical information deficiencies, and hallucinated content were recorded. Statistical analysis was performed using the Wilcoxon Signed-Rank test and Spearman correlation analysis. A p value < 0.05 was considered statistically significant.

Results and Conclusion: No statistically significant differences were found between expert evaluations across all domains ($p > 0.05$). Mean GQS values were 4.1±0.6 for the pediatrician and 4.0±0.7 for the forensic medicine specialist. A strong positive correlation was observed between experts (Spearman $r=0.82$, $p < 0.01$). Critical information deficiencies were detected in 40% (2/5) of cases, while hallucinated content was identified in 20% (1/5). Overall, ChatGPT-generated forensic reports demonstrated high-quality performance; however, clinically important deficiencies were observed, particularly in abuse and neglect scenarios. These findings suggest that LLMs may serve as supportive tools in forensic pediatrics but require expert validation before clinical use.

Table 1. Evaluation of ChatGPT-generated forensic reports by two experts

Parameter	Pediatrics (Mean ± SD)	Forensic Medicine (Mean ± SD)	p value
Medical accuracy	4.2 ± 0.6	4.1 ± 0.7	0.68
Case completeness	3.9 ± 0.7	3.8 ± 0.8	0.72
Clarity / organization	4.0 ± 0.5	3.9 ± 0.6	0.64
Global Quality Score	4.1 ± 0.6	4.0 ± 0.7	0.70

(GQS)

Table 1 shows that there were no statistically significant differences between pediatric and forensic medicine expert evaluations across all assessed domains (p>0.05).

Table 2. Critical findings in AI-generated reports

Variable	**n / N**	Percentage
Critical information deficiency	2 / 5	40%
Hallucinated content	1 / 5	20%

Table 2 shows critical deficiencies in 40% and hallucinations in 20% of cases.

Keywords: Pediatric injury; forensic report; large language models

---

Ref No: 1840

Vasospastic angina: STEMI or false alarm?

Şamil Altay Besler[1]

[1]SBÜ Şanlıurfa Mehmet Akif İnan Eğitim ve Araştırma Hastanesi, Acil Tıp Kliniği

Şamil Altay Besler / SBÜ Şanlıurfa Mehmet Akif İnan Eğitim ve Araştırma Hastanesi, Acil Tıp Kliniği

Introduction and Purpose: Vasospastic angina (VSA) (variant or Prinzmetal angina) is defined as chest pain resulting from transient myocardial ischemia following insufficient oxygenation caused by epicardial coronary spasm. It usually occurs at rest but is accompanied by transient electrocardiogram (ECG) findings (ST segment elevation or depression, T-wave pathologies). VSA, a subtype of non-occlusive ischemia (INOCA) pathologies in the coronary arteries, is associated with fatal clinical outcomes such as sudden cardiac arrest, acute myocardial

infarction, and syncope. In this case report, we wanted to emphasize that pseudoephedrine-containing medications, frequently prescribed in the emergency department, can provoke VSA.

Materials and Methods: A 44-year-old male patient presented to the emergency department with complaints of left-sided chest pain that had been ongoing for approximately 2 hours. The patient, who had no history of cardiovascular disease, had previously presented to the emergency department earlier that morning with complaints of myalgia, cough, and nasal congestion; he was subsequently prescribed medication containing 60 mg of pseudoephedrine, of which he received two doses. The patient's GCS was 15 and vital signs were normal. A three-lead ECG taken during patient transfer by the 112 emergency medical team showed ST segment elevation in inferior derivations and ST segment depression in derivations D1, AVL, and AVR (Figure 1). A repeat ECG in the emergency department showed that the same findings persisted in the same derivations (Figure 2). A second ECG taken approximately 12 minutes later showed a regression of the pathological findings (Figure 3). Blood tests revealed troponin T values of 7.3, 64.8, 105, and 129 µg/L (upper limit 100) at 2-hour intervals from admission; CRP of 6.95 mg/L (upper limit 5). Patient was admitted to the coronary intensive care unit and underwent angiography. Angiography revealed no major stenosis in any of the coronary arteries; the procedure was completed without complications, and medical follow-up was recommended.

Figure 1

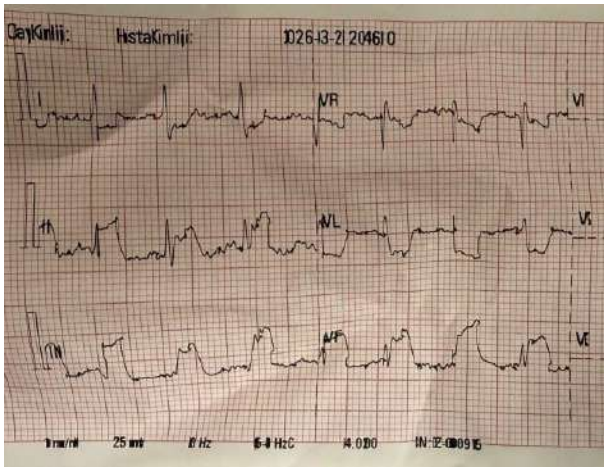

Figure 2

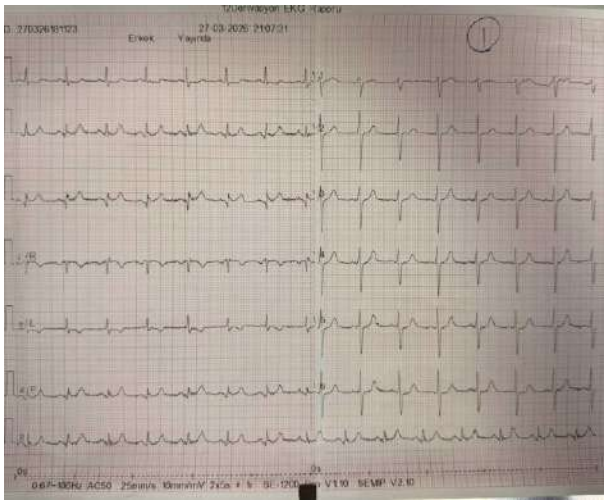

Figure 3

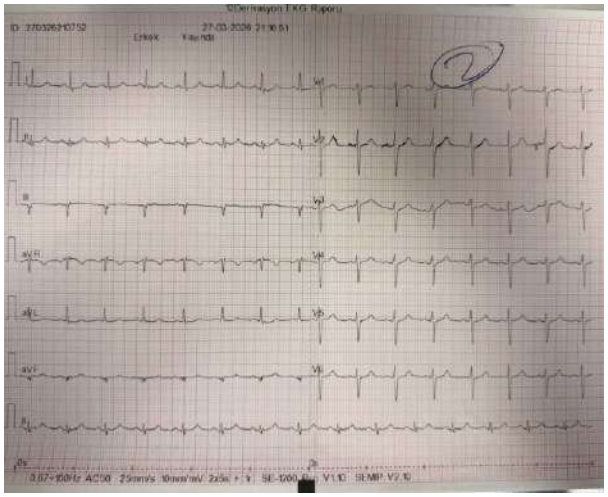

Results and Conclusion: VSA, the most common mimic of acute coronary syndrome in terms of clinical presentation, requires careful monitoring with ECG and laboratory findings to prevent potentially poor clinical outcomes. Patients presenting to the emergency department with chest pain should have their medication use investigated, and VSA should be considered as a possibility.

Keywords: vasospastic angina, STEMI, pseudoephedrine

Ref No: 1893

Determinants of mortality in methanol intoxication cases and evaluation of a novel prognostic score

Hatice Yollar[1], Muhammet Gökhan Turtay[2], Esra Pamukçu[3]

[1]Clinic of Emergency Medicine, University of Health Sciences Konya City Hospital, Konya, Türkiye.
[2]Clinic of Emergency Medicine, University of Health Sciences Beyhekim Training and Research Hospital, Konya, Türkiye.
[3]Department of Statistics, Faculty of Science, Firat University, Elazığ, Turkey.

Hatice Yollar / Clinic of Emergency Medicine, University of Health Sciences Konya City Hospital, Konya, Türkiye.

Introduction and Purpose: Objective: Methanol intoxication is a toxicological emergency characterized by multisystem involvement, where delays in diagnosis and treatment may lead to fatal outcomes. In this study, clinical, biochemical, and radiological parameters predicting mortality in patients admitted to the emergency department due to methanol poisoning were comprehensively evaluated. Additionally, the predictive performance and clinical applicability of the newly developed Methanol Prognostic Mortality Score (MPMS) were investigated.

Materials and Methods: Materials and Methods: This retrospective, single-centre cohort study included 92 patients evaluated in the emergency department between 2020 and 2024 following methanol ingestion. Demographic characteristics (age, sex), clinical findings at admission (consciousness status, visual symptoms), laboratory parameters, inflammatory indices, coagulation profile, and neuroimaging findings were systematically recorded. ICU triage scores were reviewed, and MPMS was developed. Cut-off values were determined using ROC curve analysis.

Results and Conclusion: Results: Male predominance (94.6%) and advanced age were significantly associated with mortality. Altered consciousness and visual disturbances emerged as primary prognostic determinants. A low Glasgow Coma Scale (GCS) was identified as the most reliable clinical indicator of central nervous system involvement. In the mortality group, Acute Physiology and Chronic Health Evaluation (APACHE II) and Sequential Organ Failure Assessment (SOFA) scores were significantly higher. Severe academia (pH < 7.0), decreased bicarbonate, and elevated lactate levels showed strong correlations with survival. Elevations in creatinine, troponin, amylase, and liver function tests were observed. Among inflammatory indices, high neutrophil-to-lymphocyte ratio (NLR) and low platelet-to-lymphocyte ratio (PLR) were strongly associated with mortality. Coagulation abnormalities in severe cases were linked

to poor prognosis. Radiologically, putaminal involvement was identified as the most characteristic finding of methanol intoxication and a guiding marker for mortality risk. MPMS, integrating clinical, biochemical, and radiological parameters, demonstrated high sensitivity and specificity. Conclusion: Advanced age, male sex, altered consciousness, visual disturbances, low GCS, severe academia, elevated lactate, putaminal involvement, and inflammatory indices are critical prognostic determinants in methanol intoxication. The newly developed MPMS, with its ease of clinical applicability, high predictive power, and integration into multidisciplinary decision-making, can serve as a valuable decision-support tool in patient management.

Keywords: Methanol intoxication, Mortality, Score

Ref No: 1919

Dashboard Injury Resulting in Traumatic Asymmetric Bilateral Hip Dislocation: A Case Report

EMRAH AVCUOĞLU[1]
[1]NİĞDE ÖMER HALİSDEMİR EĞİTİM VE ARAŞTIRMA HASTANESİ
EMRAH AVCUOĞLU / NİĞDE ÖMER HALİSDEMİR EĞİTİM VE ARAŞTIRMA HASTANESİ

Introduction and Purpose: Asymmetric bilateral hip dislocation is a rare injury with a complex mechanism, and its management can be particularly challenging, especially in delayed cases. We report a 17-year-old male who sustained asymmetric hip dislocation (right inferior, left superior) following an in-vehicle traffic accident. Closed reduction under sedation was performed in the operating room 2 hours post-injury. Hip dislocations should ideally be reduced within 6 hours. In high-energy trauma, post-reduction imaging is crucial to confirm successful reduction and to identify any associated fractures.

Materials and Methods: A 17-year-old male was brought to the emergency department following a high-energy in-vehicle traffic accident. He had been seated in the front passenger seat without a seatbelt, with his knees braced against the dashboard.On admission, he was conscious, oriented, and cooperative (GCS: 14), with stable vital signs. Both lower extremities were flexed toward the abdomen. Physical examination revealed right basal rales, abdominal abrasions with tenderness in the right upper and lower quadrants, marked bilateral pelvic tenderness with limited range of motion, and lumbar tenderness.Imaging demonstrated bilateral pulmonary contusions, a grade 2 liver injury (segment 5), a 2 cm laceration of the right kidney, and fractures of the L1–L2 transverse processes. Additionally, right inferior and left superior hip dislocations were identified.Following initial management, the patient underwent closed

reduction under sedation. Post-reduction imaging confirmed successful reduction without additional pathology. He was discharged in good condition after 5 days of hospitalization.

Before reduction



Results and Conclusion: The hip joint is among the most stable joints in the human body due to its strong ligaments, thick capsule, and surrounding musculature. Consequently, dislocation in a healthy young individual typically requires high-energy trauma. In this case, bilateral hip dislocation resulted from a dashboard injury.Physical examination is the primary diagnostic tool for hip dislocation, and plain radiographs should be obtained both before and after reduction. Delayed reduction increases the risk of complications such as avascular necrosis, heterotopic ossification, and osteoarthritis. Surgical intervention may be necessary for major fractures or failed closed reduction. Prompt reduction, early detection of associated injuries, and close post-discharge follow-up are essential for optimal outcomes.

After reduction

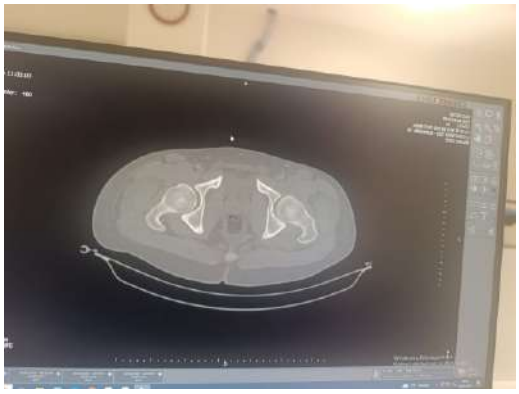

Keywords: Bilateral hip dislocation, dashboard injury, Trauma

Ref No: 1938

Specific Neuradiological Sign in a Trauma Patient: Mount Fuji.

Onur Bozdağ[1], Elif Yıldız[2], Asel Hale Pilgeci[2], Bahadır Taşlıdere[1], Başar Cander[1]

[1]Bezmialem Vakıf University, Emergency Department.
[2]Bezmialem Vakıf University, Medical Faculty.

Onur Bozdağ / Bezmialem Vakıf University, Emergency Department.

Introduction and Purpose: Pneumocephalus refers to the presence of air within the cranial cavity and most commonly occurs following craniofacial trauma, neurosurgical procedures, or skull base defects . Although typically benign and self-limiting, tension pneumocephalus is a rare but life-threatening condition characterized by progressive intracranial air accumulation causing mass effect and neurological deterioration.

Materials and Methods: A 92-year-old male presented to the emergency department after a ground-level fall at home while walking to the bathroom. According to history, he had experienced a similar fall four days prior but did not seek medical attention at that time.Non-contrast cranial computed tomography demonstrated extensive bilateral extra-axial air collections in the frontal regions, consistent with pneumocephalus. The frontal lobes were displaced posteriorly, findings suggestive of tension pneumocephalus (Mount Fuji sign). Additional extra-axial pneumocephalus was also observed in the anterior and temporal regions. Further evaluation with thin-slice CT was recommended to assess for a possible skull fracture. Neurosurgery was consulted due to pneumocephalus and subdural effusion, and no urgent surgical intervention was recommended; close follow-up with levetiracetam 500 mg twice daily and further evaluation with contrast-enhanced brain MRI and heavily T2-weighted sequences were advised.During intensive care unit follow-up, contrast-enhanced cranial MRI was performed. Imaging demonstrated persistent bilateral frontal extra-axial air collections consistent with pneumocephalus, more prominent on the right side, along with a bilateral frontal subdural effusion, also more pronounced on the right.After three days in the intensive care unit, the patient was transferred to the neurosurgery ward for further management.

Results and Conclusion: This case illustrates a rare but clinically significant presentation of tension pneumocephalus in an elderly patient following minor head trauma. Advanced ageand the presence of head trauma likely contributed to the development of intracranial air accumulation in this patient.Radiologically, the presence of the Mount Fuji sign on CT is highly suggestive of tension pneumocephalus and indicates significant mass effect requiring close monitoring or intervention. In this case, despite imaging findings consistent with tension pneumocephalus, the patient was managed conservatively due to stable clinical status,

emphasizing that management should be individualized based on both radiological and clinical findings.

Keywords: Neuroimagining, Mount Fuji sign, Tension Pneumocephalus

---

Ref No: 2010

The Double-Edged Sword: Intracerebral Hemorrhage and Aneurysm Risk in a Patient with Cardiac Valve Replacement

Resul Yollar[1], Ceren Şen Tanrıkulu[1], Yakup Sağlam[1], Ayla Mollaoğlu[1], Mehmet Gül[1];
[1]Emergency Medicine Department, Konya City Hospital, Türkiye

Resul Yollar / Emergency Medicine Department, Konya City Hospital, Türkiye

Introduction and Purpose: Intracerebral hematoma is a life-threatening emergency with high mortality and morbidity, particularly in patients with a history of cardiac surgery and cerebrovascular events (CVE). Anticoagulant therapy significantly increases the risk of bleeding in this patient group. In this report, we present a case of intracranial hematoma and a possible aneurysm in a patient with a history of valve replacement and CVE.

Materials and Methods: Case: A 70-year-old male patient presented to the emergency department with complaints of nausea, vomiting, and syncope. His Glasgow Coma Scale (GCS) score was 15, blood pressure was 90/60 mmHg, heart rate was 39 beats per minute, oxygen saturation was 94%, and body temperature was 36.4°C. Electrocardiography revealed sinus rhythm. The patient had a history of Coumadin use. On admission, hypotension and bradycardia were noted. Cranial imaging revealed an approximately 5 cm hematoma in the right occipital region, accompanied by perifocal edema and intraventricular hemorrhagic extension. CT angiography demonstrated a 4 mm hyperdense lesion within the center of the hematoma (suggestive of aneurysm?). Interventional radiology was not considered. The patient was admitted to the intensive care unit and followed by neurology.

Results and Conclusion: In our case, anticoagulant use following valve replacement and a history of CVE increased the risk of bleeding. CT angiography plays a critical role in the differential diagnosis of vascular pathologies (e.g., aneurysm) in intracranial hematomas (6). The presence of a hyperdense lesion within the hematoma has been reported in the literature to be associated with aneurysms. A similar finding was observed in our case; however, no interventional procedure was planned. Intracranial hemorrhages in patients with a history of cardiac surgery and CVE may follow a complicated course. CT angiography is crucial for early diagnosis and interventional planning.

Keywords: intracerebral hematoma, Aneurysm, emergency department

Ref No: 2104

Treatment management of high-grade renal laceration

Müslime Kasa[1], Muhammet Gökhan Turtay[1], İlknur şahin[1], Onur Metin[1]

[1]Türkiye Sağlık Bilimleri Üniversitesi, Beyhekim Eğitim ve Araştırma Hastanesi, Acil Tıp Kliniği, Konya/Türkiye

Muhammet Gökhan Turtay / Türkiye Sağlık Bilimleri Üniversitesi, Beyhekim Eğitim ve Araştırma Hastanesi, Acil Tıp Kliniği, Konya/Türkiye

Introduction and Purpose: The kidneys are the organ most frequently injured due to blunt trauma. Renal injuries account for between 1% and 5% of all trauma cases. Young men are affected more frequently. One quarter of all solid organ injuries are due to kidney trauma. Renal trauma can result in damage to the parenchyma and vascular structures, as well as the urinary collecting system and renal pelvis. Causes include direct blows, motor vehicle accidents and falls, inferior rib fractures, sports injuries and pedestrian injuries. The most common injury mechanism is sudden deceleration injury or a direct blow to the back or side. Penetrating trauma near the kidney can cause renal pedicle rupture and renal artery dissection. Renal injury should be suspected in patients presenting with costovertebral pain, abdominal or back pain, a palpable mass, ecchymosis, hypotension and shock. Bicycle accidents, especially in children, are a significant cause of renal trauma. Haemodynamic instability and haematuria increase suspicion of renal injury. However, the degree of haematuria does not predict the severity of renal injury and it may not be present at all. We present the case of a 16-year-old male patient with a grade 4–5 renal laceration caused by impact with a bicycle handlebar during a fall. Serious consequences can arise from seemingly minor injuries. Here, we present the emergency department management and non-operative treatment of a patient who developed a high-grade renal laceration due to blunt trauma.

Materials and Methods: Renal Laceration



Figure 1: A large hematoma is observed around the left kidney (red arrow).

Results and Conclusion: In conclusion, rapid diagnosis in the emergency department setting prevents unwanted complications. Based on the patient's vital signs and laboratory findings, a conservative approach can be safely applied even in cases of high-risk kidney injuries in patients with stable hemodynamics. This treatment will reduce the need for unnecessary surgery.

Keywords: Blunt trauma, renal laceration, hematuria

Ref No: 2108

Acute Lymphoblastic Leukemia Presenting with Pulmonary Thromboembolism in the Postoperative Period: Case Report

Muhammet Emin Uzun1, İsmail Ataş1, Özlem Bilir1

1Recep Tayyip Erdoğan University Training and Research Hospital, Department of Emergency Medicine, Rize, Türkiye

Muhammet Emin Uzun / Recep Tayyip Erdoğan University Training and Research Hospital, Department of Emergency Medicine, Rize, Türkiye

Introduction and Purpose: Pulmonary thromboembolism (PTE) is a common clinical entity, especially in the postoperative period, and carries a high mortality risk. However, in some cases, PTE may be the first clinical manifestation of underlying malignancies. Acute lymphoblastic leukemia (ALL) is a rare but aggressive hematologic malignancy in adults and usually presents with cytopenia or signs of infection. The aim of this case report is to emphasize the importance of establishing the underlying diagnosis of ALL in a patient presenting with PTE.

Materials and Methods: A 58-year-old male patient was admitted to the emergency department with dyspnea and lower extremity complaints after varicose vein surgery. Thoracic computed tomography angiography revealed thromboembolism at the level of the subsegmentary branch of the right pulmonary artery. Laboratory tests revealed marked leukocytosis and thrombocytopenia. Upon observation of blastic cell infiltration in the peripheral smear, further hematologic evaluation was performed and the patient was diagnosed as acute lymphoblastic leukemia.

Figure 1



Contrast-enhanced thorax CT angiography sections show filling defects in the right lung lower lobe segmentary pulmonary artery branches consistent with thromboembolism

Results and Conclusion: In some cases, pulmonary thromboembolism may be the first sign of underlying malignancies. Especially in the presence of concomitant significant hematologic abnormalities, these findings should not be considered as merely reactive changes and further evaluation for hematologic malignancies should be performed. This case demonstrates the importance of comprehensive evaluation and investigation of underlying causes in patients diagnosed with PTE in the emergency department.

Keywords: pulmonary thromboembolism, acute lymphoblastic leukemia, emergency department

---

Ref No: 2111

A hidden airway threat: Isolated thyroid laceration without goiter after blunt neck trauma

MAHMUT MURAT1, MELİSA TAŞTAN1, MUSTAFA SAFA PEPELE1, SERDAR DERYA1, RIDVAN SÖNMEZ1, MELİKE KARATAŞ AYHAN1, ŞÜKRÜ GÜRBÜZ1, NESLİHAN YÜCEL1, MEHMET EDİZ SARIHAN1

1INONU UNIVERSTY

SERDAR DERYA / INONU UNIVERSTY

Introduction and Purpose: A stable trauma patient with a clear airway can still deteriorate hours later, which is the defining danger of blunt thyroid injury. Thyroid gland injuries occur in approximately 1–2% of blunt neck trauma cases and are most commonly associated with pre-existing goiters. Isolated lacerations in structurally normal glands are exceedingly rare. The critical and underappreciated risk is delayed airway obstruction; patients may present as hemodynamically stable without stridor, yet develop life-threatening hematoma or soft tissue edema within 24 hours. This case highlights that stability at presentation does not exclude impending airway compromise and that active observation is a therapeutic decision.

Materials and Methods: A 27-year-old woman without known thyroid disease presented to the emergency department after a motor vehicle accident without a seatbelt; airbags were deployed. The patient presented with right-sided neck pain and swelling. Vital signs were stable (blood pressure, 120/80 mmHg; heart rate 84/min, SpO_2, 96%). Examination revealed ecchymosis, right lower neck tenderness, and swelling without pulsation; carotid pulses were bilaterally intact. No stridor or respiratory distress was observed. Bedside ultrasonography revealed a hypoechoic, avascular area in the right thyroid lobe consistent with laceration and sternocleidomastoid hemorrhage. Contrast-enhanced neck computed tomography confirmed a right lobe laceration without tracheal deviation or vascular injury. Thyroid-stimulating hormone (TSH) levels were mildly suppressed (0.278 mIU/L), and free T3 and T4 levels were mildly elevated without clinical signs of thyroid storm. Conservative management was chosen based on four criteria: hemodynamic stability, absence of stridor, no active hemorrhage on imaging, and stable hemoglobin levels. The patient was admitted for 24-hour close airway monitoring.

Image of the patient's neck.



Neck swelling and ecchymosis.

Doppler ultrasound image.



Doppler sonography demonstrates hypervascularity of the thyroid gland; however, no flow is detected within the lesion. The surrounding vascular structures are intact, and no evidence of active bleeding is observed.

Ultrasonographic image.



A hypoechoic appearance in the left thyroid gland on ultrasonography, suggestive of laceration.

Computed tomography image.



On contrast-enhanced neck CT, hypodense lesions suggestive of a hematoma are observed in the right thyroid gland, without evidence of airway or vascular injury.

Results and Conclusion: No airway compromise or deterioration was observed. The patient was discharged with precautions for neck swelling, stridor, or dyspnea. At follow-up, she was asymptomatic, and her thyroid function had normalized. Three actionable messages emerge: first, isolated thyroid laceration can occur without goiter and must be considered in the differential diagnosis of blunt neck trauma; second, initial stability does not exclude delayed obstruction — observation is not passive, but critical; third, conservative management is safe under strict criteria, but the 24-hour window demands active surveillance. Thyroid injury after blunt neck trauma should not be underestimated.

Keywords: Thyroid laceration, blunt neck trauma, conservative management

Ref No: 2115

Gallstone Ileus with Spontaneous Rectal Evacuation via Enema: A Rare Case of Cholecystoduodenal Fistula

Ekim Sağlam Gürmen[1], Muhammed Fatih Kaban[1], Mustafa Yorgancıoğlu[2]

[1]Manisa Celal Bayar University School of Medicine, Department of Emergency Medicine, Manisa, Turkey
[2]İzmir Torbalı State Hospıtal, Emergency Department, İzmir, Turkey

Muhammed Fatih Kaban / Manisa Celal Bayar University School of Medicine, Department of Emergency Medicine, Manisa, Turkey

Introduction and Purpose: Gallstone ileus is a rare but potentially life-threatening complication of cholelithiasis, accounting for 1–4% of all mechanical intestinal obstructions. It is typically caused by the passage of a large gallstone into the intestinal lumen through a bilioenteric fistula, most commonly resulting from chronic cholecystitis (1,2). Although the ileocecal valve is the most frequent site of obstruction, gastric outlet obstruction due to a gallstone is referred to as Bouveret Syndrome. Complete passage of a gallstone through the gastrointestinal tract followed by rectal evacuation is exceedingly rare (3).We present an unusual case in which a giant gallstone was evacuated rectally following an enema, resulting in resolution of the ileus, while an underlying 8 mm cholecystoduodenal fistula remained

Materials and Methods: A 72-year-old male presented with a three-day history of generalized abdominal pain, bloating, and dark-colored vomiting. Initial evaluation revealed widespread air-fluid levels and dilated colonic loops consistent with mechanical obstruction. Clinical relief was achieved following the administration of an enema.Upon admission to our center, the patient's vital signs were stable. Laboratory results indicated significant leukocytosis (WBC: 18.73x10³/µL), neutrophilia (81.1%), and elevated CRP (143 mg/L). Contrast-enhanced CT scans revealed: An 8 mm cholecystoduodenal fistula between the gallbladder fundus and the duodenum. Pneumobilia within the intrahepatic bile ducts. increased wall thickness at the rectosigmoid junction and stranding in the mesorectal fatty planes, likely occurring during the rectal evacuation of the stone.Although the obstruction was resolved via enema, intravenous broad-spectrum antibiotic therapy was initiated due to the risk of ascending cholangitis associated with the fistula and high inflammatory markers. An elective colonoscopy was subsequently planned.

Results and Conclusion: Gallstone ileus is typically managed through surgical enterolithotomy (4). This case represents a rare example of "spontaneous resolution" involving the rectal evacuation of a giant stone originating from a cholecystoduodenal fistula following an enema.

While enemas carry a risk of perforation in fragile bowel segments, in this instance, it successfully resolved the ileus (5).However, even if the passage of the stone resolves the mechanical obstruction, the fistula and the inflammatory response persist. Clinicians must thoroughly evaluate the biliary system after the obstruction is cleared and closely monitor systemic inflammatory parameters.

Keywords: Gallstone ileus; Cholecystoduodenal fistula; Pneumobilia

---

Ref No: 2165

Risk Stratification and Treatment Approaches in Acute Pulmonary Embolism: A Focus on Right Heart Dysfunction

BURCU YORMAZ[1]

[1]Selcuk University Medicine Faculty Department of Chest Disease,

BURCU YORMAZ / Selcuk University Medicine Faculty Department of Chest Disease,

Introduction and Purpose: Pulmonary embolism (PE) is a life-threatening condition with a wide spectrum of clinical presentations, making risk stratification and treatment decisions challenging. Despite advances in diagnostic and therapeutic options, a standardized approach remains limited due to heterogeneous patient profiles. Right ventricular (RV) dysfunction has emerged as a key determinant of prognosis. This study aims to evaluate the central role of right heart dysfunction in guiding risk stratification and treatment strategies in acute PE

Results and Conclusion: Right ventricular dysfunction was identified as the most critical factor influencing disease severity and clinical decision-making. Patients without evidence of RV dysfunction were categorized as low risk and managed with anticoagulation alone. Intermediate-risk patients required individualized assessment, particularly when imaging and biomarkers indicated RV strain. High-risk patients with hemodynamic instability benefited from aggressive reperfusion strategies, including thrombolysis and mechanical thrombectomy.In conclusion, PE management should primarily focus on right heart function rather than relying solely on traditional scoring systems. Individualized, resource-adapted approaches are essential for optimizing patient outcomes.

Keywords: Pulmonary Embolism; Right Ventricular Dysfunction; Risk Stratification;

Ref No: 2198

Inflammation-Based indices and functional outcomes after mechanical thrombectomy in acute ischemic stroke

Mustafa Uçar[1], Muhammed İkbal Şaşmaz[2]

[1]Manisa Celal Bayar University, Faculty of Medicine, Department of Cardiology
[2]Manisa Celal Bayar University, Faculty of Medicine, Department of Emergency Medicine

Muhammed İkbal Şaşmaz / Manisa Celal Bayar University, Faculty of Medicine, Department of Emergency Medicine

Introduction and Purpose: Mechanical thrombectomy is an established treatment for acute ischemic stroke caused by large vessel occlusion; however, functional outcomes remain heterogeneous despite successful recanalization (1). Inflammatory processes have been increasingly implicated in post-stroke prognosis (2,3). This study aimed to evaluate the association between inflammation-based indices and short-term functional outcomes in patients undergoing mechanical thrombectomy.

Materials and Methods: This retrospective observational study included patients who underwent mechanical thrombectomy for anterior circulation acute ischemic stroke. Functional outcome was assessed using the modified Rankin Scale (mRS) at discharge and dichotomized as favorable (mRS ≤3) and poor (mRS > 3). Demographic characteristics, comorbidities, electrocardiographic rhythm, and admission laboratory parameters were recorded. Systemic inflammatory response index (SIRI), systemic immune-inflammation index (SII), neutrophil-to-lymphocyte ratio (NLR), and platelet-to-lymphocyte ratio (PLR) were calculated. Comparisons were performed using Mann–Whitney U and Fisher's exact tests, as appropriate.

Results and Conclusion: A total of 18 patients with acute anterior circulation ischemic stroke who underwent mechanical thrombectomy were included. Favorable functional outcome (mRS ≤3) was observed in 8 patients (44.4%), while 10 patients (55.6%) had poor outcomes. Patients with poor outcomes were significantly older compared with those with favorable outcomes (median 68 vs. 47 years, p=0.026). Atrial fibrillation was exclusively observed in the poor outcome group ($p < 0.001$). Other comorbidities, including diabetes mellitus, hypertension, and coronary artery disease, were similar between groups.Inflammation-based indices were markedly higher in patients with poor functional outcomes. Median SIRI, SII, NLR, and PLR values were all significantly elevated in the poor outcome group compared with the favorable outcome group (all $p < 0.01$) (Table 1). A representative case demonstrating successful mechanical aspiration with complete reperfusion (TICI 3) is shown in Figure 1. In-hospital mortality occurred in four patients, all within the poor outcome group. Systemic inflammation has been increasingly

recognized as a key contributor to ischemic brain injury and secondary neuronal damage following large vessel occlusion (4). Inflammation-based indices measured at admission were strongly associated with poor short-term functional outcomes following mechanical thrombectomy. These readily available markers may help identify high-risk patients and assist early prognostic stratification in acute ischemic stroke.

Figure 1.



Representative digital subtraction angiography images of a patient with acute anterior circulation ischemic stroke. (A) Selective internal carotid artery angiography demonstrating total occlusion of the internal carotid artery (arrow). (B) Post-procedural angiography following mechanical aspiration showing successful reperfusion with TICI 3 flow in the distal internal carotid artery and its branches.

Table 1

Variable	Favorable outcome (mRS ≤3, n=8)	Poor outcome (mRS >3, n=10)	*p* value
Age, years	47	68	**0.026**
Male sex, n (%)	5 (62.5)	3 (30.0)	0.168
Atrial fibrillation, n (%)	0 (0)	10 (100)	**<0.001**
Diabetes mellitus, n (%)	3 (37.5)	6 (60.0)	0.343
Hypertension, n (%)	3 (37.5)	7 (70.0)	0.168
Coronary artery disease, n (%)	3 (37.5)	5 (50.0)	0.596
SIRI	1.78	5.98	**<0.001**
SII	1034.8	2400.0	**0.001**
NLR	4.17	11.37	**0.001**
PLR	122.7	221.9	**0.006**

Baseline characteristics and inflammatory indices according to functional outcome

Keywords: Acute ischemic stroke, mechanical thrombectomy, inflammation

Ref No: 2213

Wunderlich syndrome

Halim Taş[1], Ali GÜR[1]

[1]Ataturk University Research Hospital

Halim Taş / Ataturk University Research Hospital

Introduction and Purpose: Wunderlich syndrome is a sudden, severe renal hemorrhage occurring in the spaces beneath and around the renal capsule due to non-traumatic (spontaneous) causes. It is a rare, potentially life-threatening emergency that typically presents with severe flank pain, flank tenderness, and hematuria (blood in the urine). It is diagnosed via CT or ultrasound and often requires rapid intervention.

Materials and Methods: A 30-year-old female patient presented to the emergency department with pain radiating from the upper right quadrant to the back, which had been present for one day. The patient had no other medical conditions and her vital signs showed no abnormalities. On examination, she had a positive right coronary artery disease (CVA) and tenderness in the upper right quadrant. A complete blood count, comprehensive biochemistry, complete urinalysis, and abdominal biopsy were ordered. The abdominal biopsy showed no abnormalities; her WBC count was 15,000 with a leftward shift. External examinations revealed no abnormalities. After symptomatic treatment failed to alleviate the pain, an abdominal ultrasound was performed. The ultrasound report stated: "Multiple lesions of varying size in the left kidney, consistent with angiomyolipomas with no significant flow coding on RDG, and a nodular appearance of approximately 85x75 mm in size with heterogeneous internal nature and echogenicity, whose relationship to the kidney cannot be clearly assessed and which does not have significant flow coding on RDG, was observed posteromedially to the left kidney. Contrast-enhanced abdominal CT is recommended." A contrast-enhanced abdominal CT scan was performed. The CT scan showed: "In the right kidney, a lesion, the largest being 9 cm in diameter, surrounded by a hematoma area containing fat density and different grades of blood products, primarily suggestive of an angiomyolipoma (Wunderlich syndrome?)." Therefore, the patient was consulted and admitted to the Urology clinic. The following day, the patient underwent AML embolization under interventional radiology guidance.

CT



Results and Conclusion: For flank and upper quadrant pain, a complete blood count, biochemistry, and urinalysis are beneficial. While preliminary diagnoses may include nephrolithiasis, acute cholecystitis, and renal infarction, it's important to keep in mind that these rare syndromes may also occur in the patient; therefore, further imaging should be considered.

Keywords: Wunderlich syndrome, stomachache

Ref No: 2218

Wernicke Encephalopathy: A Case Report with Typical Clinical and Imaging Findings

Ozan Deniz Keleş[1], İsa Yıldırım[1], Ahmet Melih Savaş[1], Selçuk Eren Çanakçı[1], Fatih Türkmen[2]

[1]Department of Emergency Medicine, Faculty of Medicine, Aydın Adnan Menderes University, Aydın, Turkey
[2]Avcılar District Health Directorate, Istanbul, Türkiye

Ozan Deniz Keleş / Department of Emergency Medicine, Faculty of Medicine, Aydın Adnan Menderes University, Aydın, Turkey

Introduction and Purpose: Wernicke Encephalopathy (WE) is an acute neurological condition caused by thiamine deficiency. If not diagnosed early, it can lead to severe neurological sequelae or mortality. It most commonly occurs due to chronic alcoholism and malnutrition. The classic clinical triad consists of altered mental status, ataxia, and oculomotor abnormalities. This report presents a case of WE diagnosed through typical clinical features and Magnetic Resonance Imaging (MRI) findings.

Materials and Methods: A 61-year-old male presented to the emergency department with a two-day history of confusion and gait instability. His medical history included cured colon cancer and chronic alcoholism. Upon admission, vital signs were stable; the patient was conscious and cooperative.Neurological examination revealed:•Bilateral isocoric pupils with reactive light reflexes.•Limited rightward gaze and vertical nystagmus during leftward gaze.•A positive Romberg test.•Other systemic and neurological examinations were unremarkable.Laboratory tests were normal, and the initial brain Computed Tomography (CT) showed no pathology. However, Diffusion MRI (FLAIR sequence) revealed T2-FLAIR signal hyperintensities in the bilateral thalami and the white matter surrounding the third ventricle. Since the patient met 4/4 of the Caine criteria, a preliminary diagnosis of WE was made. Intravenous thiamine treatment was initiated, and a neurology consultation was requested. Following admission to the neurology ward and three days of thiamine therapy, the patient showed significant symptomatic improvement and was subsequently discharged.

Results and Conclusion: Evaluating the typical clinical triad alongside characteristic MRI findings ensures a rapid diagnosis of Wernicke Encephalopathy. In patients with known risk factors, early initiation of thiamine therapy can lead to reversible clinical recovery.

Keywords: confusion, wernicke encephalopathy, gait instability

---

Ref No: 2240

Emergency approach to a patient with cardiac arrest following an electrical injury

Yasin Bülbüloğlu1
1SANLIURFA BALIKLIGOL STATE HOSPITAL
Yasin Bülbüloğlu / SANLIURFA BALIKLIGOL STATE HOSPITAL

Introduction and Purpose: A 39-year-old male with no known comorbidities or surgical history was brought to the emergency department by his relatives. He was in cardiac arrest following an electrocution incident at his workplace. He had no prior history of coronary angiography.

Materials and Methods: Physical Examination: No entry or exit wounds from the electrical current were identified. Epistaxis (nosebleed) due to a fall was present. GCS was 3. No palpable pulse.Resuscitation: Following approximately 15 minutes of effective Cardiopulmonary Resuscitation (CPR), the ECG revealed Pulseless Ventricular Tachycardia (pVT). After successful defibrillation, Acute ST-Segment Elevation Myocardial Infarction (STEMI) was identified.Post-CPR Vital Signs: Blood Pressure: 105/75 mmHg, Heart Rate: 73 bpm, Respiratory Rate: 24 breaths/min, Temperature: 36.5°C, SpO_2: 95% (Intubated).ECG: Diffuse ST-segment changes were present on the post-arrest ECG.Imaging: Brain CT showed no hemorrhage. Computed Tomography Angiography (CTA) of the abdomen and thorax revealed no vascular pathology.

Pulseless Ventricular Tachycardia (pVT) on ECG

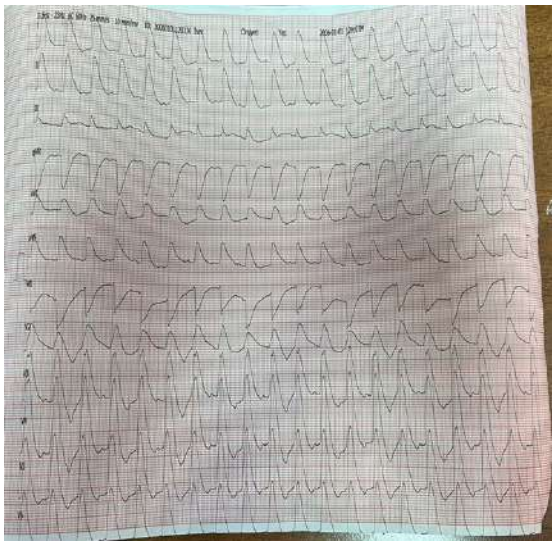

Acute MI findings on post-arrest ECG

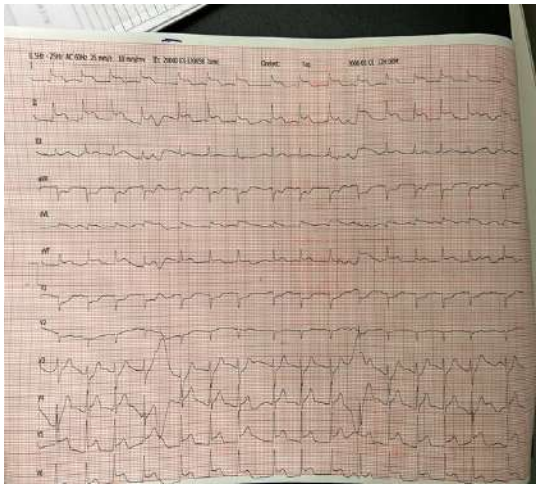

Results and Conclusion: The patient, suspected of having Acute ST-Elevation Myocardial Infarction (STEMI), was administered a 300 mg loading dose of Aspirin via an orogastric tube. An urgent referral was organized to a center capable of performing emergency Percutaneous Coronary Intervention (PCI). Following the coronary angiography procedure at the external facility and subsequent monitoring, the patient was discharged at the end of the 5th day.

Keywords: Acute, arrest, ST

Ref No: 2242

Mesenteric Venous Thrombosis and Secondary Ileus Accompanied by Ventricular Bigeminy: A Rare Clinical Presentation

ÖMER FARUK ÖZ[1], EMRE KALKAN[1], BAŞAR CANDER[1], ZEYNEP ABANOZ[1]
[1]BEZMIALEM VAKIF UNIVERSITY

ÖMER FARUK ÖZ / BEZMIALEM VAKIF UNIVERSITY

Introduction and Purpose: A rare disorder called mesenteric vein thrombosis (MVT) can manifest acutely, subacutely, or persistently. Symptomatic cases usually appear as nonspecific abdominal pain, with or without evidence of intestinal ischemia. In patients with high clinical suspicion, the diagnosis is typically made by imaging tests (abdominal CT or MRI). Ventricular bigeminy is typically a benign arrhythmia but may accompany systemic inflammatory or metabolic disturbances. The coexistence of MVT, secondary ileus, and ventricular bigeminy is extremely rare.

Materials and Methods: A 84-year-old male patient applied to the emergency department with a complaint of vomiting and abdominal pain for 1 day. The patient has heart failure, arrhythmia, hypertension as a known chronic disease. When the patient arrives at the cricital care unit vital signs were; fever:36,50C, pulse:63/min, oxygen saturation(SpO2):95%, respiratory rate:20/min, arterial blood pressure:155/66 mmHg, fingertip blood sugar:186mg/dl. On physical examination, the patient's general condition was fine, Glasgow Coma Scale: 15 (Verbal5, Motor6, Eye4)General tenderness on abdominal examination, no guarding or rebound was detected. In laboratory findings were, Urea: 39 mg/dl, blood ure nitrogen: 18 mg/dl, creatinine: 1.00 mg/dl, eGFR: 69 ml/min, potassium 4.82 mmol/L, white blood cell: 9.37x 10^3/uL, lactate:1.6 mg/dL, INR: 1.01, CRP: 3.8 mg/L. ECG

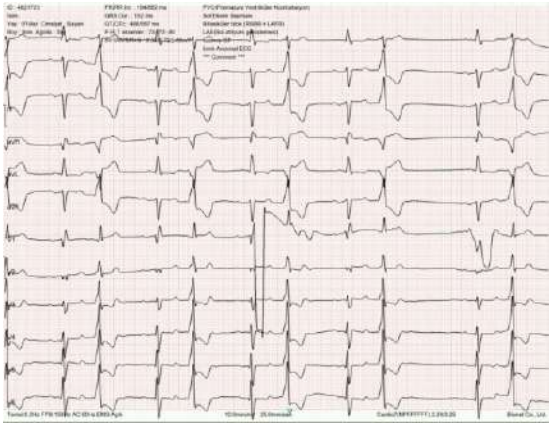

Figure 1: ECG image showing ventricular bigeminy

CT



Figure 2: Monophasic whole-abdominal computed tomography with IV contrast is shown in the coronal plane, ischemic loops of the small bowel with diffuse wall thickness increase and no enhancement in the left abdominal quadrant (arrows). Marked edema and contamination are observed in the mesenteric fat planes surrounding the ischemic loops (stars). Dilated loops with normal wall enhancement compared to the ischemic loops are seen in the right abdominal quadrant (arrowhead).

Results and Conclusion: MVT, or acute mesenteric venous thrombosis, is a rare condition with nonspecific symptoms. Whether intestinal infarction occurs depends on the location, size, and speed of thrombus development . The coexistence of ventricular bigeminy and MVT is fascinating. Although arrhythmias are often caused by electrolyte imbalances or myocardial ischemia, they can also arise from systemic inflammatory or hypoxic stress. In this case, the ventricular bigeminy probably represented a temporary systemic response rather than an underlying cardiac condition.Prompt imaging is key in diagnosing MVT, as laboratory findings are nonspecific. Contrast-enhanced CT remains the gold standard, allowing visualization of thrombus and assessment of bowel viability.Treatment typically involves anticoagulation, supportive care, and in some cases, thrombolysis or surgical intervention if bowel necrosis develops.This case underscores the need for a holistic diagnostic approach in patients presenting with both cardiac arrhythmia and abdominal symptoms, as systemic conditions may underlie both findings.

Keywords: Mesenteric venous thrombosis, ventricular bigeminy, ileus

Ref No: 2249

Late-Onset Clozapine-Induced Agranulocytosis Presenting as Severe Febrile Neutropenia

Ekim Sağlam Gürmen[1], Burak Dilsizler[1]

[1]Manisa Celal Bayar University School of Medicine , Emergency Department , Manisa , Türkiye

Burak Dilsizler / Manisa Celal Bayar University School of Medicine , Emergency Department , Manisa , Türkiye

Introduction and Purpose: Clozapine is an atypical antipsychotic indicated for treatment-resistant schizophrenia (1). Despite its efficacy, it carries a well-established risk of severe hematologic adverse effects, particularly agranulocytosis (1,4). Agranulocytosis is defined by a marked reduction in the absolute neutrophil count (ANC), predisposing patients to life-threatening infections and sepsis (3). For this reason, regular hematological monitoring is mandatory during clozapine therapy (4). We present a case of late-onset clozapine-induced agranulocytosis manifesting as severe febrile neutropenia.

Materials and Methods: A 50-year-old woman with a 20-year history of schizophrenia was admitted to the emergency department (ED) with a one-week history of high fever and altered mental status. She had been receiving clozapine 300 mg/day for four years. On admission, her temperature was 39.4°C, heart rate 115 bpm, and blood pressure 114/73 mmHg.Physical examination revealed bilateral rhonchi, an erythematous infected lesion on the right middle finger, and impaired orientation compared to baseline.Laboratory investigations demonstrated profound pancytopenia: WBC 0.45 $\times 10^3/\mu L$, ANC 0.02 $\times 10^3/\mu L$, hemoglobin 8.8 g/dL, and CRP 32.7 mg/dL. Urinalysis was positive for nitrites and bacteria. Peripheral smear confirmed severe leukopenia and absence of neutrophils.The patient was diagnosed with febrile neutropenia secondary to clozapine-induced agranulocytosis. Clozapine was immediately discontinued (4). Empirical broad-spectrum antibiotics (piperacillin/tazobactam) and granulocyte colony-stimulating factor (G-CSF) were initiated in the ED (2).

Results and Conclusion: Febrile neutropenia is a medical emergency requiring rapid etiological assessment (2). In psychiatric patients presenting with fever, drug-induced agranulocytosis—particularly due to clozapine—must be considered (4). Although the highest risk occurs within the first 18 weeks of treatment, late-onset hematologic toxicity can develop even after years of stable therapy (1). Early discontinuation of clozapine and prompt initiation of antibiotics and G-CSF are critical to reducing morbidity and mortality (5).

Keywords: Clozapine, Febrile Neutropenia, Schizophrenia

Ref No: 2263

Design and Clinical Significance of an Artificial Intelligence-Assisted System for Diagnosing Peripheral and Central Vertigo in the Emergency Department

Ömer TURALİOĞLU[1], Erdal Tekin[1], Esra ODABAŞ YILDIRIM[1]
[1]Atatürk University
Erdal Tekin / Atatürk University

Introduction and Purpose: Differentiating between peripheral and central vertigo in patients presenting to the emergency department with acute dizziness is clinically critical, as diagnostic delays may lead to serious morbidity and mortality. The aim of this study was to develop and evaluate an artificial intelligence–based decision support model to assist in distinguishing peripheral and central vertigo in patients presenting with acute dizziness in the emergency department.

Materials and Methods: In this prospective observational study, a total of 140 patients presenting to the emergency department with acute dizziness were included. Patients were classified as peripheral vertigo (n=86) or central vertigo (n=54) based on clinical history, physical examination findings, vestibular tests, and diffusion MRI results. The dataset was divided into training (80%) and test (20%) sets. Three machine learning models were developed: Logistic Regression (LR), Support Vector Machine (SVM), and RF. Model performance was evaluated using ROC-AUC, accuracy(ACC), precision, recall, and F1 score. Since the primary clinical priority was not to miss central vertigo cases, decision thresholds were optimized to maximize sensitivity. Model interpretability was evaluated using feature importance and SHAP analyses, while performance uncertainty was assessed using bootstrap resampling.

Results and Conclusion: Among the included patients, 61.4% were classified as peripheral vertigo and 38.6% as central vertigo. Neurological symptoms were significantly more common in the central vertigo group. In contrast, tinnitus, ear fullness, and positive Dix-Hallpike test results were more frequent in peripheral vertigo. Among the machine learning models, the RF model demonstrated the highest discriminative performance (ROC-AUC=0.92). With the optimized threshold, the RF model achieved an ACC of 78.6%, sensitivity of 90.9%, and specificity of 70.5%. Bootstrap analysis confirmed the robustness of the model performance with 95% confidence intervals. SHAP and feature importance analyses identified Dix-Hallpike test, dizziness severity, neurological deficit, and gait disturbance as the most influential predictors in the model. The findings of this study suggest that artificial intelligence–based models may support clinical decision-making in distinguishing peripheral and central vertigo in patients presenting with acute dizziness. In particular, the RF model demonstrated high discriminative performance and sensitivity, indicating its potential usefulness as a supportive tool for the early detection of central vertigo in emergency department settings.

Keywords: vertigo, artificial intelligence, machine learning

Ref No: 2279

Acute Appendicitis

Halim Taş[1], Ali GÜR[1]

[1]Ataturk University Research Hospital

Halim Taş / Ataturk University Research Hospital

Introduction and Purpose: Appendicitis is inflammation of the appendix. Symptoms commonly include right lower abdominal pain, nausea, vomiting, fever and decreased appetite. However, approximately 40% of people do not have these typical symptoms. Severe complications of a ruptured appendix include widespread, painful inflammation of the inner lining of the abdominal wall and sepsis. Appendicitis is primarily caused by a blockage of the hollow portion in the appendix. This blockage typically results from a faecolith, a calcified "stone" made of feces.

Materials and Methods: A 55-year-old male patient presented to the emergency department with abdominal pain, predominantly in the left lower quadrant, and nausea and vomiting, which had been present for two days. The patient had no other medical conditions and no abnormalities in his vital signs. Upon arrival, we examined his complete blood count and extensive biochemistry. His complete blood count showed a WBC count of 20,000 with a leftward shift, which was noteworthy. Due to the lack of other biochemical abnormalities, the patient did not improve with symptomatic treatment, and his Alvarado score was between 5 and 6, necessitating further imaging. A contrast-enhanced abdominal CT scan revealed a 25x13 mm appendicolith in the proximal appendix, consistent with appendicitis. The appendix diameter was measured at 21 mm and increased at this level. Additionally, contrast enhancement, increased thickness, and staining in the periapendicular fatty planes of the appendix walls were observed. These findings are significant for acute appendicitis. The patient was referred to the emergency general surgery clinic and underwent emergency surgery. **BT**



Results and Conclusion: In cases of pain localized particularly in the lower right quadrant, acute appendicitis should always be considered. A complete blood count is crucial in this regard. The gold standard for diagnosis is contrast-enhanced abdominal CT imaging. The presence of fever, loss of appetite, nausea and vomiting, and right-sided localized pain should raise suspicion of appendicitis.

Keywords: acute appendicitis, stomachache

Ref No: 2316

Multidisciplinary Stroke Code (Neurocode)Team: Is it time to broaden the workforce on the scene?

Hatice Yelda Yıldız[1], Yavuz Bekmezci[1], Sevil Yusufi[1], Ali Sağlık[2], Tarık Ocak[2], Yakup Krespi[1]

[1]Department of Neurology, Istinye University Faculty of Medicine, Istanbul, Türkiye
[2]Department of Emergency Medicine, Istinye University Faculty of Medicine, Istanbul, Türkiye

Tarık Ocak / Department of Emergency Medicine, Istinye University Faculty of Medicine, Istanbul, Türkiye

Introduction and Purpose: Acute ischemic stroke (AIS) care relies on highly time-sensitive and well-coordinated workflow systems. Although guideline-based stroke pathways emphasize rapid reperfusion and multidisciplinary organization, real-world evidence comparing different in-hospital workflow models within the same comprehensive stroke center remains limited. This study aimed to compare two sequential real-world stroke workflow models—a neurologist-led model and a Neurocode team model composed of trained non-neurologist stroke practitioners (general practitioner hospitalists and a neurocode nurse) operating under neurologist supervision—with respect to door-to-needle time (DNT) performance and early radiological outcomes in patients with AIS treated with intravenous thrombolysis (IVT).

Materials and Methods: This retrospective single-center cohort study was conducted at the Istinye University Liv Hospital Bahçeşehir Comprehensive Stroke Center using prospectively and consecutively collected registry data. Adult patients with AIS who received IVT were included and analyzed across two sequential workflow periods (neurologist-led vs. Neurocode team). Extracted variables included demographic, clinical, imaging, and workflow parameters. Primary endpoints were DNT (analyzed both as continuous and categorical < 60 minutes), hemorrhagic transformation (HT, including PH1/PH2), in-hospital mortality, and 3-month functional outcome measured by the modified Rankin Scale (mRS).

Results and Conclusion: Results:A total of 573 AIS patients were included: 284 (49.6%) in the neurologist-led period and 289 (50.4%) in the Neurocode period. Baseline stroke severity was comparable between groups (NIHSS: 12.09 ± 6.35 vs. 11.72 ± 6.55, p=0.486). Mean DNT did not differ significantly between periods. However, the proportion of patients achieving DNT < 60 minutes was significantly higher in the Neurocode period (74.0% vs. 52.5%, p < 0.001). Early radiological outcomes, including hemorrhagic transformation, were comparable between groups. Three-month functional outcomes (mRS) were similar between groups.Conclusions:A structured Neurocode workflow model demonstrated non-inferior performance compared to a neurologist-led model in terms of DNT and early radiological safety outcomes, with improved adherence to guideline-recommended DNT targets. These findings support the feasibility of multidisciplinary, protocol-driven stroke workflow models, particularly in resource-constrained settings.

Variable	Neurologist-Led (Period 1) (n = 284)	Neurocode (Period 2) (n = 289)	p Value
Demographic and Clinical Characteristics			
Age (yr) — mean ± SD	66.82 ± 14.20	70.73 ± 13.06	**0.002**
Admission NIHSS score — mean ± SD	12.09 ± 6.35	11.72 ± 6.55	0.486
Hypertension — %	56.0	66.5	**0.007**
Diabetes mellitus — %	27.0	36.9	**0.009**
Process Metrics and Early Safety Complications			
Door-to-Needle Time (DNT) (min) — mean ± SD	46.01 ± 24.18	46.84 ± 29.80	0.963
DNT < 60 min — %	**52.5**	**74.0**	**<0.001**
Hemorrhagic transformation at 24h — %	18.2	18.6	0.982
Infarct expansion at 24h — %	33.7	32.8	0.451

Note: Statistically significant values ($p < 0.05$) are highlighted in bold. NIHSS indicates National Institutes of Health Stroke Scale; SD, standard deviation; DNT, Door-to-Needle Time.

Demographic and Clinical Characteristics

Clinical Endpoint	Neurologist-Led (n = 284)	Neurocode (n = 289)	p Value	Visual Comparison
Long-Term Functional Outcomes (3 Months)				
mRS = 0 (No symptoms) — %	23.5	22.7	0.208	
mRS 0–2 (No significant disability) — %	43.5	42.8	0.976	
Mortality (mRS 6) — %	30.1	31.0	0.976	

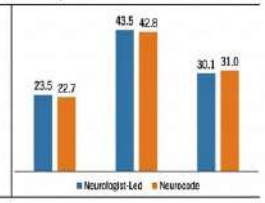

Note: mRS indicates modified Rankin Scale.

Clinical Outcomes

Keywords: Acute Ischemic Stroke, Door-to-Needle Time, Stroke Workflow

---

Ref No: 2348

Hidden Danger Behind Syncope in a Patient with Down Syndrome: Massive Pulmonary Embolism

Mohamad Mukhtar Hamoud[1], Fatma Çakmak[2]
[1]Istanbul Atlas University Faculty of Medicine Hospital, Emergency Department,
[2]Istanbul Atlas University Faculty of Medicine, Department of Emergency Medicine,

Fatma Çakmak / Istanbul Atlas University Faculty of Medicine, Department of Emergency Medicine,

Introduction and Purpose: Syncope is a common emergency department presentation with a broad differential ranging from benign vasovagal episodes to life-threatening cardiovascular conditions. Pulmonary embolism (PE), although uncommon as a cause of syncope, carries high mortality when present. Here, we report a case of massive PE initially investigated for neurological causes, where bedside clinical examination was decisive for diagnosis.

Materials and Methods: A 34-year-old male with Down syndrome presented with recurrent syncope episodes over the last 48 hours, each lasting 1–2 minutes with spontaneous recovery. He had previously undergone neurological evaluation, including brain CT and MRI, which were unremarkable.On arrival to the emergency department, history taking was limited due to cognitive and communication barriers. Vital signs revealed hypotension (95/60 mmHg), tachycardia (124 bpm), tachypnea (24/min), and oxygen saturation of 91% on room air.Physical examination was critical and revealed:Loud P2 componentBilateral basal cracklesLeft lower extremity swelling with a 3 cm increase in diameterPositive Homans signThese findings were consistent with deep vein thrombosis (DVT).Diagnostic WorkupArterial blood gas analysis showed respiratory alkalosis with hypoxemia. D-dimer was significantly elevated (4850 ng/mL). ECG demonstrated sinus tachycardia with right heart strain features. Troponin I was mildly elevated.Given the presence of DVT signs and unexplained syncope with tachycardia, the patient was classified as high probability for PE.Imaging and DiagnosisCT pulmonary angiography revealed a near-complete occlusion of the right main pulmonary artery extending into lobar branches, consistent with massive PE. RV/LV ratio was > 1, indicating right ventricular strain.Management and OutcomeThe patient was diagnosed with high-risk PE and started on therapeutic low-molecular-weight heparin. He was admitted to intensive care for close hemodynamic monitoring and possible thrombolysis if deterioration occurred.

Results and Conclusion: Syncope may be the first and only presentation of massive PE. In patients with communication barriers, meticulous physical examination becomes crucial. Recognition of DVT at bedside can rapidly redirect diagnosis and be lifesaving.

Keywords: Syncope, Pulmonary embolism, Deep vein thrombosis

Ref No: 2351

Diagnostic Profile of Tumor Lysis Syndrome in Oncologic Emergency Admissions: A Retrospective Comparative Study

Arzu Babacan[1], Ahmet Sefa Yeter[1]

[1]Dr. Abdurrahman Yurtaslan Oncology Training and Research Hospital, University of Health Sciences, Emergency Service, Ankara, Turkey

Arzu Babacan / Dr. Abdurrahman Yurtaslan Oncology Training and Research Hospital, University of Health Sciences, Emergency Service, Ankara, Turkey

Introduction and Purpose: Introduction and Purpose: Tumor lysis syndrome (TLS) is a metabolic oncologic emergency characterized by hyperkalemia, hyperuricemia, hyperphosphatemia, and hypocalcemia resulting from rapid tumor cell destruction. Its clinical course may be associated with acute kidney injury, cardiac arrhythmias, and increased mortality. A substantial proportion of oncology patients initially present to the emergency department (ED), and early differentiation of TLS from other oncologic emergencies is important for appropriate clinical management. Although TLS has been extensively studied in the context of hematologic malignancies, comparative data evaluating its diagnostic profile among oncology patients presenting to the ED remain limited. This study aimed to compare the demographic, clinical, and laboratory characteristics of patients diagnosed with TLS and those with other oncologic emergencies in the emergency setting.

Materials and Methods: This retrospective study was conducted in the emergency department of a tertiary oncology hospital between 2017 and 2020. A total of 761 oncologic emergency (OE) admissions were evaluated. Patients were divided into two groups: TLS (n=43) and other OE (n=718). Demographic characteristics, cancer types, comorbidities, laboratory parameters, and clinical outcomes were statistically compared between groups.

Results and Conclusion: Our study presents oncological emergency diagnoses in Table 1. No significant differences were found between the groups in terms of age and gender. All patients in the TLS group had solid malignancies (p=0.026). The prevalence of diabetes mellitus was higher in the TLS group (p=0.006) (Table 2). In the laboratory evaluation, leukocyte, neutrophil, BUN, creatinine, uric acid, potassium, phosphorus, liver enzymes, CRP, and D-dimer levels were significantly higher in the TLS group; sodium, calcium, total protein, and albumin levels were significantly lower ($p < 0.05$) (Table 3). The rate of direct discharge from the emergency department was lower in the TLS group (p=0.005). The overall mortality rate was 67.4% in the TLS group, which was significantly higher than in other oncological emergencies ($p < 0.001$) (Table 4).TLS is associated with distinct laboratory abnormalities and markedly increased

mortality among oncology patients presenting to the emergency department. Careful evaluation of routine laboratory parameters in the ED may facilitate early recognition and guide clinical management in this high-risk population.

Table

Table 1. Emergency diagnosis for patients with cancer admitted to the emergency service

Oncologic Emergencies (N=761)	(n/%)
Metabolic causes	**83 (11.0)**
TLS	43 (5.7)
Syndrome involving inappropriate ADH	22 (2.9)
Maling hypercalcemia	18 (2.4)
Mechanic causes	**361 (47.4)**
Malignant pleural effusion	128 (16.8)
Intestinal and biliary obstruction	91 (12.0)
Increased ICP	83 (10.9)
Cardiac tamponade	18 (2.4)
Pathological fracture	14 (1.8)
VCSS	12 (1.6)
Spinal cord compression	11 (1.4)
Hyper viscosity	4 (0.5)
Treatment-related causes	**20 (2.6)**
Hemorrhagic cystitis	9 (1.2)
Anaphylaxis/capillary leakage syndrome	9 (1.2)
Chemotherapeutic extravasation	2 (0.2)
Blood disorders	**347 (45.6)**
Febrile neutropenia and sepsis/septic shock	174 (22.9)
Anemia/leucopenia/thrombocytopenia	85 (11.2)
Acute bleeding/coagulopathy	45 (5.9)
Arterial or venous embolism	41 (5.4)
GVHD	2 (0.3)
Multiple oncologic emergency diagnoses	**50 (6.6)**

Total number of diagnoses; ADH: Anti-diuretic hormone, ICP: Intracranial pressure, VCSS: Vena cava superior syndrome, GVHD: Graft-versus-host disease, TLS: Tumor lysis syndrome

Table 2: Age, sex, cancer type, and comorbidities of the groups

	TLS (n=43)	Other OEs (n=718)	P
Age	62.0 (52.0-71.0)	59.0 (51.0-68.0)	.442*
Sex			.096†
Female	16 (37.2)	361 (50.3)	
Male	27 (62.8)	357 (49.7)	
Cancer type (n/%)			.026‡
Solid	43 (100.0)	648 (90.3)	
Hematologic	-	70 (9.7)	
Comorbidities (n/%)	34 (79.1)	402 (56.0)	.003†
Hypertension	17 (39.5)	284 (39.6)	.998†
DM	16 (37.2)	141 (19.6)	.006†
CAD	7 (16.3)	83 (11.6)	.352‡
COPD	6 (14.0)	68 (9.5)	.335‡
Asthma	2 (4.7)	16 (2.2)	.270‡

Mann-Whitney U test, †Pearson Chi-square test, ‡ Fisher's exact test, TLS: Tumor lysis syndrome, CAD: Coronary arterial disease, COPD: Chronic obstructive pulmonary disease

Table

Table 3: Laboratory parameters of tumor lysis and other oncological emergency groups

	TLS (n=43)	Other OE (n=718)	P*
	Median (IQR; 25-75 percentiles)		
WBC (x10³/mm³)	15. 2 (9.7-20.0)	6.6 (2.1-11.3)	<0.001
Neutrophile (/mm³)	12.2.0 (7.7-16.9)	4.4 (0.9- 8.5)	<0.001
Hb (g/dL)	10.8 (8.0-12.2)	10.4 (8.9-12.0)	.983
Platelet (x10³/mm³)	205.0 (81.0-287.0)	183.0 (96.0-300.0)	.786
Glucose (mg/dL)	115.0 (94.0-153.0)	114.0 (98.5-145.5)	.709
BUN (mg/dL)	65.0 (42.0-91.0)	17.0 (11.6-26.0)	<0.001
Creatinine (mg/dL)	2.5 (1.9-3.7)	0.7 (0.5-1.0)	<0.001
Uric acid (mg/dL)	10.1 (9.8-12.0)	5.1 (3.5-6.3)	<0.001
Na (mg/dL)	133.0 (128.8-137.3)	136.0 (133.0-138.0)	.015
K (mg/dL)	6.5 (6.2-6.8)	4.1 (3.7-4.6)	<0.001
Ca (mg/dL)	6.2 (6.1-7.0)	8.2 (7.7-8.9)	<0.001
P (mg/dl)	6.1 (5.7-7.1)	3.4 (2.5-4.2)	<0.001
Total protein (mg/dL)	5.0 (4.4-5.4)	5.5 (5.0-6.2)	<0.001
Albumin	2.3 (2.0-2.8)	3.1 (2.5-3.6)	<0.001
ALT (U/L)	39.0 (20.0-146.0)	19.0 (12.0-33.0)	<0.001
AST (U/L)	64.0 (29.0-183.0)	25.0 (17.0-44.0)	<0.001
GGT (U/L))	82.0 (50.0-255.0)	46.0 (23.5-111.0)	<0.001
Amylase (U/L)	89.0 (41.0-125.0)	46.0 (31.5-76.5)	<0.001
Total bilirubin (mg/dL)	1.1 (0.5-2.8)	0.7 (0.4-1.1)	.005
Direct bilirubin (mg/dL)	0.4 (0.1-1.8)	0.2 (0.1-0.4)	.002
CRP (mg/dL)	222.5 (139.8-254.5)	90.0 (25.0-174.0)	<0.001
D-Dimer (ng/mL)	7040.0 (2617.5-12000.0)	2597.0 (1298.0-4400.0)	.003

** Mann-Whitney U test, TLS: Tumor lysis syndrome*

Table 4: Outcomes of the groups in the emergency service and overall outcomes

	TLS (n=43)	Other OEs (n=718)	P
Outcome in ES			.005*
Discharge from ES	1 (2.3)	127 (17.7)	
Hospitalization	42 (97.7)	591 (82.3)	
Overall outcome			<0.001†
Discharge from the hospital	14 (32.6)	584 (81.3)	
Mortality	29 (67.4)	134 (18.7)	

Fisher's exact test, †Pearson Chi-square test, TLS: Tumor lysis syndrome

Table 1. Emergency diagnosis for patients with cancer admitted to the emergency service

Table 1. Emergency diagnosis for patients with cancer admitted to the emergency service

Oncologic Emergencies (N=761)	(n/%)
Metabolic causes	**83 (11.0)**
TLS	43 (5.7)
Syndrome involving inappropriate ADH	22 (2.9)
Maling hypercalcemia	18 (2.4)
Mechanic causes	**361 (47.4)**
Malignant pleural effusion	128 (16.8)

Intestinal and biliary obstruction	91 (12.0)
Increased ICP	83 (10.9)
Cardiac tamponade	18 (2.4)
Pathological fracture	14 (1.8)
VCSS	12 (1.6)
Spinal cord compression	11 (1.4)
Hyper viscosity	4 (0.5)
Treatment-related causes	**20 (2.6)**
Hemorrhagic cystitis	9 (1.2)
Anaphylaxis/capillary leakage syndrome	9 (1.2)
Chemotherapeutic extravasation	2 (0.2)
Blood disorders	**347 (45.6)**
Febrile neutropenia and sepsis/septic shock	174 (22.9)
Anemia/leucopenia/thrombocytopenia	85 (11.2)
Acute bleeding/coagulopathy	45 (5.9)
Arterial or venous embolism	41 (5.4)
GVHD	2 (0.3)
Multiple oncologic emergency diagnoses	**50 (6.6)**
Total number of diagnoses: ADH: Anti-diuretic hormone, ICP: Intracranial pressure, VCSS: Vena cava superior syndrome, GVHD: Graft-versus-host disease, TLS: Tumor lysis syndrome	

Table 2: Age, sex, cancer type, and comorbidities of the groups

Table 2: Age, sex, cancer type, and comorbidities of the groups

	TLS (n=43)	Other OEs (n=718)	P
Age	62.0 (52.0-71.0)	59.0 (51.0-68.0)	.442*
Sex			
Female	16 (37.2)	361 (50.3)	.096†
Male	27 (62.8)	357 (49.7)	
Cancer type (n/%)			
Solid	43 (100.0)	648 (90.3)	.026‡
Hematologic	-	70 (9.7)	
Comorbidities (n/%)	34 (79.1)	402 (56.0)	.003†
Hypertension	17 (39.5)	284 (39.6)	.998†
DM	16 (37.2)	141 (19.6)	.006†
CAD	7 (16.3)	83 (11.6)	.352†
COPD	6 (14.0)	68 (9.5)	.335†
Asthma	2 (4.7)	16 (2.2)	.270‡

Mann-Whitney U test, †Pearson Chi-square test, ‡ Fisher's exact test, TLS: Tumor lysis syndrome, CAD: Coronary arterial disease, COPD: Chronic obstructive pulmonary disease

Table 3: Laboratory parameters of tumor lysis and other oncological emergency groups

Table 3: Laboratory parameters of tumor lysis and other oncological emergency groups

	TLS (n=43)	Other OE (n=718)	P*
	Median (IQR; 25-75 percentiles)		
WBC (x10^3/mm^3)	15. 2 (9.7-20.0)	6.6 (2.1-11.3)	<0.001
Neutrophile (/mm^3)	12.2.0 (7.7-16.9)	4.4 (0.9- 8.5)	<0.001
Hb (g/dL)	10.8 (8.0-12.2)	10.4 (8.9-12.0)	.983
Platelet (x10^3/mm^3)	205.0 (81.0-287.0)	183.0 (96.0-300.0)	.786
Glucose (mg/dL)	115.0 (94.0-153.0)	114.0 (98.5-145.5)	.709
BUN (mg/dL)	65.0 (42.0-91.0)	17.0 (11.6-26.0)	<0.001
Creatinine (mg/dL)	2.5 (1.9-3.7)	0.7 (0.5-1.0)	<0.001
Uric acid (mg/dL)	10.1 (9.8-12.0)	5.1 (3.5-6.3)	<0.001
Na (mg/dL)	133.0 (128.8-137.3)	136.0 (133.0-138.0)	.015
K (mg/dL)	6.5 (6.2-6.8)	4.1 (3.7-4.6)	<0.001

Ca (mg/dL)	6.2 (6.1-7.0)	8.2 (7.7-8.9)	<0.001
P (mg/dl)	6.1 (5.7-7.1)	3.4 (2.5-4.2)	<0.001
Total protein (mg/dL)	5.0 (4.4-5.4)	5.5 (5.0-6.2)	<0.001
Albumin	2.3 (2.0-2.8)	3.1 (2.5-3.6)	<0.001
ALT (U/L)	39.0 (20.0-146.0)	19.0 (12.0-33.0)	<0.001
AST (U/L)	64.0 (29.0-183.0)	25.0 (17.0-44.0)	<0.001
GGT (U/L))	82.0 (50.0-255.0)	46.0 (23.5-111.0)	<0.001
Amylase (U/L)	89.0 (41.0-125.0)	46.0 (31.5-76.5)	<0.001
Total bilirubin (mg/dL)	1.1 (0.5-2.8)	0.7 (0.4-1.1)	.005
Direct bilirubin (mg/dL)	0.4 (0.1-1.8)	0.2 (0.1-0.4)	.002
CRP (mg/dL)	222.5 (139.8-254.5)	90.0 (25.0-174.0)	<0.001
D-Dimer (ng/mL)	7040.0 (2617.5-12000.0)	2597.0 (1298.0-4400.0)	.003

** Mann-Whitney U test, TLS: Tumor lysis syndrome*

Table 4: Outcomes of the groups in the emergency service and overall outcomes

Table 4: Outcomes of the groups in the emergency service and overall outcomes

	TLS (n=43)	Other OEs (n=718)	P
Outcome in ES			
Discharge from ES	1 (2.3)	127 (17.7)	.005*
Hospitalization	42 (97.7)	591 (82.3)	
Overall outcome			
Discharge from the hospital	14 (32.6)	584 (81.3)	<0.001†
Mortality	29 (67.4)	134 (18.7)	

Fisher's exact test, †Pearson Chi-square test, TLS: Tumor lysis syndrome

Keywords: Tumor lysis syndrome, oncologic emergencies, emergency department

Ref No: 2357

A retrospective analysis of the demographic and clinical features of patients who arrived at the emergency department due to traffic accidents

Mehmet Reşit Öncü[1]

[1]Van Yüzüncü Yıl Üniversitesi, Faculty of Medicine, Emergency Medicine

Mehmet Reşit Öncü / Van Yüzüncü Yıl Üniversitesi, Faculty of Medicine, Emergency Medicine

Introduction and Purpose: Trauma remains one of the leading causes of mortality and morbidity worldwide, particularly among young individuals, and constitutes a major public health concern. Global data shows that millions of people are hurt or die every year from road traffic accidents (RTAs), and around two-thirds of these deaths occur among the working-age population (18–59 years). This highlights the substantial social and economic impact of injuries caused by RTAs. RTAs account for a significant proportion of trauma cases and place a considerable burden on healthcare systems, particularly in developing countries. This study aimed to retrospectively analyze the demographic characteristics, trauma mechanisms, clinical findings, and management of patients presenting to the emergency department following RTAs.

Materials and Methods: This retrospective observational study included patients who presented to the emergency department of a tertiary university hospital with RTAs in 2024 and had accessible data. Patient information was obtained from the hospital's electronic medical records system

Results and Conclusion: A total of 286 patients were included, of whom 65.4% were male, and 34.6% were female, with a mean age of 33.3 ± 17.8 years. Most cases (81.8%) involved in-vehicle RTAs, followed by pedestrian-related (15.0%) and motorcycle accidents (3.1%); 7.7% of patients were referred from other centers. Tables 1 and 2 show patients' demographic and clinical characteristics and odds ratios for mortality, while clinical findings, injury characteristics, and patient outcomes are summarized in Table 3. In-vehicle RTAs were the most common mechanism of injury in this study, emphasizing their important role in trauma epidemiology. Parameters associated with mortality indicate that low GCS reflects both central nervous system dysfunction and systemic complication risk, elevated creatinine and potassium levels reflect multiorgan dysfunction and metabolic derangement, and low hemoglobin and platelet levels reflect bleeding and coagulopathy. In multivariate logistic regression analysis, low GCS and elevated creatinine levels were identified as independent predictors of mortality. The mean emergency department stay of approximately three hours underscores the prolonged nature of trauma patient evaluation, which can be attributed to the use of imaging modalities and the

necessity of a multidisciplinary approach. It is crucial to develop preventive strategies for RTAs and enhance trauma management protocols.

Table 1. Patients' Demographic and Clinical Characteristics

Variable	Surviving (Mean)	Ex (Mean)	p value
Age	32.8	51.6	0.105
GCS	14.84	8.37	<0.001
HGB	14.23	10.33	<0.001
WBC	10.43	10.33	0.654
Kreatinin	0.87	3.44	0.003
Glukoz	118.4	102.9	0.823
Potasyum	4.06	5.37	0.019
PLT	256	178	0.011
Sodyum	138.2	139.0	0.101

This table summarizes the demographic (e.g., age, gender) and clinical characteristics of the patients included in the study, providing an overview of the study population.

Table 2. Odds Ratios for Mortality and Associated Risk Factors

Variable	OR (Odds Ratio)	95% CI	p value
GCS	0.62	0.48 – 0.81	<0.001
HGB	0.81	0.59 – 1.12	0.201
Kreatinin	1.74	1.18 – 2.95	0.012
Potasyum	1.39	0.98 – 2.64	0.078
PLT	0.996	0.991 – 1.002	0.118

This table presents the odds ratios for mortality and the associated risk factors, showing how different variables are related to the likelihood of death.

Table 3. Clinical Findings, Injury Characteristics, and Outcomes of the Patient

Parameter	Result / (n)
Commonly injured regions	Head and neck; thorax; lower extremities
Most common fracture types	Rib fractures; tibia, fibula, and femur fractures
Most common admitting services	Orthopedics; Thoracic Surgery
Intensive care unit admissions	Anesthesiology and Reanimation: 10; Pediatric: 3
Imaging performed	Brain CT: 242; Thorax CT: 170; Pelvis CT: 55
Patients undergoing surgery	31
Tube thoracostomy in ED	7
Patients with no imaging	3 / (unstable/arrest)
Emergency department mortality	5
Intensive care mortality	3

This table presents the patients' clinical findings, characteristics of their injuries, and outcomes, providing an overall summary of their clinical course and results.

Keywords: Emergency department, GCS, Traffic accident

Ref No: 2376

Oxygen-Resistant Cyanosis: A Case of Suspected Methemoglobinemia in a Secondary Care Emergency Department Confirmed by Co-oximetry at a Tertiary Center

Mustafa Yorgancıoğlu[1], Ekim Sağlam Gürmen[2]

[1]İzmir Torbalı State Hospital
[2]Manisa Celal Bayar University Hospital, Emergency Department,

Mustafa Yorgancıoğlu / İzmir Torbalı State Hospital

Introduction and Purpose: Methemoglobinemia is a dyshemoglobinemia caused by oxidation of hemoglobin iron from the ferrous (Fe^{2+}) to the ferric (Fe^{3+}) state, resulting in functional hypoxia. MetHb levels are normally below 1–2%, while higher levels may lead to cyanosis and systemic symptoms.Acquired forms are most commonly associated with local anesthetics, particularly benzocaine. In the emergency setting, cyanosis unresponsive to oxygen therapy, combined with discrepancy between pulse oximetry and arterial blood gas findings, suggests dyshemoglobinemia and raises suspicion for saturation gap.

Materials and Methods: Case PresentationA 32-year-old male presented with dyspnea and lip cyanosis 30 minutes after a dental procedure involving topical benzocaine. Vital signs were: blood pressure 124/78 mmHg, heart rate 108/min, respiratory rate 22/min, temperature 36.8°C, and SpO_2 83% on room air. The patient was conscious, with grayish discoloration of the lips and nail beds. Lung examination was normal.Oxygen therapy was initiated via a non-rebreather mask at 10 L/min. Arterial blood gas analysis revealed pH 7.40, $PaCO_2$ 37 mmHg, and PaO_2 172 mmHg. Despite high calculated oxygen saturation, pulse oximetry remained at 84–85%, suggesting dyshemoglobinemia and raising suspicion for saturation gap.The patient was referred to a tertiary center. External records revealed a MetHb level of 18%. After methylene blue therapy in the intensive care unit, clinical improvement was observed, and the patient was discharged within 24 hours.

Results and Conclusion: Methemoglobinemia causes functional hypoxia and may mimic pulmonary disorders. Cyanosis typically appears when MetHb exceeds 10%, while symptoms such as dyspnea may occur at higher levels. Acquired cases are most commonly associated with benzocaine exposure. Pulse oximetry often shows values around 82–86% despite normal or elevated PaO_2, creating discrepancy suggestive of dyshemoglobinemia (saturation gap). Definitive diagnosis is established by co-oximetry, and methylene blue is recommended in symptomatic patients or when MetHb exceeds 20%. Methemoglobinemia should be considered in patients with cyanosis unresponsive to oxygen therapy despite normal or elevated PaO_2. In settings where co-oximetry is unavailable, early referral based on clinical suspicion is essential.

This case highlights that discrepancy between pulse oximetry and arterial blood gas findings is a key diagnostic clue in the emergency department.

Laboratory biochemical parameters



Parametre Adı	Sonuç	Birim	Normal Değerler		Önceki Sonuç
Troponin I	5.31	ng/L	0.0	47	8.34 / 11.93

Laboratory biochemical parameters, complete blood count, and troponin I level of the patient at admission.

Arterial Blood Gas Analysis

Parametre Adı	Sonuç	Birim	Normal Değerler		Önceki Sonuç
pH	7,40		7,35	7,45	7,381/7,365
pCO2	37	mmHg	32	48	33,3/40,1
pO2	172	mmHg	83	108	95,1/ 90,4
Na+	141	mmol/L	135	146	140/141
K+	4,32	mmol/L	3,4	4,5	4,14/4,33
Cl-	105	mmol/L	98	106	101/103
Ca++	1,20	mmol/L	1,15	1,29	1,21/1,24
Hct	44,8	%	36	53	52,5/50,1
Glu	90	mg/dL	70	104	85/90
Lac	1,1	mmol/dL	0,5	1,6	0,2/0,5
tHb	15,6	g/dL	11,7	17,4	17,3/16,8
COHb	1,2	%	0,5	1,5	0,7/1,1
sO2	84	%	95	99	98,3/99,2
BEecf	-0,5	mmol/l	(-3)	(+3)	1,0/1,5
BE(B)	-0,5	mmol/L	(-7)	(+2)	1,0/1,5
HCO3-	23,3	mmol/L	21	28	26,3/25,8
Osmolarite	291				285/290
HCO3std	23,5	mmol/L	21	28	26,0/25,9

Arterial blood gas analysis results at presentation.

Keywords: Methemoglobinemia, Benzocaine, Saturation gap

Ref No: 2421

Emergency Department Rabies Vaccinations: An Epidemiological Study at Kars University Hospital

Levent Şahin[1], Merih Şimşek[2]

[1]Kafkas University, Medical School, Emergency Medicine Department
[2]Afyon Health Sciences University, Faculty of Medicine, Department of Medical Microbiology

Levent Şahin / Kafkas University, Medical School, Emergency Medicine Department

Introduction and Purpose: Rabies is a viral zoonotic disease, mostly transmitted from rabid dogs, that causes encephalomyelitis in humans and is fatal. This study aimed to investigate the epidemiology of cases who presented to the emergency department due to suspected rabies animal contact and received the rabies vaccine.

Materials and Methods: Gender, age, mode of contact with suspected rabies-infected animals, animal species, animal ownership and vaccination status, wound care, and whether vaccinations or immunoglobulins were administered were retrospectively examined in patients who presented to the emergency department.

Results and Conclusion: The study was completed with a total of 107 cases, 67 men and 40 women. The animals that caused suspected contact included 39 dogs, 36 cats, 9 foxes, 8 horses, 6 bears, 6 sheep, and 5 cows. Of these animals, 36.4% were stray and unvaccinated, while 33.6% were owned and vaccinated. The rate of escaped animals was 23.4%, while the percentage of owned and vaccinated animals was very low (6.5%). Thirty-four of the cases received only vaccination (rabies, tetanus, or rabies + tetanus). Forty-two patients received wound care and vaccination prophylaxis, while 31 patients received immunoglobulin treatment. It was determined that risky animal contact was most common among young and middle-aged men. These animals were generally stray, unvaccinated, or escaped. Taking stray street animals into shelters under veterinary control and raising awareness about rabies could significantly reduce potential cases.

Keywords: Rabies, risky animal contact, vaccine

Ref No: 2426

Investigation of the Effect of Inflammatory Indexes and Shock Indexes on Clinical Course and Prognosis in Pulmonary Embolism

Muhammet Onur Yurten[1], Muhammed Ekmekyapar[1], Erkut Erol[1]

[1]Department of Emergency Medicine, Elazığ Fethi Sekin City Hospital, Elazığ, Türkiye

Muhammed Ekmekyapar / Department of Emergency Medicine, Elazığ Fethi Sekin City Hospital, Elazığ, Türkiye

Introduction and Purpose: Pulmonary embolism (PE) is a life-threatening condition caused by thrombi arising from the deep veins of the lower extremities and causing obstruction in the pulmonary artery and/or its branches. This study investigated the effect of the systemic immune-inflammatory index (SII), systemic inflammatory response index (SIRI), shock index (SI), and modified shock index (MSI) on the clinical course and prognosis in PE patients.

Materials and Methods: A total of 259 adult patients were included in the study. The data consisted of age, gender, vital signs (temperature, pulse, blood pressure, SpO_2), comorbidities, presenting complaints, and hematological parameters (complete blood count, biochemistry, CRP, blood gas, lactate, D-dimer, troponin, etc.). In addition, SIRI, SII, SI, and MSI values were calculated and added to the data. The days of admission to the ward and intensive care unit were recorded for the patients. Patient mortality status was assessed, and the study population was stratified into two groups: survivors and non-survivors. Furthermore, the mortality status of the patients was divided into three groups based on time: survivors, early mortality (≤28 days), and late mortality (> 28 days).

Results and Conclusion: Mortality occurred during hospitalization in 36 patients. Mortality occurred in the early period (≤28 days) in 30 patients and in the late period (> 28 days) in 6 patients. When comparing the survivors and non survivors, the mortality group had a noticeably higher age. Regarding the length of stay, the intensive care unit stay was significantly longer in the deceased patients, while the ward stay was noticeably shorter in these patients. When comparing blood parameters between the two groups, white blood cells (WBC), monocytes, glucose, aspartate aminotransferase (AST), lactate dehydrogenase (LDH), D-dimer, lactate, and urea were significantly higher in the mortality group; hemoglobin (Hb), lymphocytes, albumin, calcium (Ca), and pH were significantly lower. In addition, SII, SIRI, SI, and MSI were noticeably higher in the mortality group. In the multivariate logistic model, age and gender were retained as mandatory covariates. In this multivariate model, only age remained independently significant. SII, SIRI, SI, and MSI are important parameters for predicting the prognosis of patients with PE.

Table 1. Comparison of age, vital signs, length of stay and hematological parameters between surviving and mortality patients

Variable	Survivors (mean±SD) n:223	Mortality (mean±SD) n:36	p
Age	69.27±15.55	79.31±11.65	**<0.001**
Systolic blood pressure	126.65±23.84	116.97±32.80	>0.05
Diastolic blood pressure	77.25±14.67	70.83±18.56	>0.05
MAP	93.72±16.19	86.21±21.86	>0.05
Fever	36.53±0.54	36.49±0.48	>0.05
Pulse	97.44±22.05	106.78±21.21	<0.05
SpO2	89.06±7.47	84.33±9.61	**<0.01**
Respiratory rate	18.70±3.02	20.28±4.39	**<0.05**
Service admission day	9.48±7.00	6.00±15.86	**<0.001**
ICU admission day	4.15±12.40	20.89±42.57	**<0.001**
Total admission days	13.56±13.80	26.86±44.28	>0.05
WBC	10.66 ± 4.02	12.96 ± 5.55	**<0.05**
Hb	13.73 ± 9.82	12.47 ± 2.12	**<0.05**
Plt	247.76 ± 99.46	240.42 ± 101.08	>0.05
Neutrophil	7.55 ± 4.14	10.13 ± 4.47	>0.05
Lymphocyte	1.74 ± 1.16	0.93 ± 0.62	**<0.05**
Monocyte	0.96 ± 0.73	1.70 ± 1.39	**<0.05**
Glucose	148.11 ± 63.78	166.17 ± 53.00	**<0.05**
AST	32.96 ± 35.29	75.39 ± 137.11	**<0.01**
ALT	27.39 ± 30.76	54.06 ± 96.95	>0.05
Üre	45.06 ± 21.45	73.49 ± 42.06	**<0.001**
Na	137.28 ± 3.74	138.56 ± 8.52	>0.05
Cl	104.23 ± 3.76	103.81 ± 7.79	>0.05
K	4.53 ± 2.81	4.59 ± 0.84	>0.05
Ca	8.99 ± 0.58	8.51 ± 0.73	**<0.001**
LDH	330.58 ± 165.23	448.91 ± 298.74	**<0.001**
Albumin	37.37 ± 21.35	32.92 ± 5.23	**<0.01**
CRP	60.06 ± 71.65	81.89 ± 78.97	>0.05

D-dimer	5.33 ± 4.51	8.46 ± 14.51	**<0.05**
Hs-TnI	170.98 ± 356.03	225.41 ± 432.58	>0.05
pH	7.38 ± 0.07	7.33 ± 0.16	**<0.05**
pCO2	42.25 ± 7.75	45.82 ± 15.97	>0.05
pO2	48.26 ± 22.78	48.02 ± 29.26	>0.05
HCO3	25.30 ± 3.62	24.78 ± 8.06	>0.05
Lactate	2.15 ± 1.57	3.63 ± 2.84	**<0.001**

MAP: Mean arterial pressure, ICU: Intensive care unit, WBC: White blood cell, Hb: Hemoglobin, Plt: Platelet, AST: Aspartate aminotransferase, ALT: Alanine aminotransferase, Na: Sodium, Cl: Chloride, K: Potassium, Ca: Calcium, LDH: Lactate dehydrogenase, CRP: C-reactive protein, Hs-TnI: High Sensitivity Troponin I

Table 2. Comparison of SIRI, SII, SI, and MSI in surviving and mortality patients

Index	**Survivors (mean±SD)** **n:223**	**Mortality (mean±SD)** **n:36**	**p**
SIRI	5.85±7.13	13.02±17.76	**<0.001**
SII	1732.66±1705.22	2713.73±2239.71	**<0.01**
SI	0.80±0.25	1.00±0.39	**<0.001**
MSI	1.07±0.31	1.34±0.53	**<0.001**

SIRI: Systemic Inflammatory Response Index, SII: Systemic Immune-Inflammatory Index, SI: Shock Index, MSI: Modified Shock Index

Table 3. ROC analyses: Characteristic analysis of SIRI, SII, SI, and MSI for mortality prediction

Index	**AUC (95% CI)**	**p**	**n**
SIRI	0.707 (0.608-0.789)	**<0.001**	259
SII	0.651 (0.553-0.748)	**<0.01**	259
SI	0.676 (0.574-0.775)	**<0.01**	259
MSI	0.679 (0.571-0.781)	**<0.01**	259

SIRI: Systemic Inflammatory Response Index, SII: Systemic Immune-Inflammatory Index, SI: Shock Index, MSI: Modified Shock Index

Table 4. Multivariate logistic regression

Variable	OR (95% CI)	p
Age	2.27 (1.32-3.90)	**<0.01**
Gender	0.41 (0.15-1.08)	>0.05
SIRI	1.45 (0.91-2.33)	>0.05
SII	1.18 (0.77-1.82)	>0.05
SI	1.07 (0.30-3.76)	>0.05
MSI	1.76 (0.50-6.21)	>0.05

SIRI: Systemic Inflammatory Response Index, SII: Systemic Immune-Inflammatory Index, SI: Shock Index, MSI: Modified Shock Index

Table 5. Systemic inflammation and hemodynamic indices (SII, SIRI, SI, MSI) between groups

Variables	Grup	n	Median [IQR]	p (KW)
SIRI	Survivor	223	3.4 [2.0-6.8]	**<0.001**
	Early mortality	30	6.6 [4.5-12.8]	
	Late mortality	6	9.6 [5.6-11.6]	
SII	Survivor	223	1132.4 [658.5-2009.8]	**<0.05**
	Early mortality	30	1891.4 [1034.1-3899.9]	
	Late mortality	6	2196.4 [1293.7-5073.3]	
SI	Survivor	223	0.8 [0.6-0.9]	**<0.01**
	Early mortality	30	0.9 [0.8-1.2]	
	Late mortality	6	0.8 [0.6-1.1]	
MSI	Survivor	223	1.0 [0.9-1.2]	**<0.01**
	Early mortality	30	1.3 [1.1-1.6]	
	Late mortality	6	1.0 [0.9-1.4]	

SIRI: Systemic Inflammatory Response Index, SII: Systemic Immune-Inflammatory Index, SI: Shock Index, MSI: Modified Shock Index

Keywords: Inflammatory indices, pulmonary embolism, shock indices

Ref No: 2508

Prediction of Intensive Care Requirement and Mortality in Patients with Traumatic Intracranial Hemorrhage Presenting to the Emergency Department: A Comparison of GCS, RTS, NEWS, and APACHE-2

Onur Bozdağ[1], Jülide Gürbüz[1], Abdullah Yaser Güney[2], Ömer Faruk Çakıroğlu[3], Onur Ali Akgün[1], Erdem Yerlioğlu[1], Başar Cander[1]

[1]Bezmialem vakıf üniversitesi
[2]Başakşehir çam ve sakura şehir hastanesi
[3]Kartal Dr Lütfi Kirdar Şehir Hastanesi

Onur Bozdağ / bezmialem vakıf üniversitesi

Introduction and Purpose: Traumatic brain injury (TBI), particularly traumatic intracranial hemorrhage (ICH), is a major cause of mortality and requires critical management in intensive care settings. Accurate early risk stratification is essential for optimizing clinical decision-making. This study aimed to compare the prognostic performance of GCS, RTS, NEWS, and APACHE-2 in predicting mortality in patients with traumatic ICH.

Materials and Methods: This retrospective observational study included adult patients presenting to the emergency department with traumatic ICH and subsequently admitted to the intensive care unit. Demographic and clinical data, along with GCS, RTS, NEWS, and APACHE-2 scores at admission, were recorded. The primary outcome was in-hospital mortality. Prognostic performance was evaluated using univariate logistic regression, receiver operating characteristic (ROC) analysis, and McFadden pseudo-R^2.

Results and Conclusion: A total of 43 patients were included, with an in-hospital mortality rate of 23.3%. Non-survivors had significantly lower GCS and RTS scores and higher NEWS and APACHE-2 scores (all $p < 0.01$). RTS was inversely associated with mortality (OR 0.49, p=0.003), whereas NEWS (OR 1.46, p=0.003) and APACHE-2 (OR 1.24, p=0.005) were positively associated. APACHE-2 demonstrated the highest AUC (0.826), while NEWS showed the highest explanatory power (McFadden R^2=0.268), specificity (93.94%), and accuracy (88.37%). GCS had the highest sensitivity (80.00%). Optimal cut-offs were RTS ≤5.5, NEWS ≥6.5, APACHE-2 ≥18.5, and GCS ≤10.APACHE-2 provides strong overall prognostic performance, whereas NEWS offers superior specificity and accuracy for risk stratification. GCS remains valuable for its high sensitivity in initial assessment. A combined approach integrating neurological and physiological scores may improve prognostic accuracy in traumatic ICH.

Keywords: apache 2, news, traumatic brain injury

Ref No: 2510

Cardiac Tamponade Associated with Atypical Antipsychotics: A Case Series of Two Patients

Lütfi Anıl Güdek[1], Burcu Simge Eroğlu[1], Arzu Çapraz Olçay[1], Büşra Bildik[1], Bora Çekmen[1]

[1]Karabuk University, Faculty of Medicine, Department of Emergency Medicine

Lütfi Anıl Güdek / Karabuk University, Faculty of Medicine, Department of Emergency Medicine

Introduction and Purpose: Atypical antipsychotics are widely used in the treatment of many psychiatric disorders, particularly schizophrenia and bipolar disorder. In addition to their metabolic effects, these medications have been shown to cause significant cardiac adverse effects such as arrhythmia, cardiomyopathy, myocarditis, and pericardial diseases.In this case series, we aimed to draw attention to rare but serious pericardial complications by presenting two cases of cardiac tamponade developing in patients using atypical antipsychotics.

Materials and Methods: Case 1:An 84-year-old female patient presented with progressively worsening dyspnea over the past 4 days. Her medical history included hypertension, diabetes mellitus, chronic kidney disease, and congestive heart failure. The patient was taking nebivolol, apixaban, isosorbide mononitrate, furosemide, linagliptin, quetiapine, and sertraline, and her quetiapine dose had been increased from 50 mg/day to 200 mg/day approximately 2 months prior.On admission, she was hypotensive (80/50 mmHg) and tachycardic. ECG showed sinus bradycardia and low voltage. Physical examination revealed jugular venous distention, muffled heart sounds, and pretibial edema. Bedside ultrasonography demonstrated a 3 cm pericardial effusion with right ventricular diastolic collapse. Thoracic CT confirmed pericardial and bilateral pleural effusion. Cardiac tamponade was diagnosed, and emergency pericardiocentesis was performed.Case 2:A 76-year-old female presented after syncope. Her history included hypertension, diabetes mellitus, and heart failure. She was using torasemide, quetiapine, risperidone, olanzapine, amlodipine, metformin, and atorvastatin. The risperidone dose had been increased from 1 to 5 mg/day 8 days prior.At admission, she was confused (GCS 10) with stable vital signs. ECG showed sinus rhythm with occasional ventricular extrasystoles. Physical examination was unremarkable. Thoracic CT revealed pericardial and bilateral pleural effusion. During follow-up, hypotension and tachycardia developed. Bedside ultrasonography showed a 3.5 cm pericardial effusion with right ventricular diastolic collapse. Cardiac tamponade was diagnosed, and pericardiocentesis was planned.

Results and Conclusion: These cases demonstrate that pericardial effusion associated with antipsychotic use may progress to cardiac tamponade and, although rare, can have a potentially

fatal course. Awareness of pericardial complications, along with early diagnosis and prompt intervention, is crucial in reducing morbidity and mortality in patients receiving antipsychotic therapy.

Keywords: Cardiac tamponade, Atypical antipsychotics, Pericardial effusion

---

Ref No: 2559

Predictive Value of Cardiometabolic Lipid Indices for ICU Admission and Mechanical Ventilation in Acute Pulmonary Embolism: Comparison with PESI, sPESI, SOFA, and APACHE II Scores

Karya Yurtsever Ucdal[2], Evren Ekingen[1]

[1]Etimesgut Şehit Sait Erturk State Hospital
[2]Hacettepe University

Evren Ekingen / Etimesgut Şehit Sait Erturk State Hospital

Introduction and Purpose: Acute pulmonary embolism (APE) carries significant morbidity requiring early identification of patients needing intensive care unit (ICU) admission or mechanical ventilation (MV). Established severity scores including PESI, simplified PESI (sPESI), SOFA, and APACHE II are widely used; however, readily calculable cardiometabolic lipid indices reflecting metabolic and inflammatory burden have not been comparatively evaluated against these scores. We investigated the predictive performance of six cardiometabolic indices — triglyceride-glucose index (TyG), TyG-BMI, triglyceride/albumin ratio (TG/Alb), total cholesterol/albumin ratio (TC/Alb), atherogenic index of plasma (AIP), and metabolic score for insulin resistance (METS-IR) — for ICU admission and MV, and compared their discriminative ability with established severity scores.

Materials and Methods: This single-center retrospective cohort study included 190 adults with CTPA-confirmed APE presenting to the emergency department between January 2020 and December 2024. Patients with chronic thromboembolic disease, active malignancy, pregnancy, or incomplete data were excluded. Cardiometabolic indices and severity scores were calculated from admission data. Primary outcome was ICU admission; secondary outcome was MV requirement. ROC analysis with DeLong's test, multivariate logistic regression adjusted for age, sex, troponin, RV/LV ratio, and D-dimer, Spearman correlation, and NRI/IDI analyses were performed.

Results and Conclusion: ICU admission occurred in 68 patients (35.8%) and 31 (16.3%) required MV. For ICU prediction, TyG-BMI (AUC: 0.772) outperformed all cardiometabolic indices (TG/Alb 0.749, METS-IR 0.734, TyG 0.718, AIP 0.709, TC/Alb 0.691), while PESI achieved 0.801, sPESI 0.783, SOFA 0.814, and APACHE II 0.826. For MV prediction, TyG-BMI reached 0.758, comparable to PESI (0.789) and sPESI (0.771), but inferior to SOFA (0.838) and APACHE II (0.851). TyG-BMI significantly correlated with PESI (r=0.41), sPESI (r=0.37), SOFA (r=0.43), and APACHE II (r=0.39; all $p < 0.001$). In multivariate analysis, TyG-BMI independently predicted ICU admission (aOR: 1.45, 95% CI: 1.19–1.77, $p < 0.001$) and MV (aOR: 1.52, 95% CI: 1.18–1.96, p=0.001). Adding TyG-BMI to sPESI improved reclassification for both ICU admission (NRI: 0.224, p=0.004) and MV (NRI: 0.196, p=0.012). Although SOFA and APACHE II remained superior overall, TyG-BMI was the strongest cardiometabolic predictor, significantly enhancing sPESI-based stratification as a complementary tool in the emergency setting.

Keywords: pulmonary embolism; TyG-BMI; mechanical ventilation

---

Ref No: 2670

Diagnosis of Ovarian Torsion in a Patient Presenting to the Emergency Department with Suspected Abdominal Gas Pain and Pharmacotherapeutic Evaluation of the Case

Nagihan DURMUS2, Sultan Tuna AKGOL GUR1, Muhammed Cengizhan DURMUS1

1Department of Emergency Medicine

2Faculty of Pharmacy

Nagihan DURMUS / Faculty of Pharmacy

Introduction and Purpose: In female patients presenting to the emergency department with abdominal pain, symptoms are often nonspecific and may be misinterpreted as gas pain, urinary tract infection, or gastrointestinal-related pain (1).It can particularly delay the diagnosis of gynecological emergencies such as ovarian torsion (2). Ovarian torsion is a surgical emergency resulting from the twisting of the ovarian vascular pedicle, which may lead to ischemic damage to ovarian tissue (3). The aim of this case report is to present the diagnosis of ovarian torsion in an unmarried female patient who presented to the emergency department with suspected gas pain and to evaluate the pharmacological treatment administered during this process from a pharmacotherapeutic perspective.

Materials and Methods: A 24-year-old unmarried female patient presented to the emergency department on 11.10.2024 with progressively worsening right lower quadrant pain and complaints suggestive of gas pain. Physical examination at admission revealed no significant abdominal guarding or rebound tenderness. At the initial evaluation, a preliminary diagnosis of R10 – Abdominal and Pelvic Pain was made, and symptomatic treatment was initiated, including 1000 mL of 0.9% sodium chloride isotonic solution, neoset 3 mg ampoule, and hyoscine-N-butylbromide 20 mg/mL injectable solution (6 ampoules). Additionally, imaging with contrast enhancement using KOPAQ 350/100 mL vial was performed. Due to worsening pain, pelvic ultrasonography revealed a cystic lesion approximately 4.25 cm in diameter in the right ovary with findings consistent with ovarian torsion (N83.2 – Other and Unspecified Ovarian Cysts). The patient underwent laparoscopic detorsion on 13.10.2024

Results and Conclusion: The agents used for symptomatic treatment during the patient's initial presentation to the emergency department were appropriate options for abdominal pain management and reduction of gastrointestinal spasms. Isotonic fluid therapy was suitable for ensuring adequate hydration, and the use of hyoscine-N-butylbromide in combination with analgesic therapy was consistent with the preliminary diagnosis of gas pain. The administration of KOPAQ (contrast agent) indicates that imaging decisions were appropriately guided by clinical findings. No known serious drug interactions or contraindications were identified for the medications used. This case highlights that early consideration of ovarian torsion in young female patients presenting with abdominal pain can accelerate the diagnostic and treatment process.

Keywords: Emergency department, Medication management, Ovarian torsion

---

Ref No: 2722

Mild Clinical Course After Intentional Co-ingestion of Castor Bean Seeds, Metoclopramide, and Melatonin: A Case Report

Ufuk Çağman1, Serhat Örün1, Efkan Anık1, Mahmut Can Çilesiz1
1Tekirdağ Namık Kemal University Emergency Medicine

Efkan Anık / Tekirdağ Namık Kemal University Emergency Medicine

Introduction and Purpose: Castor bean (Ricinus communis) seed ingestion is classically associated with ricin exposure and a potentially severe gastrointestinal toxidrome, yet clinical severity after oral ingestion is variable and may not correlate directly with the reported number of seeds. We aimed to present a case of intentional co-ingestion of castor bean seeds, metoclopramide, and melatonin that resulted in an unexpectedly mild clinical course despite a seemingly high-risk exposure.

Figure 1 Figure 2



Commercially sourced package of castor beans reportedly ingested by the patient; the number of remaining seeds was consistent with both the quantity reported by the patient and the total number indicated on the package.

Materials and Methods: A 32-year-old man was referred to our tertiary emergency department after a suicide attempt involving oral ingestion of 20 chewed castor bean seeds, 120 mg metoclopramide, and 45–60 mg melatonin approximately 30 minutes before presentation. Initial decontamination with gastric lavage and activated charcoal had already been performed at an outside center about 1 hour after ingestion. On arrival, he underwent detailed clinical evaluation, electrocardiographic monitoring, serial laboratory testing, poison center consultation, and psychiatric assessment, followed by close observation for 96 hours.

The seeds in the package were identified as Ricinus communis through comparison of their size, shape, and surface patterns with open-source references.

Table 1

	Admission	After 24 Hours	After 48 Hours		Admission	After 24 Hours	After 48 Hours
WBC (10^3u/L)	15.8	9.0	6.3	KREATİNİN (mg/dL)	1.2	1.0	0.8
HGB (g/dL)	17.1	13.6	14.6	ÜRE (mg/dL)	39.2	18.2	16.4
MCV (fL)	86.3	81.6	82.7	GFR (mL/dk)	73.5	97.9	104
PLT (10^3u/L)	332	244	286	NA+ (mmol/L)	134.0	135.0	136.4
pH* (log[H+]-)	7.33	7.35	7.34	CL- (mmol/L)	97.4	103.7	106.7
HCO3* (mmol/L)	17.6	18.2	17.8	CA++ (mg/dL)	9.6	8.7	8.6
pCO2* (mmHg)	33.0	37.0	36.8	K+ (mmol/L)	4.0	3.1	3.54
pO2* (mmHg)	17.1	18.8	18.1	ALT (IU/L)	20	21	24
Lac* (mmol/L)	2.7	1.7	1.4	AST (IU/L)	19.0	16.0	21
COHb* (%)	0.3	1.0	0.7	GGT (IU/L)	23.1	22.0	26
Anyon Gap* (mmol/L)	19.3	17.9	18.3	ALP (IU/L)	142.0	98.0	102.0
Baz Açığı* (mmol/L)	-8.9	-6.5	-6.2	AMİLAZ (U/L)	75.0	51.0	54
TROPONİN (ng/L)	4.1	4.9	3.8	LİPAZ (U/L)	33.7	180.9	57.8
CRP (mg/L)	6.5	24.9	12.9				

Laboratory findings on admission and during follow-up. * Venous blood gas.

Results and Conclusion: At presentation, the patient was hemodynamically stable except for sinus tachycardia (123 beats/min; QTc 453 ms). He reported nausea, vomiting, epigastric burning, and abdominal pain, but physical examination revealed no abdominal tenderness, guarding, rebound, neurologic deficit, or respiratory abnormality. Serial laboratory tests showed no major end-organ injury; follow-up remained notable mainly for mild metabolic disturbance and transient lipase elevation without clinical deterioration. During 96 hours of monitoring, no hemodynamic instability, major arrhythmia, significant neurologic toxicity, or severe gastrointestinal complication developed. The patient was discharged after psychiatric reassessment and outpatient follow-up planning. This case highlights that outcome after oral castor bean ingestion may depend more on effective toxin release, timing of presentation, and prompt gastrointestinal decontamination than on seed count alone. Careful risk stratification and short-interval reassessment should guide management in castor bean co-ingestion cases.

Keywords: Castor bean poisoning, Toxicology, Multidrug ingestion

Ref No: 2735

Psoas Abscess: A Case Report of a Patient Presenting with Fever and Hip Pain

İlyas Daşkıran[1], Davut Kaya[2]

[1]Malatya Turgut Özal Üniversitesi
[2]Malatya Eğitim Araştırma Hastansi

İlyas Daşkıran / Malatya Turgut Özal Üniversitesi

Introduction and Purpose: A psoas abscess is a rare infection that may lead to significant morbidity and mortality if diagnosis is delayed. Clinical findings are often nonspecific and may present as fever, low back pain, flank pain, groin pain, limited hip movement, and difficulty in walking. Therefore, diagnosis may be delayed, particularly in the emergency department. Current management recommends the combination of broad-spectrum antibiotic therapy with image-guided percutaneous drainage or, in selected cases, surgical drainage.In this case report, we present a patient who was admitted with fever, right flank pain, and difficulty in walking, diagnosed with a psoas abscess by computed tomography, and successfully treated with percutaneous drainage.

Materials and Methods: A 44-year-old male patient presented to the emergency department with a three-day history of fever, malaise, right flank pain, and pain radiating to the right hip. His medical history included type 2 diabetes mellitus and hypertension. He reported difficulty walking due to increasing pain over the past week, with a marked increase in pain especially when the right hip was extended. There was no history of trauma. He reported mild dysuria; however, there were no significant gastrointestinal complaints.At admission, vital signs were as follows: temperature 37.6°C, blood pressure 95/60 mmHg, heart rate 116 beats/min, respiratory rate 20 breaths/min, and oxygen saturation 97%. Physical examination revealed tenderness in the right flank and right lower abdominal quadrant. Pain increased with passive extension of the right hip, and examination findings suggestive of psoas irritation were noted. No neurological deficit was detected.

Results and Conclusion: Psoas abscess is a rare but clinically significant infection. Because it presents with nonspecific symptoms, diagnosis may be delayed. It should be considered in patients with fever, low back/flank pain, hip pain aggravated by movement, and elevated inflammatory markers. Early imaging, appropriate antibiotic therapy, and timely drainage can lead to successful clinical outcomes.

Keywords: psoas abscess, iliopsoas abscess, emergency department

Ref No: 2756

Ruptured ectopic pregnancy presenting with pelvic free fluid in a hemodynamically stable patient: a case mimicking appendicitis

Fadime ÖZYİĞİT GÖK[1], Demet ACAR[1], Emre GÖK[1], Mine Kayacı Yıldız[1], Mehmet Gül[1]

[1]Emergency Medicine Department,Konya City Hospital,Türkiye

Fadime ÖZYİĞİT GÖK / Emergency Medicine Department,Konya City Hospital,Türkiye

Introduction and Purpose:

Introduction and Aim: Ectopic pregnancy is one of the leading causes of maternal mortality in early pregnancy. Hemodynamic stability does not exclude rupture, and the clinical presentation may mimic surgical pathologies such as appendicitis. In this study, we present a case of ectopic pregnancy with a risk of rupture despite an apparently stable clinical condition.

Materials and Methods:

Case: A 28-year-old female presented to the emergency department with complaints of lower quadrant abdominal pain and vomiting for 12 hours. Vital signs were stable. Laboratory results revealed a β-hCG level of 1885 mIU/mL and a CRP level of 25 mg/L. Blood gas analysis showed a lactate level of 3.2 mmol/L and metabolic acidosis. Ultrasonography demonstrated no intrauterine gestational sac and the presence of pelvic free fluid. Contrast-enhanced abdominal CT revealed pelvic free fluid and pathology around the right ovary, while no findings suggestive of appendicitis were detected. Based on the clinical and imaging findings, a diagnosis of ruptured ectopic pregnancy was considered.

Results and Conclusion:

Discussion and Conclusion: In women of reproductive age presenting with lower quadrant pain, stable vital signs do not exclude rupture. The presence of pelvic free fluid and the absence of an intrauterine gestational sac are critical for the diagnosis of ectopic pregnancy. Early diagnosis plays a vital role in reducing mortality. Therefore, careful evaluation and close follow-up are essential in clinical practice.

Keywords: Ectopic pregnancy, Rupture, Differential diagnosis of appendicitis

Ref No: 2761

Evaluation Of The Demographic Characteristics And Laboratory Parameters Of Dialysis Patients

FURKAN KORKMAZ[1]
[1]Malatya Eğitim Ve Araştırma Hastanesi

FURKAN KORKMAZ / Malatya Eğitim Ve Araştırma Hastanesi

Introduction and Purpose: Aim:Patients with chronic kidney disease (CKD) receiving dialysis treatment frequently present to emergency departments due to various clinical conditions. This study aimed to evaluate the demographic characteristics and laboratory parameters of dialysis patients presenting to the emergency department and to investigate potential differences according to sex.

Materials and Methods: Materials and Methods:This retrospective study included patients with chronic kidney disease who presented to the emergency department between February 15, 2026, and March 15, 2026, and had received dialysis treatment at least once. During the study period, 31 patients were identified, and 23 patients who met the inclusion criteria were analyzed. Demographic data and laboratory parameters were obtained from the hospital's electronic medical record system. The normality of data distribution was assessed using the Shapiro–Wilk test. Variables with normal distribution were expressed as mean ± standard deviation, whereas non-normally distributed variables were presented as median (interquartile range, IQR). Comparisons according to sex were performed using the Independent Samples t-test or the Mann–Whitney U test.

Results and Conclusion: Results:Of the 23 patients included in the study, 11 (47.8%) were male and 12 (52.2%) were female. Albumin levels were found to be significantly higher in male patients compared to female patients (3.59 ± 0.43 g/dL vs. 3.04 ± 0.64 g/dL, $p = 0.026$). Hemoglobin levels were also higher in male patients ($p = 0.023$). In contrast, no statistically significant differences were observed between sexes in terms of age, CRP, neutrophil, amylase, lymphocyte, platelet, monocyte, creatinine, urea, potassium, and sodium levels ($p > 0.05$).Conclusion:It was demonstrated that albumin and hemoglobin levels were higher in male patients among dialysis patients presenting to the emergency department. Although albumin reference ranges in healthy individuals are generally considered to be independent of sex, it is suggested that higher albumin levels may be observed in male patients with chronic kidney disease undergoing dialysis. These findings need to be supported by studies conducted with larger patient cohorts.

Keywords: Chronic kidney disease, albumin, hemoglobin

Ref No: 2763

Invasive Rhino-Orbital-Cerebral Mucormycosis Presenting with Isolated Ocular Findings in an Immunocompetent Patient: A Case Report

Alanur Tarhan[1], Muradiye Kısmet[2], Cüneyt Arıkan[2]

[1]Department of Emergency Medicine, Dokuz Eylul University Hospital, Izmir, Türkiye
[2]Dokuz Eylul University Faculty of Medicine, Department of Emergency Medicine, Izmir, Türkiye

Muradiye Kısmet / Dokuz Eylul University Faculty of Medicine, Department of Emergency Medicine, Izmir, Türkiye

Introduction and Purpose: Mucormycosis is a rapidly progressive and often fatal invasive fungal infection caused by fungi of the order Mucorales. It is most commonly seen in immunosuppressed patients, particularly those with uncontrolled diabetes mellitus or malignancy. The rhino-orbital-cerebral form typically presents with fever, sinusitis findings, and necrotic nasal lesions. However, it is rare in immunocompetent individuals, and atypical presentations may delay diagnosis. We report a case of rhino-orbital-cerebral mucormycosis in a patient with no known comorbidities presenting with isolated ocular findings.

Materials and Methods: A 69-year-old male with no known chronic disease presented with left eyelid drooping and vision loss. He reported fever, headache, facial fullness, and nasal congestion for one week. Vital signs were stable. Examination revealed marked left-sided ptosis. Ophthalmologic evaluation showed lateral deviation, mydriasis, restricted inward and upward gaze, and absence of direct light reflex in the left eye. The right eye was normal, and no necrotic lesions were observed in the oral cavity or palate.Laboratory findings showed leukocytosis (WBC: 18,000) and elevated C-reactive protein (281mg/L). Cranial MRI demonstrated a contrast-enhancing lesion adjacent to the ethmoid sinus and diffusion restriction in the right temporal lobe. Paranasal CT revealed loss of aeration in the ethmoid and sphenoid sinuses. Cranio-orbital MRI showed increased enhancement in the left retrobulbar area and findings consistent with cerebritis. Following multidisciplinary evaluation, rapid progression with contralateral vision loss prompted urgent surgery. Intraoperative findings revealed extensive necrosis in the sphenoid sinus and surrounding tissues, and debridement was performed. Histopathology confirmed invasive mucormycosis. Despite antifungal therapy, intracranial involvement progressed, and the patient died on the seventh day of intensive care.

Figure 1

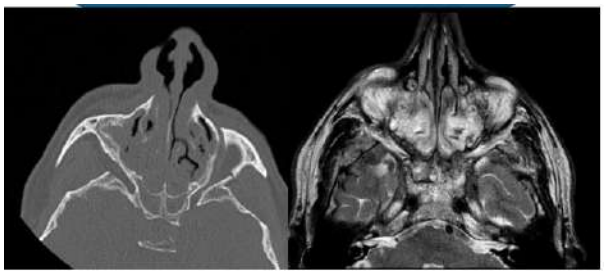

Figure 1. Paranasal sinus CT demonstrating loss of aeration in the paranasal sinuses and thinning of the bony structures of the sphenoid sinus (1). Contrast-enhanced brain MRI (T1-weighted) showing a hypointense area in the right temporal lobe suggestive of a purulent collection (2).

Figure 2

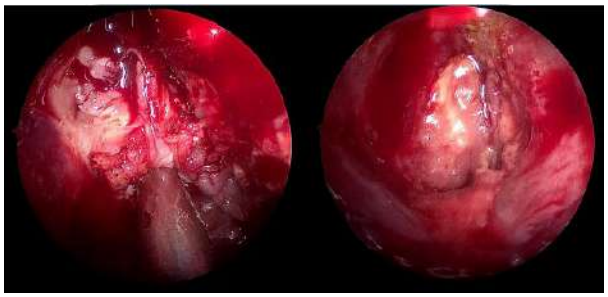

Figure 2 Intraoperative view showing inflamed ethmoid cells and necrotic mucosa of the sphenoid sinus.

Results and Conclusion: This case is notable for occurring in an immunocompetent patient and presenting initially with isolated ocular findings without nasal necrosis. In emergency practice, symptoms such as ptosis or vision loss are often attributed to neurological or vascular causes, which may delay consideration of invasive fungal infections. However, mucormycosis can rapidly cause vascular and intracranial complications due to its angioinvasive nature. Therefore, it should be included in the differential diagnosis of rapidly progressive ophthalmoplegia or vision loss, even in the absence of classical findings, and prompt imaging and surgical evaluation are essential.

Keywords: Mucormycosis, Ophthalmoplegia, Immunocompetent Patient

Ref No: 2770

Celiac artery syndrome presenting with recurrent pancreatitis: A rare case report

Dr. Enes Yılmaz[1], Dr. Şamil Emin Yalçın[1], Asst. Prof. Dr. Mevlana GÜL[1]

[1]Ataturk University Emergency Department

Dr. Şamil Emin Yalçın / Ataturk University Emergency Department

Introduction and Purpose: Celiac artery syndrome (CAS), also known as Median Arcuate Ligament Syndrome (MALS), is a rare clinical entity characterized by the compression of the celiac artery by the median arcuate ligament as it exits the abdominal aorta. This compression leads to a reduction or total obstruction of blood flow to the distal branches of the artery. While chronic postprandial abdominal pain and weight loss are common presentations, its manifestation as recurrent pancreatitis is extremely rare. The objective of this report is to present a unique case where recurrent acute pancreatitis attacks were triggered by celiac artery compression.

Materials and Methods: A 54-year-old male patient presented with postprandial epigastric pain. He had no history of systemic disease or prior surgery. Initial vital signs were stable: blood pressure 128/86 mmHg, pulse 87 bpm, and oxygen saturation 96%. Physical examination revealed tenderness in the epigastric region without defense or rebound. Laboratory investigations were performed to identify the etiology of the abdominal pain.

Results and Conclusion: Laboratory results showed significantly elevated levels: amylase 4824 U/L, lipase 6467 U/L, gamma-glutamyl transferase (GGT) 193 U/L, alanine aminotransferase (ALT) 518 U/L, aspartate aminotransferase (AST) 456 U/L, and lactate dehydrogenase (LDH) 528 U/L. Total bilirubin was 1.87 mg/dL. Initial imaging did not reveal a common etiology for pancreatitis (such as gallstones). However, detailed re-evaluation of CT scans identified significant compression of the celiac artery, confirming the diagnosis of CAS. Identifying and addressing the compression successfully resolved the patient's recurrent pancreatitis attacks.In conclusion, although pancreatitis is common, rare etiologies like CAS should be considered in patients where standard diagnostic workups are negative. Detailed vascular evaluation is crucial in recurrent cases of unknown origin.

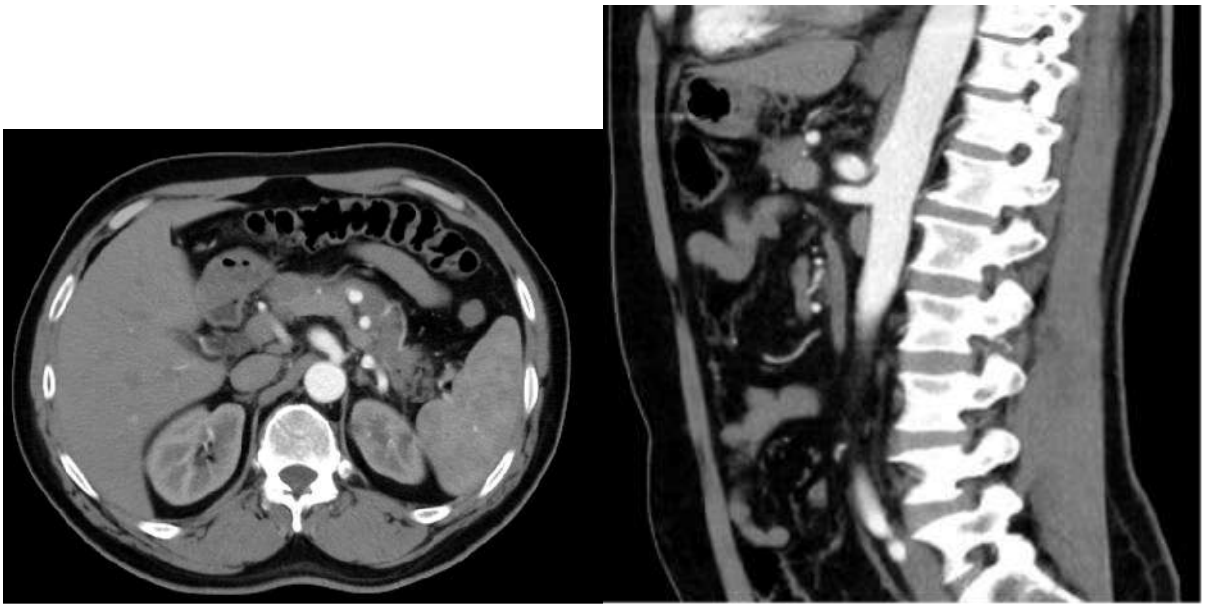

tomography1 tomography2



tomography3

Keywords: Celiac artery syndrome, Recurrent pancreatitis, Median arcuate ligament syndrome

Ref No: 2774

Atropine-Induced Delirium in Organophosphate Poisoning

Ekim Sağlam Gürmen[1], Deniz Şimşek[1]

[1]Manisa Celal Bayar University School of Medicine, Department of Emergency Medicine, Manisa, Turkey

Deniz Şimşek / Manisa Celal Bayar University School of Medicine, Department of Emergency Medicine, Manisa, Turkey

Introduction and Purpose: Delirium is an acute neuropsychiatric syndrome marked by sudden disturbances in consciousness, attention, and cognition. In the emergency department (ED), infections, metabolic disorders, and medications are common causes (1). Drugs with anticholinergic properties, such as atropine, carry a high risk of central nervous system effects (2,3). Atropine is essential in organophosphate poisoning treatment but may rarely cause central anticholinergic toxicity and delirium, which can mimic worsening poisoning and complicate management (4). This case highlights atropine-induced delirium, its differential diagnosis, and the importance of recognizing central adverse effects during therapy.

Materials and Methods: A 48-year-old male with suspected organophosphate exposure received atropine at 1 mg every 5 minutes (cumulative dose 50 mg) at an outside ED. Approximately 1.5 hours later, he developed acute agitation and altered mental status and was transferred to our ED. On admission, he was confused, GCS 12, vitals stable. Examination revealed chemical burns, warm dry skin, and mydriasis. Laboratory results, including ABG, CRP, WBC, pseudocholinesterase, and troponin, were unremarkable aside from neutrophilia. Other causes of delirium—hypoxia, sepsis, metabolic disturbances, ongoing organophosphate toxicity—were excluded. The temporal relationship with atropine administration and anticholinergic signs supported the diagnosis of atropine-induced delirium. The patient was admitted to the anesthesia ICU for close monitoring and supportive care.

Results and Conclusion: Anticholinergic delirium results from central muscarinic receptor blockade, presenting with agitation, confusion, mydriasis, and fluctuating consciousness (1,3). While atropine is lifesaving in organophosphate poisoning, high cumulative doses may trigger central toxicity (4). Rapid onset of delirium after atropine, coupled with exclusion of alternative causes, confirms the diagnosis (1,3). Unrecognized atropine-induced delirium may be mistaken for poisoning progression, potentially leading to harmful dose escalation. Management focuses on supportive care, dose reassessment, and, if necessary, short-term sedatives. Physostigmine may be considered in selected cases but carries risks (5).Atropine-induced delirium should be

considered in any patient with altered mental status during organophosphate poisoning treatment, even at therapeutic doses, to avoid mismanagement and ensure appropriate supportive care(4).

Keywords: Atropine, Delirium, Organophosphate poisoning

Ref No: 2779

Trauma in Pregnancy: A Retrospective Analysis of Emergency Department Presentations and Obstetric Outcomes

Mehmet Soyugüzel[1], Gülbanu Emrem[1]

[1]Afyonkarahisar Health Sciences University

Gülbanu Emrem / Afyonkarahisar Health Sciences University

Introduction and Purpose: Exposure to trauma during pregnancy is a situation frequently encountered in the emergency department (ED) that carries serious risks regarding maternal and fetal morbidity and mortality. The objective of this study is to retrospectively examine the demographic characteristics, trauma mechanisms, clinical management processes, and obstetric outcomes of pregnant patients presenting with trauma to the ED of a tertiary hospital.

Materials and Methods: For this retrospective and descriptive study, approval was obtained from the Non-Interventional Clinical Research Ethics Committee of Afyonkarahisar Health Sciences University, dated 06.02.2026 and numbered 2026/113. Within the scope of the study, forensic cases presenting to the ED between 01.01.2021 and 01.01.2026 were screened via the hospital automation system. Following the examination of approximately 7000 forensic cases, a total of 40 trauma cases identified as pregnant at the time of the incident were reached. After excluding 15 patients with missing file data or who refused medical treatment, 25 patients who fully met the inclusion criteria were included in the study (Figure 1). Data were analyzed using the IBM SPSS Statistics for Windows, Version 27.0 program.

Distribution of Forensic Cases Involving Pregnant Women

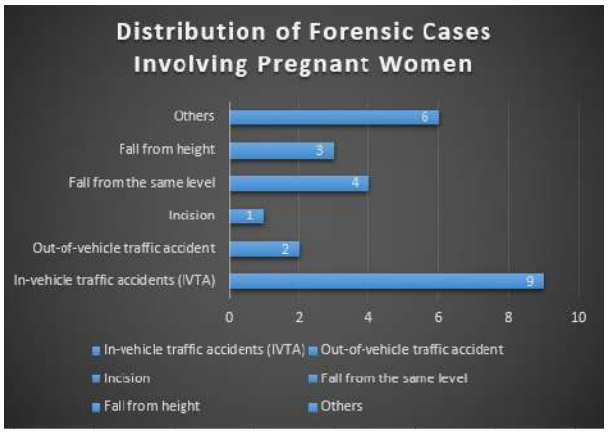

Trauma mechanism: 1: IVTA, 2: ADTK, 3: Incision, 4: İş kazası 5: Fall from the same level 6:Fall from height 7: Others

Demographic characteristics, trauma mechanisms, clinical management processes, and obstetric outcomes of pregnant patients presenting with trauma to the ED

Variables		
Age (Years)		
Mean ± Standard Deviation	29.88 ± 6.15	-
Median (Minimum - Maximum)	30.00 (21 - 44)	-
Gestational Age (Trimester)	n	%
1st Trimester (0-13 Weeks)	13	52.0
2nd Trimester (14-26 Weeks)	7	28.0
3rd Trimester (27+ Weeks)	5	20.0

Trauma Mechanism		
In-Vehicle Traffic Accident (IVTA)	8	32.0
Out-of-Vehicle Traffic Accident (OVTA)	3	12.0
Laceration / Cut	3	12.0
Occupational Accident	2	8.0
Fall from Same Level	3	12.0
Fall from Height	3	12.0
Other	3	12.0
Injured Body Region		
Extremity	8	32.0
Thorax	5	20.0
Head - Neck	4	16.0
Abdomen	4	16.0
External / Skin	1	4.0
Multiple Trauma	1	4.0
Unspecified / Other	2	8.0
Administered Treatment / Medication Use		
Supportive Fluid Therapy Only	23	92.0
None / Not Administered	2	8.0
Presentation Outcome		

(ED Outcome)		
Admission to Relevant Ward	12	48.0
Discharged	11	44.0
Intensive Care Unit (ICU) Admission	1	4.0
Referral to External Center	1	4.0
Death (Maternal Mortality)	0	0.0
Obstetric Outcomes		
Normal	25	100.0
Placental Abruption / PROM* / Fetal Loss	0	0.0

Results and Conclusion: The mean age of the 25 cases included in the study was 29.88 ± 6.15. It was observed that the ED presentations of the patients occurred most frequently in the first trimester (52.0%). The most common trauma mechanism encountered in the cases was in-vehicle traffic accidents (IVTA) (32.0%), and the most frequently injured body region was determined as the extremities (32.0%). In medical follow-up, 92.0% of the patients received supportive fluid therapy, and regarding the outcome, 48.0% were admitted to the relevant clinics, while 44.0% were discharged (Table 1). Obstetric outcomes were evaluated as normal in all of the examined cases (100.0%), and secondary fetal loss, placental abruption, or premature rupture of membranes were not observed.Unlike forensic series in the literature where assault and violence cases in pregnancy are prominent, IVTA stands out as the most common etiological factor in our general pregnant trauma population. In conclusion, systematic evaluation, close monitoring, and a multidisciplinary approach in the process from triage to discharge are of vital importance for maternal and fetal survival in pregnant trauma patients.

Keywords: Pregnancy, trauma, traffic accidents

Ref No: 2791

Heat stroke associated multiple organ dysfunction syndrome and disseminated intravascular coagulation: a case report

Elif Yeşim Gündaş[1], Muhammed Hamdi Uyar[1], Ahmet Melih Savaş[1], Ozan Deniz Keleş[1], Selçuk Eren Çanakçı[1]

[1]Department of Emergency Medicine, Faculty of Medicine, Aydın Adnan Menderes University, Aydın, Turkey

Ozan Deniz Keleş / Department of Emergency Medicine, Faculty of Medicine, Aydın Adnan Menderes University, Aydın, Turkey

Introduction and Purpose: Heat stroke is a life-threatening condition characterized by a core body temperature above 40°C accompanied by central nervous system dysfunction. Severe cases may progress to systemic inflammatory response, rhabdomyolysis, disseminated intravascular coagulation (DIC), and multiple organ dysfunction syndrome (MODS). Early recognition and aggressive supportive management are essential to prevent mortality and long-term neurological damage. We aimed to present a severe case of heat stroke complicated by MODS and DIC requiring intensive care management.

Materials and Methods: A 56-year-old male with no known comorbidities presented to the emergency department after working under direct sunlight for approximately four hours at a construction site. He developed vomiting followed by syncope and was brought to the hospital by ambulance. On admission he was tachycardic (156 bpm), tachypneic (36/min), and hyperthermic with a core body temperature of 40°C. His Glasgow Coma Scale score was 5 and oxygen saturation was 78%, requiring endotracheal intubation for airway protection. Initial laboratory evaluation revealed leukocytosis, thrombocytopenia, elevated liver enzymes, and markedly increased creatine kinase and myoglobin levels suggesting rhabdomyolysis. Brain imaging revealed no acute pathology.

Results and Conclusion: The patient was diagnosed with severe heat stroke complicated by rhabdomyolysis, disseminated intravascular coagulation, and multiple organ dysfunction syndrome. Intensive care management included aggressive fluid resuscitation, temperature control, mechanical ventilation, and supportive treatment including blood products. During follow-up, laboratory abnormalities gradually improved and neurological status recovered. The patient was successfully extubated and discharged after complete neurological recovery. This case highlights that heat stroke may rapidly progress to life-threatening systemic complications. Early recognition, rapid cooling, and multidisciplinary management are crucial for favorable outcomes.

Emergency care timeline of the patient from initial presentation to discharge

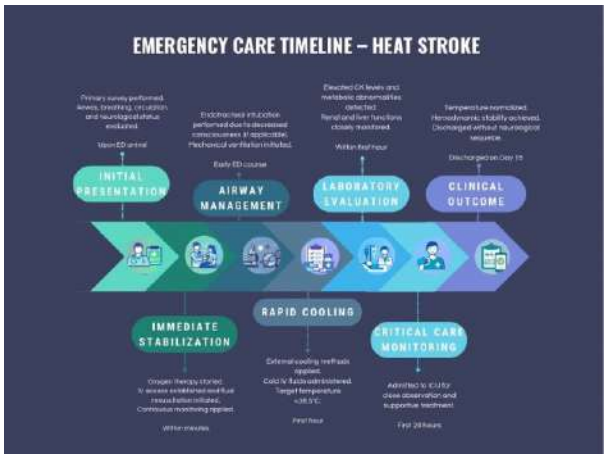

Keywords: Heat stroke, Multiple organ dysfunction syndrome, Rhabdomyolysis

---

Ref No: 2792

Neutrophil-to-Lymphocyte Ratio as a Prognostic Marker in Acute Exacerbation of COPD

Burcu Yormaz[1]

[1]. Selcuk University Medicine Faculty Department of Chest Disease,Konya,Turkıye

Burcu Yormaz / . Selcuk University Medicine Faculty Department of Chest Disease,Konya,Turkıye

Introduction and Purpose: Acute exacerbations of chronic obstructive pulmonary disease (AECOPD) are a major cause of hospitalization and mortality worldwide. Early identification of high-risk patients is essential for optimizing treatment strategies. The neutrophil-to-lymphocyte ratio (NLR), derived from routine blood tests, has emerged as a potential inflammatory biomarker. This study aims to evaluate the prognostic value of NLR in patients presenting with AECOPD.

Materials and Methods: A comprehensive review of clinical studies investigating NLR in AECOPD was conducted. Data regarding associations between NLR levels and clinical outcomes, including hospitalization duration, need for intensive care, mechanical ventilation, and

mortality, were analyzed. The relationship between NLR and other inflammatory markers such as CRP and procalcitonin was also assessed.

Results and Conclusion: Elevated NLR values were consistently associated with more severe disease, prolonged hospital stay, increased need for intensive care, and higher mortality rates. NLR was found to correlate with systemic inflammation and disease burden. Compared to other biomarkers, NLR is inexpensive, widely available, and rapidly obtainable.In conclusion, NLR represents a practical and effective biomarker for risk stratification in AECOPD. Its integration into routine clinical assessment may facilitate early identification of high-risk patients and improve clinical outcomes

Keywords: COPD; Exacerbation; Neutrophil-to-Lymphocyte Ratio

Ref No: 2891

Halp score as an early predictor of disease severity in ileus patients presenting to the emergency department

Elif Yaren Gundogdu1, Ayse Isik Guven1, Basar Cander1, Bahadır Taslidere1

1BEZMIALEM VAKIF UNIVERSITY

Elif Yaren Gundogdu / BEZMIALEM VAKIF UNIVERSITY

Introduction and Purpose: Abdominal pain is one of the most common reasons for emergency department visits, and ileus represents a frequent but clinically challenging condition where early risk stratification is often difficult. Identifying patients who may require surgery or prolonged hospitalization at presentation remains a key issue. The hemoglobin, albumin, lymphocyte, and platelet (HALP) score combines inflammatory and nutritional parameters and may provide a practical tool for early assessment. This study aimed to evaluate the role of HALP score in predicting disease severity and clinical outcomes in ileus patients.

Materials and Methods: This retrospective single-center study included 216 adult patients diagnosed with ileus between January 2019 and December 2024. Demographic characteristics, treatment modalities, tumor presence, and laboratory parameters were recorded. HALP score was calculated from initial laboratory values. Its relationship with surgical intervention, malignancy, length of hospital stay, and mortality was analyzed. Correlation analysis with neutrophil-to-lymphocyte ratio (NLR) was also performed.

Results and Conclusion: Of the patients, 36.6% required surgical treatment, while 63.4% were managed conservatively. HALP scores were significantly lower in patients undergoing surgery (p=0.009) and in those with malignancy (p=0.010). A statistically significant negative correlation was found between HALP score and length of hospital stay (p=0.026). No association was observed between HALP score and mortality (p=0.952). HALP score also showed a strong inverse correlation with NLR ($p < 0.001$). These findings suggest that HALP score reflects disease severity rather than mortality risk and may support early risk stratification in emergency practice.

Keywords: Ileus, HALP score, risk stratification

Ref No: 2912

Comparison of Lipid Profiles in Diabetic and Non-Diabetic Patients

Turgut Dolanbay[1], Ömer Serdar Mamur[1]
[1]Malatya Turgut Özal Üniversitesi
Ömer Serdar Mamur / Malatya Turgut Özal Üniversitesi

Introduction and Purpose: Objective: This study aimed to compare lipid profile parameters between diabetic and non-diabetic patients and to evaluate the effects of diabetes on lipid metabolism.

Materials and Methods: Materials and Methods: This is a retrospective and descriptive study including a total of 31 patients from an existing dataset. The patients were divided into two groups based on the presence of diabetes mellitus: diabetic and non-diabetic patients. Laboratory analyses evaluated total cholesterol, LDL-C, HDL-C, and triglyceride levels, while TG/HDL and LDL/HDL ratios were calculated for a more detailed assessment of atherogenic risk.

Results and Conclusion: Results: No statistically significant differences were observed between diabetic and non-diabetic patients regarding total cholesterol ($p = 0.184$), LDL cholesterol ($p = 0.212$), HDL cholesterol ($p = 0.098$), and triglyceride ($p = 0.071$) levels. However, upon evaluating atherogenic indices, the TG/HDL ratio was found to be significantly higher in diabetic patients ($p = 0.041$). The LDL/HDL ratio did not show a statistically significant difference between the groups ($p = 0.089$).Conclusion: Although statistical significance was not achieved in the majority of classical lipid parameters, atherogenic changes are observed in the lipid profiles of diabetic patients. In particular, the significantly higher TG/HDL ratio highlights the importance of this index as a key indicator of diabetic dyslipidemia and increased cardiovascular risk.

Keywords: Diabetes Mellitus, Lipid Profile, Atherogenic Index

Ref No: 2948

Complete Atrioventricular Block Accompanying İnferior Myocardial İnfarction: A Case Report

Ahmet Muhammet Şahingeri[1], Birsen Ertekin[1], İlknur Şahin[1], Muhammet Gökhan Turtay[1], Berra Kalkavan Doğan[1], Müslime Kasa[1]

[1]University of Health Sciences Beyhekim Training and Research Hospital, Clinic of Emergency Medicine, Konya, Türkiye.

Muhammet Gökhan Turtay / University of Health Sciences Beyhekim Training and Research Hospital, Clinic of Emergency Medicine, Konya, Türkiye.

Introduction and Purpose: In this case report, we present a patient with complete atrioventricular block secondary to inferior myocardial infarction on the background of multivessel coronary artery disease.

Materials and Methods: A 67-year-old male patient with a history of diabetes mellitus was brought to the emergency department by emergency medical services after experiencing syncope. His vital signs on presentation were temperature 36.9°C, blood pressure 50/30 mmHg, pulse 40/minute, respiratory rate 16/minute, and oxygen saturation 95%. He was conscious, oriented, and cooperative. His fingerstick blood glucose was 650 mg/dL. Electrocardiography revealed bradycardia, ST elevation in leads II, III, and aVF, and third-degree atrioventricular complete block. The patient was taken to the resuscitation room and an external pacemaker (30 mV, 90 bpm) was applied, with the voltage gradually increased. A total of 1.5 mg of atropine was administered. After pacing, his blood pressure rose to 120/70 mmHg and his pulse rate to 90/min. Laboratory tests showed hs-troponin 201 ng/L, creatine kinase-MB 13.9 U/L, creatinine 1.5 mg/dL, and potassium 5.1 mmol/L. Following cardiology consultation, the patient was admitted to the coronary care unit. During coronary angiography, the patient experienced multiple episodes of ventricular tachycardia, and recurrent cardioversion was performed. Coronary angiography revealed 80% stenosis in the proximal left anterior descending artery, 100% occlusion in the post-D1 segment, 90% stenosis in the proximal OM1 branch of the circumflex artery, a long segment lesion of 95% in the proximal right coronary artery, and 100% thrombosis in the right coronary artery posterior descending branch. Stents were placed in the proximal RCA and the branches. A temporary pacemaker was inserted. The patient was followed for 4 days in the intensive care unit and 3 days in the ward. The patient, who did not develop malignant arrhythmia, was discharged in good health.

Figure 1. ECG taken at the time of application

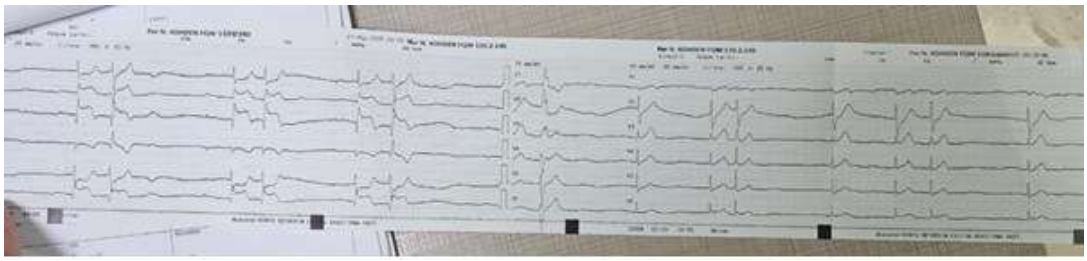

Results and Conclusion: It should be remembered that rapid diagnosis of conduction disorders and myocardial infarction associated with right coronary artery occlusion, and especially early reperfusion therapy, will reduce mortality rates.

Keywords: Complete atrioventricular block, External pacemaker, Inferior myocardial infarction

---

Ref No: 2952

Hematocrit and LDL Cholesterol Relationship At High Altitude: Early Cardiovascular Risk Phenotype In Young Men

FETHİ AHMET ATILGAN[1], FERİD GOJAYEV[2], FATİH OĞUR[3]

[1]ELAZIĞ FETHİ SEKİN ŞEHİR HASTANESİ ACİL TIP KLİNİĞİ
[2]İSTANBUL KOŞUYOLU YÜKSEK İHTİSAS EĞİTİM VE ARAŞTIRMA HASTANESİ
[3]ŞIRNAK ŞEHİT TÜMGENERAL AYDOĞAN AYDIN DEVLET HASTANESİ

FETHİ AHMET ATILGAN / ELAZIĞ FETHİ SEKİN ŞEHİR HASTANESİ ACİL TIP KLİNİĞİ

Introduction and Purpose: Hematocrit and LDL Cholesterol Relationship At High Altitude: Early Cardiovascular Risk Phenotype In Young Men.The aim of this study was to evaluate the relationship between hematocrit levels and lipid profile in young male individuals living at high altitude and to investigate whether the coexistence of altitude-dependent erythrocytosis and atherogenic lipid profile constitutes a potential cardiovascular risk phenotype.

Materials and Methods: This study was planned as a retrospective and cross-sectional study analyzing laboratory data obtained during routine clinical practice.The study was conducted in Şırnak Province, located in southeastern Turkey and situated approximately 1400 meters above

sea level.The study population consisted of 200 male individuals aged 30–45 years who had been living at high altitude for at least one year. Known cardiovascular disease, chronic kidney disease, chronic liver disease, active infection, and the presence of secondary causes of erythrocytosis were considered exclusion criteria. Additionally, female individuals were excluded from the study to eliminate gender-dependent physiological variability in hematological and lipid parameters and to obtain a homogeneous study population.The study covers the period from January 2025 to March 2026.

Results and Conclusion: The mean hemoglobin level was 16.88 ± 0.99 g/dL and the mean hematocrit level was 49.8 ± 2.76%. The mean LDL cholesterol level was 120.7 ± 29.4 mg/dL.In 74% of participants, hematocrit was found to be ≥49%, while in 77.5%, LDL cholesterol was ≥100 mg/dL. The percentage of individuals with LDL ≥130 mg/dL was 37.5%. Both high hematocrit and high LDL cholesterol were observed in 59% of participants.When participants were divided into two groups based on their hematocrit levels and compared, it was found that the high hematocrit group had a significantly higher red blood cell count. No statistically significant difference was found between the groups in terms of LDL cholesterol levels. When the relationship between hematocrit and LDL cholesterol levels was evaluated using scatter plot analysis, no significant linear correlation was found.However, the high prevalence of high hematocrit and high LDL cholesterol together indicates that these two parameters can frequently coexist in the same individuals. This finding suggests that hematological and metabolic cardiovascular risk factors may tend to cluster in young individuals living at high altitudes.

Keywords: altitude, erythrocytosis, LDL

Ref No: 2965

Approach to "Simple" Trauma in the Emergency Department: Intracranial Injury Detected Following Wire Penetration

Can Karakoç1, Melih Yüksel1, Mehmet Oğuzhan Ay1, Yeşim İşler1, Umut Ocak1, Halil Kaya1

1University of Health Sciences, Bursa Yuksek Ihtisas Training and Research Hospital, Department of Emergency Medicine, Bursa/Türkiye

Can Karakoç / University of Health Sciences, Bursa Yuksek Ihtisas Training and Research Hospital, Department of Emergency Medicine, Bursa/Türkiye

Introduction and Purpose: Although minor head traumas are frequent among emergency department visits, penetrating injuries caused by occupational accidents require special attention. Particularly, flying fragments (projectile objects) during metal cutting carry significant kinetic

energy due to their high velocity, despite having a small mass. This presentation reports a case of a patient who was clinically stable but radiologically diagnosed with a parietal fracture and contusion caused by a metal fragment that flew off while cutting wire at the workplace.

Materials and Methods: A 19-year-old male patient presented to the emergency department on foot with the complaint of being struck in the head by a snapped piece of wire that flew off while he was cutting metal wire at his workplace. The patient did not report any loss of consciousness, vomiting, or seizures at the time of the incident. The patient's general condition was good, and he was evaluated as conscious, oriented, and cooperative (GCS: 15). The neurological examination revealed no motor or sensory deficits, nor any cranial nerve pathology. Scalp examination showed a penetrating entry hole of approximately 1 cm in diameter, with irregular borders and no active bleeding, in the left parietal region.Because the injury was caused by a high-velocity object and had a penetrating nature, a non-contrast Brain Computed Tomography (CT) was performed. CT Findings: A minimally displaced fracture line was detected in the left parietal bone (Figure 1), along with a minimal contusion area in the brain parenchyma (at the cortical level) immediately adjacent to this line (Figure 2). No epidural or subdural hematoma was observed. The patient was consulted with the neurosurgery clinic. A prophylactic tetanus vaccine was administered, and broad-spectrum antibiotic therapy (Ceftriaxone) was initiated to prevent the risk of intracranial infection. The patient was admitted to the neurosurgery clinic.

Figure 1

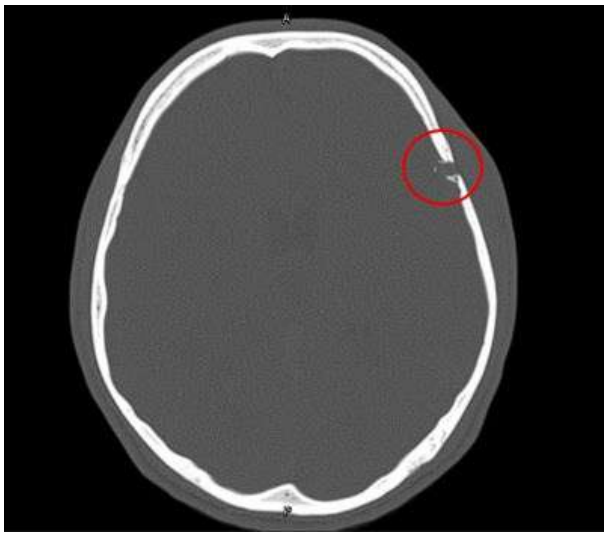

A minimally displaced fracture line was detected in the left parietal bone

Figure 2

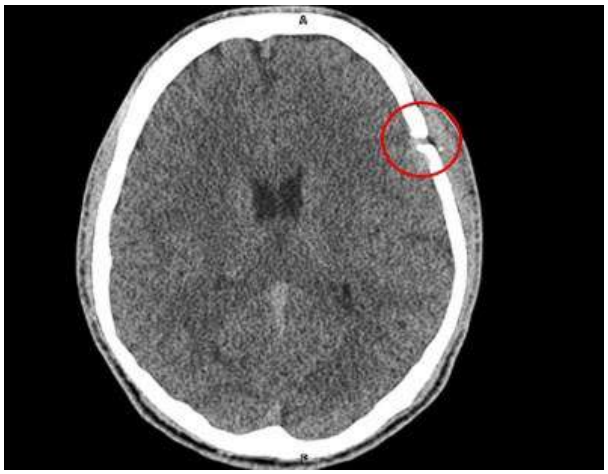

Minimal contusion in the left parietal area.

Results and Conclusion: Therefore, in patients with a history of a high-velocity flying fragment, the threshold for cranial imaging should be kept low, even if the GCS is 15. This approach is critical in preventing overlooked intracranial infections and late-stage neurological sequelae.

Keywords: Emergency Department, Head Trauma, Parietal Fracture

Ref No: 3019

Evaluation of Emergency Department Triage in a Tertiary Hospital Over the Years

Mehmet Sezer1, Nur Kaplan Demir2

1Malatya Turgut Özal Üniversitesi
2Battalgazi İlçe Sağlık Müdürlüğü

Mehmet Sezer / Malatya Turgut Özal Üniversitesi

Introduction and Purpose: Triage systems are vital in emergency departments to prevent delays in patient care and efficiently distribute the increasing workload. In Türkiye, the number of emergency department admissions is constantly increasing, affecting all aspects of emergency department service delivery and triage practices. To compare emergency department triage characteristics, patient flow, and hospitalization rates in a tertiary referral hospital between 2024 and 2025.

Materials and Methods: A retrospective review was conducted for all emergency department admissions to Malatya Training and Research Hospital between January-December 2024 and January-December 2025. Data on total admissions, repeat admissions, ambulance arrivals, triage categories, observation rates, and hospitalization rates were analyzed and compared across years.

Results and Conclusion: A total of 902,347 patients presented to the emergency department in 2024, compared to 899,585 in 2025, indicating a relatively stable annual patient volume. However, repeat visits decreased from 7,912 to 6,271, suggesting improved patient management or follow-up strategies. The number of patients transported by ambulance services (112) remained unchanged at 38,778 in both years.A marked shift in triage distribution was observed. Green zone admissions increased substantially from 83,007 in 2024 to 421,841 in 2025, whereas yellow zone admissions decreased from 805,331 to 463,531. In parallel, hospitalizations increased from 23,187 to 25,071 patients.Monthly average comparisons demonstrated statistically significant differences between the two years. Hospitalizations increased from 1,932.3 to 2,089.3 (p=0.002), ambulance arrivals from 1,231.1 to 1,782.8 (p=0.017), and total patient numbers from 58,288.2 to 59,755.5 (p=0.046). Observation admissions decreased significantly from 33,167.0 to 29,888.7 (p=0.012). Green zone admissions increased markedly (6,917.3 vs. 35,153.4, $p < 0.001$), while yellow zone admissions decreased significantly (67,110.9 vs. 38,627.6, $p < 0.001$).Region-based evaluation revealed mean patient numbers of 21,035.3 ± 14,951.7 for the green zone, 52,869.3 ± 15,952.2 for the yellow zone, and 1,175.9 ± 95.3 for the red zone.Overall, these findings indicate a notable shift in patient distribution without a major change in total volume. The increase in green zone admissions, along with reduced repeat visits and increased hospitalization rates, suggests improved triage accuracy and clinical decision-making. However, the persistently low hospitalization rate (approximately 2%) in both years highlights a substantial burden of non-urgent emergency department utilization.—

Table-1

Table-1

Değişken	2024 ort.	2025 ort.	p
Yatış	1932.3	2089.3	0.017
112	1231.1	1782.8	0.012
Gözlem	33167.0	29888.7	0.046

Toplam	58288.2	59755.5	
Yeşil	6917.3	35153.4	<0.001
Sarı	67110.9	38627.6	<0.001

Temporal Trends in Emergency Department Patient Volumes

Keywords: Emergency department, Hospitalization, Triage

Ref No: 3036

Cold Agglutinin Disease-Related Hemolytic Anemia and Associated Hepatobiliary Dysfunction in the Emergency Department

Muhammet Emin Uzun[1], Ensar Topaloğlu[1], Gürkan Altuntaş[1]

[1]Recep Tayyip Erdoğan University Training and Research Hospital, Department of Emergency Medicine, Rize, Türkiye

Muhammet Emin Uzun / Recep Tayyip Erdoğan University Training and Research Hospital, Department of Emergency Medicine, Rize, Türkiye

Introduction and Purpose: Cold agglutinin disease (CAD) and cold agglutinin syndrome (CAS) are rare forms of autoimmune hemolytic anemia characterized by complement-mediated hemolysis triggered by cold exposure. Patients frequently present with nonspecific symptoms, which may delay diagnosis, particularly in the emergency department. Laboratory inconsistencies such as hemoglobin–hematocrit discordance and erythrocyte agglutination may provide important diagnostic clues. This report presents a case of cold agglutinin–related hemolytic anemia associated with hepatobiliary dysfunction following prolonged cold exposure.

Materials and Methods: A 61-year-old woman presented to the emergency department with bilateral leg pain and cramps, right upper quadrant abdominal pain, and dyspnea. Her medical history included diabetes mellitus, hypertension, and chronic obstructive pulmonary disease. Symptoms developed after an approximately 18-hour bus journey from a warm to a colder region, during which the patient experienced significant cold exposure. Physical examination revealed mild jaundice and right upper quadrant tenderness. Initial laboratory findings showed hemoglobin–hematocrit inconsistency, markedly elevated mean corpuscular hemoglobin concentration, leukocytosis, increased lactate dehydrogenase, and hyperbilirubinemia

accompanied by elevated hepatobiliary enzymes. Reanalysis of the blood sample after warming at 37°C corrected the hematologic discrepancies. Peripheral blood smear demonstrated erythrocyte agglutination, supporting the diagnosis of cold agglutinin disease.

Figure 1

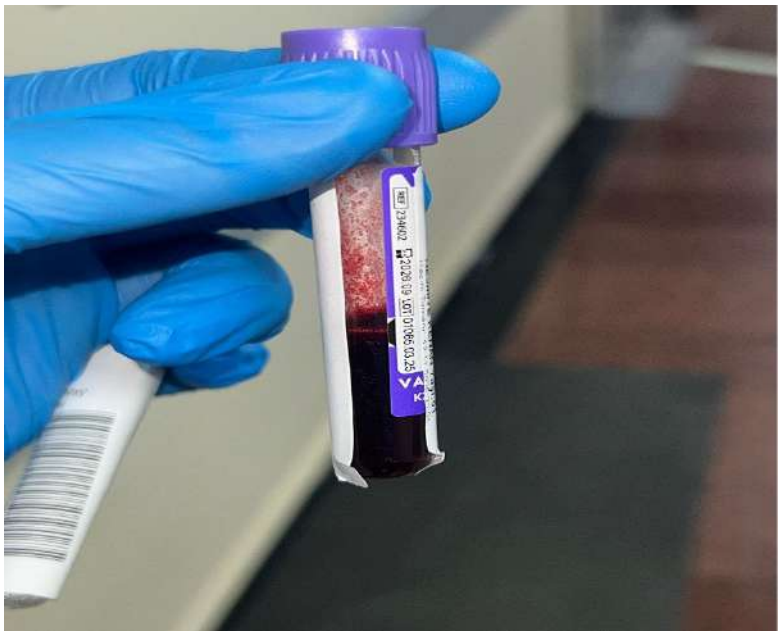

Erythrocyte agglutination in a hemogram tube

Results and Conclusion: This case demonstrates that cold agglutinin–related hemolytic anemia may present with atypical symptoms and multisystem involvement, including hepatobiliary enzyme elevation. Recognition of laboratory inconsistencies and a history of cold exposure are essential for early diagnosis. Considering CAD in patients presenting with hemolysis and unexplained biochemical abnormalities in the emergency department may prevent diagnostic delay and facilitate appropriate management.

Keywords: cold agglutinin disease, autoimmune hemolytic anemia, hepatobiliary dysfunction

Ref No: 3051

Hepatic Portal Venous Gas (PVG) due to Alkaline Corrosive Agent Ingestion in a Patient with Prior Sleeve Gastrectomy: A Case Report of an Uncommon Presentation

Zeynab Haidara[1], İsa Kılıçaslan[1], Lamiya Aliyeva[1], Saliha Betül Çakır[1]

[1]Gazi University Faculty of Medicine

İsa Kılıçaslan / Gazi University Faculty of Medicine

Introduction and Purpose: Hepatic portal venous gas (PVG) is a radiologic finding frequently associated with severe intra-abdominal pathology such as bowel ischemia; however, it may also reflect less severe, non-surgical conditions.This report describes a case of PVG following accidental ingestion of an alkaline household cleaning agent (sodium percarbonate) in a patient with a history of sleeve gastrectomy. This case demonstrates an atypical, non-surgical etiology of PVG and underscores the importance of an evidence-based approach to evaluation and management.

Materials and Methods: A 36-year-old woman presented to the emergency department with hematemesis after accidental ingestion of approximately 50 mL of an alkaline household cleaning agent (sodium percarbonate), which was mistaken for water. Clinical assessment comprised physical examination, laboratory analysis, and contrast-enhanced computed tomography (CT) to evaluate for complications including perforation or ischemia.



Figure 1



Figure 2

Figure 3 A



Figure 3 B



Results and Conclusion: The patient experienced recurrent hematemesis following ingestion. Computed tomography revealed hepatic portal venous gas within the portal venous system, consistent with mucosal injury. No evidence of perforation, free air, or free fluid was observed. The patient remained hemodynamically stable, with normal lactate levels and absence of peritoneal signs. In the absence of clinical or radiologic indicators of severe pathology, conservative management was pursued. The patient's clinical course was uneventful, and recovery was achieved without complications.This case demonstrates that PVG, although frequently associated with serious abdominal pathology, may also result from less severe causes such as caustic ingestion. Recognition of these atypical etiologies broadens the differential diagnosis and enables management of PVG based on patient stability and comprehensive assessment. Integration of clinical, laboratory, and imaging findings can prevent unnecessary interventions and facilitate optimal outcomes in non-surgical PVG cases.

Keywords: alkaline corrosive caustic ingestion, portal venous gas, sleeve gastrectomy

Ref No: 3052

Serum Surfactant Protein-D And Stratifin For Early Risk Stratification in Adults Presenting to The Emergency Department With Acute Dyspnea: A Prospective Cohort Study

Serhat Örün[1], Ufuk Çağman[1], Alperen Ermiş[1], Murat Balkaya[1], Abdullah Talha Demirel[1], Türkan Kurulday[1], Mahmut Can Çilesiz[1], Aliye Çelikkol[2], Mehmet Ali Payam[2]

[1]Tekirdağ Namık Kemal University Department of Emergency Medicine
[2]Tekirdağ Namık Kemal University Department of Medical Biochemistry

Ufuk Çağman / Tekirdağ Namık Kemal University Department of Emergency Medicine

Introduction and Purpose: Dyspnea is a common and etiologically heterogeneous presentation in emergency departments (ED) and is associated with significant short-term morbidity and mortality. Identification of biomarkers that reflect early clinical severity may support risk stratification in this population. Surfactant protein-D (SP-D) and stratifin (14-3-3σ, SFN) are biomarkers that have been associated with lung injury and inflammatory responses; however, their prognostic value in unselected ED patients presenting with acute dyspnea remains unclear.

Materials and Methods: This prospective cohort study included adult patients presenting with acute dyspnea to a tertiary-care ED. Serum SP-D and stratifin levels were measured at ED admission using enzyme-linked immunosorbent assay (ELISA). Clinical outcomes were defined as hospital admission, intensive care unit admission, and in-hospital mortality. The control group consisted of age- and sex-matched ED patients without dyspnea. Associations between biomarker levels and clinical outcomes were evaluated using univariable analyses and univariable logistic regression.

Results and Conclusion: A total of 107 patients were included (65 patients with dyspnea and 42 controls). Serum SP-D and stratifin levels differed significantly between the dyspnea group and controls ($p < 0.05$). In univariable analyses, lower SP-D levels and higher stratifin levels were associated with adverse clinical outcomes. Univariable logistic regression analyses demonstrated associations between biomarker levels and in-hospital mortality; no covariate adjustment was performed.. In ROC analyses, CRP (AUC 0.862) and stratifin (AUC 0.811) demonstrated good discriminative performance for mortality, whereas SP-D did not (AUC 0.401).

Figure 1

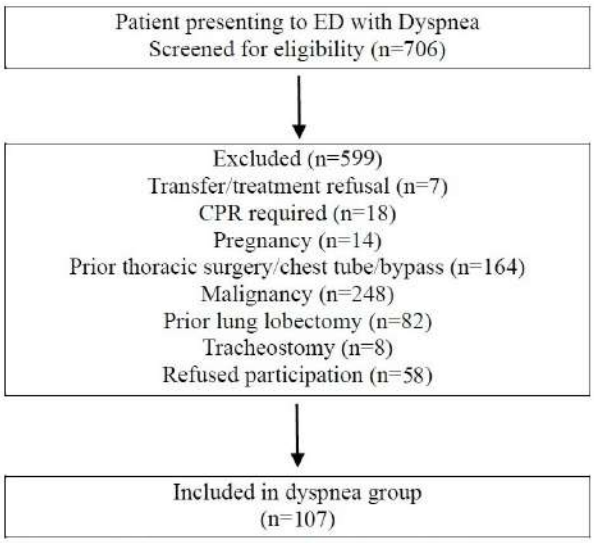

Figure 1. Patient screening and enrollment flowchart.

Patient screening and enrollment flowchart.

Table 1: Demographic characteristics and body mass index distribution

	Case group (n=65)	Control group (n=42)	p value
Sex			
Female	30 (46.2%)	27 (64.3%)	0.07
Male	35 (53.8%)	15 (35.7%)	
Age	72.46 ± 11.39	69.94 ± 9.9	0.19
BMI			
Normal weight	26(40%)	13(31%)	
Overweight	21(32.3%)	19(45.2%)	0.63
Obese	18 (27.7%)	10(23.8)	

BMI: Body mass index, Values are presented as n (%) or mean ± standard deviation.

Table 2: Thoracic computed tomography findings among patients presenting with dyspnea in the case group.

CT findings	n(%)
Increased cardiothoracic ratio	23 (35.4%)
Consolidation	19 (29.2%)
Effusion	18 (27.7%)
Ground-glass opacity	16 (24.6%)
Emphysema	8 (12.3%)
Pulmonary embolism	6 (9.2%)
Bronchiectasis	6 (9.2%)
Atelectasis	5 (7.7%)
Pulmonary edema	3 (4,6%)
Interstitial fibrosis	2 (3.1%)

CT; computed tomography

Table 3: Comparison of laboratory parameters between case and control groups

	Case group (n=65)	Control group (n=42)	p value
SP-D ng/ml	18.78 ± 3.15	77.76 ± 12.88	<0.001
Stratifin ng/ml	192.31 ± 31.05	78.15 ± 12.96	<0.001
WBC 10^3/uL	11.46 ± 5.48	7.71 ± 2.42	<0.001
Neutrophil 10^3/uL	8.97 ± 5.27	5.19 ± 2.38	<0.001
Lymphocyte 10^3/uL	1.57 ± 1.30	1.80 ± 0.86	0.322
Eosinophil	0.13 ± 0.14	0.14 ± 0.09	0.822
Hb g/dL	12.28 ± 2.06	12.16 ± 1.37	0.741
Htc %	37.85 ± 6.67	35.42 ± 4.03	0.022
Plt 10^3/uL	248061 ± 96181	269975 ± 73378	0.215
CRP mg/L	67.95 ± 76.09	22.92 ± 48.45	<0.001
ALT IU/L	23.45 ± 25.92	37.77 ± 75.60	0.279
AST IU/L	30.62 ± 22.36	30.96 ± 40.69	0.958
Troponin ng/L	74.37 ± 306.01	11.66 ± 7.68	0.292
Creatinine mg/dl	1.20 ± 0.91	0.94 ± 0.34	0.086
Urea mg/dl	55.04 ± 29.96	44.13 ± 21.22	0.031

pH log [H+]-	7.32 ± 0.056	7.38 ± 0.007	0.675
pO2 mmHg	63.64 ± 14.87	68.32 ± 8.40	0.493
pCO2 mmHg	38.96 ± 12.58	33.44 ± 8.71	0.342
HCO3 mmol/L	25.12 ± 3.27	23.50 ± 4.95	0.124
Lactate mmol/L	2.07 ± 1.18	1.63 ± 0.63	0.057

SP-D; surfactant protein-D, WBC; white blood cell, Hb; hemoglobin, Htc; hematocrit, Plt; platelet count, CRP; C-reactive protein, ALT; alanine aminotransferase, AST; aspartate aminotransferase.

Table 4: Association of serum SP-D and stratifin levels with clinical outcomes

	SP-D (mean ± SD)	p value	Stratifin (mean ± SD)	p value
Ward admission				
No	50.86 ± 31.13	0,003	129 ± 61	0.002
Yes	30.18 ± 24.90		174 ± 54	
ICU admission				
No	45.69 ± 30.9	<0,001	140 ± 62	0.008
Yes	24.53 ± 18.41		177 ± 48	
In-hospital mortality				
No	21.00 ± 3,89	<0,001	214 ± 37	0.004
Yes	43.18 ± 30,54		143 ± 60	

SP-D; surfactant protein-D, ICU; intensive care unit.

Table 5: Univariable logistic regression analyses for in-hospital mortality

Variable	Mortality OR (95% CI)	p value
Age	1.09 (0.99–1.19)	0.094
CRP	1.015 (1.006–1.025)	0.002
SP-D	0.95 (0.89–1.02)	0.177
Stratifin	1.03 (1.00–1.05)	0.022

Univariable logistic regression analyses were performed to evaluate associations with in-hospital mortality. Multivariable modeling was not conducted due to the limited number of mortality events in order to avoid model overfitting. Odds ratios (ORs) are presented with 95% confidence intervals (CIs). OR; odds ratio, CI; confidence interval, CRP; C-reactive protein, SP-D; surfactant protein-D.

Keywords: Surfactant protein-D, Stratifin, Dyspnea

Ref No: 3072

Sex-Based Differences in Carboxyhemoglobin Levels, Venous Blood Gas Parameters, and Hematologic Indices in Acute Carbon Monoxide Poisoning

Emre Oğur[1]

[1]Malatya Turgut Özal University, Faculty of Medicine, Department of Emergency Medicine

Emre Oğur / Malatya Turgut Özal University, Faculty of Medicine, Department of Emergency Medicine

Introduction and Purpose: Carbon monoxide (CO) poisoning remains one of the leading causes of unintentional poisoning deaths worldwide. Although its pathophysiology is well characterized, sex-specific variations in clinical and laboratory manifestations and their implications for diagnosis and prognosis remain insufficiently investigated.To characterize sex-based differences in carboxyhemoglobin (COHb) levels, venous blood gas parameters, and hematologic biomarkers among patients diagnosed with acute CO poisoning.

Materials and Methods: This retrospective study included adult patients with isolated CO poisoning who presented to the emergency department between March 2025 and February 2026. Statistical analyses were performed using SPSS Statistics 27. Parametric variables are expressed as mean ± standard deviation (SD); non-parametric variables as median (IQR). Between-sex comparisons of parametric variables were conducted using the independent samples t-test; non-parametric variables were analyzed using the Mann–Whitney U test. Spearman's rank-order correlation coefficient was used to assess associations among non-parametric variables.

Results and Conclusion: A total of 32 patients were included in the study: 17 males and 15 females. The mean age was 48 years. All patients were discharged alive. COHb and hemoglobin levels were significantly higher in males than in females (p=0.024 and p=0.02, respectively). In contrast, venous PO_2, platelet count, and lymphocyte count were significantly elevated in females (p=0.005, p=0.004, and p=0.05, respectively). Moderate, statistically significant negative correlations were observed between age and both albumin ($r=-0.574$, $p < 0.001$) and lymphocyte count ($r=-0.473$, p=0.006). A strong positive correlation was found between lymphocyte and monocyte counts ($r=0.635$, $p < 0.001$).Sex significantly influences key laboratory parameters including COHb, venous PO_2, and hematologic indices in acute CO poisoning. These findings underscore the need to establish sex-specific reference thresholds for diagnostic and prognostic assessment. Moreover, they provide a robust foundation for future prospective studies aimed at refining risk stratification and personalized management strategies.

Keywords: carbon monoxide poisoning, sex differences, carboxyhemoglobin

---

Ref No: 3100

Demographic and clinical characteristics of patients with carbon monoxide intoxication in the emergency department

Mehmet SOYUGÜZEL[1], Sebahattin AKYOL[1]

[1]Afyonkarahisar Health Sciences University Faculty of Medicine Department of Emergency Medicine

Sebahattin AKYOL / Afyonkarahisar Health Sciences University Faculty of Medicine Department of Emergency Medicine

Introduction and Purpose: Carbon monoxide (CO) is an odorless, tasteless, and colorless gas causing life-threatening intoxications. Because initial clinical symptoms—such as headache, dizziness, and nausea—are highly non-specific, CO poisoning frequently mimics other disorders. The primary toxic mechanism involves the gas rapidly binding to hemoglobin to form carboxyhemoglobin (COHb), significantly decreasing the oxygen-carrying capacity of the blood and causing severe tissue hypoxia. Establishing a diagnosis requires a high index of suspicion, careful epidemiological evaluation, and thorough clinical examination. This study aims to evaluate the demographic characteristics, etiologies, clinical presentations, laboratory findings, and outcomes of patients admitted to the emergency department with acute CO intoxication.

Materials and Methods: A total of 37 patients admitted to the emergency department with acute CO poisoning were included in this study. Patient demographics, mode of arrival, comorbidities, etiologies, presenting complaints, laboratory parameters, and clinical outcomes were analyzed retrospectively. All examined variables are summarized in Table 1.

Demographic, clinical, and laboratory characteristics of patients with carbon monoxide intoxication

Variables	**Values**
Age (Years), Mean ± SD	37.00 ± 23.40
Gender, n (%)	
Male	18 (48.6)
Female	19 (51.4)
Mode of Arrival, n (%)	
Ambulance	24 (64.9)
Other (Self-presentation, etc.)	13 (35.1)
Type of Poisoning, n (%)	
Stove/Heater	17 (45.9)
Fire	7 (18.9)
Other	13 (35.1)
Comorbidities, n (%)	
None	32 (86.5)
Diabetes Mellitus (DM)	1 (2.7)
Other	4 (10.8)
Presenting Complaints, n (%)	
Headache	7 (18.9)
Nausea	6 (16.2)
Dyspnea	5 (13.5)
Syncope	8 (21.6)
Dizziness	8 (21.6)
Seizure/Contraction	1 (2.7)
Cough	1 (2.7)
Laboratory Parameters, Mean ±	

SD	
Blood Glucose	122.54 ± 32.46
Lactate*	20.61 ± 15.25
Platelet (Plt)	286.65 ± 105.68
ALT	18.32 ± 9.49
Sodium (Na)	138.73 ± 2.29
Length of Stay in Emergency Dept. (Hours), Mean ± SD	10.65 ± 6.11
Outcome, n (%)	
Discharge	21 (56.8)
Referral	3 (8.1)
Refusal of Treatment	10 (27.0)
Other	3 (8.1)

Results and Conclusion: The mean age of the population was 37.00 ± 23.40 years, with 19 (51.4%) females. The majority arrived via ambulance (64.9%) and had no known comorbidities (86.5%). The primary etiology of poisoning was stove or heater use (45.9%), followed by fire exposure (18.9%). The most frequent presenting complaints were syncope (21.6%), dizziness (21.6%), headache (18.9%), and nausea (16.2%). Mean initial laboratory values included a lactate level of 20.61 ± 15.25 mmol/L and blood glucose of 122.54 ± 32.46 mg/dL. The mean length of stay in the emergency department was 10.65 ± 6.11 hours. Ultimately, 21 patients (56.8%) were safely discharged, 3 (8.1%) required referral to another facility, and 10 (27.0%) refused treatment.Acute CO intoxication frequently presents with non-specific neurological symptoms, predominantly linked to domestic heating sources in this cohort. Although the majority of patients are successfully treated and discharged, the notably high rate of treatment refusal highlights an urgent need to increase public awareness regarding the potentially delayed, life-threatening risks of CO poisoning and the necessity of completing medical observation.

Keywords: Carbon monoxide, Emergency Department, Carboxyhemoglobin

Ref No: 3151

Pediatric oropharyngeal penetrating injury caused by a kitchen mixer attachment: a case report

Mehmet Okay[1], Ramazan Köylü[1], Harun Sandal[1], Ayla Mollaoğlu[1], Mehmet Gül[1]

[1]Emergency Medicine Department, Konya City Hospital, Türkiye

Mehmet Okay / Emergency Medicine Department, Konya City Hospital, Türkiye

Introduction and Purpose: Oropharyngeal trauma in the pediatric population typically occurs secondary to falls with objects such as pens, toothbrushes, or toy parts in the mouth. However, penetrating injuries caused by objects with complex geometries, such as kitchen utensils, are rarely reported in the literature, and their management carries a high risk due to the proximity of vital anatomical structures. In this report, we aim to present the surgical management of a 3-year-old patient with a transfixing (full-thickness) soft palate injury caused by a kitchen mixer attachment, along with a comparative analysis of similar pediatric traumas in the literature.

Materials and Methods: A 3-year-old female patient was brought to our emergency department following an injury sustained when a mixer attachment entered her mouth while she was playing with it. Clinical examination revealed that the metal spiral attachment had entered through the inner aspect of the buccal mucosa, perforated the soft palate, and extended toward the nasopharynx. The patient was taken to the operating room for a minor surgical procedure under general anesthesia. To minimize tissue damage, the spiral-shaped foreign body was removed en bloc utilizing rotational maneuvers. The patient experienced no postoperative complications and was discharged with appropriate recommendations.

Results and Conclusion: Although midline injuries in oropharyngeal penetrating trauma carry a lower vascular risk compared to lateral wall injuries (which pose a risk to the carotid artery), the geometry of the object is the primary determinant of the surgical technique. Similar cases in the literature emphasize that extracting spiral objects with direct linear traction can dramatically exacerbate tissue lacerations. The "atraumatic vectorial extraction" technique employed in this case played a critical role in preventing iatrogenic trauma. In the context of childhood domestic accidents, kitchen utensils can act not only as sharp objects but also as sources of complex penetrating and lacerating trauma. In such cases, following the securing of the airway, surgical maneuvers tailored to the object's geometry and a multidisciplinary approach are essential for an uncomplicated recovery.

Keywords: Pediatric trauma, Oropharyngeal injury, Home accidents

Ref No: 3172

The Effect of Electrolyte Disorders on Mortality and Hospital Stay in Patients Presenting to the Emergency Department with Acute Exacerbation of COPD

Cem Doğan[1], Muhammed Ekmekyapar[1]

[1]Department of Emergency Medicine, Elazığ Fethi Sekin City Hospital, Elazığ, Türkiye

Muhammed Ekmekyapar / Department of Emergency Medicine, Elazığ Fethi Sekin City Hospital, Elazığ, Türkiye

Introduction and Purpose: Chronic Obstructive Pulmonary Disease (COPD) is a condition characterised by chronic respiratory symptoms and abnormalities in the airways (bronchitis, bronchiolitis, alveolar emphysema), which frequently leads to progressive airway obstruction. COPD exacerbations constitute the leading cause of mortality and hospital admissions among COPD patients. This study investigated the effects of electrolyte disturbances on mortality and length of hospital stay in patients with COPD exacerbations.

Materials and Methods: The patients' age, gender, vital signs (temperature, pulse, blood pressure, oxygen saturation), comorbid conditions, haematological parameters (complete blood count, biochemistry, CRP, blood gas, lactate, etc.), inflammation parameters and radiological imaging were examined. Biochemical parameters including glucose, BUN, creatinine, uric acid, albumin and electrolyte levels were recorded. Patients' admission status to the ward or intensive care unit and length of stay were recorded. Mortality rates among hospitalised patients were analysed.

Results and Conclusion: A total of 328 patients were included in the study. Of the patients, who had a mean age of 71.5 ± 9.8 years, 91 were women and 237 were men. There were 21 (6.4%) patients with mortality. The mean age of patients with mortality was higher, and their intensive care and total hospitalisation durations were longer, whilst their ward stay duration was shorter. In terms of laboratory values, the haemoglobin and albumin levels were lower in the group with mortality, whilst glucose, urea and phosphorus levels were higher. When patients were divided into three groups based on electrolyte levels (low, normal and high) and evaluated, significant differences in mortality were observed between the groups for sodium, potassium, chloride and phosphorus levels, whereas no significant differences were found for magnesium and calcium levels. When patients were divided into three groups based on low, normal and high electrolyte levels and assessed in terms of length of hospital stay, a significant difference was found between the groups for chloride and phosphorus levels, whereas no significant difference was found for sodium, potassium, calcium and magnesium levels. In patients with acute

exacerbations of COPD, electrolyte imbalances influence the length of hospital stay and mortality rates.

Table-1: Comparison of patients' lengths of stay and vital signs

	Total (n=328)	No mortality (n=307)	Mortality (n=21)	p
Number of days spent in the ward, median (min–max)	8 (0-51)	8 (0-36)	0 (0-51)	**<0,001**
Number of days spent in intensive care, median (min–max)	0 (0-127)	0 (0-127)	10 (0-115)	**<0,001**
Total length of stay, median (min-max)	11 (1-127)	10 (1-127)	16 (2-123)	**0,025**
Systolic blood pressure, median (min-max)	130 (90-200)	135 (90-200)	110 (95-160)	**<0,001**
Diastolic blood pressure, median (min-max)	80 (50-130)	80 (50-120)	65 (50-130)	**<0,001**
Body temperature, median (min-max)	36,4 (36-38,6)	36,4 (36-38,6)	36,7 (36-37,9)	**0,046**
Pulse rate, median (min-max)	96 (42-150)	95 (42-147)	119 (71-150)	**<0,001**
SO2 ± SD	70,8 ± 9,7	71,2 ± 9,6	64,5 ± 9,2	**0,002**

Table-2: Comparison of groups by serum sodium level

	Hyponatraemia (n=38)	Eunatraemia (n=284)	Hypernatraemia (n=6)	p
Mortality				
None, n (%)	33 (86,8)	270 (95,1)#	4 (66,7)#	**0,004**
Present, n (%)	5 (13,2)	14 (4,9)#	2 (33,3)#	
Length of stay in the ward, median (min–max)	7 (0-28)	8 (0-51) #	0 (0-8) #	**0,001**
Length of stay in intensive care, median (min–max)	5 (0-127) #	0 (0-115) #^	15 (0-70)^	**<0,001**

Total length of stay, median (min–max)	11(3-127)	10 (1-123)	15 (8-70)	0,293

#^ It shows which groups in the current row show a significant difference

Table-3: Comparison of groups according to serum potassium levels

	Hypokalaemia (n=11)	Normokalaemia (n=301)	Hyperkalaemia (n=16)	p
Mortality				
None, n (%)	8 (72,7) #	285 (94,7) #	14 (87,5)	**0,008**
Present, n (%)	3 (27,3) #	16 (5,3) #	2 (12,5)	
Length of stay in the ward, median (min–max)	8,1 ± 9,2	9,1 ± 7,1	6,2 ± 7	0,277
Length of stay in intensive care, median (min–max)	9,5 ± 14,9	4,4 ± 12,4	8,1 ± 4,5	0,214
Total length of stay, median (min–max)	17,6 ± 14	13,5 ± 14	14,3 ± 8,4	0,601

It shows which groups in the current row show a significant difference

Table-4: Comparison of groups according to blood chloride levels

	Hypochloremia (n=72)	Normochloremia (n=228)	Hyperchloremia (n=28)	p
Mortality				
None, n (%)	63 (87,5) #	218 (95,6) #	26 (92,9)	**0,049**
Present, n (%)	9 (12,5) #	10 (4,4) #	2 (7,1)	
Length of stay in the ward, median (min–max)	7 (0-36)	8 (0-51)	8 (0-26)	0,401
Length of stay in intensive care, median (min–max)	6 (0-127) #^	0 (0-115) #	0 (0-11) ^	**<0,001**
Total length of stay, median (min–max)	12 (3-127) #	10 (1-123) #	10 (2-26)	**0.025**

#^ It shows which groups in the current row show a significant difference

Table-5: Comparison of groups according to serum phosphorus levels

	Hypophosphataemia (n=22)	Normophosphataemia (n=270)	Hyperphosphataemia (n=36)	p
Mortality				
None, n (%)	22 (100)	256 (94,8) #	29 (80,6) #	**0,002**
Present, n(%)	0 (0)	14 (5,2) #	7 (19,4) #	
Length of stay in the ward, median (min–max)	10 (0-33)	8 (0-51)	6 (0-36)	0,144
Length of stay in intensive care, median (min–max)	0 (0-23) #	0 (0-72) ^	9 (0-127) #^	**<0,001**
Total length of stay, median (min–max)	11 (2-36)	10 (1-123) #	14 (3-127) #	**0,026**

#^ It shows which groups in the current row show a significant difference

Keywords: COPD, electrolyte imbalances, mortality

Ref No: 3205

Predictive Value of Appendiceal Diameter for Perforation in Acute Appendicitis

MEHMET YAŞAR[1], FATMA TORTUM[1]

[1]ATATURK UNIVERSITY

MEHMET YAŞAR / ATATURK UNIVERSITY

Introduction and Purpose: This study aimed to evaluate the relationship between appendiceal diameter and the risk of perforation in patients with acute appendicitis and to determine whether appendiceal diameter can serve as a predictive factor for perforation.

Materials and Methods: This prospective observational study was conducted in the emergency department of a tertiary care hospital between February 1, 2026, and April 1, 2026. Adult patients (≥18 years) diagnosed with acute appendicitis were consecutively enrolled. Patients with incomplete data were excluded. Perforation status was determined based on intraoperative findings and/or radiological evaluation. Patients were divided into two groups according to the presence or absence of perforation.Statistical analyses were performed using IBM SPSS Statistics (IBM Corp., Armonk, NY, USA). Continuous variables were expressed as mean ± standard deviation or median (interquartile range), and categorical variables as frequencies and percentages. Normality was assessed using the Kolmogorov–Smirnov test. Group comparisons were performed using the Independent Samples t-test or Mann–Whitney U test, as appropriate. Categorical variables were compared using the Chi-square or Fisher's exact test. Logistic regression analysis was used to evaluate the association between appendiceal diameter and the risk of perforation. A p-value < 0.05 was considered statistically significant.

Demographic and Clinical Characteristics of the Patients (N=43)

Variables	Value (n=43)
Age (Years), Mean ± SD (Range)	31.16 ± 12.71 (19 - 61)
Gender, n (%)	
Female	25 (58.1%)
Male	18 (41.9%)
Imaging Modality, n (%)	
Computed Tomography (CT)	32 (74.4%)
Ultrasonography (USG)	11 (25.6%)
Appendix Diameter (mm), Mean ± SD (Range)	9.56 ± 3.46 (5.0 - 24.0)
Complications, n (%)	
Absent	40 (93.0%)
Present (Perforation)	3 (7.0%)

Results and Conclusion: A total of 43 patients were included in the study. Of these, 3 patients (7.0%) had perforated appendicitis, while 40 patients (93.0%) had non-perforated appendicitis (Table 1). The appendiceal diameter was significantly higher in patients with perforation than in those without (p = 0.031, Mann–Whitney U test) (Table 2). Univariate logistic regression analysis demonstrated that appendiceal diameter was significantly associated with perforation risk (OR: 1.50, 95% CI: 1.00–2.24, p = 0.049) (Table 3). Each 1 mm increase in appendiceal diameter was associated with a 1.5-fold increase in the likelihood of perforation. Overall, the logistic regression model was statistically significant (p = 0.007), indicating that appendiceal diameter is a meaningful predictor of perforation in patients with acute appendicitis.Appendiceal diameter is significantly associated with perforation risk in acute appendicitis. Increased

diameter may serve as a simple and useful predictor for identifying patients at higher risk of perforation.

Comparison of Appendix Diameter and Age Based on Complication Status

Variables	Complications Absent (n=40)	Complications Present (n=3)	p-value
Appendix Diameter (mm)	8.91 ± 2.38	15.66 ± 7.37	**0.031***
Age (Years)	31.52 ± 12.87	25.33 ± 13.05	0.435

Multivariate Logistic Regression Analysis for Predictors of Perforation

Variable	Odds Ratio (OR)	95% Confidence Interval (CI)	p-value
Appendiceal diameter (per 1 mm increase)	1.50	1.00 – 2.24	0.049

Keywords: Appendiceal Diameter, Acute Appendicitis, Perforation

---

Ref No: 3227

Relationship Between Hemogram and Biochemical Parameters and Hospital Length of Stay in Lung Cancer Patients Evaluated in the Emergency Department

Korkut Dolanbay[1]

[1]Malatya Turgut Özal University

Korkut Dolanbay / Malatya Turgut Özal University

Introduction and Purpose: This study aimed to investigate the relationship between the demographic characteristics, hemogram, and biochemical parameters of patients with lung cancer presenting to the emergency department and their length of hospital stay.

Materials and Methods: This study was designed retrospectively. Patients aged over 18 years with a diagnosis of lung cancer who presented to the emergency department within the last month were included. Patients with incomplete data were excluded. The data were statistically analyzed, and the relationships between hematological and biochemical parameters and clinical outcomes were evaluated.

Results and Conclusion: Results:Of the patients, 63.6% were male and 36.4% were female, with a mean age of 67.4 ± 12.1 years. No statistically significant association was found between sex and age, laboratory parameters, or length of hospital stay. However, a moderate negative correlation was observed between neutrophil levels and length of hospital stay. No significant relationships were identified between other biochemical and hematological parameters and clinical outcomes.Conclusion:The evaluation of hematological and biochemical parameters in patients with lung cancer presenting to the emergency department may provide insight into the clinical course. In particular, neutrophil levels are associated with the length of hospital stay. This finding suggests that the inflammatory response may play an important role in disease prognosis. Further studies with larger sample sizes are needed.

Keywords: lung cancer; emergency department; hemogram

Ref No: 3230

The Diagnostic Challenge of Metabolic Disturbances: Thiazide-Induced Hyponatremia as a Stroke Mimic

AHMET CELAL ÖZSOY[1]

[1]University of Health Sciences, Sanliurfa Mehmet Akif Inan Training and Research Hospital, Department of Emergency Medicine

AHMET CELAL ÖZSOY / University of Health Sciences, Sanliurfa Mehmet Akif Inan Training and Research Hospital, Department of Emergency Medicine

Introduction and Purpose: AbstractBackground: Acute ischemic stroke requires rapid intervention, yet "stroke mimics" account for approximately 22% to 45.75% of emergency evaluations. Hyponatremia, the most prevalent electrolyte abnormality in acute care, is a significant metabolic cause of these mimics. Thiazide-induced hyponatremia (TIH) is a common pharmacological trigger that can manifest as focal neurological deficits (FNDs), including hemiparesis and aphasia, precisely mirroring a large vessel occlusion.

Materials and Methods: Case Presentation: A 62-year-old female with a history of hypertension treated with thiazide diuretics presented via "Stroke Code" with sudden onset right-sided hemiparesis and motor aphasia. Clinical evaluation showed an NIHSS score of 14. While neuroimaging ruled out acute hemorrhage and large vessel occlusion, laboratory results identified severe hypotonic hyponatremia (Sodium: 114 mmol/L). The patient was treated with a

controlled 3% hypertonic saline infusion. Within four hours, her sodium levels reached 120 mmol/L, resulting in the complete resolution of all neurological deficits (NIHSS 0).

Results and Conclusion: Conclusion: Severe hyponatremia can accurately mimic the clinical presentation of an acute ischemic stroke. This case emphasizes the critical importance of early metabolic screening within "Stroke Code" protocols. Distinguishing metabolic disturbances from vascular events is essential to avoid unnecessary thrombolytic interventions and to implement targeted treatments, such as controlled sodium correction, to prevent complications like osmotic demyelination syndrome.

Keywords: Thiazide-induced hyponatremia, Stroke mimic, Focal neurological deficits

---

Ref No: 3243

Traumatic Gallbladder Perforation Following Blunt Abdominal Trauma: A Rare but Fatal Complication

Ekim Sağlam Gürmen[1], Mustafa Deveci[1]

[1]Manisa Celal Bayar Üniversitesi Tıp Fakültesi, Acil Tıp Anabilim Dalı, Manisa, Türkiye

Mustafa Deveci / Manisa Celal Bayar Üniversitesi Tıp Fakültesi, Acil Tıp Anabilim Dalı, Manisa, Türkiye

Introduction and Purpose: Motor vehicle collisions are among the most common causes of emergency department admissions and may present with a wide clinical spectrum ranging from minor injuries to severe trauma requiring urgent surgery (1). In patients with multiple trauma, certain intra-abdominal injuries may be overlooked during the initial assessment due to competing priorities. In abdominal trauma, the liver and spleen are the most frequently injured organs(2).Traumatic gallbladder perforation is extremely rare; however, when it occurs, early diagnosis is crucial because it may lead to serious complications such as biliary peritonitis and sepsis(3).

Materials and Methods: A 76-year-old male with chronic kidney disease on hemodialysis, hypertension, and coronary artery disease was brought to the emergency department one hour after a motor vehicle collision. He was conscious and cooperative; blood pressure was75/45 mmHg, heart rate 90 beats/min, and SpO_2 98%. Abdominal examination revealed right upper quadrant tenderness without peritoneal signs.Venous blood gas showed lactate 6.9mmol/L, consistent with metabolic acidosis. Serial hemograms demonstrated a decrease in hemoglobin

(11.8 g/dL to 9.3 g/dL) and leukocytosis. Elevated AST and ALT were attributed to blunt hepatic injury.Thoracic CT revealed a manubrium sterni fracture, multiple rib fractures, and minimal bilateral pneumothorax. Contrast-enhanced abdominal CT demonstrated gallbladder wall disruption with displacement of gallstones and intraluminal contents outside the gallbladder fossa. Grade 2 hepatic contusions and free intra-abdominal fluid were also present, consistent with traumatic gallbladder perforation.Emergency exploratory laparotomy and cholecystectomy were performed. Intraoperatively, he developed hemodynamic instability requiring inotropic support and erythrocyte transfusion. In the ICU, metabolic acidosis and elevated lactate persisted despite broad-spectrum antibiotics. His condition deteriorated, leading to cardiac arrest and death despite advanced life support.

Results and Conclusion: Traumatic gallbladder injuries account for approximately 1.9–2.1%of blunt abdominal trauma cases and may be diagnosed late due to their rarity (5). Clinical findings are often subtle, and contrast-enhanced CT is the primary diagnostic modality(6). Indirect signs such as pericholecystic fluid, wall contour disruption, and intraluminal high-density material should raise suspicion(6).When perforation is suspected, surgical exploration and cholecystectomy are generally recommended(3).This case emphasizes that rare gallbladder injuries should be considered in trauma patients and that early imaging plays a vital role in diagnosis and management

Keywords: Biliary peritonitis, Blunt abdominal trauma, Gallbladder perforation

---

Ref No: 3324

The effect of NSAID use on emergency department visits with decompensated heart failure

Kevser Simbil[1], Behcet Al[1], Turab Sami Altay[1], Halil Emre Bilgic[1]

[1]Istanbul Medeniyet University

Kevser Simbil / Istanbul Medeniyet University

Introduction and Purpose: Objective:This study aimed to evaluate the association between recent nonsteroidal anti-inflammatory drug (NSAID) use and clinical presentation and in-hospital outcomes among patients presenting to the emergency department with acute decompensated heart failure

Materials and Methods: This prospective, single-center, observational study was conducted between October 20, 2023, and May 21, 2025, in the Emergency Medicine Department of a University Hospital. A total of 400 patients diagnosed with decompensated heart failure were included. For statistical analyses, differences between patients who used NSAIDs and those who did not were compared using Pearson's Chi-Square Test, while Fisher's Exact Test was applied when appropriate.

Results and Conclusion: Results: Among the 400 participants, 54.3% were female, and 54.0% were aged ≥80 years. NSAID use within the preceding 10 days was observed in 27.8% of patients. A substantial proportion of patients presented with advanced heart failure, with the majority classified as NYHA Class III or IV, and 44.0% required intensive care unit admission during hospitalization.NSAID use was more frequently observed among older patients and in those presenting with clinical features such as hypertension and tachypnea. However, no consistent or statistically significant associations were identified between recent NSAID exposure and in-hospital mortality or intensive care unit admission. These findings should be interpreted in the context of the study's observational design and the presence of multiple clinical confounders.Conclusion:Recent NSAID use was common among patients presenting to the emergency department with acute decompensated heart failure. In this cohort, NSAID exposure was not clearly associated with differences in in-hospital outcomes, and further analyses adjusting for clinical confounders are warranted.

Keywords: Heart Failure, Emergency Department, NSAID

Ref No: 3351

Halp Score As A Clinical Decision-Making Tool For Surgical Intervention In Ileus Patients

Elif Betül Balci[1], Ayse Isik Guven[1], Basar Cander[1], Bahadır Taslidere[1]

[1]Bezmialem Vakıf University

Elif Betül Balci / Bezmialem Vakıf University

Introduction and Purpose: In patients presenting to the emergency department with ileus, determining the need for surgical intervention remains a major clinical challenge. Early clinical findings may be nonspecific, and delays in decision-making can increase morbidity. Therefore, simple and accessible biomarkers that support early risk assessment are needed. The hemoglobin, albumin, lymphocyte, and platelet (HALP) score may provide such information by reflecting both inflammatory and nutritional status. This study aimed to evaluate the role of HALP score in predicting the need for surgical intervention in ileus patients.

Materials and Methods: This retrospective study included 216 adult patients diagnosed with ileus between January 2019 and December 2024. Patients were categorized into conservative (63.4%) and surgical (36.6%) treatment groups. HALP scores were calculated from initial laboratory values and compared between groups. Additional analyses were performed to evaluate associations with clinical features.

Results and Conclusion: HALP scores were significantly lower in patients who required surgical intervention compared to those managed conservatively (p=0.009). Lower HALP values were also observed in patients with malignancy (p=0.010), suggesting an association with more severe underlying pathology. These findings indicate that HALP score may serve as a useful adjunct in identifying patients at higher risk for surgical intervention. While it should not replace clinical judgment, it may support decision-making, particularly in borderline cases where the clinical picture is unclear. Given its simplicity and availability from routine laboratory tests, HALP score can be easily integrated into emergency department workflows without additional cost or delay.

Keywords: Ileus, HALP score, surgical decision

Ref No: 3383

Fatal Pneumomediastinum Following Suspected Odontogenic Infection

Şeyma Nur Çalışır1, Abdullah Yaser Güney1, Zeynep Karakuş1, Aytaç Polat1

1Başakşehir Çam ve Sakura Şehir Hastanesi

Şeyma Nur Çalışır / Başakşehir Çam ve Sakura Şehir Hastanesi

Introduction and Purpose: Pneumomediastinum is an uncommon condition characterized by the presence of air in the mediastinum and is usually benign and self-limiting (1). However, secondary pneumomediastinum associated with trauma, esophageal injury, or deep neck infections—particularly of odontogenic origin—may spread to the mediastinum and result in life-threatening complications such as pneumothorax and empyema (2).

Materials and Methods: A 49-year-old woman presented to the emergency department with throat swelling and dyspnea. Her medical history was significant for diabetes mellitus and hyperlipidemia. Her symptoms had progressively worsened over the preceding three days. She reported a history of tooth extraction three months earlier, with no recent history of trauma or any additional invasive procedure. On initial physical examination, she was found to be in severe respiratory distress. Non-crepitant swelling extending from the submandibular region was noted. Her vital signs revealed an oxygen saturation of 85% on room air, a heart rate of 128 beats/min,

and an arterial blood pressure of 142/91 mmHg. Laboratory evaluation demonstrated elevated acute-phase reactants. Thoracic computed tomography showed air densities extending from the right cervical region into the mediastinum, pneumomediastinum, an associated right focal pneumothorax, and a 3.5-cm pleural effusion. During follow-up, the patient developed respiratory failure and was subsequently intubated. Following intubation, tube thoracostomy was performed, and pleural fluid analysis was consistent with empyema. Pleural fluid culture grew Streptococcus anginosus. Despite intensive care management, her clinical condition progressively deteriorated, and she died during her stay in the intensive care unit.

1.



Results and Conclusion: Pneumomediastinum is a rare emergency department presentation, most commonly seen in children and young adults (3). This case is remarkable because of its complicated course with pneumothorax and empyema. Intraoral procedures may cause deep neck infection and secondary pneumomediastinum (3 ,4). Although the dental extraction had been performed three months earlier, isolation of S. anginosus, an oral flora organism associated with abscess formation, together with cervical-to-mediastinal air on imaging, suggests an insidious oral and deep neck infectious source (5,6,7). Clinicians should consider infectious complications, pneumothorax, and empyema in pneumomediastinum patients with a history of dental procedures. Early recognition, close monitoring, and timely airway management are crucial for preventing mortality.

2.

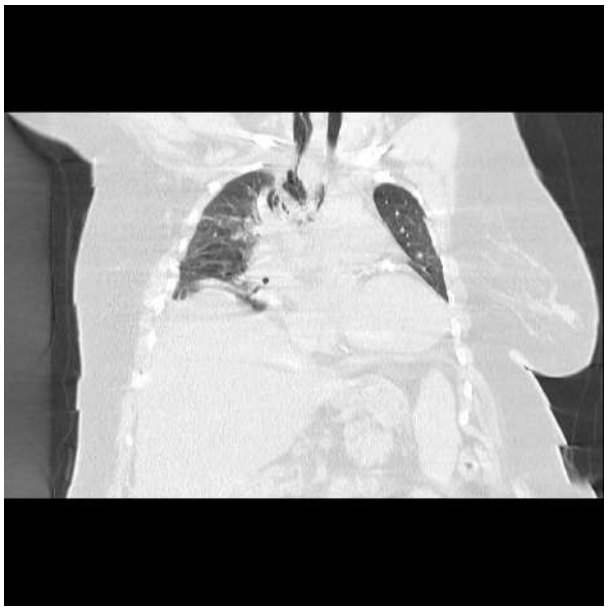

3.

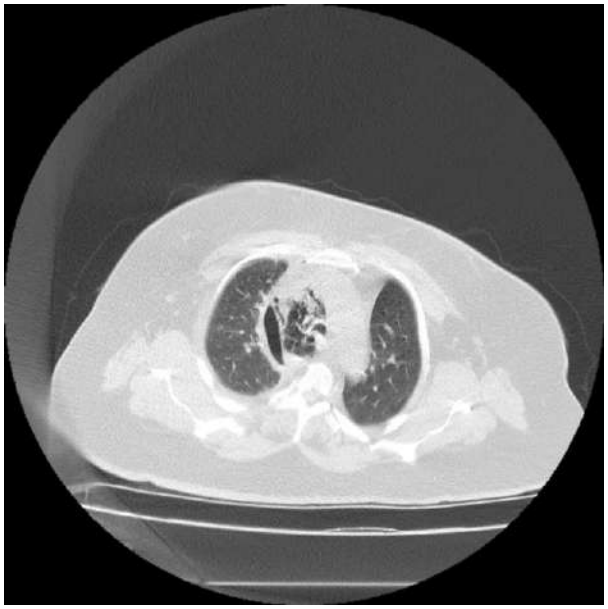

Keywords: emphysema, emergecy, pneumomediastinum

Ref No: 3416

Diagnostic Performance of a YOLOv8n-Based Artificial Intelligence Model for Detecting Nasal Bone Fractures on Lateral Nasopharyngeal Radiographs in the Emergency Department

Ekim Sağlam Gürmen[1], Musap Taha Güvengil[1]

[1]Manisa Celal Bayar University School Of Medicine , Emergency Department , Manisa, Türkiye

Musap Taha Güvengil / Manisa Celal Bayar University School Of Medicine , Emergency Department , Manisa, Türkiye

Introduction and Purpose: Nasal bone fractures are among the most frequently encountered facial injuries in emergency departments (EDs) (1). While lateral nasopharyngeal radiographs are widely used due to their accessibility and cost-effectiveness, interpretation often depends on the experience of the clinician or radiologist, which may lead to diagnostic variability, particularly in busy or high-volume ED settings (2). Recent advances in artificial intelligence (AI), especially deep learning models like YOLOv8n, offer the potential to enhance diagnostic accuracy and provide real-time decision support for fracture detection (3-6) This study aimed to assess the diagnostic performance and practical utility of a YOLOv8n-based AI model for identifying nasal bone fractures on lateral radiographs in a real-world ED population.

Materials and Methods: We conducted a retrospective analytical study including 1,099 adult patients who presented with nasal trauma between January 2021 and December 2023. Radiographs were randomly divided into training (80%) and independent test (20%) datasets. Fracture status was determined based on combined clinical evaluation and radiological interpretation. The YOLOv8n model was trained for 50 epochs using standard data augmentation techniques. Performance metrics evaluated included accuracy, precision, recall (sensitivity), F1-score, and mean average precision at an intersection-over-union threshold of 0.5 (mAP@0.5). Additionally, confusion matrix analysis was performed to provide a detailed understanding of classification outcomes

Results and Conclusion: Among the patients,62.9% were male, with a median age of 31 years. The overall fracture rate was 23.4%.Trauma mechanism was significantly associated with fracture presence (p=0.001), with assault-related injuries showing the highest fracture rate (34.5%). On the independent test set,the AI model demonstrated an accuracy of 86.8%, precision of 65.2%,recall of 69.8%,F1-score of 0.67, and mAP@0.5 of 0.711. Confusion matrix analysis revealed 30 true positives, 161 true negatives,13 false negatives,and 16 false positives, highlighting the model's balanced performance in detecting fractures and non-fracture cases.Conclusion:The YOLOv8n-based AI model showed clinically acceptable performance for

detecting nasal bone fractures on lateral radiographs and could serve as a rapid screening and decision-support tool in high-volume ED settings(6). Its integration into clinical workflows may improve efficiency, reduce diagnostic variability and potentially mitigate medicolegal risks (3).Further multicenter prospective studies are warranted to validate these findings and explore real-time deployment in emergency care environments

Keywords: nasal fracture, artificial intelligence, deep learning

---

Ref No: 3427

Opinions of Pamukkale University Faculty of Medicine Students Regarding Emergency Medicine Residency Training

Murat Seyit[1], Merve Begüm Gündüz[1], Suna Zehra Sevici[1], Arif Emre Yenibağcı[1]

[1]Pamukkale University Faculty of Medicine

Murat Seyit / Pamukkale University Faculty of Medicine

Introduction and Purpose: This study aims to determine the perspectives of medical faculty students on residency in Emergency Medicine. A study was planned by three 2nd-year medical students within the scope of the Special Study Module (SSM). 150 students participated in the survey, and their responses are detailed below.

Materials and Methods: Among the participants, 23 (15.3%) were 1st-year, 84 (56%) were 2nd-year, 13 (8.7%) were 3rd-year, 6 (4%) were 4th-year, 9 (6%) were 5th-year, and 15 (10%) were 6th-year students. Knowledge of Residency Specialties: 31 (20.7%) believe they have sufficient information about the specialties in the Examination for Specialty in Medicine (TUS), 61 (40.7%) are undecided, and 58 (38.7%) do not believe they are sufficiently informed.Regarding the preference for Emergency Medicine in the TUS:•4 (2.7%) are definitely considering it.•27 (18%) are partially considering it.•34 (22.7%) are undecided.•55 (36.7%) are partially not considering it.•30 (20%) are definitely not considering it.Reasons for choosing Emergency Medicine (among 31 students):•Interest/Passion: 5 (16.1%)•Academic career: 1 (3.2%)•Promising future: 1 (3.2%)•Professional satisfaction: 9 (29%)•Short-term patient follow-up: 8 (25.8%)•Shift-based work schedule: 1 (3.2%)•Teamwork environment: 2 (6.5%)•Depending on the exam score: 4 (12.9%)Reasons for NOT choosing Emergency Medicine (among 85 students):•Heavy workload: 24 (28.2%)•Stressful environment: 19 (22.4%)•Irregular working hours: 21 (24.7%)•Security concerns: 5 (5.9%)•Pressure of rapid decision-making: 15 (17.6%)•Not suitable for teamwork:

1 (1.2%)Alternative Specialty PreferencesAmong the 85 students who do not consider Emergency Medicine, their preferred specialties are as follows: Family Medicine (3.5%), Anatomy (1.2%), Anesthesiology and Reanimation (2.4%), Neurosurgery (4.7%), Pediatrics (3.5%), Child and Adolescent Psychiatry (3.5%), Dermatology (7.1%), Physical Medicine and Rehabilitation (7.1%), Physiology (1.2%), General Surgery (2.4%), Ophthalmology (10.6%), Air and Space Medicine (1.2%), Internal Medicine (3.5%), Obstetrics and Gynecology (3.5%), Cardiovascular Surgery (2.4%), Cardiology (4.7%), Otorhinolaryngology (5.9%), Neurology (3.5%), Orthopedics and Traumatology (7.1%), Plastic, Reconstructive and Aesthetic Surgery (8.2%), Radiation Oncology (1.2%), Psychiatry (3.5%), Underwater and Hyperbaric Medicine (1.2%), Medical Pharmacology (1.2%), Medical Genetics (1.2%), Medical Pathology (1.2%), Urology (2.4%), and 1.2% are not considering any specialty.

Perspectives on Emergency Medicine

Regarding the preference for Emergency Medicine in the TUS:

- 4 (2.7%) are definitely considering it.
- 27 (18%) are partially considering it.
- 34 (22.7%) are undecided.
- 55 (36.7%) are partially not considering it.
- 30 (20%) are definitely not considering it.

Reasons for choosing Emergency Medicine (among 31 students):

- Interest/Passion: 5 (16.1%)
- Academic career: 1 (3.2%)
- Promising future: 1 (3.2%)
- Professional satisfaction: 9 (29%)
- Short-term patient follow-up: 8 (25.8%)
- Shift-based work schedule: 1 (3.2%)
- Teamwork environment: 2 (6.5%)
- Depending on the exam score: 4 (12.9%)

Reasons for NOT choosing Emergency Medicine (among 85 students):

- Heavy workload: 24 (28.2%)
- Stressful environment: 19 (22.4%)
- Irregular working hours: 21 (24.7%)
- Security concerns: 5 (5.9%)
- Pressure of rapid decision-making: 15 (17.6%)
- Not suitable for teamwork: 1 (1.2%)

Results and Conclusion: We believe that increasing the promotion of Emergency Medicine and highlighting its attractive aspects to students is essential to encourage its selection as a specialty

Keywords: Intern, Emergency medicine, Student

Ref No: 3536

Evaluation of Swimming Pool Water Quality and Effectiveness of Follow-up Interventions In A District-Based Surveillance Program

Fatih Türkmen[1], Selçuk Eren Çanakçı[2]

[1]Avcılar District Health Directorate, Istanbul, Turkey
[2]Department of Emergency Medicine, Adnan Menderes University, Aydın, Turkey

Selçuk Eren Çanakçı / Department of Emergency Medicine, Adnan Menderes University, Aydın, Turkey

Introduction and Purpose: Swimming pool water quality is an important public health concern due to the risk of waterborne infections. Regular monitoring and timely corrective actions are essential to ensure safe recreational water environments. This study aimed to evaluate the microbiological and chemical quality of swimming pool water samples and to assess the effectiveness of follow-up interventions in samples found to be non-compliant.

Materials and Methods: A total of 50 swimming pool water samples collected by Istanbul Avcılar District Health Directorate between September 2025 and March 2026 were included in this study. Samples collected as part of follow-up monitoring after initial non-compliant results were excluded from the primary analysis. Thus, 41 routine samples were evaluated. Microbiological parameters included total colony count, Pseudomonas aeruginosa, coliform bacteria, and Escherichia coli. Chemical parameters included nitrate, nitrite, turbidity, cyanuric acid, copper, aluminum, pH, residual chlorine, ammonium, color, and total alkalinity. Results were evaluated in accordance with the Turkish Regulation on the Health Principles of Swimming Pools (Official Gazette No. 27866, dated March 6, 2011). Follow-up samples were analyzed separately to evaluate the effectiveness of corrective actions.

Results and Conclusion: Results: Among the 41 routine samples, 8 (19.5%) were found to be non-compliant with at least one parameter. Microbiological non-compliance was detected in 5 samples (12.2%), while chemical non-compliance was observed in 4 samples (9.8%). One sample (2.4%) showed both microbiological and chemical non-compliance. The most frequent microbiological issue was coliform bacteria, detected in 4 samples (9.8%), followed by Pseudomonas aeruginosa in 1 sample (2.4%). Escherichia coli was not detected in any sample. Among chemical parameters, only one sample (2.4%) showed pH deviation, while all turbidity measurements were within acceptable limits. All non-compliant samples (n=8) had corresponding follow-up analyses, and full compliance was achieved in all cases (100%). Conclusion: A considerable proportion of swimming pool water samples showed non-compliance, predominantly due to microbiological contamination. However, follow-up

monitoring and targeted interventions were highly effective, achieving full correction in all cases. These findings highlight the critical role of regular surveillance and prompt response in maintaining safe swimming pool environments.

Table 1. Microbiological and chemical analysis results of routine samples (n=41)

Parameter	**Non-compliant n (%)**
Overall non-compliance	8 (19.5%)
Microbiological non-compliance	5 (12.2%)
Coliform bacteria	4 (9.8%)
Pseudomonas aeruginosa	1 (2.4%)
Escherichia coli	0 (0%)
Chemical non-compliance	4 (9.8%)
pH	1 (2.4%)
Turbidity	0 (0%)
Other chemical parameters	3 (7.3%)
Both microbiological & chemical	1 (2.4%)

Keywords: public health, surveillance, swimming pool water

Ref No: 3551

Pulmonary Embolism Associated With Oral Contraceptive Use in a Young Female Patient

Nevzat HERGÜL[1], Mehmet Şirin BÜYÜKKAYA[2], Sevdegül KARADAŞ[1], Barış ÇİÇEK[1]
[1]Van Yüzüncü Yıl University, Faculty of Medicine
[2]Health Sciences University Van Training and Research Hospital

Barış ÇİÇEK / Van Yüzüncü Yıl University, Faculty of Medicine

Introduction and Purpose: Pulmonary embolism (PE) is a potentially fatal condition caused by acute obstruction of the pulmonary arterial circulation. Although it is more commonly associated with advanced age and multiple comorbidities, PE should also be considered in young patients with acquired thromboembolic risk factors. Oral contraceptive (OC) use is a well-established cause of hypercoagulability and increases the risk of venous thromboembolism, particularly during the first year of use. The aim of this case is to highlight OC use as a significant and potentially isolated risk factor for PE in young women presenting with acute dyspnea.

Materials and Methods: A 21-year-old woman presented to the emergency department with dyspnea lasting three days. Her medical history was otherwise unremarkable, but she reported regular OC use for the previous six months. On admission, body temperature was 36.5°C, blood pressure 100/70 mmHg, heart rate 118 beats/min, respiratory rate 22 breaths/min, and oxygen saturation 95%. She was conscious, cooperative, and oriented. Lung auscultation revealed normal breath sounds. Chest radiography showed no significant abnormality. Laboratory findings included hemoglobin 11 g/dL, platelet count 230,000/mm³, and INR 0.9. Bilateral lower extremity venous Doppler ultrasonography showed no evidence of thrombosis. Because the Wells score was 4.5, computed tomography pulmonary angiography was performed without prior D-dimer testing. Imaging demonstrated filling defects consistent with emboli in multiple segmental branches of both pulmonary arteries, predominantly in the lower lobe branches (Figure 1). Intravenous unfractionated heparin was initiated with an 80 U/kg bolus followed by continuous infusion at 18 U/kg/h. The patient was hospitalized in the chest diseases department and discharged on a direct oral anticoagulant after seven days.


Figure 1

CT pulmonary angiography revealing bilateral pulmonary emboli, as indicated by arrows.

Results and Conclusion: This case demonstrates that OC use may represent an independent risk factor for PE even in the absence of other recognized predisposing factors. Estrogen-containing contraceptives promote hypercoagulability by altering procoagulant and anticoagulant pathways, thereby increasing thrombotic risk. In young women presenting with acute dyspnea, PE should remain in the differential diagnosis, and OC use should be specifically questioned. Early recognition and prompt anticoagulant treatment are essential to reduce morbidity and mortality.

Keywords: oral contraceptives, dyspnea, Pulmonary embolism

Ref No: 3631

Mobile Multiplace Hyperbaric Oxygen Unit for Crush Injuries in Earthquake Disasters: A National Capacity Analysis from Türkiye and a Deployment Model

Recep Özkan[1], Erdal Tekin[2]

[1]Erzurum City Hospital
[2]Atatürk University

Erdal Tekin / Atatürk University

Introduction and Purpose: Türkiye is located on active seismic fault lines and has experienced large-scale earthquakes causing significant morbidity. Crush injuries and acute compartment syndrome are major contributors to limb loss in disaster settings. Hyperbaric oxygen therapy (HBOT) enhances tissue oxygenation, reduces edema, improves leukocyte function, and has been reported to decrease amputation rates in selected cases of acute traumatic ischemia. However, access to HBOT during disasters may be limited due to geographic clustering of fixed centers. This study aimed to analyze the national hyperbaric treatment capacity in Türkiye and propose a deployable mobile multiplace HBOT system for early on-site intervention in disaster zones.

Materials and Methods: The number and geographic distribution of HBOT centers in Türkiye were evaluated using publicly available institutional data. Distribution patterns were analyzed in relation to earthquake-prone regions. Potential delays associated with intercity transfer of crush victims were conceptually assessed. Based on identified capacity gaps, a conceptual design model for a truck-mounted mobile multiplace hyperbaric chamber was developed to allow rapid deployment to affected areas.

Results and Conclusion: A total of 57 HBOT centers operate across 28 provinces in Türkiye, with significant concentration in major metropolitan areas. In large-scale disasters, transportation of crush victims to distant centers may result in treatment delays. A mobile multiplace HBOT unit could provide early intervention directly within disaster zones, potentially reducing amputation rates and improving limb salvage outcomes. Such a system may also support provinces without fixed HBOT infrastructure or areas where facilities are damaged during disasters. Integrating mobile hyperbaric systems into national disaster preparedness planning may strengthen acute trauma management capacity in Türkiye.

Figure 1



Figure 1. Geographic distribution of the 57 hyperbaric oxygen therapy (HBOT) centers across 28 cities in Türkiye included in the study. Additional HBOT facilities in Batman, Aydın, Ordu, and Zonguldak are currently in the planning phase and are therefore not included in the present analysis.

fig 2

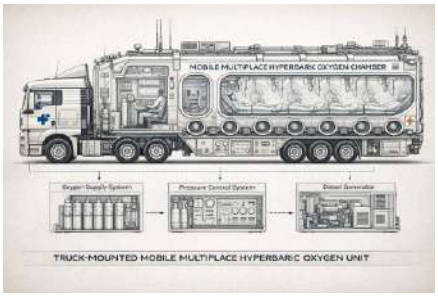

Figure 2. Technical schematic representation of a truck-mounted mobile multiplace hyperbaric oxygen unit designed for rapid disaster deployment. The system includes a multiplace chamber (2.0–2.8 ATA capacity), integrated oxygen supply module, pressure control system, and independent power generator.

Keywords: hyperbaric oxygen therapy, crush injury, mobile medical systems

Ref No: 3668

Postpartum Posterior Reversible Encephalopathy Syndrome Presenting with Tonic-Clonic Seizures: A Case Report

İbrahim Halil Yasak[1], Cansu Doğan[1], Fatma Taş[1]

[1]Harran University Faculty of Medicine

Cansu Doğan / Harran University Faculty of Medicine

Introduction and Purpose: Posterior reversible encephalopathy syndrome (PRES) is a clinical-radiological syndrome characterized by acute or subacute-onset headache, encephalopathy, seizures, and visual disturbances; neuroimaging typically reveals vasogenic edema in the posterior regions. Pregnancy-related hypertensive disorders, particularly preeclampsia and eclampsia, are well-established triggers for PRES.

Materials and Methods: Case presentation: A 26-year-old female patient was brought to the emergency department on the fourth postpartum day due to recurrent generalized tonic-clonic seizures and altered consciousness. At presentation, her arterial blood pressure was 170/120 mmHg. A non-contrast cranial computed tomography scan revealed no acute pathology. Diffusion-weighted magnetic resonance imaging showed signal increases in the bilateral parieto-occipital and frontal regions without diffusion restriction, consistent with acute infarction; the findings were consistent with PRES.

Figure 1

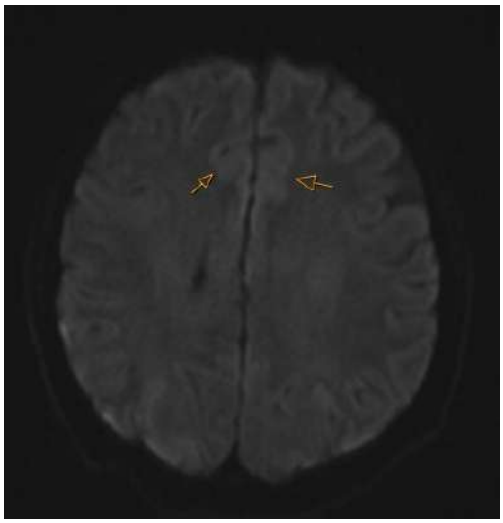

Bilateral frontal cortical-subcortical signal intensities on diffusion-weighted magnetic resonance imaging

Figure 2

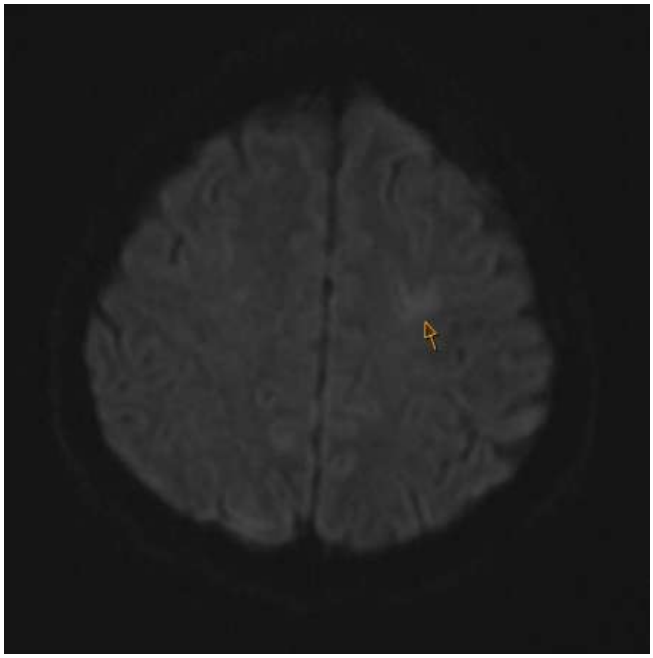

Increased signal intensity in the left frontal cortical-subcortical region on diffusion-weighted magnetic resonance imaging

Results and Conclusion: Conclusion: In cases presenting with seizures and encephalopathy during the postpartum period, particularly those with severe hypertension, PRES should be considered first in the differential diagnosis. A normal cranial CT scan does not rule out PRES; magnetic resonance imaging is of critical importance in diagnosis. Early diagnosis and rapid multidisciplinary management can reduce the risk of permanent neurological damage.

Keywords: posterior reversible encephalopathy syndrome, postpartum, hypertensive emergency

Ref No: 3681

Acute Liver Failure and Hepatic Encephalopathy Developing on the Basis of Chronic Alcoholism

Bekir Kılıç[1], İlknur Şahin[1], Muhammet Gökhan Turtay[1], Gökhan Yılmaz[1], Ahmet Muhammet Şahingeri[1], Ali Tayyip Kömürcü[1]

[1]University of Health Sciences, Beyhekim Training and Research Hospital, Clinic of Emergency Medicine, Konya, Türkiye.

Muhammet Gökhan Turtay / University of Health Sciences, Beyhekim Training and Research Hospital, Clinic of Emergency Medicine, Konya, Türkiye.

Introduction and Purpose: In this case report, we presented a 22-year-old female patient with chronic alcoholism who experienced a hepatic encephalopathy episode with progressive hyperbilirubinemia, hyponatremia, disorientation, and asterixis following alcohol intoxication and was referred to a liver transplant centre.

Materials and Methods: A 22-year-old female patient was brought to the emergency department with a diagnosis of alcohol intoxication. She was uncooperative and agitated secondary to high-dose alcohol ingestion. Laboratory investigations revealed aspartate aminotransferase (AST) 466 U/L, alanine aminotransferase (ALT) 307 U/L, gamma-glutamyl transferase (GGT) 1254 U/L, total bilirubin 2.2 mg/dL, sodium 131 mEq/L, and an ethanol level of 469.3 mg/dL. Abdominal ultrasonography showed only Grade 2 steatosis, with no other significant pathology. The patient was admitted to the intensive care unit due to treatment-resistant active nausea and vomit. During follow-up, her ethanol level decreased to 198 mg/dL, and transaminase levels dropped by 20–30%. However, the total bilirubin level rose to 7.7 mg/dL, resulting in a marked icteric clinical state. Prognostic scoring yielded a Model for End-Stage Liver Disease score of 18. Visual and auditory hallucinations and asterixis developed, indicating the progression of hepatic encephalopathy. The patient, evaluated as stage 3 hepatic encephalopathy, was transferred to a centre with gastroenterology and liver transplant capabilities for further management.

Results and Conclusion: Hepatic encephalopathy must be included in the differential diagnosis of patients presenting with altered consciousness and a history of alcohol use. Furthermore, it should be kept in mind that liver transplantation may be required in patients with active hepatic encephalopathy and a Model for End-Stage Liver Disease score above 15.

Keywords: Alcoholism, Hepatic encephalopathy, MELD

Ref No: 3685

Extreme High Anion Gap Metabolic Acidosis and Anuric Acute Kidney Injury Triggered by Gastrointestinal Infection in Severe Anorexia Nervosa: A Case Report

AHMET DURSUN DEMİR[1], YAVUZ SELİM GÜZEL[1], HIZIR UFUK AKDEMİR[1]

[1]Department of Emergency Medicine, Ondokuz Mayıs University Faculty of Medicine, Samsun, Türkiye

YAVUZ SELİM GÜZEL / Department of Emergency Medicine, Ondokuz Mayıs University Faculty of Medicine, Samsun, Türkiye

Introduction and Purpose: Anorexia nervosa is a severe eating disorder associated with profound malnutrition and systemic complications, including electrolyte disturbances, acid–base disorders, and multi-organ dysfunction. Prolonged starvation, vomiting, and hypovolemia may lead to life-threatening metabolic derangements such as lactic acidosis, ketoacidosis, and acute kidney injury. Early recognition of these complications in the emergency setting is critical to reduce mortality.

Materials and Methods: A 24-year-old female with a long-standing history of anorexia nervosa presented to the emergency department with cessation of oral intake, persistent vomiting, abdominal pain, and anuria. On admission, she appeared severely cachectic (body mass index 11.7 kg/m²) and was hypotensive (70/40 mmHg) with tachycardia. Arterial blood gas analysis revealed profound metabolic acidosis with a pH of 6.90, bicarbonate level of 6.4 mmol/L, and lactate level of 16 mmol/L. The calculated anion gap was markedly elevated at 40.6 mmol/L, consistent with severe high anion gap metabolic acidosis.Urinalysis demonstrated ketonuria, suggesting a multifactorial etiology involving both lactic acidosis and starvation ketoacidosis. Laboratory evaluation also revealed acute kidney injury with a serum creatinine level of 5.13 mg/dL and complete anuria. Despite aggressive fluid resuscitation, hypotension persisted, necessitating vasopressor support with norepinephrine.Given the presence of severe metabolic acidosis, hemodynamic instability, and anuric acute kidney injury, emergent renal replacement therapy was initiated, and the patient underwent hemodialysis. Post-dialysis evaluation demonstrated significant improvement in acid–base parameters (pH 7.33; bicarbonate 18 mmol/L; lactate 9.4 mmol/L).Microbiological analysis revealed Salmonella species in stool culture, indicating a gastrointestinal infection that likely contributed to dehydration and metabolic decompensation. The patient was subsequently managed in the intensive care unit with close monitoring of metabolic and renal parameters.

Results and Conclusion: Severe anorexia nervosa may lead to extreme metabolic derangements, particularly when combined with triggering factors such as infection and dehydration. High

anion gap metabolic acidosis and acute kidney injury can rapidly become life-threatening. Early acid–base evaluation, prompt hemodynamic stabilization, and timely initiation of renal replacement therapy are essential to improve outcomes in such critically ill patients.

Keywords: Anorexia nervosa, High anion gap metabolic acidosis, Acute kidney injury

---

Ref No: 3746

Deep Thrombocytopenia Induced by Terbinafine Use: A Case Report

İsa Yıldırım[1], Ozan Deniz Keleş[1], Murat Teker[1], Ahmet Melih Savaş[1], Ayhan Aköz[1]

[1]Department of Emergency Medicine, Faculty of Medicine, Aydın Adnan Menderes University, Aydın, Türkiye

İsa Yıldırım / Department of Emergency Medicine, Faculty of Medicine, Aydın Adnan Menderes University, Aydın, Türkiye

Introduction and Purpose: Drug-induced thrombocytopenia is a clinically significant condition where over 200 medications are known to cause immune-mediated suppression of platelet production, increased platelet destruction, or platelet aggregation. While usually well-tolerated, the antifungal agent terbinafine can rarely lead to serious hematological side effects. This report presents a case of deep thrombocytopenia suspected to be induced by terbinafine, emphasizing the importance of medication history in differential diagnosis.

Materials and Methods: A 71-year-old male presented to the emergency department with epistaxis (nosebleed) and gingival bleeding. Upon examination, while active epistaxis had ceased, gingival bleeding continued, and petechiae were observed on the buccal mucosa. The patient's medical history included diabetes mellitus and benign prostatic hyperplasia.A detailed history revealed the patient had been using terbinafine for approximately two months to treat a fungal infection on his hand. Laboratory results showed a critical platelet count of 2,000/mm³. Liver function tests and coagulation parameters were within normal limits. Based on the clinical presentation and laboratory findings, the patient was diagnosed with drug-induced thrombocytopenia due to terbinafine and was admitted to the hematology department for further evaluation and treatment.

Results and Conclusion: In patients presenting with mucocutaneous bleeding and deep thrombocytopenia, drug-induced etiologies must be considered in the differential diagnosis. Although rare, terbinafine can cause severe thrombocytopenia, particularly during long-term use.

Early diagnosis, discontinuation of the offending drug, and prompt hematological evaluation are vital to preventing life-threatening bleeding complications.

Keywords: Thrombocytopenia, terbinafine, petechiae

Ref No: 3781

Retrospective Analysis of Crimean-Congo Hemorrhagic Fever Cases Presenting to the Emergency Department

Şebnem Şenol Akar1, Esra Erdem Kıvrak1, Deniz Özer1, Ekim Sağlam Gürmen2

1Manisa Celal Bayar University School of Medicine, Infectious Diseases Department, Manisa, Türkiye

2Manisa Celal Bayar University School of Medicine, Emergency Department, Manisa, Türkiye

Ekim Sağlam Gürmen / Manisa Celal Bayar University School of Medicine, Emergency Department, Manisa, Türkiye

Introduction and Purpose: Crimean-Congo hemorrhagic fever (CCHF) is a life-threatening viral infection in endemic regions, often presenting with nonspecific symptoms in the emergency department (ED), which may delay diagnosis. Early recognition is crucial for timely management and infection control.

Materials and Methods: This retrospective study evaluated 15 patients with PCR-confirmed CCHF who presented or were referred to the Emergency Department of Manisa Celal Bayar University between 2012 and 2025. Demographic, clinical, laboratory, and initial treatment data were obtained from medical records.

Results and Conclusion: Fifty-three percent of patients were female, with a mean age of 48.3 ± 13.1 years. Most patients (93.3%) lived in rural areas, and 40% were engaged in farming or animal husbandry. The mean time from tick exposure to hospital admission was 9.08 (2–30) days. Fever and fatigue were present in all patients, while nausea–vomiting (46.6%), myalgia, and abdominal pain (40%) were common. Hemorrhagic manifestations were observed in 73.3% of cases.At ED admission, leukopenia (86.6%), neutropenia (60%), and thrombocytopenia (80%) were prominent findings. Prolonged INR and aPTT were detected in 40% and 46.6% of patients, respectively. Median fibrinogen and D-dimer levels were 260 [220.5–292] g/L and 605 [115.75–1251.5] ng/mL. Elevated AST and ALT levels were observed in 86.6% and 73.3% of patients,

respectively, and 71.4% had elevated CPK levels. A significant negative correlation was found between platelet count and AST/ALT levels ($p < 0.05$).All patients received ribavirin, and 66.6% required blood product transfusion. Intensive care unit admission was necessary in 20% of cases, with an in-hospital mortality rate of 6.6%. In conclusion, in endemic areas, the combination of exposure history, fever, thrombocytopenia, and elevated transaminases should prompt early suspicion of CCHF in the ED. Rapid diagnosis is essential to improve outcomes and prevent transmission.

Keywords: Crimean- fever, Emergency department, Thrombocytopenia Congo hemorrhagic

---

Ref No: 3782

Evaluation of Inflammatory and Biochemical Markers in Hospitalized Acute Gastroenteritis Cases

Ömer Serdar Mamur[1], Neslihan Kaya[2]

[1]Malatya Turgut Özal Üniversitesi
[2]Kafkas Üniversitesi

Ömer Serdar Mamur / Malatya Turgut Özal Üniversitesi

Introduction and Purpose: Objective: The present study aims to investigate the demographic characteristics and the impact of laboratory parameters (WBC, CRP, albumin, BUN/creatinine ratio) on the length of hospital stay in adult patients hospitalized with a preliminary diagnosis of acute gastroenteritis (AGE).

Materials and Methods: Materials and Methods: A total of 37 patients over the age of 18 with complete data records were included in the study. For data analysis, following normality testing, the Mann-Whitney U test, Independent Samples t-test, and Spearman correlation analysis were utilized. The threshold for statistical significance was set at $p < 0.05$.

Results and Conclusion: Results: The mean age of the patients was 70.22±14.21 years, with males comprising 62.2% of the study population. The median length of hospital stay was determined to be 3 days. Correlation analyses revealed a very strong, positive, and highly significant relationship between the length of hospital stay and CRP levels ($r = 0.946$; $p < 0.001$). A strong positive correlation was observed between age and the BUN/creatinine ratio ($r = 0.699$; $p < 0.001$). Additionally, moderate, negative significant correlations were identified between albumin levels and age ($r = -0.431$; $p = 0.008$), as well as WBC counts ($r = -0.529$; $p = 0.001$).

No statistically significant differences were found between genders regarding laboratory parameters and the length of stay.Discussion and Conclusion: CRP levels serve as a robust predictor of the length of hospital stay, particularly in elderly patients with AGE. Furthermore, the age-related decline in renal perfusion (indicated by an elevated BUN/creatinine ratio) and decreased albumin levels underscore the critical need for close clinical monitoring in this vulnerable demographic.

Table 1. Descriptive Statistics of Demographic Characteristics, Laboratory Parameters, and Clinical Data of the Patients

	n	mean	±sd		n	median	IQR(25-75)
age	37	70,22	14,21	wbc	37	7,2	4,55-11,45
				crp	37	9,7	4,4-12,75
				albumin	37	3,1	2,9-3,3
				Bun/kre	37	50	32,58-64,72
				h-los	37	3	2,0-4,0

Keywords: Acute Gastroenteritis, BUN/Creatinine Ratio, Dehydration

---

Ref No: 3787

Acute pancreatitis with inflammatory progression despite early regression of pancreatic enzymes and imaging findings of mesenteric inflammation: an atypical course causing diagnostic challenge

Emre Gök[1], Fatih Cemal Tekin[1], Fadime Özyiğit Gök[1], Ayşe Işık[1], Mehmet Gül[1]

[1]Emergency Medicine Department, Konya City Hospital, Türkiye

Emre Gök / Emergency Medicine Department, Konya City Hospital, Türkiye

Introduction and Purpose: Acute pancreatitis (AP) is an inflammatory disease typically characterized by severe epigastric pain and elevated pancreatic enzyme levels. Diagnosis is generally established through a combination of clinical, biochemical, and imaging findings. However, in some cases, pancreatic enzyme levels may show limited elevation and rapidly decline, while inflammatory parameters continue to progress. This biochemical-inflammatory

dissociation may create diagnostic challenges and affect clinical management. In this report, we present an atypical case of acute pancreatitis demonstrating inflammatory progression despite early regression of pancreatic enzymes, accompanied by imaging findings of mesenteric inflammation.

Materials and Methods: A 57 year old female presented with epigastric pain, nausea, vomiting, and fever lasting for four days. The pain radiated to the back, and a 6 kg weight loss due to impaired oral intake was reported over the last three days. Physical examination revealed epigastric and right upper quadrant tenderness. Initial laboratory findings showed C-reactive protein (CRP) of 34 mg/L, amylase of 149 U/L, and lipase of 177 U/L. Contrast-enhanced abdominal CT demonstrated edema in mesenteric planes and mesenteric fat stranding around the inferior pancreas and the second portion of the duodenum. On the third day of hospitalization, CRP increased to 128 mg/L, while amylase and lipase levels declined. Based on systemic inflammatory response and imaging findings, antibiotic therapy was initiated, resulting in clinical and laboratory improvement.

Results and Conclusion: In this case, the increase in inflammatory parameters despite early regression of pancreatic enzymes created diagnostic difficulty. Management was guided by integrating mesenteric inflammatory findings and systemic response. In acute pancreatitis, biochemical regression does not exclude the diagnosis; clinical and radiological correlation with serial inflammatory monitoring is essential. In selected cases with suspected infection, guideline-based antibiotic therapy may contribute to clinical improvement.

Keywords: Acute pancreatitison, Enzyme regression, Mesenteric inflammation

---

Ref No: 3789

Ruptured renal angiomyolipoma detected following a motor vehicle accident

Bünyamin Baytemür[1], Yakup Birlik[1], Kudret Selki[1]

[1]Düzce University Faculty of Medicine, Department of Emergency Medicine

Bünyamin Baytemür / Düzce University Faculty of Medicine, Department of Emergency Medicine

Introduction and Purpose: Renal angiomyolipomas (AML) are typically benign tumors; however, they can rupture and lead to life-threatening hemorrhage, particularly following trauma. This report aims to present the emergency department management of a 61-year-old female patient who was incidentally diagnosed with a ruptured renal AML during trauma imaging after a motor vehicle accident

Materials and Methods: A 61-year-old female was brought to the emergency department following an MVA. The patient was conscious and hemodynamically stable upon arrival. Physical examination revealed maxillofacial trauma findings and a deformity in the right wrist. Contrast-enhanced computed tomography imaging identified fractures of the mandible, bilateral temporomandibular joints , and the L1 vertebra , along with a right distal radius fracture. Additionally, a 7x6 cm heterogenous mass with fat-density components and suspected active extravasation was detected in the right kidney, consistent with a ruptured AML (Figure-1). The patient was also diagnosed with concurrent diabetic ketoacidosis.

Figure 1. CT Scan with Ruptured Renal Angiomyolipoma

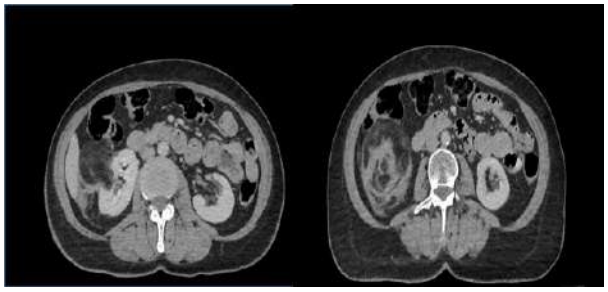

CT Scan with Ruptured Renal Angiomyolipoma

Results and Conclusion: Orthopedic surgeons applied a splint for the limb fractures. Treatment for DKA was initiated with intravenous fluids, insulin, and sodium bicarbonate infusion. Regarding the ruptured AML, the urology department recommended conservative management as there were no signs of clinical deterioration, no significant drop in hemoglobin levels, and vital signs remained stable. The patient was managed with immobilization and close monitoring. In multitrauma cases, routine trauma imaging is essential for the early detection of potentially fatal internal organ hemorrhages like ruptured AML and for guiding multidisciplinary decisions for conservative management.

Keywords: Renal angiomyolipoma, Blunt abdominal trauma, Multitrauma

Ref No: 3817

A Rare Cause of Resistant Headache in Emergency Room

Öyküm Deniz Koygun[1], Elif Bakoğlu[1], Alanur Tarhan[1], Figen Coşkun[1]

[1]Dokuz Eylül University, Faculty of Medicine

Öyküm Deniz Koygun / Dokuz Eylül University, Faculty of Medicine

Introduction and Purpose: Headaches account for approximately 2-3% of emergency department visits. While most are benign, some may be due to life-threatening secondary causes. We present a case diagnosed after further investigation due to persistent pain without neurological findings.

Materials and Methods: A 56-year-old male presented with a headache that started suddenly at night and worsened progressively, accompanied by vomiting. It was the most severe headache of his life. He had no previous similar attacks. There was no history of head trauma or infectious disease.The patient's vital signs were stable, and no pathological findings were detected during physical and neurological examinations. Further imaging was performed due to the sudden onset headache that was resistant even to narcotic analgesics.

Results and Conclusion: CT revealed a sellar mass measuring approximately 20×28mm expanding the sellar cavity and extending into the right sphenoid sinus (Figure 1). CT angiography excluded vascular pathology. The MRI scan revealed a 33×26×22mm lesion transgressing the sella, invading both cavernous sinuses predominantly on the right (Figure 2,3,4). There was minimal central enhancement and narrowing of the prepontine cistern, consistent with pituitary adenoma. The preoperative prolactin level was 54.50 ng/mL, indicating mild to moderate hyperprolactinemia.The patient underwent joint evaluation by neurosurgery, neurology, endocrinology and ophthalmology departments on the same day, was admitted to the neurosurgery ward and underwent transsphenoidal hypophysectomy without complications. Histopathological examination confirmed the diagnosis; immunohistochemical staining positive for synaptophysin and prolactin established a diagnosis of prolactinoma.Pituitary adenomas can closely mimic primary headaches. Pain arises from trigeminal afferents within the diaphragma sellae and surrounding dura, presenting as frontal or retro-orbital pain indistinguishable from migraine. Advanced imaging, including MRI, is essential in patients with sudden, resistant headaches.Treatment is guided by tumor size, growth pattern, and hormonal activity. Prolactinomas generally respond to dopamine agonist therapy, and surgery is not the primary approach. Macroadenomas exerting mass effect on the optic chiasm or extending into the cavernous sinus, and tumors secreting growth hormone or adrenocorticotropic hormone, are

primarily treated surgically. In this case, surgery was decided due to lesion size, anatomical location, resistant headache, and risk of vision loss.

Figure 1. Axial Cranial CT



Figure 2. T1 weighted coronal MRI

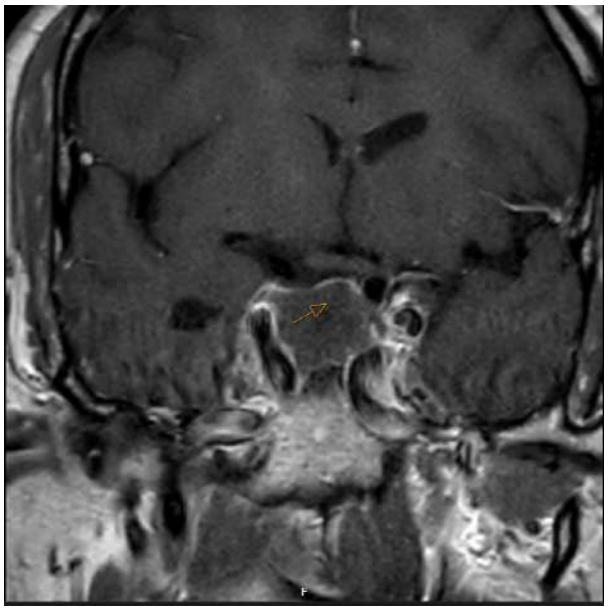

Figure 3. T1 weighted sagittal MRI

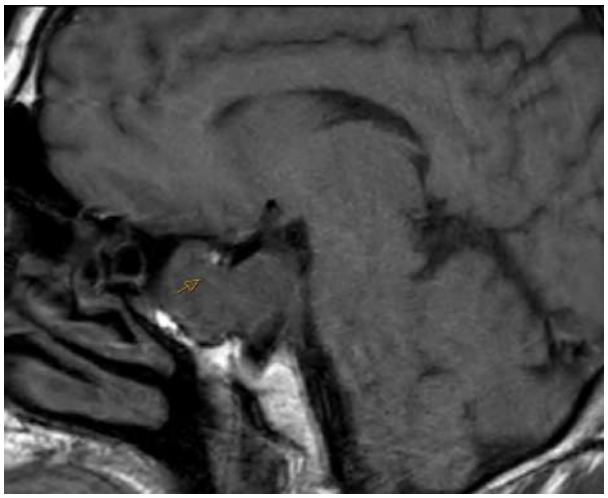

Figure 4. T2 weighted sagittal MRI

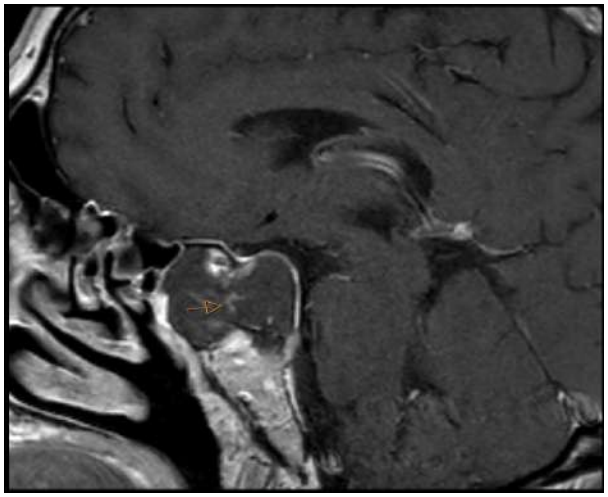

Keywords: pituitary adenoma, thunderclap headache, transsphenoidal surgery

Ref No: 3820

Heatmap-Based Analysis of Drowning Incidents and Triage Codes in a Coastal Region: The Case of Mersin, Türkiye

Mustafa Ekici[1], Muhammet Ali Erinmez[1]

[1]Mersin İl Sağlık Müdürlüğü

Mustafa Ekici / Mersin İl Sağlık Müdürlüğü

Introduction and Purpose: Drowning incidents represent a significant public health problem, particularly in coastal regions, and constitute high-risk cases for prehospital emergency medical services. This study aimed to investigate the spatial distribution of drowning incidents and their relationship with triage codes in Mersin, Türkiye, between 2023 and 2025.

Materials and Methods: This retrospective and descriptive study included drowning and near-drowning cases recorded by the Mersin Provincial Ambulance Service Chief Physician between January 1, 2023, and May 31, 2025. Triage codes, incident locations, and annual distributions were analyzed. Geographic Information Systems were used to visualize case density through heatmap analysis. Data were analyzed using IBM SPSS Statistics 21.

Results and Conclusion: A total of 419 drowning and near-drowning cases were recorded during the study period. Of these, 14.8% were assessed as dead at the scene, while 30.78% were transported to hospitals with red triage codes (Figure 1). Overall, 30.79% of cases were classified as red, 14.8% as black, 35.8% as yellow, and 20.5% as green (Figure1). The number of cases was 194 in 2023, 196 in 2024, and 29 in the first five months of 2025. When projected to the end of 2025, approximately 70 cases are expected, indicating a lower incidence compared to previous years. This decrease is likely due to the seasonal increase in drowning cases during summer months and the absence of summer data for 2025 (Table 1). District-based analysis showed that cases were most concentrated in Erdemli (28.64%), Silifke (21.24%), and Tarsus (12.65%), with a marked clustering along the coastal line (Table 2). Heatmap analysis proved to be an effective tool for identifying high-risk areas (Figure 2). The high proportion of red and black triage codes highlights the critical importance of effective team planning and preventive interventions in prehospital emergency medical services.

	2023		2024		2025 (ilk 5 ay)	
	n	%	n	%	n	%
Siyah	29	14,9	24	12,2	6	20,7
Kırmızı	52	26,9	66	33,7	11	37,9
Sarı	67	34,5	70	35,7	10	34,5
Yeşil	46	23,7	36	18,4	2	6,9
TOPLAM	190	100	196	100	29	100

Tablo.1-Boğulma Vakaları Triyaj Renk Kodlarının Yıllara Göre Dağılımı

Table 1

İLÇE ADI	2023	2024	2025 İLK 5 AY	TOPLAM	ORAN %
ERDEMLİ	50	57	13	120	28,64
SİLİFKE	41	43	5	89	21,24
TARSUS	30	23	-	53	12,65
MEZİTLİ	18	12	3	33	7,88
ANAMUR	19	10	3	32	7,64
YENİŞEHİR	10	17	3	30	7,16
AKDENİZ	15	10	1	26	6,21
BOZYAZI	5	8	-	13	3,10
TOROSLAR	1	8	-	9	2,15
GÜLNAR	2	5	1	8	1,91
AYDINCIK	3		-	3	0,72
MUT		3	-	3	0,72
TOPLAM	194	196	29	419	100

Tablo.2- Boğulma Vakalarının İlçelere Dağılımı

Table 2

Figure 1



Grafik.1- 29 Aylık Süreçte Yaşanan Boğulma Vakalarının Triyaj Renk Kodlarına Dağılımı

Figure 2

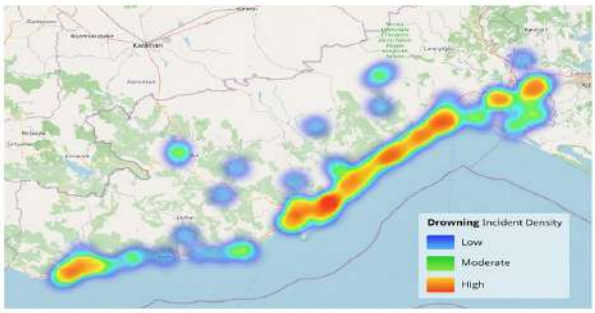

Fotoğraf.1- Mersin İli Boğulma Isı Haritası

Keywords: Drowning, Triage, Heatmap

Ref No: 3858

Association of CRP/Albumin Ratio with Hospitalization in Patients with Cellulitis Presenting to the Emergency Department

Ahmet Hakan Taş[1], Serap Dolanbay[2]

[1]Malatya Turgut Özal Üniversitesi
[2]Kars Kafkas Üniversitesi

Ahmet Hakan Taş / Malatya Turgut Özal Üniversitesi

Introduction and Purpose: Introduction:Cellulitis is an acute bacterial infection of the dermis and subcutaneous tissue and is commonly encountered in the emergency department. It most frequently affects the lower extremities and presents with erythema, increased temperature, edema, and tenderness. The most common causative agents are beta-hemolytic streptococci and Staphylococcus aureus. Although hospitalization rates have increased in recent years, the need for admission is not always clearly defined. Clinical decisions are typically based on a combination of clinical findings, comorbidities, and laboratory data. However, the role of routine laboratory parameters in predicting hospitalization remains unclear.Objective:To investigate the association between routine laboratory parameters, particularly the C-reactive protein/albumin ratio (CAR), and hospitalization in patients with cellulitis.

Materials and Methods: This retrospective observational study included patients diagnosed with cellulitis in the emergency department between November 1, 2025, and February 1, 2026. Demographic data and laboratory parameters, including white blood cell (WBC), neutrophil (NEU), albumin, CRP, and CAR, were recorded. Patients were divided into hospitalized and non-hospitalized groups. Statistical analyses were performed using IBM SPSS 27, and the diagnostic performance of CAR was evaluated using ROC curve analysis.

Results and Conclusion: Results:A total of 43 patients were included, of whom 20.9% were hospitalized. WBC and neutrophil levels were significantly higher in hospitalized patients ($p < 0.001$). While CRP and albumin alone were not significantly associated with hospitalization ($p > 0.05$), CAR showed a significant association ($p=0.045$). The area under the ROC curve for CAR was 0.719, indicating moderate discriminative ability, with an optimal cut-off value of approximately 2.13.Conclusion:CAR may be a practical and easily applicable marker for predicting hospitalization in cellulitis patients and may provide greater clinical value than individual parameters.

Keywords: Cellulitis, Emergency Department, CRP/Albumin Ratio

Ref No: 3874

Clinical Characteristics of Suicide-Related Drug and Toxic Substance Ingestions Presenting to the Emergency Department in 2024: A Retrospective Study

Süleyman Nogay[1]

[1]Malatya Turgut Özal University

Süleyman Nogay / Malatya Turgut Özal University

Introduction and Purpose: Acute poisonings are among the leading causes of emergency department admissions worldwide and are associated with significant morbidity and mortality. In particular, suicide-related drug and toxic substance ingestions are considered medical emergencies requiring rapid clinical evaluation and appropriate treatment. Determining the demographic and clinical characteristics of these cases is important for identifying risk factors and improving clinical management.

Materials and Methods: In this retrospective study, adult patients presenting to the emergency department of Malatya Training and Research Hospital between January 1 and December 31, 2024, due to suicide-related drug or toxic substance ingestion were evaluated. Patients were selected from cases recorded with the ICD-10 diagnosis code X44 in the hospital information system. Demographic characteristics, types of toxic agents ingested, treatment methods applied, and clinical outcomes were analyzed. Statistical analyses were performed using IBM SPSS Statistics version 27.0.

Results and Conclusion: Results: A total of 90 patients who met the inclusion criteria were evaluated. Of the patients, 85.6% were female. The most frequent admissions occurred in winter (35.6%) and summer (30%). Psychiatric drugs (35.6%) were the most commonly misused agents, followed by analgesics (21.1%) and multiple drug ingestions (16.7%). Supportive treatment was administered to 54.4% of the patients, while activated charcoal, gastric lavage, and antidote therapies were used in some cases. A total of 76.7% of patients were followed in inpatient wards and 23.3% in intensive care units, and all patients were discharged with full recovery.Conclusion: Suicide-related toxic substance ingestions are common clinical conditions encountered in the emergency department. Early evaluation, appropriate supportive treatment, and close clinical monitoring play an important role in achieving favorable clinical outcomes.

Keywords: acute intoxication, suicide attempt, drug poisoning

Ref No: 3935

The Role of Acute Phase Reactants and Demographic Data in Predicting Mortality and Prognosis in Patients with Meningitis

İsmail Akçalı[1], Keziban Erenler[2]
[1]Malatya Turgut Özal University, Faculty of Medicine, Department of Emergency Medicine
[2]Malatya Education and Research Hospital, Department of Anesthesiology and Intensive Care

İsmail Akçalı / Malatya Turgut Özal University, Faculty of Medicine, Department of Emergency Medicine

Introduction and Purpose: Meningitis, whose incidence varies by region, remains a significant health problem, particularly in low-and middle-income countries. Early diagnosis and the timely initiation of antimicrobial therapy are among the most critical parameters determining prognosis. Laboratory parameters play a vital role in achieving an early diagnosis.In this study, we aimed to determine the predictability of mortality and prognosis in patients with meningitis in light of demographic characteristics and acute phase reactants.

Materials and Methods: This study was conducted through a retrospective analysis of the data of 41 patients who were hospitalized and treated with a pre-diagnosis of meningitis at Malatya Training and Research Hospital between December 2025 and March 2026. Data were obtained by screening the hospital automation system and patient files. The following data were recorded for all patients included in the study: age, gender, serum C-reactive protein (CRP) and albumin levels at admission, total duration of hospital stay (days), and in-hospital mortality status. Statistical analyses were performed using SPSS v26.0 software.

Results and Conclusion: The mean age of 41 patients was 68.02±14.40 years, and 31.7% were female. Median CRP was 8.5 mg/L, mean albumin was 2.94±0.52 g/dL, and median hospital stay was 7 days. Mortality occurred in 9.7% of patients. CRP levels were significantly higher and hospital stay was longer in patients with mortality (p=0.013 and p=0.001, respectively). CRP showed a moderate positive correlation with length of stay (r=0.457; p=0.003), while age was moderately associated with mortality (r=0.317; p=0.043).This study demonstrates that advanced age and a high systemic inflammatory response are directly associated with mortality in patients diagnosed with meningitis. High CRP levels were shown to be a statistically significant and robust biomarker for predicting both mortality risk and length of hospital stay. Low albumin levels and the high mean age of our patients play an important role in determining the prognosis. Consequently, elderly male patients with a high inflammatory load should be monitored more closely.

Keywords: Meningitis, C-reactive protein (CRP), Mortality

Ref No: 3951

Flail Chest

Murat Gür[1], Halil Kaya[1], Yeşim Işler[1], Melih Yüksel[1], Mehmet Oğuzhan Ay[1], Umut Ocak[1]

[1]University of Health Sciences, Bursa Yüksek İhtisas Training and Research Hospital, Department of Emergency Medicine, Bursa/Türkiye

Murat Gür / University of Health Sciences, Bursa Yüksek İhtisas Training and Research Hospital, Department of Emergency Medicine, Bursa/Türkiye

Introduction and Purpose: Flail chest, also known as 'flail chest', refers to blunt chest trauma. This type of chest injury, characterized by fractures in two or more adjacent ribs, occurs particularly after high-energy trauma such as severe traffic accidents, falls, or collisions.

Materials and Methods: A 79-year-old female patient was brought to the emergency department by ambulance after a non-vehicular traffic accident. Her medical history included hypertension and rheumatoid arthritis. Blood pressure measured at presentation was 110/50, respiratory rate: 18, saturation: 95, conscious, general condition fair. Abdominal examination was unremarkable, nm: normal, ss: rales present in right lung sounds. Laboratory values for our patient were ast: 165, alt: 168, wbc: 9830, hgb: 12.5. The aim of this study is to emphasize that early and supportive treatment is extremely important in cases where flail chest is detected. Otherwise, more serious problems that cause life-threatening complications may arise, and if treatment is delayed, cases may result in death. Imaging performed on our patient (Figures 1-2) revealed multiple rib fractures and accompanying hemothorax in the right hemithorax.Following this, the patient was referred to thoracic surgery and intensive care, and admitted to intensive care for further examination and treatment.

Figure 1



Figure 2



Results and Conclusion: As is well known, flail chest cases are easily recognizable by paradoxical chest movements. Approximately 5 to 15 percent of chest wall injuries develop into flail chest. This disease, characterized by the chest wall moving inward during inhalation and outward during exhalation, can be detected by symptoms such as respiratory distress. In some patients, this disease can be diagnosed by advanced imaging tests even without these symptoms. Indeed, in our case, although paradoxical breathing had not yet developed, the diagnosis was made by imaging and clinical examination. Patients with flail chest are at high risk of developing life-threatening complications such as pneumothorax, hemothorax, and shock. Protecting the airway is crucial in the initial intervention. Chest stabilization, early diagnosis, and early intervention are of vital importance in these patients.

Keywords: pneumothorax, hemothorax, flail chest

Ref No: 3981

Drug-induced hyponatremia presenting with reversible glossopharyngeal nerve palsy and bulbar dysfunction: a case report

Elif Yeşim Gündaş[1], MUHAMMED HAMDİ UYAR[1], Ahmet Melih Savaş[1], İsa Yıldırım[1], Ayhan Aköz[1]
[1]Aydın Adnan Menderes University Faculty of Medicine
İsa Yıldırım / Aydın Adnan Menderes University Faculty of Medicine

Introduction and Purpose: Hyponatremia is a common electrolyte disorder encountered in emergency departments and may present with a wide spectrum of neurological manifestations. Although most cases manifest with non-specific symptoms such as headache, confusion, nausea, or seizures, atypical focal neurological deficits may rarely occur and mimic central nervous system pathologies. These presentations may lead to unnecessary imaging, delayed diagnosis, and increased healthcare costs. We aimed to present a rare case of reversible glossopharyngeal nerve palsy and bulbar dysfunction associated with drug-induced hyponatremia.

Materials and Methods: A 73-year-old man presented to the emergency department with persistent hiccups and progressively worsening dysphagia for three days. His medical history included chronic obstructive pulmonary disease, coronary artery disease, anxiety disorder, hypertension, and polyneuropathy. He was receiving multiple medications including clopidogrel, metoprolol, sertraline, gabapentin, leflunomide, and venlafaxine. Physical examination revealed loss of the gag reflex and impaired swallowing without motor deficit or lateralizing neurological findings. Vital signs were stable. Cranial nerve examination suggested glossopharyngeal nerve involvement with sensory loss in the posterior third of the tongue. Laboratory evaluation demonstrated severe hyponatremia (Na^+: 121 mEq/L), while brain computed tomography and diffusion-weighted magnetic resonance imaging showed no acute pathology.

Results and Conclusion: Drug-induced hyponatremia causing reversible glossopharyngeal nerve palsy and bulbar dysfunction was suspected. The patient was treated with controlled administration of 3% hypertonic saline in the emergency observation unit. Serum sodium levels were closely monitored to avoid rapid correction. As sodium levels gradually improved, the patient's gag reflex, swallowing function, and hiccups resolved completely. After normalization of electrolyte levels and adjustment of medications, the patient was discharged without neurological sequelae. This case highlights that metabolic disturbances such as hyponatremia may present with atypical focal neurological findings. Emergency physicians should consider electrolyte abnormalities in the differential diagnosis of patients presenting with unexplained cranial nerve deficits.

Keywords: Hyponatremia, Glossopharyngeal nerve palsy, Dysphagia

Ref No: 4035

MERS Triggered by Recurrent Seizures in an Epileptic Adult

Levent Şahin[1], Barış Kaban[1], Meriç Aksin[1], Mehman Murvatzada[1]

[1]Kafkas Üniversitesi, Tıp Fakültesi, Acil Tıp AD

Levent Şahin / Kafkas Üniversitesi, Tıp Fakültesi, Acil Tıp AD

Introduction and Purpose: Mild Encephalitis/Encephalopathy with a Reversible Splenial Lesion (MERS) is a rare clinico-radiological syndrome typically reported in pediatric populations, characterized by transient lesions in the splenium of the corpus callosum. Adult cases are uncommon and are generally precipitated by infections, metabolic disturbances, or seizures.

Materials and Methods: We report the case of a 28-year-old woman with a known history of epilepsy who presented to the emergency department with recurrent seizures and secondary head trauma. Brain imaging revealed diffusion-restricted lesions in the splenium, consistent with MERS. The patient was successfully managed with anti-seizure medications and supportive care, achieving rapid clinical stabilization.

Diffusion-weighted MRI demonstrating hyperintense lesion in the splenium of the corpus callosum.

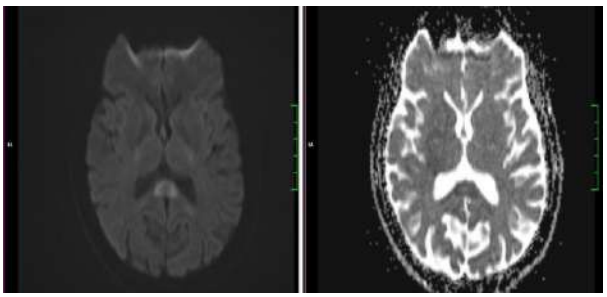

Non-contrast CT showing subtle hypodense area in the splenium.

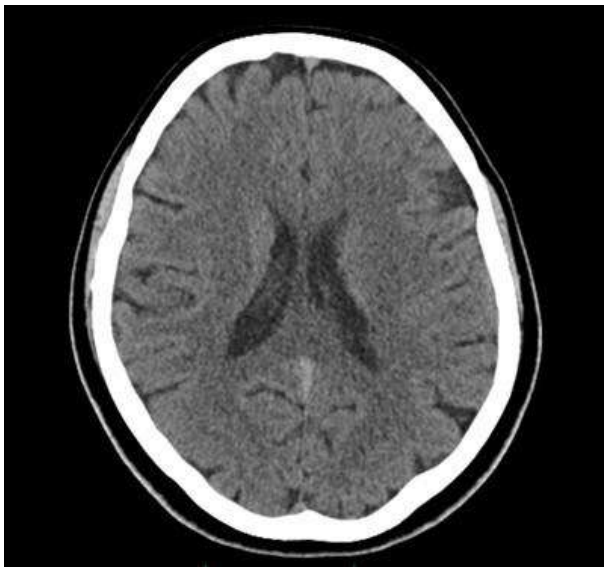

Results and Conclusion: This case highlights the rare association of recurrent epileptic seizures with MERS in adults and underscores the importance of recognizing this reversible entity to prevent unnecessary interventions. In these patients, MRI remains the gold standard for diagnosis. With seizure control and supportive care, patients generally show rapid recovery.

Keywords: Epilepsy, Generalized seizures, MERS

Ref No: 4087

The Hidden Cause of Syncope: A Case of Subclavian Steal Syndrome in the Emergency Department

Salih KARAKOYUN[1], Emre ERDEM[1], Yakup BİRLİK[1]

[1]Düzce University School of Medicine, Department of Emergency Medicine, Düzce, Turkey.

Salih KARAKOYUN / Düzce University School of Medicine, Department of Emergency Medicine, Düzce, Turkey.

Introduction and Purpose: Syncope is a common yet diagnostically challenging presentation in the emergency department (ED), with a broad and heterogeneous differential diagnosis. While most cases are benign or cardiogenic, rare vascular etiologies such as subclavian steal syndrome (SSS) may be overlooked. We aim to emphasize SSS as an uncommon but clinically significant

cause of syncope in emergency medicine practice and to highlight the importance of careful physical examination in raising diagnostic suspicion.

Materials and Methods: A 51-year-old female patient with a history of diabetes mellitus and hypertension was admitted to the ED with sudden-onset chest pain followed by approximately 10 minutes of loss of consciousness while standing. She reported recurrent episodes of dizziness and syncope over the past six years. On initial evaluation, she was conscious, oriented, and cooperative. Vital signs revealed a temperature of 36.1°C, heart rate of 100 beats/min, blood pressure of 180/90 mmHg, and oxygen saturation of 97% on room air. Neurological examination showed no focal deficits. However, vascular examination revealed a diminished left radial pulse. Repeat blood pressure measurement demonstrated a significant inter-arm difference (left arm: 97/65 mmHg; right arm: 160/79 mmHg). Electrocardiography and echocardiography were within normal limits. Brain computed tomography, diffusion-weighted MRI, and CT angiography showed no evidence of acute cerebrovascular pathology or large vessel occlusion. Aortic angiography revealed significant stenosis of the left subclavian artery.

“The stenotic segment of the left subclavian artery is demonstrated by the arrow.”



“The stenotic segment of the left subclavian artery is demonstrated by the arrow. ”

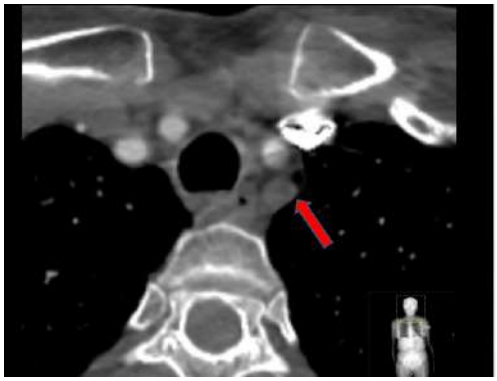

Results and Conclusion: Based on recurrent syncope, inter-arm blood pressure discrepancy, and diminished left radial pulse, the patient was diagnosed with subclavian steal syndrome and admitted for further vascular evaluation and management. This case highlights that SSS should be considered in patients presenting with unexplained syncope, particularly when accompanied by recurrent dizziness and asymmetric upper extremity blood pressures. Thorough physical examination, including bilateral blood pressure measurement and pulse assessment, is essential for early recognition. Prompt diagnosis in the ED can prevent misdiagnosis and guide appropriate imaging and management strategies.

Keywords: Inter-arm blood pressure difference, Subclavian steal syndrome, Syncope

---

Ref No: 4117

The Prognostic Value of Biochemical Markers in Predicting Length of Hospital Stay in Electrical Injuries

Ömer ÖZCAN1

1Malatya Turgut Özal University, Faculty of Medicine, Department of Emergency Medicine,

Ömer ÖZCAN / Malatya Turgut Özal University, Faculty of Medicine, Department of Emergency Medicine,

Introduction and Purpose: Electrical shock is an important cause of trauma affecting multiple organ systems, with clinical presentations ranging from mild skin lesions to severe conditions such as cardiac arrhythmias, muscle necrosis, rhabdomyolysis, and acute kidney injury. This variability complicates patient evaluation and management in the emergency department. The extent of tissue damage depends on the intensity, duration, and pathway of the electrical current. Injury to muscle and myocardial tissue may elevate biochemical markers such as creatine kinase (CK), CK-MB, and aspartate aminotransferase (AST). Kidney injury secondary to rhabdomyolysis is reflected by increased blood urea nitrogen (BUN) and creatinine levels.This study aimed to evaluate the demographic and laboratory characteristics of adult patients presenting with electrical shock and to investigate their relationship with hospitalization and length of stay.

Materials and Methods: This retrospective study included 25 patients aged ≥18 years diagnosed with electrical shock. Demographic data, clinical outcomes, and laboratory parameters were obtained from hospital records. Parametric data were expressed as mean ± standard deviation,

and non-parametric data as median (IQR). Independent samples t-test, Mann–Whitney U test, and Spearman correlation analysis were used. Statistical significance was set at $p < 0.05$.

Results and Conclusion: Sixty percent of patients were male, with a mean age of 33±10.95 years. Eighteen patients were discharged, and seven were hospitalized. CK, CK-MB, and AST levels showed strong positive correlations with length of hospital stay ($r=0.728–0.792$; $p < 0.001$). Creatinine and urea levels were also positively correlated with hospitalization duration. Significant correlations were found among creatinine, CK, CK-MB, and AST, and gender differences were observed in creatinine, hemoglobin, and platelet valuesCK, CK-MB, AST, urea, and creatinine levels are associated with hospital stay duration and may help predict disease severity. Early evaluation may aid in identifying high-risk patients.

Keywords: Electrical shock, rhabdomyolysis, creatine kinase

Ref No: 4128

An Endocrine Emergency That May Be Overlooked in the Emergency Department

Ekrem Bulut[1], Merve Bulut[1], Ayça Çalbay[1]

[1]Atatürk University Faculty of Medicine

Ekrem Bulut / Atatürk University Faculty of Medicine

Introduction and Purpose: Sodium–glucose cotransporter-2 (SGLT2) inhibitors are widely used agents in the treatment of type 2 diabetes mellitus. However, they may cause atypical and life-threatening euglycemic diabetic ketoacidosis (EDKA), in which blood glucose levels are normal or only mildly elevated (usually < 250 mg/dL). The absence of marked hyperglycemia may delay diagnosis in the emergency department. We present the management of a case of EDKA triggered by infection.

Materials and Methods: A 55-year-old woman with diabetes mellitus, using metformin and empagliflozin, presented to the emergency department with nausea, vomiting, and fatigue. On examination, she was dehydrated and tachycardic (110 bpm). Capillary blood glucose was 185 mg/dL. Hydration was initiated with a preliminary diagnosis of acute gastroenteritis; however, arterial blood gas analysis was obtained after the patient developed deep and rapid breathing consistent with Kussmaul respiration. Arterial blood gas revealed pH 7.15 and HCO_3 10 mEq/L. Urinalysis showed 3+ ketones, and blood ketone level was 5.2 mmol/L. The patient was diagnosed with EDKA due to high anion gap metabolic acidosis. The SGLT2 inhibitor was

discontinued, and guideline-directed intravenous fluid resuscitation, dextrose, and insulin infusion were initiated. After improvement of acidosis, the patient was admitted to the endocrinology intensive care unit.

Results and Conclusion: Tintinalli and UpToDate state that SGLT2 inhibitors lower blood glucose by inducing glucosuria but may trigger ketogenesis by reducing insulin secretion and increasing glucagon release. Infection or dehydration can accelerate this process. Rosen's Emergency Medicine emphasizes that in patients using SGLT2 inhibitors with unexplained metabolic acidosis, blood and urine ketone levels should be evaluated even when glucose levels are normal. This case highlights the importance of maintaining a high index of suspicion for ketoacidosis in emergency practice despite normoglycemia.

Keywords: SGLT2 Inhibitor, normal glucose levels, ketoacidosis

---

Ref No: 4133

Association of the BUN/Creatinine Ratio with 30-Day Mortality and Its Diagnostic Performance in Non-Traumatic Subarachnoid Hemorrhage

Muhammed Eyyüb Polat[1], Beyzanur Kartal[2]

[1]Malatya Tutrgut Ozal University, Malatya/Türkiye
[2]Inonu University, Faculty of Medicine, Department of Radiology, Malatya, Türkiye

Muhammed Eyyüb Polat / Malatya Tutrgut Ozal University, Malatya/Türkiye

Introduction and Purpose: Subarachnoid hemorrhage (SAH) is a severe neurological emergency with high morbidity and mortality, where early risk stratification is essential. Easily accessible biochemical markers are increasingly used alongside clinical and radiological scores to predict prognosis. This study aimed to assess the association between the blood urea nitrogen (BUN)/creatinine ratio and 30-day mortality, and to evaluate its predictive performance in patients with non-traumatic SAH presenting to the emergency department.

Materials and Methods: This retrospective observational study included patients with imaging-confirmed non-traumatic SAH who presented to the emergency department over the past two years. Demographic and laboratory data were obtained from the hospital information system. Evaluated parameters included WBC, hemoglobin, platelet count, BUN, creatinine, glucose, albumin, and sodium. The BUN/creatinine ratio was calculated, and serum osmolarity was derived using a standard formula. Patients were grouped according to 30-day mortality. Group

comparisons were performed using the Mann-Whitney U test due to non-normal distribution. The predictive performance of the BUN/creatinine ratio was evaluated by ROC analysis, and the optimal cut-off value was determined using the Youden index.

Results and Conclusion: Results:A total of 40 patients were included, comprising 24 (60%) males and 16 (40%) females. The 30-day mortality rate was 12.5%. The BUN/creatinine ratio was significantly associated with mortality (p=0.043), with higher values in non-survivors. No significant associations were observed between mortality and other laboratory parameters, including WBC, Hb, PLT, BUN, creatinine, glucose, albumin, sodium, and serum osmolarity (all $p > 0.05$). ROC analysis showed that the BUN/creatinine ratio had significant discriminative ability for predicting mortality (AUC=0.783, 95% CI: 0.649-0.917, p=0.043). The optimal cut-off value was 53.1, with a sensitivity of 60% and specificity of 80%.Conclusion:The BUN/creatinine ratio was significantly associated with 30-day mortality in non-traumatic SAH and showed acceptable discriminative performance. As a rapid, inexpensive, and readily available parameter in the emergency department, it may be useful for early risk stratification and clinical decision-making. Larger, multicenter prospective studies are needed to confirm these findings.

Figure 1. Receiver operating characteristic (ROC) curve of the BUN/creatinine ratio for predicting mortality.

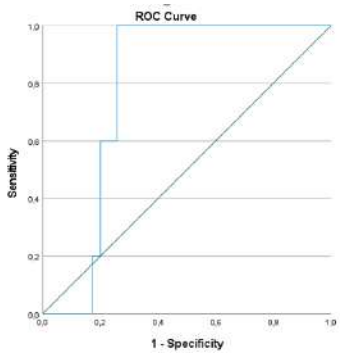

Table 1. Descriptive statistics and distribution characteristics of laboratory parameters

Table 1. Descriptive statistics and distribution characteristics of laboratory parameters

Variables	n	p value	SD	mean	median	IQR 25%	IQR 75%
WBC (×10³/µL)	40	0,012			11,2	8,2	14,9
Hb (g/dL)		0,134	±0,2	13,3			

PLT (×10³/µL)	0,993	±14,8	248,6			
BUN (mg/dL)	<0,001			42,1	30,3	50,3
Creatinine (mg/dL)	<0,001			0,8	0,7	1
Glucose (mg/dL)	0,001			159	133	199
Albumin (g/dL)	<0,001			4	3,6	4,1
Na^+ (mmol/L)	<0,001			139	136	141
BUN/Creatinine ratio	0,001			44,7	35,8	53,9
Serum Osmolarity (mOsm/kg)	0,001			300	294	307

Keywords: Subarachnoid hemorrhage, BUN/creatinine ratio, prognosis

Ref No: 4136

Individualized Treatment Strategies in Intermediate-Risk Pulmonary Embolism: A Clinical Perspective

BURCU YORMAZ[1]

[1]Selcuk University Medicine Faculty Department of Chest Disease,Konya,Turkıye

BURCU YORMAZ / Selcuk University Medicine Faculty Department of Chest Disease,Konya,Turkıye

Introduction and Purpose: Intermediate-risk pulmonary embolism (PE) represents a clinically challenging group due to variable disease progression and lack of clear treatment guidelines. While anticoagulation remains the cornerstone of therapy, the role of advanced reperfusion strategies continues to evolve. This study aims to evaluate individualized treatment approaches in intermediate-risk PE patients.

Materials and Methods: A literature-based clinical review was conducted focusing on intermediate-risk PE characterized by right ventricular dysfunction without hemodynamic instability. Current evidence regarding catheter-directed thrombolysis, systemic thrombolysis,

and mechanical thrombectomy was analyzed. Clinical indicators of deterioration were also evaluated**.**

Results and Conclusion: Intermediate-risk PE patients demonstrated heterogeneous outcomes. Advanced reperfusion strategies showed early improvement in right ventricular function and hemodynamic parameters; however, their impact on long-term mortality remains uncertain. Clinical deterioration markers, including worsening biomarkers and imaging findings, were crucial in identifying patients who may benefit from intervention.In conclusion, management of intermediate-risk PE should be individualized and guided by dynamic clinical assessment rather than fixed protocols. Future prospective studies are required to define optimal treatment pathways.

Keywords: Thrombolysis; Thrombectomy; Individualized Treatment

---

Ref No: 4152

The Great Mimicker's Silent Strike: Aortic Dissection Masquerading As Acute Ischemic Stroke

Ahmet Celal ÖZSOY[1]

[1]University of Health Sciences, Sanliurfa Mehmet Akif Inan Training and Research Hospital, Department of Emergency Medicine

Ahmet Celal ÖZSOY / University of Health Sciences, Sanliurfa Mehmet Akif Inan Training and Research Hospital, Department of Emergency Medicine

Introduction and Purpose: ABSTRACTIntroduction: Aortic dissection (AD) is a life-threatening medical emergency characterized by the separation of the aortic wall layers. Often called the "great mimicker," AD can present with a wide range of symptoms that overlap with conditions like acute coronary syndrome or pulmonary embolism. While the classic presentation involves tearing chest or back pain, up to 38% of cases go unnoticed during initial evaluations due to atypical symptoms or the complete absence of pain.

Figure 1: The dissection flap in the ascending aorta is indicated by a red arrow

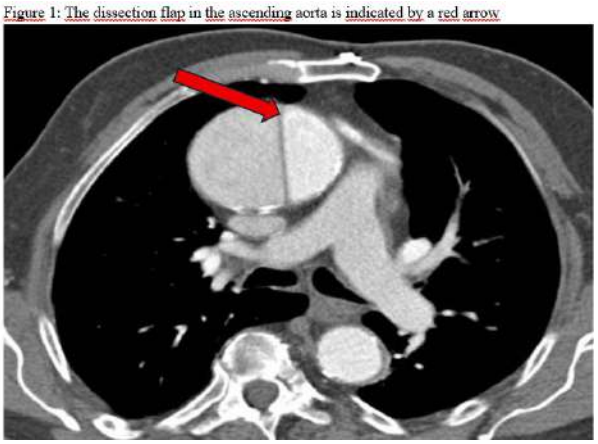

Figure 1: The dissection flap in the ascending aorta is indicated by a red arrow

Figure-2: The dissection flap in the left carotid artery is indicated by a red arrow

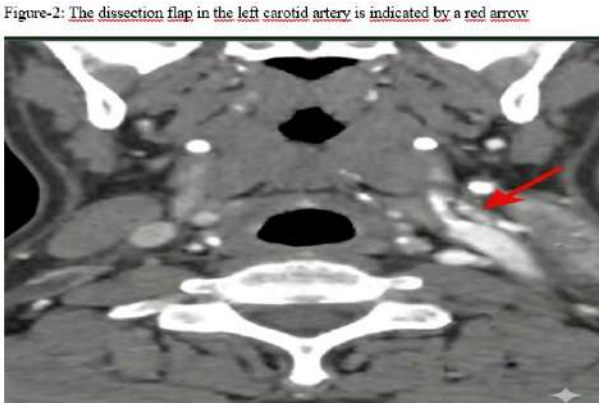

Figure-2: The dissection flap in the left carotid artery is indicated by a red arrow

Materials and Methods: Case Presentation: A 62-year-old male with a history of hypertension presented to the emergency department with acute right-sided weakness and aphasia. Notably, the patient reported no thoracic, back, or abdominal pain. During the physical examination, a significant pulse discrepancy was identified: the right radial pulse was strong, while the left was markedly diminished. Although initial brain CT was clear, CT angiography revealed a Stanford Type A aortic dissection originating in the ascending aorta and extending into the left carotid

artery. MRI confirmed extensive acute ischemic infarction in the left hemisphere. Upon diagnosing cerebral hypoperfusion secondary to AD, planned thrombolytic therapy—which would have been catastrophic—was canceled, and the patient was rushed to cardiovascular surgery.

Results and Conclusion: Conclusion: Painless aortic dissection presents a major diagnostic challenge, as neurological symptoms can overshadow the underlying vascular pathology. This case emphasizes the critical importance of performing a complete physical examination, including checking for pulse discrepancies, in patients presenting with stroke symptoms. Maintaining a high index of suspicion for AD is vital to avoid contraindicated treatments like thrombolytics and to ensure timely, life-saving surgical intervention.

Keywords: Aortic dissection, Acute ischemic stroke mimic, Stanford Type A

Ref No: 4202

Diagnosis and treatment of nerve injuries.

Metin Görgü[1], Şükrü Burak Tönük[1], Figen Coşkun[2]

[1]Abant İzzet Baysal University
[2]Dokuz Eylül University Emergency Department

Figen Coşkun / Dokuz Eylül University Emergency Department

Introduction and Purpose: Peripheral and facial nerve injuries are frequently encountered in traumas caused by sharp objects. Primary and early primary repair is crucial for functional recovery in nerve injuries. Therefore, diagnosis at the initial presentation at the emergency room is important. Nerve injuries are one of the clinical conditions that can sometimes be overlooked in patients, leading to significant functional loss, morbidity and to legal problems. Knowledge of the affected anatomical regions and current treatment methods will contribute to improved clinical outcomes. In this study, we retrospectively evaluated the diagnostic methods, most frequently affected anatomical regions, treatment approaches, and outcomes of facial and peripheral nerve injuries seen in our emergency department.

Materials and Methods: This study included 101 patients treated for facial and peripheral nerve injury. Amputations and brachial plexus injuries were excluded from the study. Patients were evaluated in terms of age, gender, injury localization, affected nerves, and outcomes. The mean age of the patients was 41, with 84 male (83%) and 17 female (17%). The majority of injuries (96%) were located in the upper extremities. The most frequently injured nerves were the digital nerves at the finger level (40%), followed by median (19%) and ulnar nerve injuries (19%). Facial nerve injuries were less common (4%). Injuries were mostly due to penetrating trauma and lacerations (98%). Primary repair was the most common treatment (%95), while nerve grafting and other surgical methods were preferred in selected cases. All patients underwent a physical therapy and rehabilitation program targeting the injured organs for the necessary duration. Rehabilitation programs included patient education, edema and pain control, range of motion maintenance and gentle stretching exercises, muscle strength maintenance and enhancement exercises, and sensory re-education. Hot/cold applications, electrical stimulation, bandaging, and orthotics were applied for these purposes. Treatment duration varied depending on the needs. The good results were 61%.

Results and Conclusion: Early diagnosis and appropriate treatment approach in nerve injuries are critically important for functional recovery. The high frequency of upper extremity and digital nerve injuries in trauma patients necessitates increasing clinical awareness regarding these areas. Morbidity can be minimized with timely, correct, and atraumatic surgical techniques and follow-up physical therapy rehabilitation.

Keywords: nerve injury, surgery, rehabilitation

Ref No: 4230

Case Report: Anaphylaxis - The Usual Suspects: Propofol, Fentanyl, Rocuronium, Methylprednisolone

Ahmet Gültekin[1], Serhat Örün[2], İlker Yıldırım[1], Sercan Bıçakçı[2], Cavidan Arar[1]

[1]Department of Anesthesiology and Reanimation, Tekirdağ Namik Kemal University Faculty of Medicine, Tekirdag, Türkiye
[2]Department of Emergency Medicine, Tekirdağ Namik Kemal University Faculty of Medicine, Tekirdag, Türkiye

Ahmet Gültekin / Department of Anesthesiology and Reanimation, Tekirdağ Namik Kemal University Faculty of Medicine, Tekirdag, Türkiye

Introduction and Purpose: Systemic glucocorticoids are commonly used to suppress allergic symptoms.(1) Allergic reactions to steroids were first reported in the 1950s.(2) Despite their anti-inflammatory and immunosuppressive properties, both immediate-type (Type I) and non-immediate-type (non-Type I) hypersensitivity reactions have been reported. The estimated prevalence of immediate-type hypersensitivity reactions ranges between 0.1% and 0.3%. Authentic corticosteroid allergy is a rare finding, with most validated cases involving reactions to additives (excipients). Methylprednisolone sodium succinate is the most frequently administered glucocorticoid in the perioperative period.(3) Neuromuscular blocking agents (rocuronium, succinylcholine) and antibiotics (penicillin derivatives and cefazolin) are among the most common causes of perioperative anaphylaxis.(4)

Materials and Methods: A 36-year-old female patient with a history of two cesarean sections and ectopic pregnancy surgery presented for tubal ligation. During general anesthesia induction, she developed anaphylaxis, was intubated, and treated in the intensive care unit for three days. (Induction agents included intravenous propofol, fentanyl, rocuronium, and methylprednisolone.) She was discharged with a diagnosis of rocuronium hypersensitivity.Twenty days later, she presented to our neurology clinic with headache, and contrast-enhanced cranial MRI was requested. Due to her anaphylaxis history, intravenous methylprednisolone was administered in the MRI unit. Subsequently, she developed hemodynamic instability and respiratory distress. Immediate 0.5 mg intramuscular adrenaline was given, and a code blue was initiated. She was monitored (SpO_2: 75%, NIBP: 90/50 mmHg, HR: 138 bpm) and transferred to the emergency department.In the emergency department, persistent instability and hypoxia required two additional 0.5 mg intramuscular adrenaline doses, intravenous fluids, and adjunctive treatments. As oxygen saturation did not improve and blood gases worsened, adrenaline infusion was started, and the patient was intubated and transferred to intensive care. After appropriate treatment and ventilation, she was extubated on day two and transferred to the inpatient unit.

Figure 1: Arterial blood gas monitoring

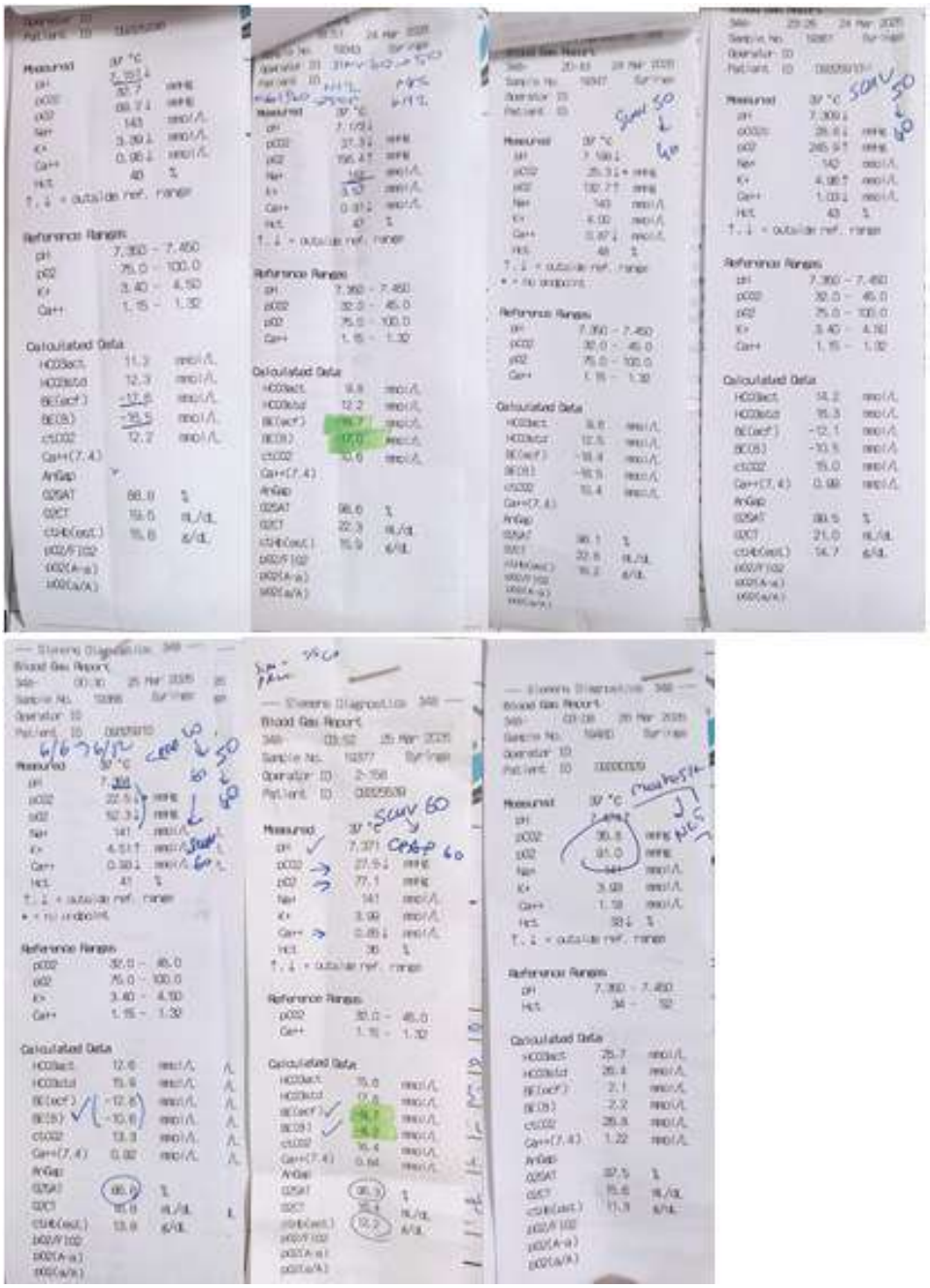

Results and Conclusion: Skin prick and intradermal tests should ideally be performed at least 4–6 weeks after the initial reaction to reduce false negatives.(4) Until results are available, all potential agents should be considered suspect.

Keywords: Anaphylaxis, Methylprednisolone, Rocuronium

Ref No: 4231

Validation of a Deep Learning Based Model APPENDIXPERT for the Detection of Acute Appendicitis on Abdominal CT in the Emergency Department

Cüneyt Arıkan[1], Öyküm Deniz Koygun[1], Aleyna Kurnaz[1], Canan Altay[2], Bedriye Müge Sönmez[1], Hülya Ellidokuz[3], Figen Coşkun[1]

[1]Dokuz Eylül University Faculty of Medicine, Department of Emergency Medicine
[2]Dokuz Eylül University Faculty of Medicine, Department of Radiology
[3]Dokuz Eylül University Faculty of Medicine, Department of Biostatistics and Medical Informatics

Öyküm Deniz Koygun / Dokuz Eylül University Faculty of Medicine, Department of Emergency Medicine

Introduction and Purpose: Acute appendicitis remains one of the most frequent surgical emergencies worldwide and may lead to severe complications such as perforation, peritonitis, abscess formation, and death. The increase in CT scans for diagnosing acute appendicitis and the resulting overcrowding in emergency departments are increasing the workload of physicians, bringing with it the risk of diagnostic errors or delays. This study aimed to evaluate the diagnostic performance of the APPENDIXPERT deep learning model in detecting acute appendicitis on abdominal CT scans.

Materials and Methods: This retrospective methodological study included adult patients presenting with non-traumatic abdominal pain to the ED of Dokuz Eylül University Hospital in 2025, who underwent both contrast-enhanced and non-contrast abdominal CT imaging. The APPENDIXPERT system (Version: BETA; HEALYSENSE Inc., İzmir, Turkey, 2025) is a deep learning-based algorithm designed to analyze abdominal CT images and detect regions suspicious for acute appendicitis. The model was trained on data from 395 patients comprising 34449 CT slices and validated using an independent dataset of 8612 slices. The gold standard for diagnosing acute appendicitis is pathological diagnosis of surgical specimens. Exclusion of acute appendicitis is performed by a specialist radiologist blinded to AI results.

Figure-1. Appendixpert analysis form example

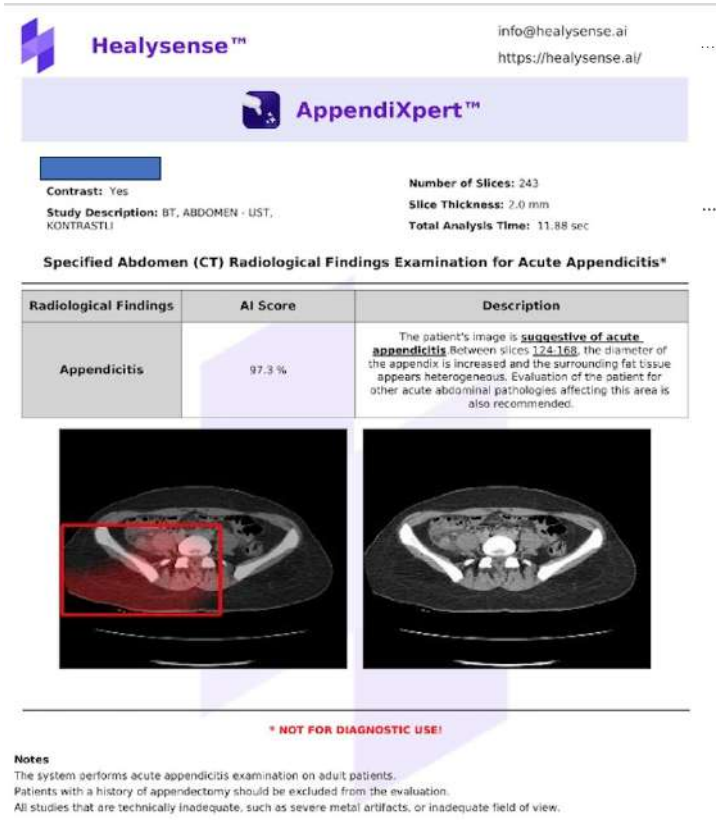

Results and Conclusion: A total of 1392 abdominal CT scans were analyzed, including 991 contrast-enhanced and 401 non-contrast studies. Acute appendicitis was radiologically and pathologically confirmed in 130 cases (119 contrast-enhanced and 11 non-contrast). The APPENDIXPERT model correctly identified 111 of these cases (102 contrast-enhanced and 9 non-contrast), yielding an overall sensitivity of 85.4%. Among 897 cases classified by the model as “no appendicitis” (572 contrast-enhanced and 325 non-contrast), 878 were correctly identified (555 contrast-enhanced and 323 non-contrast), corresponding to a specificity of 97.9%. The APPENDIXPERT deep learning model demonstrated high diagnostic accuracy in detecting acute appendicitis on abdominal CT scans, with particularly strong specificity in ruling out the disease. These findings suggest that AI-assisted tools may serve as valuable adjuncts in emergency radiology, improving diagnostic efficiency and supporting clinical decision-making.With further validation and integration into clinical practice, such models have the potential to enhance patient care by reducing diagnostic delays, optimizing resource utilization, and alleviating radiology workload in emergency departments.

Table-1.Diagnostic Performance of the APPENDIXPERT in Detecting Acute Appendicitis on CT

			Radiology & Pathology	**Radiology**	
			Yes (n)	No (n)	
Non-contrast CT	**Appendixpert**	Yes (n)	9	67	**11.8%**
		No (n)	2	323	**%99.4%**
			81.8%	**82.8%**	
Contrast-enhanced CT	**Appendixpert**	Yes (n)	102	317	**24.3%**
		No (n)	17	555	**97.0%**
			85.7%	**63.6%**	
Total	**Appendixpert**	Yes (n)	111	384	**22.4%**
		No (n)	19	878	**97.9%**
			85.4%	**69.6%**	

Keywords: Appendixpert, Acute appendicitis, Deep learning

Ref No: 4244

A Rare Condition in the Etiology of Persistent Low Back Pain: Spinal Epidural Abscess (SEA)

Muradiye Kısmet[1], Alanur Tarhan[1], Figen Coşkun[1]
[1]Dokuz Eylul Un. Faculty of Medicine
Muradiye Kısmet / Dokuz Eylul Un. Faculty of Medicine

Introduction and Purpose: Although spinal epidural abscess (SEA) is a rare condition,it may result in severe neurological sequelae and mortality.In recent years, the incidence has increased due to advancements in diagnostic modalities, a rise in invasive procedures, and the more frequent occurrence of predisposing risk factors.The classical triad for SEA —fever, low back pain, and neurological deficit—is reported to be present in only 10–15% of cases.In this report, we present a patient who was admitted with persistent low back pain resistant to analgesic therapy and was subsequently diagnosed with SEA through advanced imaging.

Materials and Methods: A 39-year-old female patient presented with severe low back pain and difficulty in movement.She denied any history of intravenous drug use, trauma, spinal surgery, or immunosuppressive conditions. It was learned that she had received intramuscular analgesic treatment at another center; however, her pain had not improved. Her body temperature and other vital signs, as well as examinations, were within normal limits. Imaging revealed a fluid collection in the epidural space extending from L3-S1 levels, causing compression of the thecal sac. Laboratory findings were as follows: WBC: 9,800/mm³, CRP: 208 mg/L, and ESR: 100 mm/h.Following contrast-enhanced lumbar MRI, the patient was diagnosed with SEA . She subsequently underwent surgery, including multilevel laminectomy and abscess drainage. Culture revealed growth of staphylococcus aureus. After six weeks of IV antibiotic therapy in the postoperative period, the patient was discharged in good health.

Results and Conclusion: SEA is often associated with diagnostic delays due to its initially nonspecific presentation. Pain that progresses despite analgesic treatment, elevated inflammatory markers, the presence of risk factors, or a recent history of invasive procedures should prompt consideration of SEA.Although diabetes mellitus, immunosuppression, intravenous drug use, spinal surgery, and epidural interventions are well-known risk factors, the literature also suggests that intramuscular injections and acupuncture may contribute to the development of SEA.Contrast-enhanced MRI is the gold standard diagnostic modality due to its high sensitivity and specificity. Staphylococcus aureus is reported to be responsible for approximately half of all cases. The absence of fever, a normal leukocyte count, or the lack of clear risk factors does not exclude an infectious etiology.

Keywords: Spinal Epidural Abscess, low back pain

Ref No: 4245

From bedside echo to successful resuscitation: intra-cpr thrombolysis in massive pulmonary embolism

Furkan Tayiz[1], Hilal Çıralıoğlu[1], Muhammed Sadettin İpek[1], Feriza Nur Babayiğit[1], Mehmet Gül[1]

[1]Emergency Medicine Department, Konya City Hospital, Türkiye

Feriza Nur Babayiğit / Emergency Medicine Department, Konya City Hospital, Türkiye

Introduction and Purpose: Acute pulmonary embolism (PE) is a clinical emergency characterized by a high risk of mortality and diagnostic complexity. Massive PE can rapidly lead to shock and cardiac arrest by causing sudden right ventricular dilatation and leftward septal shift, which severely decreases cardiac output. In such fulminant cases, conventional resuscitation is often insufficient. Current guidelines emphasize that if the cause of arrest is PE, thrombolytic therapy administered during resuscitation is life-saving.

Materials and Methods: A 45-year-old female patient was brought to the emergency department unconscious and hypotensive following a syncopal episode. While her ECG showed inferior ST-segment elevation, bedside echocardiography (ECHO) revealed an excessively dilated and akinetic right ventricle with a leftward septal shift. As preparations were underway, the patient went into cardiac arrest. Intravenous (IV) alteplase (100 mg) was administered via an accelerated protocol simultaneously with CPR. Return of spontaneous circulation (ROSC) was achieved at the 5th minute of administration. After stabilizing following recurrent arrests within the first 15 minutes, a CT angiography confirmed massive PE. The patient was discharged without any neurological sequelae on the 8th day of intensive care follow-up.

Results and Conclusion: Mortality rates in cardiac arrests due to massive PE can reach as high as 70%. Although successful outcomes with prolonged resuscitation have been reported in similar cases in the literature, the primary key intervention is early thrombolysis performed without interrupting resuscitation. Since catheter-directed or surgical methods are time-consuming, IV alteplase is strictly indicated in cases of suspected PE presenting with cardiac arrest. Thrombolytics administered during resuscitation dramatically increase survival by rapidly reducing the clot burden. Despite distracting findings in cases of multi-trauma or shock, the rapid identification of right heart strain via bedside ECHO ensures the timely administration of this life-saving treatment.

Keywords: massive pulmonary embolism, resuscitation, thrombolysis

Ref No: 4246

Rhabdomyolysis Developing Due to Hypothermia: A Case Report

Asiye ÖZKAN[1]

[1]Malatya Turgut Özal University, Faculty of Medicine, Department of Emergency Medicine,

Asiye ÖZKAN / Malatya Turgut Özal University, Faculty of Medicine, Department of Emergency Medicine,

Introduction and Purpose: Rhabdomyolysis is a clinical condition characterized by the release of intracellular contents into the circulation as a result of damage to skeletal muscle cells. Trauma, drugs, infections, intense exercise, and hypothermia are among the important causes of rhabdomyolysis. Although rhabdomyolysis due to hypothermia is rare, it can lead to serious complications. This article presents the case of a 40-year-old male shepherd who developed rhabdomyolysis after being exposed to a cold environment for a long time.

Materials and Methods: The patient reported that their urine had darkened. Blood parameters measured were: AST 443 U/L, ALT 105 U/L, LDH 1019 U/L, CK 25000 U/L, CK-MB 721 U/L, K 3.3 mmol/L, Ca 8.8 mg/Dl, Troponin < 0.100, INR 1.54, BUN 28.5 mg/Dl, Creatinine 0.98 mg/Dl. It was learned that liver and kidney function tests and electrolyte values were normal at the patient's visit three weeks prior.

Results and Conclusion: Rhabdomyolysis is a syndrome that develops as a result of damage to the muscle cell membrane, causing cellular contents to leak into the circulation (1).Hypothermic rhabdomyolysis can occur especially in individuals who remain in cold environments for a long time. Cold-induced vasoconstriction and decreased muscle perfusion can lead to muscle cell damage (4).Clinically, muscle pain, muscle tenderness, weakness, and dark urine may be observed (2).In the diagnosis of rhabdomyolysis, an increase in serum CK levels more than 5 times the normal level is an important criterion (5). In this patient, the CK value was found to be 25000 U/L. The most serious complication of rhabdomyolysis is acute kidney injury, which can develop in approximately 10–40% of cases (3).Aggressive fluid therapy initiated early in rhabdomyolysis reduces the development of acute kidney injury (6). Therefore, early diagnosis and aggressive fluid therapy are critically important. In this case, thanks to early diagnosis and rapid hydration therapy, no renal complications developed. In individuals who have been exposed to cold for a long time and experience symptoms such as muscle pain and dark urine, rhabdomyolysis should always be considered. Early diagnosis and appropriate fluid therapy can prevent the development of serious complications.

Keywords: Rhabdomyolysis, hypothermia, myoglobinuria

Ref No: 4314

Multivessel spontaneous coronary artery dissection in the postpartum period: a case report

Dicle BULAK[1], Ensar OLCAY[1], Damla ANBARLI METIN[1], Murat KOYUNCU[1], Busra BILDIK[1], Bora CEKMEN[1]

[1]Karabuk University, Faculty of Medicine, Department of Emergency Medicine

Dicle BULAK / Karabuk University, Faculty of Medicine, Department of Emergency Medicine

Introduction and Purpose: Spontaneous coronary artery dissection (SCAD) is a rare but potentially fatal cause of acute coronary syndrome, particularly in young women during pregnancy and the postpartum period. Because postpartum SCAD may present with multivessel involvement, malignant arrhythmias, and initially subtle findings, early recognition can be challenging. This case report aimed to present a postpartum case of multivessel SCAD with initially non-diagnostic electrocardiogram (ECG) and troponin findings and to highlight the diagnostic and management difficulties encountered in the emergency department.

Materials and Methods: A 30-year-old woman who had undergone vaginal delivery 30 days earlier presented to the emergency department with constricting chest pain radiating to the left arm. She was hemodynamically stable on admission. The initial ECG showed minimal ST-segment depression in leads I and aVL (Figure 1), and the initial troponin level was normal. Bedside echocardiography revealed an ejection fraction of 39% and diffuse apical hypokinesia. During follow-up, serial ECGs demonstrated new T-wave inversions in leads V1–V3 (Figure 2), and troponin levels increased. With a preliminary diagnosis of non-ST-segment elevation myocardial infarction, coronary angiography was performed because of worsening chest pain. Angiography showed a long-segment dissection extending from the left main coronary artery to the left anterior descending and circumflex arteries, with TIMI 0 flow. During the procedure, recurrent ventricular fibrillation occurred, requiring defibrillation, and two drug-eluting stents were implanted in the left anterior descending artery-left main coronary artery segment. The patient died during the 16th hour of intensive care follow-up due to recurrent ventricular arrhythmias.

Figure 1. First ECG

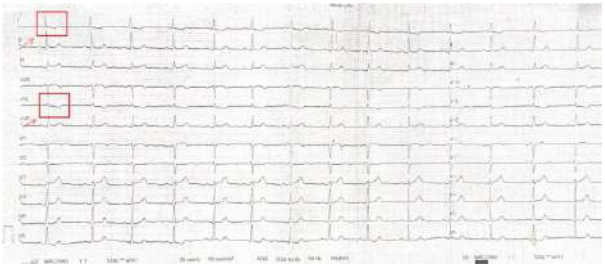

The red arrow and rectangular box indicate minimal ST segment depression in the DI-aVL derivations.

Figure 2. Control ECG

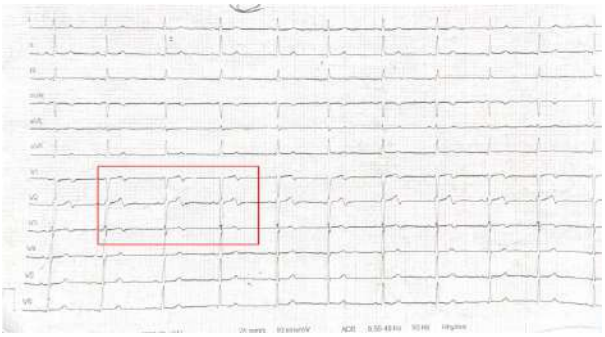

The red rectangle contains newly developed T-wave negativity in derivations V1-2-3.

Results and Conclusion: Postpartum spontaneous coronary artery dissection is a clinical entity that should always be considered in the differential diagnosis of chest pain in young women, as it may initially present with normal ECG and troponin findings yet rapidly deteriorate and lead to fatal outcomes. In the presence of persistent chest pain in the postpartum period, serial biomarker elevation, dynamic ECG changes, or regional wall motion abnormalities on echocardiography, early cardiology consultation and timely invasive evaluation should not be delayed. This case underscores that even when initial investigations are misleading, careful monitoring, repeated assessment, and a high index of clinical suspicion are crucial for early diagnosis and management.

Keywords: Postpartum Period, Coronary Vessel Dissection, Acute Coronary Syndrome.

Ref No: 4360

Clinical Utility of CT-Based Right Ventricular Dysfunction in Risk Stratification of Acute Pulmonary Embolism

Burcu Yormaz[1]

[1]Selcuk University Medicine Faculty Department of Chest Disease,Konya,Turkıye

Burcu Yormaz / Selcuk University Medicine Faculty Department of Chest Disease,Konya,Turkıye

Introduction and Purpose: Rapid and accurate risk stratification is essential in the management of acute pulmonary embolism (PE). Computed tomography (CT) is widely used for diagnosis and provides additional information regarding right ventricular (RV) function. This study aims to evaluate the clinical utility of CT-derived parameters of RV dysfunction in predicting disease severity and guiding treatment decisions

Materials and Methods: A review of clinical studies evaluating CT findings associated with RV dysfunction was performed. Parameters including RV/left ventricular (LV) ratio, interventricular septal deviation, and contrast reflux into the inferior vena cava were analyzed. These findings were compared with echocardiographic parameters, cardiac biomarkers, and clinical outcomes.

Results and Conclusion: CT-derived indicators of RV dysfunction, particularly an RV/LV ratio greater than 0.9, were strongly associated with increased risk of clinical deterioration and mortality. CT imaging provided rapid and reproducible assessment of cardiac involvement, especially in emergency settings where echocardiography may not be immediately available.In conclusion, CT imaging plays a dual role in both diagnosis and risk stratification of PE. Incorporating CT-based RV assessment into routine clinical practice may improve early triage and management decisions.

Keywords: Pulmonary Embolism; Computed Tomography; Right Ventricular Dysfunction

Ref No: 4471

Pan-Immune-Inflammation Value and Clinical Outcomes in Pulmonary Embolism

Lütfi Anıl Güdek[1], Ensar Olçay[1], Adem Boz[1], Akın Seçkin[1], Büşra Bildik[1], Bora Çekmen[1]
[1]Karabuk University, Faculty of Medicine, Department of Emergency Medicine
Lütfi Anıl Güdek / Karabuk University, Faculty of Medicine, Department of Emergency Medicine

Introduction and Purpose: Inflammation plays a central role in the development and progression of venous thromboembolism.The Pan-Immune-Inflammation Value (PIV), calculated from neutrophil, platelet, monocyte, and lymphocyte counts, has emerged as a novel biomarker reflecting systemic inflammatory status. Although PIV has been associated with prognosis in various cardiovascular and oncological conditions, its role in patients with pulmonary embolism remains unclear. Therefore, this study aimed to evaluate the association of the PIV score with hospitalization, ICU admission, and in-hospital mortality in patients with pulmonary embolism.

Materials and Methods: Patients who were diagnosed with Pulmonary Embolism (PE) via computed tomography pulmonary angiography in the emergency department were included in the study. Demographic data (age, sex) and comorbidities (coronary artery disease, hypertension, diabetes mellitus, atrial fibrillation, and cerebrovascular disease) were recorded. Clinical outcomes, including hospitalization, intensive care unit (ICU) admission, length of hospital and ICU stay, and in-hospital mortality, were obtained from medical records.The Pan-Immune-Inflammation Value (PIV) was calculated using admission complete blood count parameters as follows: (neutrophil × platelet × monocyte) / lymphocyte.

Results and Conclusion: A total of 143 patients with PE were included. The median PIV was 545.75 (IQR: 295.36–1395.45). Hospitalization was required in 93.7% of patients, 42.7% were admitted to the ICU, and in-hospital mortality was 7.7%.No statistically significant difference in PIV values was observed between hospitalized and non-hospitalized patients ($p = 0.990$). Although higher PIV levels were noted in patients requiring ICU admission and in those who died during hospitalization, these differences did not reach statistical significance ($p = 0.102$ and $p = 0.233$, respectively). PIV values did not differ significantly according to PE localization ($p = 0.054$).Correlation analysis demonstrated a moderate positive relationship between PIV and length of hospital stay ($p < 0.001$), whereas no significant correlation was found between PIV and ICU length of stay ($p = 0.092$). In multivariable analysis, both age (OR: 1.03, $p = 0.029$) and PIV (per 100-unit increase; OR: 1.04, $p = 0.020$) were identified as independent predictors of ICU admission.Overall, although PIV was associated with longer hospital stay, it showed limited value in predicting major clinical outcomes. Further large-scale, prospective studies are needed to clarify its prognostic role.

Keywords: Pulmonary Embolism, PIV, prognosis

Ref No: 4475

Blunt Abdominal Trauma Presenting with an Abdominal Wall Hematoma in an Adolescent Patient: A Case Report

Barış ÇİÇEK[1], Nevzat HERGÜL[1], Gizem GİZLİ TAN[1]

[1]Van Yüzüncü Yıl University, Faculty of Medicine

Barış ÇİÇEK / Van Yüzüncü Yıl University, Faculty of Medicine

Introduction and Purpose: Blunt abdominal trauma is a frequent cause of emergency department admissions and may manifest with a spectrum of intra-abdominal or abdominal wall injuries. While abdominal wall hematomas are relatively uncommon in the adolescent population, they should be considered in the differential diagnosis for trauma patients presenting with localized abdominal pain and a palpable mass. We report the case of a 17-year-old male patient who presented to the emergency department following a traffic accident and was subsequently diagnosed with a hematoma of the right abdominal oblique muscle.

Materials and Methods: A previously healthy 17-year-old male was admitted to the emergency department after being involved in a traffic accident. On arrival, he was alert and oriented with a Glasgow Coma Scale score of 15. His vital signs were stable and within normal limits.The patient reported pain in his head, neck, and abdomen. Physical examination revealed a palpable, tender hematoma localized to the mid-inferior aspect of the right lateral abdominal wall. No guarding, rigidity, or rebound tenderness was noted.Computed tomography imaging revealed a hematoma confined to the right abdominal oblique muscle (Figure 1 and Figure 2). No intra-abdominal solid organ injury or free fluid was identified. Further systemic examination, including respiratory, pelvic, and neurovascular assessments, was unremarkable. The patient was admitted to the ward for conservative management and close clinical observation of the abdominal wall hematoma. **Figure 1**



Contrast-enhanced abdominal computed tomography demonstrating a well-defined intramuscular hematoma within the right abdominal oblique muscle.

figure 2

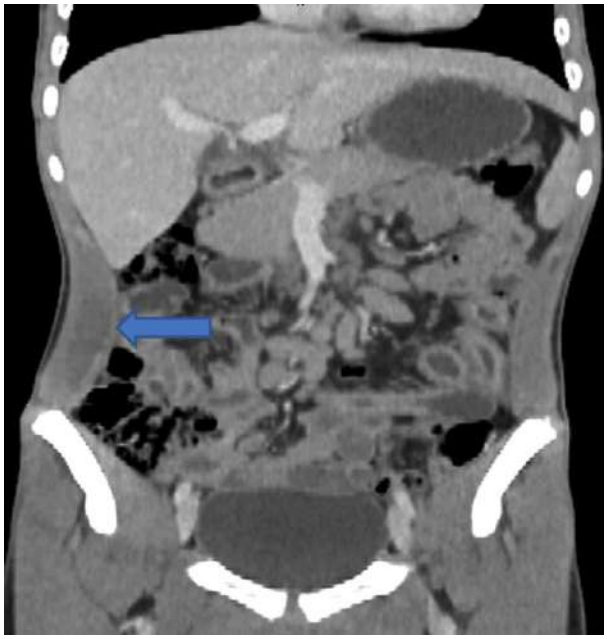

Coronal section demonstrating the hematoma (arrow)

Results and Conclusion: Abdominal wall hematomas following blunt trauma are a diagnostic challenge, particularly in adolescents where they are infrequently encountered. This case underscores the importance of considering abdominal wall injuries in patients with localized pain and a mass after trauma. Advanced imaging, particularly computed tomography, is invaluable for differentiating these hematomas from intra-abdominal injuries, thereby preventing unnecessary surgical exploration.This case highlights the critical role of meticulous physical examination and appropriate radiological evaluation in trauma patients with localized abdominal pain. Early and accurate recognition of an abdominal wall hematoma can prevent invasive procedures and guide effective conservative management

Keywords: Blunt abdominal trauma, Abdominal Wall Hematoma, abdominal oblique muscle.

Ref No: 4497

Central Retinal Artery Occlusion Presenting with Sudden Vision Loss: A Case Report

Onur Bozdağ[1], Elif Yıldız[2], Asel Hale Pilgeci[2], Bahadır Taşlıdere[1], Başar Cander[1]
[1]Bezmialem Vakıf University, Emergency Medicine.
[2]Bezmialem vakıf University, Medical Faculty.
Onur Bozdağ / Bezmialem Vakıf University, Emergency Medicine.

Introduction and Purpose: Central retinal artery occlusion (CRAO) is an ophthalmic emergency characterized by sudden, painless, and severe vision loss, most commonly affecting elderly individuals with underlying vascular risk factors such as hypertension, diabetes mellitus. In this report, we present a case of acute unilateral vision loss due to Central retinal artery occlusion (CRAO) in a patient with multiple vascular risk factors and recent discontinuation of antiplatelet therapy, highlighting the importance of etiological evaluation and secondary prevention.
Materials and Methods: A 70-year-old female was admitted to the emergency department with sudden onset, painless vision loss in the left eye. She reported a similar episode of vision loss in the same eye two days prior, lasting approximately two hours. Additionally, she described intermittent brief episodes of pain over the left temporal region in the preceding two days. Neurological examination revealed severe visual impairment in the left eye, with inability to perceive hand motion, while the right eye was intact. Confrontation testing demonstrated complete visual field loss in all quadrants of the left eye. Direct light reflex was present in the right eye, while no response was elicited in the left eye. No other focal neurological deficits were identified. Ophthalmologic evaluation demonstrated retinal edema and optic disc pallor, raising suspicion for acute central retinal artery occlusion (CRAO). Ultrasonography of the temporal artery was performed to differentiate giant cell arteritis; however, no diagnostic findings were obtained. Clinically, the patient was diagnosed with acute central retinal artery occlusion affecting the left eye, and hyperbaric oxygen therapy was recommended.

Results and Conclusion: Central retinal artery occlusion (CRAO) is a vision-threatening emergency. Patients typically present with sudden, painless, and profound unilateral vision loss, as seen in our case. The presence of vascular risk factors such as diabetes mellitus and coronary artery disease, along with recent discontinuation of antiplatelet therapy, likely contributed to an embolic event. Carotid imaging in this patient revealed moderate stenosis, unstable atherosclerotic plaques may serve as a source of microembolization leading to retinal artery occlusion.This case underscores the importance of rapid diagnosis, thorough etiological evaluation, and initiation of secondary prevention strategies, particularly antiplatelet therapy, to reduce the risk of further ischemic events.

Keywords: Sudden Vision Loss, Central Retinal Artery Occlusion, Hyperbaric Oxygen Therapy

Ref No: 4582

The Role of Oral Contraceptive Use and Recent Surgery in Mortality Among Women Under 35 Years of Age with Pulmonary Embolism

Bilal Kartal[1]

[1]Malatya Turgut Özal Üniversitesi Acil Tıp Anabilim Dalı

Bilal Kartal / Malatya Turgut Özal Üniversitesi Acil Tıp Anabilim Dalı

Introduction and Purpose: AbstractObjective:Pulmonary embolism (PE) is a life-threatening condition associated with significant morbidity and mortality. Although oral contraceptive (OC) use and recent surgical interventions are well-established risk factors for the development of PE, their impact on short-term mortality, particularly in young women, remains unclear. This study aimed to evaluate the effect of OC use and recent surgical history on 30-day mortality in women under 35 years of age diagnosed with PE.

Materials and Methods: Materials and Methods:This retrospective observational study was conducted in the Emergency Department of Malatya Training and Research Hospital. Female patients under 35 years of age diagnosed with PE between September 2020 and September 2025 were screened. Among 57 patients identified through ICD codes, 19 patients with radiologically confirmed PE and complete clinical data were included. OC use was defined as continuous use for at least 3 months prior to diagnosis, and recent surgery as any surgical procedure within the preceding 6 months. Demographic data, laboratory parameters, and arterial blood gas values at admission were analyzed. The primary outcome was 30-day mortality. Appropriate statistical tests were applied, and $p < 0.05$ was considered significant.

Results and Conclusion: Results:Of the 19 patients, 3 (15.8%) died and 16 (84.2%) survived. OC use was present in 31.6% of patients, while 15.8% had a history of recent surgery. Among all evaluated variables, only serum albumin levels were significantly associated with mortality. Patients who died had lower albumin levels compared to survivors (2.97 ± 0.32 g/dL vs 3.66 ± 0.51 g/dL, p=0.040). No significant associations were found between mortality and other laboratory or arterial blood gas parameters (all $p > 0.05$). Additionally, neither OC use nor recent surgical history was significantly associated with mortality (p=0.517 and p=0.422, respectively).Conclusion:In women under 35 years of age with PE, OC use and recent surgery do not appear to significantly affect short-term mortality. In contrast, low serum albumin may serve as a potential prognostic marker. Mortality in young PE patients may be more closely related to disease severity and physiological reserve rather than triggering risk factors. Larger studies are needed to confirm these findings.

Table 1. Demographic and Laboratory Characteristics of the Study Population

Variables	n	Mean	SD	Median	IQR	
					25%	75%
Yaş (yıl)		29,1	±1,1			
Albumin (g/L)		3,5	±0,1			
CRP (mg/L)				2,7	0,7	5,9
WBC (×10⁹/L)		12,1	±0,9			
Plt (×10⁹/L)		279,1	±14,7			
Hb (g/dL)		12,7	±0,4			
pO_2 (mmHg)	**19**	34,8	±3,6			
pCO_2 (mmHg)				37	34	42
pH				7,38	7,36	7,42
Laktat (mmol/L)				1,8	1,4	3,8
Troponin (ng/L)				0,1	0,1	0,3
D-Dimer (ng/mL)				2,7	1,7	6

Keywords: Pulmonary embolism, oral contraceptives, young women

Ref No: 4627

The Trap of Atypical Extremity Pain: Recognizing Hidden Substance Misuse in Complicated Soft Tissue Infections

Ali Küçükosmanoğlu[1], Ayla Mollaoğlu[1], Hakan Ateş[1], Mustafa Arar[1], Mehmet Gül[1]
[1]Emergency Medicine Department, Konya City Hospital, Türkiye
Ali Küçükosmanoğlu / Emergency Medicine Department, Konya City Hospital, Türkiye

Introduction and Purpose: The buprenorphine/naloxone combination (Suboxone), used in the treatment of substance use disorder, is designed for oral/sublingual administration; however, intravenous misuse can lead to serious complications. In this case, we present a patient who developed a soft tissue infection and concomitant venous thrombosis after dissolving and injecting the drug intravenously.

Materials and Methods: Case: A 26-year-old male presented with swelling and pain in the left antecubital region. Laboratory findings revealed a CRP level of 175 mg/L and a leukocyte count of 12,000/mm³, which decreased to 85 mg/L during follow-up. Ultrasonography demonstrated findings consistent with chronic thrombosis in the cephalic vein, as well as acute thrombus causing near-complete luminal occlusion in the axillary and brachial veins. Additionally, a hypoechoic area measuring approximately 40×27×80 mm (hematoma/abscess?) and diffuse subcutaneous edema were identified in the medial aspect of the arm. The patient was evaluated in a multidisciplinary setting involving orthopedics, infectious diseases, cardiovascular surgery, and plastic surgery. Debridement was performed, cultures were obtained, broad-spectrum antibiotic therapy was initiated, and anticoagulant treatment was recommended. Due to tissue loss and the need for reconstruction, the patient was referred to a center with microsurgical capabilities.

Results and Conclusion: The coexistence of acute and chronic thrombosis observed in this case demonstrates that vascular damage in patients with substance use disorder is cumulative and that repeated injections lead to irreversible impairment of the venous system. The management of such complex conditions requires a multidisciplinary approach, as intervention by a single specialty is insufficient. Early initiation of broad-spectrum empirical antibiotic therapy, aggressive surgical debridement, anticoagulation to reduce the risk of pulmonary embolism, and the use of microsurgical techniques to repair tissue defects are critical for improving prognosis and preventing amputation.In conclusion, follow-up of patients receiving addiction treatment should not be limited to psychiatric support alone; patients must be thoroughly informed about the medical risks associated with improper drug use. Healthcare professionals should consider hidden substance use in the differential diagnosis of patients presenting with atypical upper extremity pain and signs of infection, and should employ early vascular and radiological imaging methods.

Keywords: Intravenous drug use, venous thrombosis, suboxone

Ref No: 4701

Acute biliary pathology coincident with Abdominal aortic aneurysm: A simultaneous occurrence, critical role of physical examination and bedside ultrasound

Dr. Enes YILMAZ[1], Dr. Şamil Emin YALÇIN[1], Asst. Prof. Dr. Mevlana GÜL[1]

[1]Ataturk University Emergency Department

Dr. Şamil Emin YALÇIN / Ataturk University Emergency Department

Introduction and Purpose: Abdominal aortic aneurysm (AAA) is a life-threatening condition that often remains asymptomatic until rupture. It can present with non-specific symptoms, leading to diagnostic delays. In the emergency department, physical examination for right upper quadrant pain must not be limited to the symptomatic area; it should systematically cover all quadrants using a gentle technique. This report emphasizes the importance of meticulous physical examination and point-of-care ultrasound (POCUS) in the incidental bedside diagnosis of coincident life-threatening pathologies.

Materials and Methods: A 77-year-old male with hypertension and a recent lung biopsy history presented with three days of burning epigastric and right upper quadrant pain. Vital signs showed a temperature of 38.8°C and oxygen saturation of 89%. While respiratory examination was unremarkable, abdominal assessment initiated with gentle superficial palpation revealed localized tenderness in the right upper quadrant. Systematic expansion of the examination to all quadrants led to the incidental discovery of a pulsatile mass at the umbilical level. Bedside POCUS demonstrated minimal intrahepatic biliary ductal dilatation and concurrently detected a 45 mm infrarenal AAA. Laboratory results confirmed hyperbilirubinemia and elevated liver enzymes, while lipase and amylase were normal.

infrarenal aorta usg



Results and Conclusion: Computed tomography (CT) confirmed a 59 mm AAA and revealed dilated intrahepatic bile ducts with a calculus at the Ampulla of Vater, identifying two

independent, "coincident" pathologies. In conclusion, even when clinical markers strongly suggest a specific etiology like biliary disease, clinicians must remain vigilant. Starting abdominal palpation gently and utilizing POCUS are vital steps for detecting separate, potentially more lethal conditions like AAA that may coexist by chance.

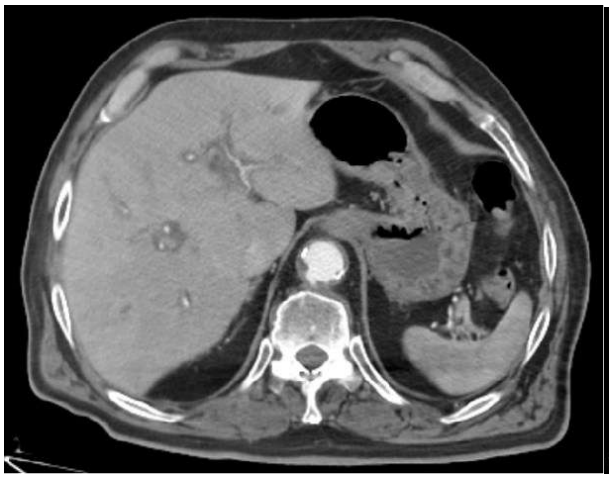

tomography1



tomography2

tomography3



Keywords: Abdominal aortic aneurysm, Cholangitis, Point-of-care ultrasound

Ref No: 4703

From Self to System: A Multidimensional Analysis of Well-Being and Burnout Among Intern Physicians

Zeynep Şenel[1], Esra İşler[1], Elif Gamze Ayvaz[1], Zeynep Altun[1], Sümeyra Kılıç[1], Mustafa Kaya[1], Ömer Avcı[2], Cüneyt Arıkan[2]

[1]Dokuz Eylül University Faculty of Medicine, Izmir, Türkiye
[2]Dokuz Eylül University Faculty of Medicine, Department of Emergency Medicine, Izmir, Türkiye

Ömer Avcı / Dokuz Eylül University Faculty of Medicine, Department of Emergency Medicine, Izmir, Türkiye

Introduction and Purpose: Emergency department (ED) training exposes intern physicians to demanding clinical, cognitive, and emotional environments, which may adversely affect their well-being. While individual resilience has traditionally been emphasized, increasing evidence highlights the critical role of system-level factors. This study aimed to evaluate intern physicians' well-being using a multidimensional framework integrating personal, systemic, and burnout-related domains.

Materials and Methods: This prospective cross-sectional study included intern physicians who completed their ED rotation at a tertiary academic center. A structured 20-item questionnaire based on the American College of Emergency Physicians wellness framework was used. The survey assessed personal well-being and self-care, system-related factors, and burnout using a 5-point Likert scale. Descriptive statistics, group comparisons, correlation analyses, and multivariable linear regression were performed.

Results and Conclusion: A total of 71 intern physicians were included. Mean scores were 26.37 ± 5.40 for personal well-being, 16.42 ± 4.70 for system-related factors, and 15.27 ± 3.85 for burnout. Female participants demonstrated significantly lower self-care scores (24.33 ± 4.34 vs. 28.11 ± 5.73, p=0.003) and lower total well-being scores (54.33 ± 10.42 vs. 61.00 ± 12.05, p=0.016) compared to males. Burnout showed a moderate correlation with personal well-being (r=0.49, $p < 0.001$) and a stronger correlation with system-related factors (r=0.59, $p < 0.001$). A multivariable linear regression model was constructed to identify independent predictors of burnout scores. Variables included personal well-being scores, system-related scores, age, and gender. In multivariable linear regression analysis, system-related factors remained a significant independent predictor of burnout ($\beta = 0.48$, $p < 0.001$), whereas personal well-being showed a weaker but still significant association ($\beta = 0.29$, $p = 0.012$). Gender was not an independent predictor after adjustment ($p > 0.05$). Intern physician well-being is influenced by both

individual and system-level factors, with system-related conditions demonstrating a stronger association with burnout. These findings support a shift from individual-focused interventions toward system-based strategies, including improvements in working conditions, team dynamics, and institutional support mechanisms

Table-1. Comparison of Scale Scores by Gender

Variable	Male (Mean±SD)	Female (Mean±SD)	p-value
Self-care	28.11 ± 5.73	24.33 ± 4.34	0.003
System	16.81 ± 4.77	15.73 ± 4.44	0.331
Burnout	16.08 ± 3.69	14.27 ± 3.89	0.050
Total Score	61.00 ± 12.05	54.33 ± 10.42	0.016

Keywords: Intern physicians, Burnout, Well-being

Ref No: 4770

Admission hyperglycemia and a composite glucose-age-blood pressure score for predicting DWI-confirmed ischemic stroke in the emergency department

Zülküf Sergen ÜNLÜ[1]

[1]Mersin City Training and Research Hospital

Zülküf Sergen ÜNLÜ / Mersin City Training and Research Hospital

Introduction and Purpose: Admission hyperglycemia is associated with adverse outcomes in acute ischemic stroke, yet most studies relied on clinical severity scales rather than radiologically confirmed injury. Diffusion-weighted imaging (DWI) provides objective confirmation of acute ischemia, and DWI-stratified glucose analyses remain scarce in emergency department (ED) literature. We aimed to investigate the association between admission glucose and DWI-confirmed ischemic stroke, evaluate a dose-response relationship, and explore whether combining glucose with age and systolic blood pressure (SBP) improves prediction.

Materials and Methods: This retrospective study included 322 consecutive adults presenting to a tertiary ED with suspected stroke between January 2021 and December 2024 who underwent admission glucose measurement and DWI during the index visit. Patients with traumatic brain injury or missing data were excluded. The primary outcome was DWI positivity; the secondary outcome was intensive care unit (ICU) admission. Patients were stratified into four glucose categories (< 110, 110-139, 140-179, and > =180 mg/dL). Multivariate logistic regression adjusted for age, SBP, neutrophil-to-lymphocyte ratio, creatinine, and sex was performed. An exploratory composite score (Glucose x Age x SBP / 1,000,000) was compared with glucose alone using ROC analysis.

Results and Conclusion: DWI positivity was present in 174 patients (54.0%). Median glucose was higher in DWI-positive than DWI-negative patients (141 vs 119 mg/dL, p < 0.001). DWI positivity increased from 41.6% (< 110 mg/dL) to 47.7%, 59.2%, and 75.0% (> =180 mg/dL) across categories (p for trend < 0.001). Hyperglycemia > =140 mg/dL doubled the odds of DWI positivity (OR 2.45, 95% CI 1.55-3.88, p < 0.001). In multivariate analysis, glucose remained independently significant (adjusted OR per 10 mg/dL: 1.05, 95% CI 1.01-1.10, p = 0.016). The multivariate model achieved AUC 0.850, outperforming glucose alone (0.642); the composite score achieved 0.804. ICU admission showed a parallel gradient (18.0% to 40.6%, p = 0.001). Admission hyperglycemia independently predicts DWI-confirmed ischemic stroke with a clear dose-response. Combining glucose with age and SBP may support early neuroimaging prioritization and warrants prospective validation.

Dose-response relationship between admission glucose categories and clinical outcomes

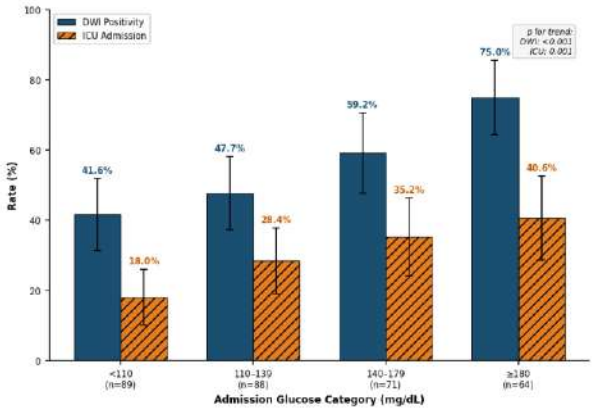

Dose-response relationship between admission glucose categories and rates of DWI positivity and ICU admission. Error bars represent 95% confidence intervals. p for trend: DWI < 0.001, ICU = 0.001.

ROC curves for predicting DWI-confirmed ischemic stroke

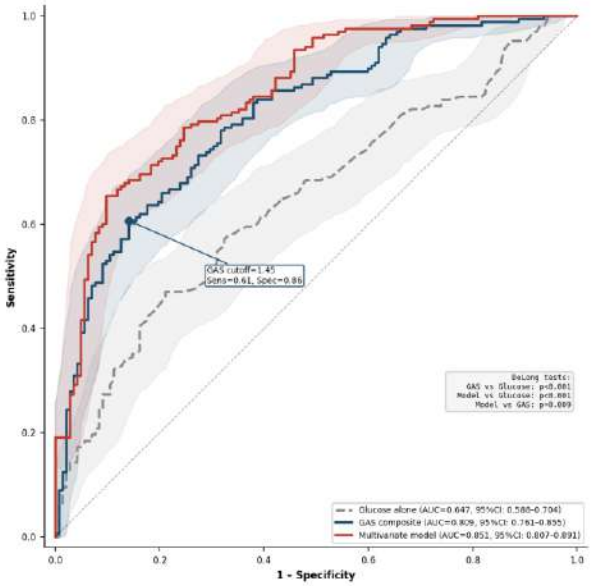

ROC curves comparing glucose alone, GAS composite score, and the multivariate model for predicting DWI-confirmed ischemic stroke. Shaded areas represent bootstrap 95% confidence bands. DeLong test: GAS vs glucose $p < 0.001$; model vs glucose $p < 0.001$; model vs GAS $p = 0.009$.

Keywords: stroke, hyperglycemia, diffusion-weighted imaging

Ref No: 4778

Early Risk Stratification in Traumatic Brain Injury: An Analysis of MEWS and rSIG Scores in Patients with Isolated Head Trauma

Ekim Sağlam Gürmen[1], Mustafa Yorgancıoğlu[2], Hakan İğdeli[1], Seçkin Turan[1]

[1]Manisa Celal Bayar University School of Medicine, Emergency Department, Manisa, Turkey
[2]İzmir Torbalı State Hospıtal, Emergency Department, İzmir, Turkey

Seçkin Turan / Manisa Celal Bayar University School of Medicine, Emergency Department, Manisa, Turkey

Introduction and Purpose: Traumatic brain injury(TBI) is a leading cause of trauma-related morbidity and mortality worldwide(1).Early identification of patients at risk for deterioration is

critical for appropriate emergency management. The Modified Early Warning Score(MEWS)and the reverse Shock Index multiplied by the Glasgow Coma Scale are simple bedside tools that may assist in early prognostic a ssessment(2,3).This study aimed to evaluate the ability of MEWS and rSIG to predict poor outcomes in patients with isolated head trauma

Materials and Methods: This retrospective observational study included patients presenting with isolated head trauma to the emergency department of Manisa Celal Bayar University Hospital between June 2021 and June 2024.Demographic and clinical data were obtained from the hospital information system.MEWS,Shock Index (SI),reverse Shock Index(rSI) and rSIG were calculated for each patient. Poor outcome was defined as intensive care unit admission and/or in-hospital mortality. Group comparisons were performed using nonparametric tests. Spearman correlation analysis, receiver operating characteristic(ROC) curves, and binary logistic regression models were used for statistical evaluation.

Results and Conclusion: A total of 705 patients(65.7% male; mean age 37.2±27.0 years)were analyzed.Pathological cranial CT findings were present in 24.7% and overall mortality was2.7%.Patients with poor outcomes had significantly higher MEWS and SI values and significantly lower GCS, rSI, and rSIG scores (all $p < 0.001$). ROC analysis demonstrated moderate predictive ability for rSIG (AUC=0.701) and limited discrimination for MEWS(AUC=0.610). Optimal cut-off values were ≤21.35 for rSIG and ≥0.5 for MEWS. In multivariate analysis, both MEWS and rSIG showed independent prognostic significance in separate models, with rSIG remaining significant in models excluding GCS. MEWS positively correlated with hospital length of stay ($r=0.385$, $p < 0.001$),whereas rSIG showed a negative correlation($r=–0.252$, $p < 0.001$).DiscussionOur study demonstrates that patients with poor outcomes after isolated head trauma exhibit higher MEWS and SI values and lower GCS, rSI, and rSIG scores. Both MEWS and rSIG are practical bedside tools for early risk stratification, with MEWS reflecting physiological deterioration and rSIG providing complementary hemodynamic–neurological information (4,5). These scores should be interpreted as adjuncts to standard clinical assessment rather than standalone triage instruments. Routine use may facilitate early clinical decision-making and closer patient monitoring in the emergency setting

Keywords: Modified Early Warning Score, Reverse Shock Index, Shock Index

Ref No: 4789

A Rare Cause of Right Upper and Lower Quadrant Pain: A Case with Suspected Bilioenteric Fistula

Berat Dilaver[1], Mümin Murat Yazıcı[1]

[1]Recep Tayyip Erdoğan University Training and Research Hospital, Emergency Medicine Department, Rize, Türkiye

Berat Dilaver / Recep Tayyip Erdoğan University Training and Research Hospital, Emergency Medicine Department, Rize, Türkiye

Introduction and Purpose: Bilioenteric fistulas are abnormal passages between the biliary tract and intestine and are rarely described clinically. In the literature, the most common causes are chronic gallstone disease, recurrent cholecystitis attacks and biliary tract anomalies. In addition, gallbladder wall changes, such as adenomyomatosis, may rarely contribute to fistula formation.

Materials and Methods: A 37-year-old man presented with abdominal pain that had been intermittent for about a month and intensified last night. He had constipation and nausea, no vomiting and anorexia. Physical examination revealed tenderness in the right upper and lower quadrants, no defense and rebound, other quadrants were normal. Laboratory findings revealed Hepatitis B surface antigen (HBsAg) 5720.56 IU/mL and lactate 3 mmol/L. Contrast-enhanced computed tomography of the abdomen showed marked colonic anus dilatation and microperforation. Hepatobiliary ultrasound revealed adenomyomatosis and bilioenteric fistula was considered. General surgery was consulted and the patient was transferred to the ward for operation.

Figure 1

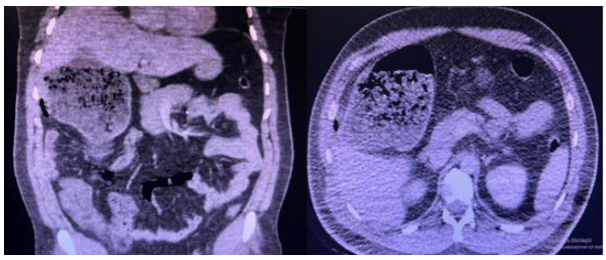

Distinct colonic anus dilatation and microperforation seen on contrast-enhanced abdominal CT sagittal and axial sections

Results and Conclusion: Clinically, bilioenteric fistulas usually present with non-specific symptoms. Abdominal pain, nausea, anorexia and sometimes low-grade fever are the most common findings. Therefore, the diagnosis is often delayed and routine physical examination and laboratory tests alone are not sufficient. Imaging plays a critical role in the diagnosis of bilioenteric fistulas. Distension of the colonic anus, increased wall thickness and the presence of free air on contrast-enhanced CT are warning signs for the possibility of fistulaBilienteric fistulas should be considered in the differential diagnosis of patients presenting with right upper and lower quadrant pain, especially in the presence of chronic biliary tract changes and adenomyomatosis.

Keywords: bilioenteric fistula, microperforation, adenomyomatosis

---

Ref No: 4814

A Case Report: Thoracic Trauma Pulmonary Artery Injury

Asaf Burak vural[1]

[1]Niğde Eğitim Araştırma Hastanesi

Asaf Burak vural / Niğde Eğitim Araştırma Hastanesi

Introduction and Purpose: Chest trauma presents a significant challenge in emergency medicine and trauma care, encompassing a wide range of injuries from rib fractures to life-threatening thoracic organ damage. Accidents, falls, assaults, and motor vehicle collisions are common causes of chest trauma. It is the second most common unintentional traumatic injury and the third leading cause of death in patients with multiple traumas. Some studies suggest that chest trauma is the leading cause of death, reaching up to 60%. In patients with severe trauma, 25% of deaths are due to chest trauma. Therefore, it is one of the largest contributors to morbidity and mortality worldwide. Damage to any vital thoracic organ and/or structures in the thoracic region can progress rapidly. Appropriate management of chest trauma in emergency departments is crucial to reduce associated complications and improve patient outcomes.

Materials and Methods: A 45-year-old male patient was brought to the emergency department with a non-vehicular traffic accident. Upon admission, his vital signs were pulse: 145 beats/min, blood pressure: 50/30 mmHg, GCS: 3. Physical examination revealed decreased breath sounds and rales in the left lung. Ultrasound showed hypoechoic (black) blood, particularly over the diaphragm on the left side, suggesting hemothorax. The patient's condition was stabilized, and imaging was requested. Thoracic CT scan revealed hemorrhagic effusion between the pericardial

layers, an 8 cm thick hemorrhagic effusion in the left hemothorax, and pneumothorax in both the left and right hemothoraxes. A tube thoracostomy was performed in the emergency department by a thoracic surgeon, and after the flow of 2000 mL of blood suggesting massive hemothorax, he was taken to emergency surgery for a thoracotomy. The patient, who underwent surgery by cardiovascular and thoracic surgeons, was found to have a laceration in the pulmonary artery and pericardium. After repair, the laceration was performed, and the patient was transferred to the intensive care unit.

Figure 1

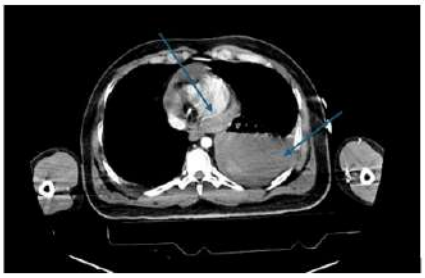

Figure 1: blood seen in the pericardium and blood seen in the left hemithorax

Figure 2

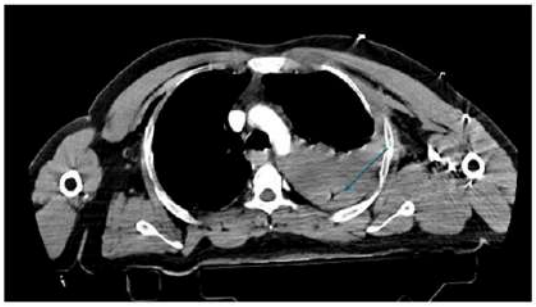

Figure 2: hematoma seen in the left hemithorax

Results and Conclusion: In conclusion, since chest traumas involve injuries to vital organs, they must be diagnosed and treated quickly, and the disrupted cardiorespiratory system dynamics must be corrected. It should be remembered that early intervention reduces mortality and morbidity.

Keywords: Pulmonary Artery Injury, Thoracic Trauma

Ref No: 4849

Fatal crush syndrome secondary to carbon monoxide exposure and prolonged immobilization: a case report

Mustafa Çiftçi[1], Mine Kayacı Yıldız[1], Tuba Arslan[1], Yasin Yıldız[1], Mehmet Gül[1]
[1]Emergency Medicine Department, Konya City Hospital,Türkiye
Tuba Arslan / Emergency Medicine Department, Konya City Hospital,Türkiye

Introduction and Purpose: Introduction Crush syndrome is a life-threatening clinical condition characterized by widespread muscle necrosis resulting from prolonged compression or immobilization, leading to rhabdomyolysis, electrolyte abnormalities, and acute kidney injury. Although it is classically associated with traumatic events such as earthquakes and severe accidents, non-traumatic causes are increasingly reported. We present a fatal case of crush syndrome developing after alcohol-induced loss of consciousness combined with carbon monoxide exposure in a closed environment.

Materials and Methods: CaseA 32-year-old previously healthy male was found unconscious approximately 10 hours after entering a closed garage to consume alcohol. He was discovered kneeling and leaning against a running vehicle. Upon admission to the emergency department, he was somnolent with a Glasgow Coma Scale score of 14. Vital signs were stable. Physical examination revealed tension in the right lower extremity, coldness of the right great toe, and absence of dorsalis pedis and posterior tibial pulses. Foley catheterization revealed cola-colored urine.Laboratory findings showed creatinine 2.89 mg/dL, creatine kinase 48,000 U/L, AST 2200 U/L, LDH 5600 U/L, potassium 7.8 mmol/L, and carboxyhemoglobin level of 19%. Arterial blood gas analysis demonstrated severe metabolic acidosis. Doppler ultrasonography revealed right popliteal vein thrombosis and impaired distal arterial flow. The patient was diagnosed with rhabdomyolysis, crush syndrome, acute kidney injury, and compartment syndrome. Emergency hemodialysis was initiated in the intensive care unit.During follow-up, compartment syndrome developed in both lower extremities, and the patient underwent emergency bilateral multi-compartment fasciotomy. Despite aggressive treatment, distal circulation could not be restored in the right lower extremity. The patient developed refractory hyperkalemia and severe metabolic acidosis postoperatively. Approximately eight hours after surgery, cardiac arrest occurred. Advanced cardiopulmonary resuscitation was unsuccessful and the patient was pronounced dead.

Results and Conclusion: Discussion and ConclusionAlcohol-related loss of consciousness combined with carbon monoxide exposure in closed environments may lead to prolonged immobilization and severe crush syndrome. This case highlights the importance of early recognition of rhabdomyolysis, crush syndrome, and compartment syndrome in patients found unconscious in closed spaces. Despite early aggressive treatment, mortality may remain high, emphasizing the need for high clinical suspicion and rapid multidisciplinary management in emergency settings.

Keywords: Crush syndrome, Rhabdomyolysis, Carbon monoxide poisoning

Ref No: 4880

A Silent Threat in the Emergency Room: An Unusual Case of Hydatid Cyst

Sumeyye Tugba SARKI CANDER[2], Egemen KOCABAS[1], Nihal AKCALI BOSTANCI[1]

[1]Çekirge State Hospital, Emergency Medicine Department, Bursa, TURKEY
[2]Bursa Yuksek Ihtisas Training and Research Hospital, Emergency Medicine Department, Bursa, TURKEY

Sumeyye Tugba SARKI CANDER / Bursa Yuksek Ihtisas Training and Research Hospital, Emergency Medicine Department, Bursa, TURKEY

Introduction and Purpose: Hydatid disease is a zoonotic infection caused by Echinococcus granulosus, commonly affecting the liver and lungs. Although often asymptomatic, patients may present to the emergency department with acute complications. The most serious is cyst rupture, which can trigger abdominal pain, allergic reactions, or life-threatening anaphylaxis. Emergency management focuses on stabilization, treatment of anaphylaxis, and surgical consultation. Early recognition is essential to reduce morbidity and mortality. In this unusual case, we aimed to highlight the diagnosis of a hydatid cyst following the patient's presentation with difficulty in defecation.

Materials and Methods: A 47-year-old male patient was brought to the emergency department by ambulance with complaints of chest and abdominal pain, along with inability to defecate for the past 10 days.The patient had left-sided pleuritic chest pain. The abdomen was markedly distended, with a palpable, tender mass extending toward the left distal region. He was diagnosed with cystic echinococcosis (hydatid cyst) many years ago but has not been under regular follow-up. Due to chest and abdominal pain, the patient was referred for imaging, including a chest X-ray and abdominal ultrasonography (USG). In the USG; there were cystic lesions consistent with recurrent hydatid cysts, the largest measuring 20 × 26 cm, occupying the midline of the abdomen and containing daughter vesicles and multiple membranes. Abdominal CT revealed; multiple hypodense cystic mass lesions were identified in all abdominal quadrants, the largest located in the upper quadrant, measuring approximately 190 × 188 mm in transverse sections, with peripheral calcifications, consistent with hydatid cysts (Image 1) The patient, diagnosed with multiple giant cystic echinococcosis, had no evidence of acute abdominal or thoracic pathology. Following evaluation and recommendations from general surgery, the patient was discharged.

Image 1

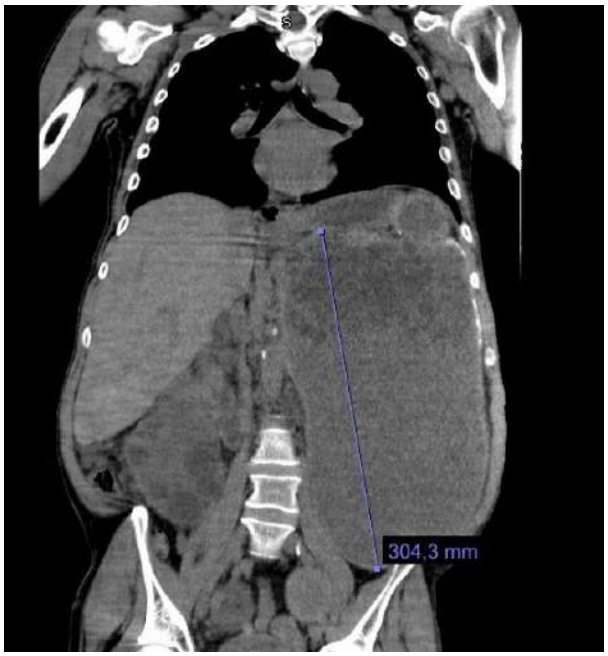

Results and Conclusion: This case highlights an unusual presentation of cystic echinococcosis with severe constipation due to mass effect of giant intra-abdominal cysts. Emergency physicians must be aware of both typical and atypical presentations to avoid missing potentially life-threatening complications. Early imaging plays a crucial role in diagnosis, and timely multidisciplinary evaluation is essential for appropriate management and prevention of complications.

Keywords: constipation, cysts, emergency department

Ref No: 4940

The macklin effectin the elderly:spontaneous pneumome diastinum triggered by parenchymal ınfiltration

Dilara İbiş[1], Osman Lütfi Demirci[1], Tuba Arslan[1], Emin Fatih Vişneci[1], Mehmet Gül[1]

[1]EmergencyMedicineDepartment, Konya City Hospital, Turkiye

Dilara İbiş / EmergencyMedicineDepartment, Konya City Hospital, Turkiye

Introduction and Purpose: Spontaneous pneumomediastinum (SPM) is a rare and generally benign clinical condition characterized by the presence of free air in the mediastinal space. This presentation discusses the diagnostic process and management of a patient who presented with complaints of impaired oral intake for the past 10 days and whose investigations revealed pneumothorax and pulmonary infiltration accompanying pneumomediastinum.

Materials and Methods: A 77-year-old male patient presented to the emergency department with complaints of anorexia, difficulty eating and drinking, and weakness that had been ongoing for the past 10 days. Physical examination at admission revealed bilateral decreased lung sounds. No evidence of subcutaneous emphysema was found. Vital signs were stable. Laboratory investigations showed a CRP level of 48 mg/L (slightly elevated). Arterial blood gas values and other tests were within physiological limits. Thoracic Computed Tomography (CT) revealed free air around the mediastinal structures (pneumomediastinum), accompanied by pneumothorax in the right apical region and widespread infiltration areas in the lung parenchyma suggestive of infectious/inflammatory processes. Following evaluations, the patient was referred to the Thoracic Surgery department and admitted to the intensive care unit.

Results and Conclusion: In cases of pneumomediastinum, the most critical point is ruling out esophageal rupture (Boerhaave Syndrome). The patient's ongoing eating disorder and low CRP level over the past 10 days support alveolar rupture secondary to parenchymal infiltrations rather than an acute perforation. The normal arterial blood gas indicates that the pneumothorax is small and has not yet disrupted the ventilation-perfusion balance. In elderly patients, pneumomediastinum may present with non-specific symptoms such as general malaise or nutritional deficiencies instead of typical chest pain. As in this case, accompanying areas of infiltration may be the primary factor triggering the Macklin effect. Treatment is generally conservative (rest, oxygen support, and close monitoring); however, the patient should be monitored for the progression of the pneumothorax. Referral or admission to a relevant intensive care unit is necessary for such cases requiring intensive care.

Keywords: Spontaneous pneumo mediastinum, emergency, macklin effect

Ref No: 4978

Emergency and Dermatologic Management of Stevens–Johnson Syndrome/Toxic Epidermal Necrolysis: A Case-Based Approach

Ayşe Sena Balcı[1], Burçe Can Kuru[1]

[1]Department of Dermatology and Venereology, Sultan II. Abdulhamid Han Training and Research Hospital, Istanbul, Turkey

Ayşe Sena Balcı / Department of Dermatology and Venereology, Sultan II. Abdulhamid Han Training and Research Hospital, Istanbul, Turkey

Introduction and Purpose: Stevens-Johnson Syndrome (SJS) and Toxic Epidermal Necrolysis (TEN) are rare but life-threatening mucocutaneous reactions, most commonly drug-induced, requiring prompt recognition and management. While initial evaluation often occurs in the emergency department, optimal outcomes depend on timely dermatologic assessment and treatment. This study aims to highlight emergency and dermatologic approaches to SJS/TEN through a representative case.

Materials and Methods: An 81-year-old female with multiple comorbidities presented with progressive erythema, pruritus, and bullous lesions. She had a history of recent exposure to voriconazole and antihypertensive medication change. Initial evaluation in an external emergency department resulted in a preliminary diagnosis of drug eruption. Due to rapid progression, she was referred to dermatology, where systemic corticosteroid therapy was initiated, followed by hospitalization. Clinical findings, laboratory parameters, histopathology, and treatment responses were retrospectively evaluated.

Results and Conclusion: On admission, the patient had widespread erythema, multiple bullae, and a positive Nikolsky sign without mucosal involvement. The SCORTEN was 4. Histopathological examination confirmed TEN. Despite treatment with systemic corticosteroids and intravenous immunoglobulin, disease progression continued. Due to refractory disease, subcutaneous etanercept was initiated, leading to rapid clinical improvement, cessation of new lesion formation, and re-epithelialization. The patient achieved near-complete recovery and was discharged after 29 days of hospitalization.This case emphasizes that early recognition of SJS/TEN in the emergency setting is critical but insufficient alone. Timely dermatologic consultation, accurate diagnosis, and appropriate escalation of immunomodulatory therapy are essential for improved outcomes. A multidisciplinary approach plays a central role in the management of these severe cutaneous adverse reactions.

Figure 1



Clinical appearance at initial presentation, showing progressive erythema, pruritus, and bullous lesions.

Figure 2



Final clinical appearance at discharge after appropriate treatment, demonstrating near-complete recovery following 29 days of hospitalization.

Keywords: Stevens-Johnson Syndrome, Toxic Epidermal Necrolysis, Dermatologic Emergencies

Ref No: 5002

Clinical Distribution and Imaging Trends in Patients Presenting with Dizziness (Vertigo): A Retrospective Study in a Tertiary Center

Mehmet Sezer[1]

[1]Malatya Turgut Özal Üniversity

Mehmet Sezer / Malatya Turgut Özal Üniversity

Introduction and Purpose: Dizziness (vertigo) is a symptom that is frequently encountered in emergency departments and requires a multidisciplinary approach, as there is no specific diagnostic algorithm. This study aimed to evaluate the clinics visited by patients presenting with dizziness, the imaging methods used in these clinics, their consultation needs, and their hospitalization rates. This study aimed to determine the epidemiological data of dizziness and evaluate the clinical approach by retrospectively examining one-month visits from patients with dizziness at a tertiary hospital.

Materials and Methods: This study retrospectively examined patients who presented to a tertiary hospital between February 23, 2026, and March 23, 2026, and were diagnosed with ICD-10 code R42 (dizziness/vertigo). A total of 1211 patients were included in the study. The clinics where patients presented were grouped as emergency department, otolaryngology, neurology, and others. In these clinics, the requested imaging methods were computed tomography (CT) and magnetic resonance imaging (MRI). The number of consultations and hospitalizations in these clinics were recorded. The data were evaluated using descriptive statistical methods.

Examination of Patients Presenting with Dizziness

	Patient(n)	BT+	MRI +	ConsultATİON	Hospitalization
Emergency Department	503	136	93	0	0
Otorhinolaryngology Department	500	16	18	25	1
Neurology Department	121	13	35	8	4
Others	87	9	25	1	3
Total	1211	174	171	34	8

Results and Conclusion: It was observed that most patients presented to the Emergency Department (n=503) and Ear, Nose and Throat (N=500) clinics. The usage rates of CT (14.4%) and MRI (14.1%) were similar. CT was most frequently preferred in the Emergency Department (27%), while MRI was most frequently preferred in the Neurology clinic (28.9%). The need for consultation (2.8%) and hospitalization rates (0.7%) were found to be low. The highest hospitalization rate is in the neurology clinic. There have been no consultations or admissions from the emergency department.The vast majority of patients presenting with dizziness can be managed on an outpatient basis, and benign etiologies are predominant. The high rate of imaging usage in the Emergency Department is thought to be due to the need for rapid diagnosis and the relatively easier accessibility of imaging facilities. Despite this high imaging rate, the low rates of consultation and hospitalization suggest that clinical evaluation needs improvement. Adopting a clinical approach based on detailed history taking and physical examination, along with the effective use of bedside vestibular and neurological assessments, can reduce unnecessary imaging rates and facilitate patient management.

Keywords: Emergency Department, İmaging Techniques, Vertigo

Ref No: 5005

Fatal Diagnosis Behind Atypical Symptoms: Aortic Dissection In The Emergency Department

Ozan Deniz Keleş[1], Berkay Sümen[1], İsa Yıldırım[1], Ahmet Melih Savaş[1], Ayhan Aköz[1]

[1]Department of Emergency Medicine, Faculty of Medicine, Aydın Adnan Menderes University, Aydın, Turkey

Ozan Deniz Keleş / Department of Emergency Medicine, Faculty of Medicine, Aydın Adnan Menderes University, Aydın, Turkey

Introduction and Purpose: Aortic Dissection is a life-threatening emergency caused by blood entering between the aortic intima and media layers. While the typical presentation involves sudden, tearing chest and back pain, clinical findings such as pulse discrepancies or new murmurs are often inconsistent. This report presents a case detected via bedside ultrasound in a patient presenting with atypical leg pain.

Materials and Methods: A 36-year-old male presented with abdominal and back pain, and left leg numbness, starting two hours prior after coughing. His medical history was unremarkable, and initial vital signs were normal. Physical examination revealed abdominal tenderness, a pale

left lower extremity, and an impalpable left popliteal pulse. Bedside ultrasonography identified a dissection flap and double lumen extending distally from the SMA level. Aortography confirmed an intimal flap starting from the aortic root, creating true and false lumens. The dissection extended through the ascending aorta, aortic arch, and descending thoracic aorta down to the iliac bifurcation. Computed tomography was consistent with Stanford Type A, DeBakey Type I Dissection. The patient was immediately referred for emergency cardiovascular surgery.

Results and Conclusion: Aortic Dissection carries high mortality, with an incidence of 3 per 100,000. Only 22% of patients are diagnosed antemortem, and mortality reaches 50% within the first 24 hours if untreated. Because AD often presents with atypical symptoms, clinicians must maintain a high index of suspicion to ensure life-saving intervention.

Keywords: Aortic dissection, cough, pain

Ref No: 5047

Pneumorhorax: Retrospective cases analysis

Barış Utku Çeçeli[1]

[1]Malatya Turgut Özal University

Barış Utku Çeçeli / Malatya Turgut Özal University

Introduction and Purpose: Pneumothorax is a clinical condition characterised by the accumulation of air in the pleural space, which can result in lung collapse. In recent years, biochemical and haematological parameters that reflect the inflammatory response have garnered attention as potential biomarkers for evaluating disease severity and clinical course in patients with pneumothorax. This study aimed to evaluate the demographic characteristics and laboratory parameters of patients diagnosed with pneumothorax. It also aimed to investigate the relationships between inflammatory markers and albumin and haemoglobin levels.

Materials and Methods: In this retrospective study, patients diagnosed with pneumothorax were examined. The demographic characteristics and laboratory parameters of the patients were evaluated. In addition, the relationships between inflammatory markers and albumin and haemoglobin levels were analysed.

Results and Conclusion: The majority of pneumothorax patients included in the study were male, with an average age of 40 years. Right pneumothorax was observed in most cases, while

left and bilateral pneumothorax were seen less frequently. In the parameters examined, a significant negative correlation was found between albumin and age, CRP, leukocyte, and monocyte values, while a significant positive correlation was found between albumin and haemoglobin. Furthermore, a significant negative relationship was detected between CRP and haemoglobin. In conclusion, routine laboratory parameters can be useful in evaluating the inflammatory process in pneumothorax patients. In particular, the relationships between albumin, hemoglobin, and inflammatory markers can provide important information about the disease process. However, further studies in larger patient groups are needed to more clearly establish the relationship of these parameters with clinical course and prognosis.

Keywords: Pneumothorax, Haematological parameters, Inflammation

---

Ref No: 5052

Possible Herbal Toxicity Following Consumption of Corn Poppy (Papaver rhoeas)

Hakan Ateş[1], Osman Lütfi Demirci[1], Mustafa Selçuk Solak[1], Gamze Yıldız[1], Mehmet Gül[1]

[1]Emergency Medicine Department, Konya City Hospital, Türkiye

Hakan Ateş / Emergency Medicine Department, Konya City Hospital, Türkiye

Introduction and Purpose: The use of herbal products for traditional therapeutic purposes is widespread worldwide. Corn poppy (Papaver rhoeas), a member of the Papaveraceae family, is a plant commonly found in Europe, the Middle East, and Anatolia. In this study, we present a case that was monitored in the toxicology intensive care unit due to symptoms that developed after the consumption of corn poppy.

Materials and Methods: CaseA 55-year-old female patient reported that she had consumed a plant known among the public as “corn poppy” due to complaints of cough and body pain persisting for approximately 3–4 days. Following the consumption of the plant, the patient developed symptoms including dizziness, weakness, and palpitations, and initially presented to an external healthcare facility. No pathological findings were detected in the examinations performed. Imaging studies were also evaluated as normal. The patient was admitted to the toxicology intensive care unit for observation due to possible herbal toxicity. The patient’s clinical condition, vital signs, and laboratory parameters were monitored for two days. Since no complications developed during the follow-up and the patient's general condition remained stable, she was discharged with recommendations.

Results and Conclusion: The widespread and uncontrolled use of herbal products may lead to various toxic effects. Although plants such as corn poppy are often considered safe, their biologically active compounds may cause clinical symptoms. Therefore, it is important to obtain a detailed history of herbal product use in patients presenting with symptoms. Additionally, in cases of herbal product-related toxicity, monitoring patients in an appropriate clinical setting and providing supportive treatment are essential for preventing potential complications.

Keywords: Corn poppy, Papaver rhoeas, herbal toxicity

Ref No: 5130

Gender disparities in academic rank and leadership positions in emergency medicine: a nationwide analysis

Büşra Bildik[1], Burcu Simge Eroğlu[1], Eda Harun[1], Cemre Akdoğan[1], Bora Çekmen[1]

[1]Karabuk University, Faculty of Medicine, Department of Emergency Medicine

Büşra Bildik / Karabuk University, Faculty of Medicine, Department of Emergency Medicine

Introduction and Purpose: As in many medical specialties, women remain underrepresented in academic and leadership positions in emergency medicine.This study aimed to evaluate the representation of female physicians across different academic ranks and leadership positions in emergency medicine clinics in Türkiye,as well as their regional distribution,in order to elucidate existing gender disparities.

Materials and Methods: Hospitals with accredited training programs in Türkiye were identified using the database of the Medical Specialty Board of the Ministry of Health.Data on academic staff were obtained from the official websites of these institutions.Emergency medicine clinics with incomplete or outdated data were excluded.Gender distribution across academic ranks and overall gender distribution by region were compared using the chi-square (χ^2) test.Pairwise comparisons of gender distribution among academic rank groups were performed using Bonferroni correction.

Results and Conclusion: A total of 1,589 post-residency physicians were included in the study,of whom 525 (33.0%) were women.Analysis by academic rank revealed that women constituted 38.0% (n=374) of specialists, 24.5% (n=53) of assistant professors, 24.9%(n=57) of associate professors,and 25.6% (n=41) of professors.The association between academic rank and gender was statistically significant ($p < 0.001$).A marked decrease in the proportion of female

physicians was observed with increasing academic rank.The gender distribution in the specialist group differed significantly from all academic rank groups ($p < 0.008$).Among department chairs, 27 (19.7%) were women.The association between department chair status and gender was also statistically significant ($p < 0.001$).Female physicians were significantly less likely to serve as department chairs compared to their male counterparts (OR:0.47; 95% CI:0.30–0.73).Regional analysis demonstrated that gender distribution varied significantly across geographical regions ($p=0.005$).Based on total physician numbers, the proportion of women was 34.1% in the Central Anatolia region and 33.3% in the Mediterranean region.Subgroup analyses indicated heterogeneity in gender distribution across regions, particularly within academic ranks.In Central Anatolia,the proportion of women was relatively higher at the specialist level but decreased markedly at higher academic levels.In contrast,in the Mediterranean region, female representation was notably low, especially at the assistant professor level.In conclusion,female physicians in emergency medicine clinics in Türkiye are underrepresented in higher academic ranks and leadership positions.Structural and institutional efforts are needed to address and reduce these persistent gender disparities.

Keywords: Gender disparities, Academic ranking

Ref No: 5173

Spontaneous Active Bleeding Secondary to Rupture of a Surrenal Adenoma: Diagnosis and Minimally Invasive Management

Enes Topaloğlu[1], İsmail Ataş[1], Gökhan Ersunan[1]

[1]Recep Tayyip Erdoğan University Training and Research Hospital, Department of Emergency Medicine, Rize, Türkiye

Enes Topaloğlu / Recep Tayyip Erdoğan University Training and Research Hospital, Department of Emergency Medicine, Rize, Türkiye

Introduction and Purpose: Spontaneous adrenal hemorrhage (SAH) is a rare but critical clinical entity with high morbidity and mortality risk, requiring rapid diagnosis and multidisciplinary approach. Clinical findings are often non-specific, which may complicate the diagnosis. The aim of this case report is to emphasize the diagnostic process and minimally invasive treatment approach of spontaneous adrenal hemorrhage due to ruptured adenoma.

Materials and Methods: A 71-year-old woman was referred to an external center for sudden onset of right flank pain and was referred to our center for further evaluation after a right perirenal hematoma was detected on abdominal computed tomography. It was learned that the patient had a history of hypertension, diabetes mellitus and chronic heart failure and was on antiaggregant therapy. Physical examination revealed right upper and lower quadrant tenderness and right costovertebral angle tenderness. Laboratory tests revealed decreased hemoglobin levels, metabolic acidosis and elevated lactate levels in arterial blood gas. Contrast-enhanced CT examination showed active extravasation from right surrenal adenoma and secondary retroperitoneal hematoma. Emergency blood product replacement was started due to ongoing bleeding and hemoglobin decrease. After multidisciplinary evaluation, interventional radiological treatment was planned as an alternative to surgery and successful transarterial embolization of the vasculature causing bleeding was performed.

Figure 1

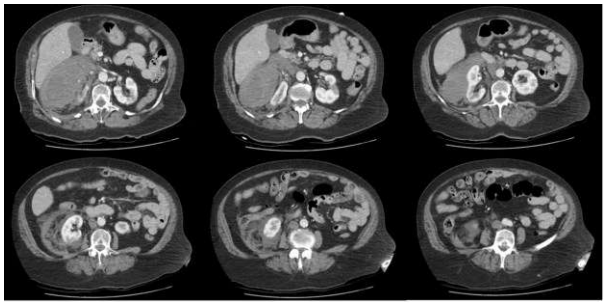

Contrast-enhanced abdominal CT scans showing heterogeneous hematoma and active contrast extravasation in the right surrenal lobe

Results and Conclusion: Spontaneous adrenal hemorrhage should be considered in the differential diagnosis, especially in elderly patients and patients on anticoagulant/antiaggregant therapy. While computed tomography plays a critical role in early diagnosis, interventional radiologic methods offer an effective and safe treatment option as an alternative to surgery in appropriate patients. Multidisciplinary approach is decisive in reducing mortality and morbidity.

Keywords: adrenal adenoma, spontaneous adrenal hemorrhage, embolization

Ref No: 5217

Relationship Between Laboratory Parameters And Mortality In Femoral Neck Fractures Presenting To The Emergency Department

Yakup Demirci[1]

[1]Malatya Turgut Özal Üniversitesi

Yakup Demirci / Malatya Turgut Özal Üniversitesi

Introduction and Purpose: Objective: The aim of this study was to evaluate the association between routine laboratory parameters obtained at the time of presentation and in-hospital mortality in patients presenting to the emergency department with a femoral neck fracture.

Materials and Methods: Materials and Methods: This single-center, retrospective study was conducted on 43 patients who presented to the emergency department with a diagnosis of femoral neck fracture between December 1, 2025, and March 1, 2026. Urea, creatinine, albumin, calcium, CRP, WBC, platelet, and hemoglobin levels at the time of presentation were analyzed. Normal distribution was assessed using the Shapiro–Wilk test; Student's t-test and the Mann–Whitney U test were used for group comparisons, while Pearson and Spearman tests were employed for correlation analysis.

Results and Conclusion: Results: The median age of the patients was 79 years (IQR: 68–89), and the median length of hospital stay was 9 days (IQR: 7–12). Urea was measured at 52.05 ± 21.80 mg/dL, platelets at 235.11 ± 108.53 ×10³/µL, and hemoglobin at 12.60 ± 1.73 g/dL. When non-parametric variables were examined, creatinine was 0.92 (0.71–1.19) mg/dL, albumin 3.8 (3.4–4.3) g/dL, CRP 5.6 (1.0–47.2) mg/L, and WBC 10.59 (8.28–15.08) ×10³/µL. Mortality analysis revealed no statistically significant differences in any of the examined parameters (all $p > 0.05$). In the correlation analysis, a moderate positive correlation was found between albumin and calcium ($r = 0.500$; $p = 0.001$), while a weak negative correlation was observed between creatinine and calcium ($r = -0.363$; $p = 0.017$).Conclusion: It was observed that emergency department admission laboratory parameters were insufficient to independently predict mortality in patients presenting with femoral neck fractures. It is considered that clinical scoring systems and comorbid conditions should be addressed together in prognostic evaluation.

Table 1. Mean and standard deviation values of our parametric data

Değişkenler	N	Anlam	SD
Üre (mg/dL)	43	52.04	21.8
Plt (10^3/uL)		235.10	18.53
Hgb (mmol/L)		12.60	1.72

Keywords: femoral neck fracture, laboratory parameters, mortality

---

Ref No: 5256

From a simple tooth extraction to fatal septic shock: a rapidly progressive case of necrotizing fasciiti

Mehmet Akif Ersoy[1], Yasin Yıldız[1], Kaya Alp Sonkaya[1], Emin Fatih Vişneci[1], Mehmet Gül[1]

[1]Emergency Medicine Department, Konya City Hospital, Türkiye

Mehmet Akif Ersoy / Emergency Medicine Department, Konya City Hospital, Türkiye

Introduction and Purpose: Odontogenic infections are the most frequent sources of spread into deep neck spaces. In elderly and diabetic patients, due to suppressed immune response, the infection can rapidly cross fascial planes, leading to necrotizing fasciitis followed by septic shock characterized by multi-organ failure. Early diagnosis and aggressive surgical intervention are critical in reducing mortality. This presentation describes a case of deep neck infection following tooth extraction that progressed to necrotizing fasciitis and resulted in mortality.

Materials and Methods: A 70-year-old female patient presented to the emergency department with complaints of pain, swelling, and erythema on the left side of the neck. Her medical history revealed a tooth extraction from the left mandible two weeks prior. Her medical history was significant for Diabetes Mellitus (DM) and Hypertension (HT). Upon admission, blood pressure was 160/70 mmHg, heart rate was 120 bpm, and body temperature was 38 °C. SpO2 was recorded as 88% under a reservoir mask. Physical examination revealed an abscess focus on the left side of the neck accompanied by fluctuation, increased local temperature, and intense erythema. The patient, diagnosed with a deep neck infection following an Otolaryngology (ENT) consultation, was transferred to the Intensive Care Unit (ICU) due to clinical deterioration. ICU follow-up laboratory parameters were as follows: WBC/Neu: 28.54/µL, CRP: 324 mg/L, Procalcitonin: 2.81 ng/mL, creatinine: 2.19 mg/dL, BUN: 89 mg/dL, K: 7.2 mEq/L, Na: 154 mEq/L, pH: 7.24, and Lactate: 13.5 mmol/L.

Results and Conclusion: This case emphasizes that even a simple tooth extraction can progress into life-threatening necrotizing processes in elderly patients with comorbidities. The rapid transition of the infection from the submandibular space to the retropharyngeal or visceral spaces makes patient management challenging. Biochemical markers such as hyperkalemia and elevated lactate levels are of vital importance in indicating the severity of sepsis and the urgent need for hemodialysis and surgical debridement. A multidisciplinary approach (ENT, Intensive Care, Infectious Diseases) is mandatory for the survival of these patients.

Keywords: Necrotizing fasciitis, Odontogenic infection, Sepsis

---

Ref No: 5287

Differentiation Between Osteomyelitis and Malignancy in Bone Lesions: A Report of Four Cases

Barış Utku Çeçeli[2], Derviş Kurnaz[1]

[1]Malatya Training and Research Hospital
[2]Malatya Turgut Özal University

Barış Utku Çeçeli / Malatya Turgut Özal University

Introduction and Purpose: The differentiation between osteomyelitis and malignancy in bone lesions detected in patients presenting with bone pain is of critical clinical importance. This study aimed to present four cases in which diagnostic difficulty was encountered and to evaluate them in the context of the relevant literature.

Materials and Methods: Three cases of osteomyelitis and one case of bone metastasis are presented. In the first case, osteomyelitis developing after trauma mimicked malignancy. In the second case, osteomyelitis was diagnosed despite the absence of prominent signs of infection. In the third case, bone metastasis was detected in a patient with no prior history of primary malignancy. In the fourth case, although osteomyelitis clinically mimicked malignancy following a traumatic femur fracture, the diagnosis was established pathologically by biopsy.

Results and Conclusion: The differentiation between osteomyelitis and malignancy in bone lesions must be made through careful clinical evaluation, imaging, and histopathological examination. Misdiagnosis may lead to unnecessary surgical interventions or delays in treatment.

Keywords: Osteomyelitis, Bone metastasis, Differantial diagnosis

Ref No: 5356

Comparison of EDACS-ADP and HEARTS3 Scores When Used With Echocardiography for Safe Discharge and Major Adverse Cardiovascular Event (MACE) Prediction in Chest Pain Patients From the Emergency Medicine Department

Mustafa Altay[1]

[1]Giresun teaching and research hospital

Mustafa Altay / Giresun teaching and research hospital

Introduction and Purpose: The HEARTS3 and EDACS-ADP scores are two prominent tools developed to guide chest pain in acute coronary syndrome. While HEARTS3 integrates history, ECG, age, risk factors, and serial troponin and ECG results, EDACS-ADP relies on symptom characteristics and ECG findings to determine low-risk disposition. Previous studies have shown these scores to be effective in isolation; however, few have explored their performance in combination with bedside echocardiography. Echocardiography, widely available in EDs, can detect wall motion abnormalities and ejection fraction reductions, adding important prognostic value. This study investigates whether combining HEARTS3 and EDACS-ADP with echocardiographic findings improves their accuracy for predicting MACE and related outcomes.

Materials and Methods: This was a retrospective observational study conducted in tertiary centre emergency medicine. Patients aged ≥18 years presenting with chest pain between January 2024 and March 2025 were included. Exclusion criteria included incomplete data or transfer from other facilities.Clinical data included age, sex, vital signs, ECG interpretations, troponin levels, risk factors (e.g., hypertension, diabetes), and echocardiographic parameters (wall motion abnormalities, EF < 49%, normal ECHO). Outcomes assessed were MACE, coronary angiography (CAG) findings, CABG, KKY, and mortality.Statistical analyses were performed using Python. Mann-Whitney U and Chi-square tests assessed univariate differences. Logistic regression models evaluated predictors of MACE. ROC curves and AUC values were computed for each scoring model with and without ECHO.

Results and Conclusion: final analysis included 176 patients with a mean age of 64.8 years (52% male). Among these, 43 patients experienced MACE, and 91 underwent CAG. HEARTS3 scores were significantly higher among MACE patients (median 8 vs. 4; $p < 0.0001$). EDACS-ADP also demonstrated statistical association with MACE ($p = 0.00008$), though with lower AUC (0.65 vs. 0.91 for HEARTS3).Addition of echocardiographic findings improved model performance: HEARTS3+ECHO yielded an AUC of 0.92, EDACS-ADP+ECHO reached 0.77. Improvement was also noted in predicting KKY and mortality.HEARTS3 maintained independent predictive value for LAD, LCx, and RCA lesions, whereas EDACS-ADP showed

weaker discriminatory ability for these endpoints.The HEARTS3 score, particularly when used in conjunction with echocardiographic findings, provides excellent predictive accuracy for MACE and coronary artery disease. EDACS-ADP remains a valid tool but was consistently outperformed by HEARTS3 in this analysis.

Comparison of CAG Lesion Correlations with HEARTS³ and EDACS-ADP

Vessel	HEARTS3 r	HEARTS3 p	EDACS_ADP r	EDACS_ADP p
RCA	0.32	<0.0001	0.166	0.028
LAD	0.407	<0.0001	0.203	0.007
LCx	0.304	<0.0001	0.118	0.124
Diagonal	0.062	0.417	0.06	0.433
No Occlusion	-0.218	0.004	-0.069	0.357

Table 1. Original Correlation with CAG Lesion Outcomes

Keywords: Emergency, hearts3, edacs-adp

Ref No: 5362

Contrast-induced nephropathy following repeated contrast exposure: a case report

Nezime Beyza Yıldırım[1], Müslüme Kasa[1], Berra Kalkavan Doğan[1], Muhammet Gökhan Turtay[1], Gökhan Yılmaz[1], Bekir Kılıç[1]

[1]University of Health Sciences, Beyhekim Training and Research Hospital, Clinic of Emergency Medicine, Konya, Türkiye.

Muhammet Gökhan Turtay / University of Health Sciences, Beyhekim Training and Research Hospital, Clinic of Emergency Medicine, Konya, Türkiye.

Introduction and Purpose: In this case report, we aimed to present a patient who developed progressive acute kidney injury with a fatal outcome following repeated exposure to contrast media within a short period in the presence of advanced age, diabetes mellitus, and heart failure.

Materials and Methods: A 75-year-old male presented to the emergency department with complaints of dyspnea, wheezing respiration, and abdominal distension. The patient's medical history revealed that he had undergone two contrast-enhanced computed tomography scans four days apart. It was also noted that colchicine and ibuprofen had been initiated due to pericardial effusion. Laboratory tests obtained in the emergency department showed a blood urea level of 93 mg/dL, serum creatinine level of 1.8 mg/dL, and C-reactive protein (CRP) level of 144 mg/L, while urine output was 50 mL/h. On the third day of intensive care unit follow-up, blood urea increased to 190 mg/dL and creatinine to 3.7 mg/dL. On the fourth day, urea was 240 mg/dL and creatinine was 4 mg/dL. Despite intensive care management, the patient's renal function progressively deteriorated and he died on the fifth day.

Results and Conclusion: In elderly patients receiving repeated contrast media administration, a history of diabetes mellitus, heart failure, and nonsteroidal anti-inflammatory drug use should be recognized as important risk factors for the development of contrast-induced nephropathy.

Keywords: Emergency, Acute kidney injury, Contrast-induced nephropathy

---

Ref No: 5391

The Role of CRP, Albumin, and CAR in Predicting Mortality in Pneumonia Patients Aged ≥75 Years in the Intensive Care Unit

Semih Kaya[1], Özlem Albay[2]

[1]Malatya Turgut Özal Üniversitesi
[2]Malatya Eğitim Araştırma Hastanesi

Semih Kaya / Malatya Turgut Özal Üniversitesi

Introduction and Purpose: Objective:This study aimed to evaluate the association of C-reactive protein (CRP), albumin, and the CRP/albumin ratio (CAR) with mortality in patients aged ≥75 years with pneumonia admitted to the intensive care unit from the emergency department.Design:Retrospective observational study.Setting:Emergency department and intensive care unit of a tertiary care hospital.Subjects:Patients aged ≥75 years diagnosed with pneumonia and admitted to the intensive care unit.

Materials and Methods: Demographic and laboratory data were obtained from hospital records. Statistical analyses were performed using IBM SPSS Statistics version 27. Normality was assessed using the Kolmogorov–Smirnov test. Parametric variables were expressed as mean ±

standard deviation, and non-parametric variables as median (IQR). Independent samples t-test and Mann–Whitney U test were used for group comparisons.

Results and Conclusion: Results:A total of 69 patients were included. The mean age was 82.9 ± 5.4 years. The overall mortality rate was 26.1%. Age was significantly higher in non-survivors (p=0.028). CRP levels were significantly associated with mortality (p=0.001). No significant association was found between albumin levels and mortality (p=0.185). CAR values were significantly higher in non-survivors (p=0.001).Conclusion:CRP and especially CAR are significantly associated with mortality in elderly patients with pneumonia. Albumin alone appears to have limited prognostic value. CAR may serve as a useful biomarker for mortality prediction by reflecting both inflammatory status and nutritional condition.

Table 1. Demografik ve Laboratuvar Parametreleri (Parametrik Veriler Ortalama ± SS, Non-parametrik Veriler Medyan [IQR])

Table 1. Demografik ve Laboratuvar Parametreleri (Parametrik Veriler Ortalama ± SS, Non-parametrik Veriler Medyan [IQR])					
Parametreler	n	Mean	SD	Median	IQR %25-75
Yaş	69	82,9	5,4		
CRP		12	6,3		
ALB		2,8	0,4		
CAR				3,8	2,7-5,5

Keywords: Pneumonia, Intensive Care Unit, C-Reactive Protein

Ref No: 5403

EASIX Score in Acute Ischemic Stroke: Association with In-Hospital Mortality and Thrombolytic Treatment

Akin Seckin[1], Arzu Capraz Olcay[1], Alican Ünal[1], Eda Harun[1], Büşra Bildik[1], Bora ÇEKMEN[1]
[1]Karabuk University, Faculty of Medicine, Department of Emergency Medicine

Arzu Capraz Olcay / Karabuk University, Faculty Of Medicine, Department Of Emergency Medicine

Introduction and Purpose: Ischemic stroke accounts for approximately 80% of all stroke cases and is one of the leading causes of morbidity and mortality worldwide. Early identification of biomarkers that can predict prognosis is crucial for improving clinical outcomes. The Endothelial

Activation and Stress Index (EASIX) is a biomarker reflecting endothelial dysfunction and systemic inflammation, and its prognostic value has been demonstrated in various critical illnesses. This study aimed to evaluate the association between the EASIX score and in-hospital mortality as well as the need for thrombolytic therapy in patients with ischemic stroke.

Materials and Methods: This study was designed as a retrospective, observational cohort study including patients who presented with a diagnosis of ischemic stroke. Demographic characteristics, comorbidities, and laboratory parameters at admission were obtained retrospectively from the hospital information system.For all patients, age, sex, comorbid conditions (cardiac disease, diabetes mellitus, hypertension, chronic obstructive pulmonary disease, chronic kidney disease, malignancy, and history of prior stroke), hospitalization status, in-hospital mortality, and length of hospital stay were recorded. Laboratory data included urea, creatinine, AST, ALT, albumin, total protein, C-reactive protein (CRP), white blood cell count (WBC), mean platelet volume (MPV), lactate dehydrogenase (LDH), platelet count (PLT), and hematocrit (HCT). In addition, the EASIX score was calculated for each patient using the formula: LDH (U/L) × creatinine (mg/dL) / platelet count (10^9/L).Two primary outcomes were evaluated in this study: in-hospital mortality and administration of thrombolytic therapy. Patients were grouped according to these outcomes, and baseline characteristics and laboratory parameters were compared between groups.

Table 1. Baseline characteristics according to in-hospital mortality

variable	total	survived	deceased	p
Age (mean ± SD)	70.0 ± 11.0	69.9 ± 11.3	70.7 ± 7.2	0.753
Gender (Kadın=1)	70 (47.6%)	68 (49.6%)	2 (20.0%)	0.101
Urea (mg/dl) (median, IQR)	39.0 (30.5–48.5)	39.0 (30.0–46.0)	59.0 (52.5–75.2)	0.004
Creatinin (mg/dl) (median, IQR)	0.90 (0.70–1.20)	0.90 (0.70–1.10)	1.05 (0.80–1.30)	0.257
AST (U/L) (median, IQR)	23.0 (18.0–29.0)	23.0 (18.0–29.0)	26.0 (23.2–31.2)	0.180
ALT (U/L)	16.0 (12.0–	16.0 (11.0–	23.0 (16.5–	0.043

(median, IQR)	22.5)	22.0)	56.2)	
Albumin (g/dl) (median, IQR)	4.10 (3.80–4.40)	4.10 (3.80–4.40)	4.00 (3.57–4.15)	0.297
Total protein (mg/dl) (mean ± SD)	6.9 ± 0.6	6.9 ± 0.6	6.8 ± 0.7	0.582
CRP (mg/L) (median, IQR)	5.5 (2.4–15.7)	5.0 (2.3–13.5)	44.9 (17.6–81.8)	0.002
WBC (10^9/L) (median, IQR)	8.4 (6.8–10.4)	8.3 (6.8–10.3)	9.7 (7.6–11.4)	0.171
MPV (fL) (mean ± SD)	9.9 ± 1.0	9.9 ± 1.0	10.3 ± 1.0	0.212
LDH (median, IQR)	233.0 (198.5–282.5)	231.0 (197.0–279.0)	270.0 (225.8–348.8)	0.117
PLT (10^9/L) (median, IQR)	230.0 (187.0–282.0)	229.0 (187.0–275.0)	305.0 (268.8–322.2)	0.060
HCT (%) (mean ± SD)	40.9 ± 4.5	40.9 ± 4.5	41.7 ± 4.6	0.472
EASIX Score (median, IQR)	0.93 (0.64–1.55)	0.93 (0.65–1.53)	0.99 (0.58–3.70)	0.658
Trombolytic treatment	17 (11.6%)	16 (11.7%)	1 (10.0%)	0.694
İschemic Area				0.065
ACA	9 (6.1%)	7 (5.1%)	2 (20.0%)	
MCA	98 (66.7%)	92 (67.2%)	6 (60.0%)	
PCA	15 (10.2%)	15 (10.9%)	0 (0.0%)	
Vertebrobasilar	9 (6.1%)	8 (5.8%)	1 (10.0%)	
Watershed	8 (5.4%)	6 (4.4%)	2 (20.0%)	

Lacunar	8 (5.4%)	9 (6.6%)	1 (10.0%)	

Results and Conclusion: While inflammatory and renal biomarkers were associated with in-hospital mortality in patients with ischemic stroke, the EASIX score did not demonstrate prognostic value for mortality or the need for thrombolytic therapy. Larger, prospective studies are needed to better clarify the role of the EASIX score in this patient population.

Keywords: Acute ischemic stroke, EASİX score

Ref No: 5448

Pediatric epidural hematoma following a pedestrian traffic accident: a case report with computed tomography findings

Enes Eler[1], Ayla Mollaoğlu[1], Rıdvan Tuncer[1], Bekir Görkem[1], Mehmet Gül[1]

[1]Emergency Medicine Department, Konya City Hospital, Türkiye

Rıdvan Tuncer / Emergency Medicine Department, Konya City Hospital, Türkiye

Introduction and Purpose: Epidural hematoma (EDH) is an important intracranial pathology characterized by blood accumulation between the dura mater and the skull following head trauma, requiring early diagnosis and treatment.It is one of the significant causes of traumatic brain injury in the pediatric population and is frequently associated with head trauma and skull fractures. Computed tomography (CT) is the fastest and most reliable imaging modality for the diagnosis of epidural hematoma.In this study, a pediatric case with epidural hematoma and a concomitant long bone fracture following a pedestrian traffic accident is presented.

Materials and Methods: A seven-year-old male patient was brought to the emergency department following a pedestrian traffic accident. During the initial evaluation, the patient's general condition was moderate, consciousness was clear, and the Glasgow Coma Scale score was assessed as 14. Physical examination revealed tenderness and swelling in the right temporal region. Additionally, pain, deformity, and limitation of movement were present in the right upper extremity. Cranial computed tomography performed as part of the trauma protocol demonstrated a hyperdense extradural collection in the right temporal region consistent with an epidural hematoma. Bone window sections revealed a linear fracture line in the right parietal bone. In addition, a right forearm radiograph showed findings consistent with comminuted fractures of the distal radius and ulna.

Results and Conclusion: Epidural hematomas usually occur due to traumatic injury of the meningeal arteries.. The most common causes in pediatric patients are traffic accidents and falls. On CT imaging, it typically appears as a biconvex (lens-shaped) hyperdense collection. Early diagnosis and appropriate treatment significantly reduce mortality. Early imaging is crucial for detecting epidural hematoma in pediatric trauma patients. Considering the possibility of multisystem trauma, other organ and extremity injuries should also be carefully evaluated.

Keywords: epidural hematoma, trauma, pediatric

Ref No: 5453

Bradycardia, renal failure, AV nodal blockade, shock, and hyperkalemia (BRASH) syndrome presenting with cardiac arrest: a case report

Adnan HOCAOGLU[1], Kazım Ersin ALTUNSOY[1], Kazım Ersin ALTUNSOY[1]

[1]Gaziantep City Hospital

Adnan HOCAOGLU / Gaziantep City Hospital

Introduction and Purpose: BRASH syndrome is a clinical entity characterized by the synergistic effect of bradycardia, renal failure, atrioventricular (AV) nodal blocker use, shock, and hyperkalemia. It is often underrecognized in emergency settings and may rapidly progress to cardiac arrest. We aimed to present a case of BRASH syndrome with an atypical and severe presentation requiring prolonged resuscitation.

Materials and Methods: A 78-year-old female with a history of hypertension and diabetes mellitus, using metformin (Glifor) and trandolapril/verapamil (Tarka Forte), was brought to the emergency department due to generalized weakness and altered condition. Initial prehospital vital signs included unmeasurable blood pressure, heart rate 79 bpm, oxygen saturation 97%, and blood glucose 189 mg/dL. The patient developed cardiac arrest five minutes after arrival at the emergency department.

Results and Conclusion: Cardiopulmonary resuscitation (CPR) was initiated immediately. Initial blood gas analysis revealed severe metabolic acidosis (pH 6.9, bicarbonate 6 mmol/L), hyperkalemia (6.5 mmol/L), and elevated lactate (unmeasurable). Calcium, sodium bicarbonate, and adrenaline were administered during CPR. Return of spontaneous circulation (ROSC) was achieved after 30 minutes. Post-ROSC, the patient remained hypotensive (40/20 mmHg) and bradycardic (40 bpm) with slow atrial fibrillation on ECG. Despite atropine administration,

aggressive fluid resuscitation, and vasopressor/inotropic support (noradrenaline, dopamine, dobutamine, and adrenaline infusion), the patient remained refractory. Laboratory findings showed acute kidney injury (creatinine 2.6 mg/dL), mild troponin elevation, and elevated liver enzymes. Imaging ruled out pulmonary embolism. The clinical picture was consistent with BRASH syndrome.BRASH syndrome should be considered in elderly patients using AV nodal blocking agents who present with shock and bradycardia, especially in the presence of renal dysfunction and hyperkalemia. Early recognition and targeted treatment are critical, as conventional resuscitation strategies may be insufficient. This case highlights the potential for rapid deterioration and cardiac arrest in BRASH syndrome.

Keywords: BRASH syndrome; hyperkalemia; bradycardia

Ref No: 5475

The Blood Glucose-to-Glasgow Coma Scale Ratio as an Early Risk Stratification Tool in Methanol Toxicity: A Pilot Study

Abdullah Yaser Güney[1], Mehmet Koşargelir[1], Selmani Doğan[1]
[1]Başakşehir Çam ve Sakura Şehir Hastanesi

Abdullah Yaser Güney / Başakşehir Çam ve Sakura Şehir Hastanesi

Introduction and Purpose: Rapid and practical tools for early risk assessment are needed in the emergency department for patients with methanol toxicity. Methanol causes central nervous system depression and may also lead to severe metabolic acidosis and visual impairment. The Glasgow Coma Scale (GCS) is widely used to assess consciousness, and lower GCS scores have been associated with increased mortality in methanol toxicity. Recent studies have also shown higher mortality among patients presenting with hyperglycemia. We therefore aimed to evaluate the association between the blood glucose-to-GCS ratio (Glu/GCS) and mortality.

Materials and Methods: This retrospective, observational, single-center study included patients admitted to the emergency department of a tertiary care hospital between March 1, 2024 and March 1, 2025, with suspected methanol ingestion and a blood methanol level > 0.5 mg/dL. The association between Glu/GCS and mortality was analyzed. Discriminatory performance was assessed by receiver operating characteristic (ROC) analysis, and area under the curve (AUC) values were compared using the DeLong test. The optimal cut-off value was determined by the Youden index.

ROC analysis of the variables

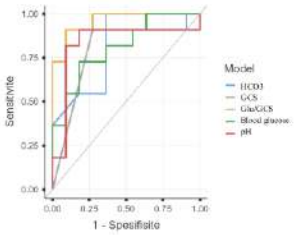

Figure 1. Receiver operating characteristic (ROC) curves of GCS, blood glucose, Glu/GCS ratio, pH, and HCO_3 in the early risk assessment of methanol toxicity.

Table 1. ROC analysis of variables for early risk assessment in methanol toxicity

Variable	AUC	Std. Error	Lower 95% CI	Upper 95% CI	p value
GCS	0.843	0.078	0.689	0.997	< .001
Glu/GCS	0.959	0.036	0.888	1.000	< .001
Blood glucose	0.810	0.093	0.627	0.993	< .001
pH	0.835	0.107	0.624	1.000	0.002
HCO_3	0.769	0.106	0.560	0.978	0.012

Abbreviations: AUC, area under the curve; CI, confidence interval; GCS, Glasgow Coma Scale; Glu/GCS, blood glucose-to-Glasgow Coma Scale ratio; HCO_3, bicarbonate.

Results and Conclusion: A total of 22 patients were included; 2 (9.1%) were female and 20 (90.9%) were male. In-hospital mortality occurred in 11 patients. GCS, pH, and bicarbonate levels were significantly lower in the mortality group, whereas blood glucose and the Glu/GCS ratio were significantly higher ($p=0.002$, $p=0.009$, $p=0.035$, $p=0.015$, and $p < 0.001$, respectively). In ROC analysis, the Glu/GCS ratio had the highest AUC (0.959, 95% CI 0.88–1.00, $p < 0.001$), followed by pH (0.835, 95% CI 0.62–1.00, $p=0.002$). However, the difference between AUCs was not significant by DeLong test ($p=0.27$). The optimal cut-off value for Glu/GCS was 29.83. The Glu/GCS ratio may be a promising bedside predictor of mortality in methanol toxicity. Because it combines two clinically relevant parameters and can be calculated at first medical contact, it may serve as a practical tool for early risk stratification. However, given the small sample size and retrospective design, these findings should be considered preliminary and require validation in larger prospective studies

Keywords: Toxicology, Emergency Medicine, Methanol Posioning

Ref No: 5506

A RARE EMERGENCY DEPARTMENT CASE: PENCIL PENETRATION INTO THE GLUTEAL REGION

MERVE AĞAÇKIRAN[1], MEHMET METİN[2], TUĞBA AKCAN[1]

[1]Hitit University Erol Olçok Research and Training Hospital,Department of Emergency Medicine,Çorum,Türkiye
[2]Hitit University Faculty of Medicine ,Department of Pediatric Surgery,Çorum,Türkiye

MERVE AĞAÇKIRAN / Hitit University Erol Olçok Research and Training Hospital,Department of Emergency Medicine,Çorum,Türkiye

Introduction and Purpose: Penetrating soft tissue injuries are common in emergency departments; however, injuries caused by everyday objects are relatively rare, particularly in the pediatric population. Due to its proximity to major vascular and neural structures, the gluteal region carries a significant risk of serious complications. We present a pediatric patient with pencil penetration into the gluteal region.

Materials and Methods: A 15-year-old male presented after being stabbed with a pencil in the left gluteus maximus by a schoolmate. He was stable, with a Glasgow Coma Scale of 15. Approximately 5.5 cm of the pencil was visible externally, while the internal length was unknown. Neurological examination was normal, distal pulses were palpable, and no active bleeding was present.Computed tomography (CT) revealed that the pencil had advanced approximately 15 cm within the subcutaneous tissue without fracturing. No major vascular or neural injury was detected, and the muscular fascia was intact.Under local anesthesia, the pencil was removed in a single attempt following the trajectory of entry. The integrity of the object was confirmed, and the wound was debrided. The patient had an uneventful course and was discharged with tetanus prophylaxis and antibiotics.

pencil into the gluteal region

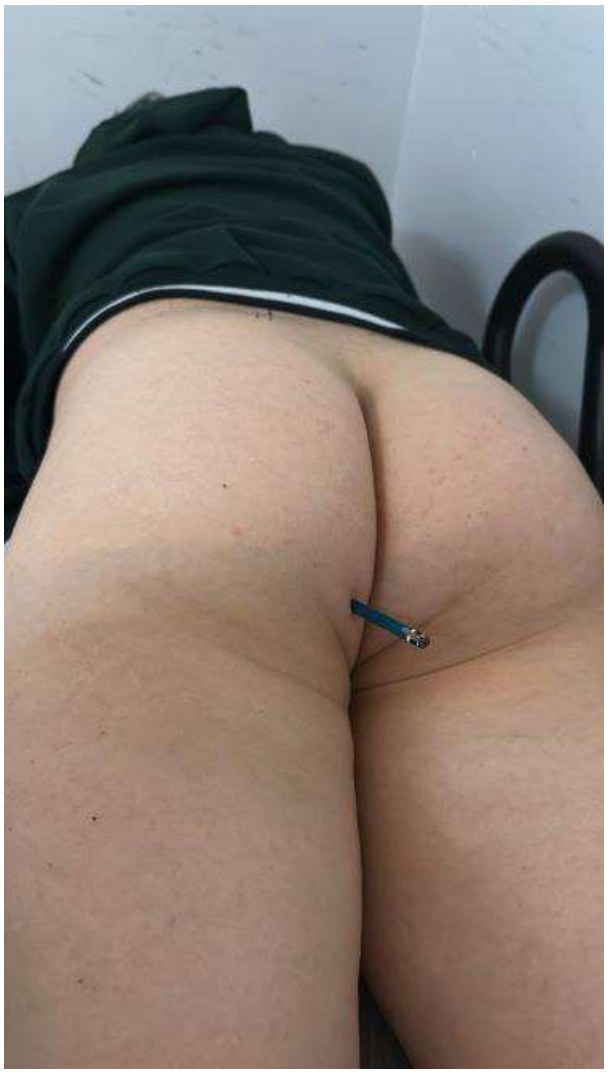

pencil into the gluteal region



pencil into the gluteal region

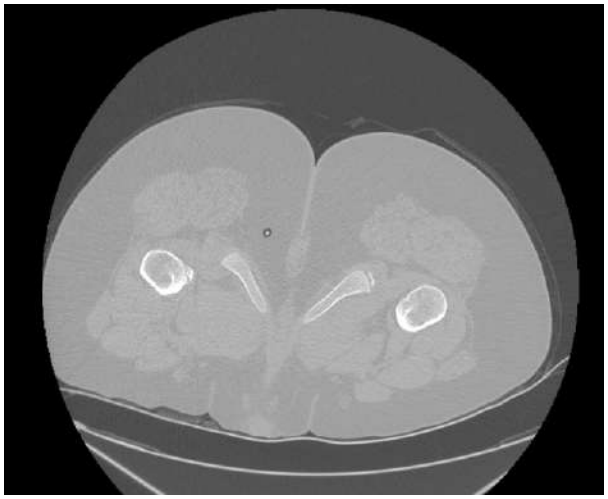

pencil into the gluteal region

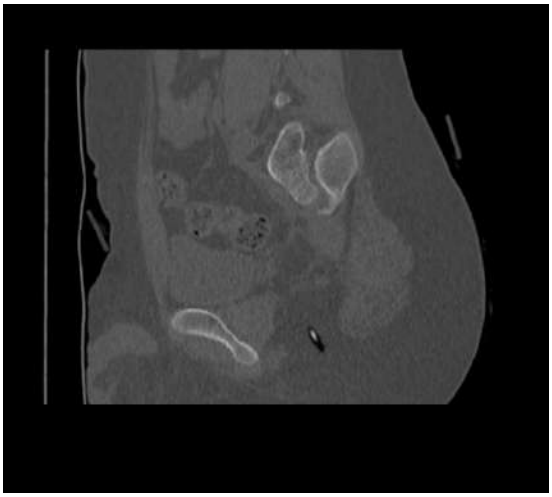

Results and Conclusion: In pediatric patients, penetrating injuries are often caused by everyday objects such as pencils or toys. While pencil injuries are typically reported in the extremities or orbital region, deep gluteal penetration is extremely rare. The gluteal region contains critical neurovascular structures, including the superior and inferior gluteal arteries and the sciatic nerve.Despite a 15 cm penetration in this case, the object remained confined to the subcutaneous tissue, preventing major complications. CT imaging played a crucial role in determining the trajectory and depth of the object and in guiding safe management. Blind removal may lead to fragmentation or occult bleeding and should be avoided. Proper wound care and complete removal are essential to prevent infectioIn pediatric penetrating injuries, the externally visible portion may be misleading. Advanced imaging and a multidisciplinary approach are essential for safe management and complication prevention.

pencil is outside



Keywords: pencil penetration, gluteal region, pediatric population

Ref No: 5524

Gastric perforation: An unusual complication after failed esophageal intubation

Vefa Cakmak[1], Mert Ozen[2]
[1]Pamukkale University, School of Medicine, Department of Radiology
[2]Pamukkale University, School of Medicine, Department of Emergency Medicine

Mert Ozen / Pamukkale University, School of Medicine, Department of Emergency Medicine

Introduction and Purpose: Iatrogenic gastric perforation is rare and most commonly occurs during surgical interventions, cardiopulmonary resuscitation, or gastric tube insertion (1). We aimed to present the computed tomography (CT) findings of gastric perforation secondary to failed intubation.

Materials and Methods: A 47-year-old male patient was brought to the emergency department by 112, following an in-vehicle traffic accident. It was learned that endotracheal intubation had been performed by 112 staff due to loss of consciousness and a 8 in the Glasgow Coma Scale score of the patient. As breath sounds could not be detected after ventilation with an Ambu-bag and oxygen saturation did not improve, the initial intubation was considered unsuccessful, and a second intubation attempt was performed.Computed tomography revealed a right temporal intraparenchymal hemorrhage in the brain. Thoracic CT demonstrated that the endotracheal tube was correctly positioned within the trachea. In addition, a contusion area was observed in the anterior segment of the right upper lobe, along with minimal left-sided pneumothorax. On abdominal CT, the stomach and intestinal loops were markedly distended with air, and diffuse free air was observed within the intraperitoneal cavity (Figures 1 and 2).



Figure 1



Figure 2

Results and Conclusion: In routine clinical practice, bilateral breath sounds, pulse oximetry, and oxygen saturation measurements are commonly used to confirm correct endotracheal tube placement. Fixation error, confirmation bias, and overconfidence are among the major factors leading to inadvertent esophageal intubation (2, 3).Iatrogenic gastric perforation is a life-threatening condition associated with significant morbidity and mortality, requiring urgent surgical intervention. The most common site of gastric perforation is the lesser curvature of the stomach. The relatively lower elasticity of this region, fewer mucosal folds, and its fixation by the hepatogastric ligament increase its susceptibility to perforation (4). In conclusion, early recognition of iatrogenic gastric perforation resulting from inadvertent esophageal intubation is critical for reducing morbidity and mortality.

Keywords: endotracheal intubation, gastric perforation, computed tomography

---

Ref No: 5532

Roux-en-Y Conversion and Endoscopic Stenting in Leak Management After Revision Mini -Gastric Bypass:A Case Complicated by Stent Migration

MERVE AĞAÇKIRAN[1], İBRAHİM AĞAÇKIRAN[2]

[1]Hitit University Erol Olçok research and Training Hospital,Emergency Department,Çorum ,Türkiye
[2]Altınbaş University, Medical Park Bahçeliecler Hospital,General Surgery Department,İstanbul,Türkiye

MERVE AĞAÇKIRAN / Hitit University Erol Olçok research and Training Hospital,Emergency Department,Çorum ,Türkiye

Introduction and Purpose: Obesity is a major global health problem associated with significant comorbidities, and bariatric surgery remains the most effective treatment for sustained weight loss. However, postoperative leaks are among the most serious complications, particularly in revision procedures, due to altered anatomy and impaired tissue perfusion. Endoscopic stenting is increasingly used as a minimally invasive treatment option, although complications such as stent migration may occur. This study aims to present a case of postoperative leak following revision mini-gastric bypass managed with Roux-en-Y conversion and endoscopic stenting, complicated by stent migration.

Materials and Methods: A 47-year-old female presented to the emergency department with severe abdominal pain. She had a history of sleeve gastrectomy six years earlier and revision

mini-gastric bypass performed six days prior. Physical examination revealed diffuse abdominal tenderness with guarding and rebound. Laboratory analysis showed leukocytosis (22,000/mm³). Contrast-enhanced computed tomography demonstrated intra-abdominal contrast extravasation. The patient underwent emergency surgery. Intraoperative findings revealed purulent fluid and dense adhesions. The gastroenterostomy was intact, but a leak was identified at the remnant stomach staple line and confirmed by intraoperative endoscopy. A Roux-en-Y gastric bypass conversion, omentopexy, and endoscopic placement of a self-expandable metal stent were performed.The postoperative course was initially uneventful, and the patient was discharged on postoperative day 10 following clinical and laboratory improvement. On postoperative day 27, she developed recurrent abdominal pain after jumping to swimming pool. Imaging revealed distal migration of the stent into the small intestine. Endoscopic removal and repositioning were successfully performed. No further migration occurred, and the stent was removed after four weeks with complete recovery.

abdominal CT

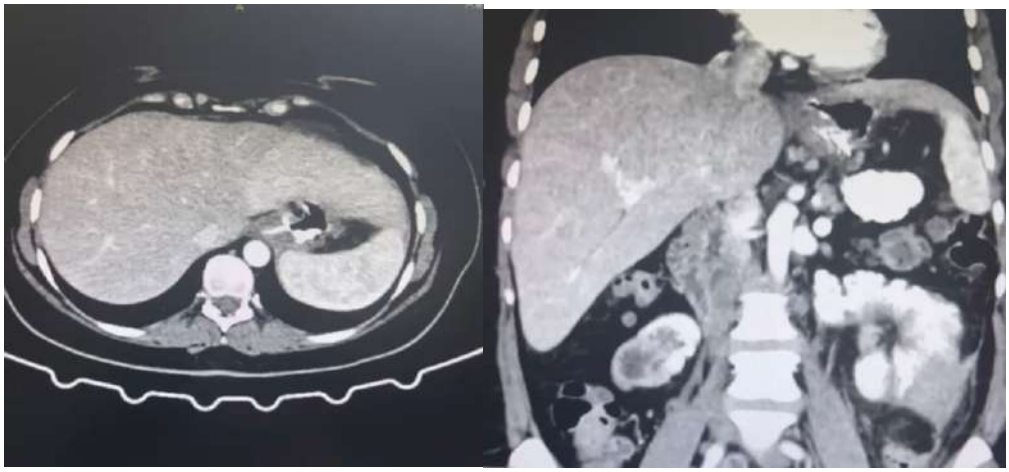

Results and Conclusion: Postoperative leak management after bariatric surgery remains complex, particularly in revision cases. This case demonstrates that a combined approach involving surgical revision and endoscopic stenting can provide effective leak control and favorable outcomes. However, stent migration represents a significant complication that may be triggered by factors such as increased intraluminal pressure or sudden physical activity. Therefore, close follow-up and careful patient counseling regarding activity restrictions are essential. This case highlights the importance of a multidisciplinary strategy and contributes to the growing evidence supporting combined therapeutic approaches in managing bariatric surgery-related leaks.

Keywords: bariatric surgery, stent migration, abdominal pain

Ref No: 5591

Paget-Schroetter Syndrome: A Case Of Upper Extremıty Deep Veın Thrombosıs Developıng After Household Chores

Nevzat HERGÜL[1], Sevdegül KARADAŞ[1], Mehmet Reşit ÖNCÜ[1], Gizem GİZLİ TAN[1]
[1]Van Yüzüncü Yıl University, Faculty of Medicine

Mehmet Reşit ÖNCÜ / Van Yüzüncü Yıl University, Faculty of Medicine

Introduction and Purpose: Paget-Schroetter syndrome (PSS) is a rare form of primary upper extremity deep vein thrombosis caused by repetitive arm movements and venous compression at the thoracic outlet. It is classically associated with athletes and strenuous occupational activity, but repetitive daily tasks may also act as precipitating factors. The aim of this case is to highlight household chores as a potential trigger for PSS in the absence of conventional thrombotic risk factors.

Materials and Methods: A 44-year-old woman presented to the emergency department with pain and progressive swelling in her dominant right arm after intensive household activities, including window cleaning and hanging curtains. The pain improved with rest but worsened with movement and palpation. Her medical history was unremarkable. She had no history of oral contraceptive use, trauma, malignancy, surgery, recent immobilization, or known thrombophilia. Family history was negative for thromboembolic disease.Vital signs were stable, with a temperature of 36.8°C, blood pressure of 125/80 mmHg, and pulse rate of 78/min. Physical examination revealed edema extending from the proximal right arm to the elbow, tenderness in the axillary region, and pain exacerbated by arm movement.Distal pulses were palpable, and no neurovascular deficit was detected (Figure 1). Complete blood count and coagulation parameters were within normal limits. Plain radiographs of the right shoulder and humerus showed no abnormal findings. Color Doppler ultrasonography demonstrated intraluminal hyperechoic material and flow defects consistent with acute thrombosis in the right axillary and subclavian veins. Cardiovascular surgery consultation was obtained. Because the patient was clinically stable, outpatient treatment with enoxaparin 1 mg/kg/day was initiated, and weekly follow-up was arranged. At the first control visit, her symptoms had improved.



Figure 1

Appearance of edema in the right upper extremity (dominant side).

Results and Conclusion: This case illustrates that PSS may occur after routine repetitive upper extremity activity, not only after athletic or occupational exertion. The absence of classical risk factors makes the history of recent repetitive arm use particularly important. In patients presenting with acute unilateral arm pain and swelling, PSS should be considered, especially when symptoms follow intense arm activity. Color Doppler ultrasonography remains a valuable first-line imaging method for diagnosis. Early recognition and appropriate anticoagulant treatment are essential to reduce morbidity and prevent progression or recurrence.

Keywords: Paget-Schroetter syndrome, upper extremity deep vein thrombosis, household chores

---

Ref No: 5621

Evaluation of the Relationship Between Inflammatory Markers and Metabolic Parameters in Diabetic Patients

Zeynep Keser1, Azize Yetişgen2
1Malatya Turgut Özal University, Faculty of Medicine, Department of Emergency Medicine,
2Malatya Training and Research Hospital, Department of Infectious Diseases

Introduction and Purpose:
The aim of this study is to evaluate the relationship between inflammatory markers (CRP, ferritin, sedimentation rate) and metabolic parameters and albumin levels in diabetic patients.

Materials and Methods:
A total of 31 diabetic patients were included in the study. Demographic characteristics, anthropometric measurements, and laboratory parameters of the patients were analysed retrospectively. The distribution of data was evaluated with the Kolmogorov-Smirnov test. The Spearman correlation test was used in the correlation analysis due to the non-parametric distribution. An independent samples t-test was applied for comparisons between genders.

Results and Conclusion:
The mean age of the patients was 65.45 ± 9.97 years, and 67.7% were male. The mean BMI was found to be 28.95 ± 4.58 kg/m². No significant difference was found between genders in terms of BMI (t = -1.53, p = 0.150). A significant positive correlation was

found between CRP and ferritin ($r = 0.62$, $p < 0.001$). Similarly, a significant positive correlation was found between CRP and sedimentation rate ($r = 0.58$, $p < 0.001$). A negative correlation was found between albumin levels and CRP ($r = -0.55$, $p < 0.01$), while a negative relationship was also observed between albumin and ferritin ($r = -0.49$, $p < 0.01$). Strong associations exist between inflammatory markers in diabetic patients. When increased inflammation is evaluated in conjunction with decreased albumin levels, it may be indicative of chronic inflammation and poor metabolic control.

Keywords: diabetic foot, ferritin, CRP

Ref No: 5700

The critical role of anamnesis in young patients with chest pain: a case of ekg-negative myocarditis

Bekir Görkem[1], Mesut Yıldız[1], Mithat Toruk[1], Dilara İbiş[1], Mehmet Gül[1]
[1]Emergency Medicine Department, Konya City Hospital, Türkiye
Dilara İbiş / Emergency Medicine Department, Konya City Hospital, Türkiye

Introduction and Purpose: Emergency department presentations of chest pain and palpitations in young adults may herald various serious cardiac and non-cardiac conditions. Myocarditis is an inflammatory disorder, typically secondary to viral agents, with a clinical spectrum ranging from asymptomatic courses to fulminant cardiogenic shock. Patients may present with symptoms mimicking acute myocardial infarction, often accompanied by elevated cardiac biomarkers (troponins). Given that the management and treatment strategies for these two clinical entities are fundamentally diametrical, prompt and accurate diagnosis is of vital importance to protect the patient from unnecessary invasive interventions.

Materials and Methods: A 27-year-old female patient with no cardiovascular risk factors presented to the emergency department with sudden-onset palpitations and chest pain. Upon evaluation, the patient's vital signs were stable, and the electrocardiogram (ECG) revealed a normal sinus rhythm without any ischemic ST-T wave changes. However, due to significantly elevated cardiac troponin levels in blood tests, the medical history was further detailed, revealing that the patient had an upper respiratory tract infection (URTI) ten days prior. Given the young age, normal ECG, troponin elevation, and history of prodromal infection, the suspicion of myocarditis increased. The patient was evaluated via echocardiography by the cardiology clinic; no ischemic findings were observed. Following the exclusion of ACS, the patient was admitted to the ward with a preliminary diagnosis of acute myocarditis.

Results and Conclusion: Acute myocarditis is an inflammatory disease of the myocardium, frequently developing secondary to viral agents, and is one of the most significant conditions mimicking ACS in clinical practice. Most sources emphasize that myocarditis closely resembles ACS due to ST-segment changes. In the presented case, however, the ECG showed a normal sinus rhythm (NSR) with no ischemic changes or ST elevation. Therefore, in patients with cardiac enzyme elevation and chest pain, a completely normal sinus rhythm on ECG does not rule out the possibility of acute myocarditis. Particularly in young patients, a detailed anamnesis and the questioning of a recent viral infection history are the most critical steps for diagnosis. Through rapid interdisciplinary evaluation, an accurate diagnosis can be established, protecting patients from unnecessary invasive procedures and the risks of anticoagulant therapies.

Keywords: Acute myocarditis, Acute coronary syndrome, Chest pain

---

Ref No: 5743

Chest Pain Misleading the Diagnosis: A Case of Aortic Dissection Mimicking Acute Myocardial Infarction

Enes Akınci[1], Sultan Tuna Akgöl Gür[1]
[1]Atatürk University Research Hospital
Enes Akınci / Atatürk University Research Hospital

Introduction and Purpose: Chest pain is one of the most frequent causes of emergency department admissions and is often associated with acute coronary syndromes. However, certain life-threatening conditions such as aortic dissection may present with similar clinical findings, leading to potential misdiagnosis and inappropriate treatment.

Materials and Methods: A 54-year-old male presented to the emergency department with sudden onset severe chest pain radiating to the back. The pain was described as tearing in nature and began approximately one hour prior to admission. The patient also reported diaphoresis and mild shortness of breath. His medical history was significant for poorly controlled hypertension, and he was not compliant with his medications.On physical examination, the patient appeared distressed and diaphoretic. His blood pressure was 160/90 mmHg in the right arm and 130/80 mmHg in the left arm. Heart rate was 105 beats per minute, and oxygen saturation was 96% on room air. Cardiovascular examination revealed no obvious murmur, but peripheral pulses were noted to be asymmetric.Electrocardiography demonstrated ST-segment elevations in the inferior leads, raising strong suspicion for an acute myocardial infarction. Based on these findings, the patient was initially considered a candidate for urgent reperfusion therapy. However, the presence of tearing chest pain radiating to the back, inter-arm blood pressure discrepancy, and

pulse asymmetry prompted further evaluation before initiating antithrombotic treatment.An emergent computed tomography angiography (CTA) of the chest was performed, which revealed an intimal flap extending from the ascending aorta to the descending thoracic aorta.The patient was diagnosed with Aortic Dissection, a life-threatening condition that can closely mimic acute myocardial infarction both clinically and electrocardiographically. The patient was immediately started on intravenous beta-blocker therapy for heart rate and blood pressure control and was urgently referred for cardiothoracic surgery.

Results and Conclusion: This case highlights the critical importance of recognizing red flag features in patients presenting with chest pain. Although ST-segment elevation typically indicates myocardial infarction, it may rarely be seen in Aortic Dissection due to coronary artery involvement. Administering antiplatelet or anticoagulant therapy in such cases can have catastrophic consequences.

Keywords: Aortic Dissection, ST-segment elevations

Ref No: 5790

Abdominal pain as a mask for severe pneumonia: A case of lower lobe involvement in a young adult

Dr. Enes YILMAZ[1], Dr. Merve BULUT[1], Asst. Prof. Dr. Mevlana GÜL[1]
[1]Ataturk University Emergency Department
Dr. Merve BULUT / Ataturk University Emergency Department

Introduction and Purpose: Abdominal pain is a frequent presenting complaint in the emergency department (ED). While typically associated with intra-abdominal pathology, lower lobe pneumonia can present as referred pain to the upper quadrants, mimicking acute surgical abdomen. This diagnostic challenge is particularly critical in young patients where respiratory symptoms may be secondary. The objective of this report is to emphasize the clinical importance of considering pulmonary etiologies in patients presenting with isolated upper quadrant pain and severe systemic inflammatory signs.

Materials and Methods: A 28-year-old male with no prior medical or surgical history presented to the ED with a two-day history of severe abdominal pain. On admission, the patient was febrile (38.9°C) and tachycardic (151 bpm), with a blood pressure of 114/69 mmHg and severe hypoxemia (spO2: 84). Physical examination revealed tenderness in the upper abdominal quadrants; however, there was no defense or rebound. Lung auscultation was significant for rales at the right lung base, while the remainder of the physical examination was unremarkable.

Laboratory tests and X-ray were ordered. Upon identifying bilateral pneumonia on the X-ray, a chest computed tomography (CT) scan was performed for a more definitive diagnosis and to evaluate the extent of pulmonary involvement.

PA lung x-ray

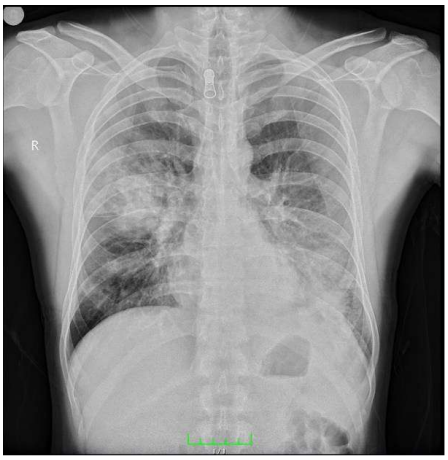

Results and Conclusion: Chest CT confirmed consolidated areas in the right upper and left lower lobes, along with a left-sided parapneumonic effusion. Laboratory findings were consistent with severe infection. The patient's abdominal pain was attributed to referred pain from lower lobe pneumonia. In conclusion, the absence of peritoneal signs (defense and rebound) in a patient with upper quadrant pain should prompt a thorough pulmonary evaluation. Early recognition of pneumonia in patients presenting with "abdominal" symptoms is vital for timely antibiotic initiation and respiratory support.

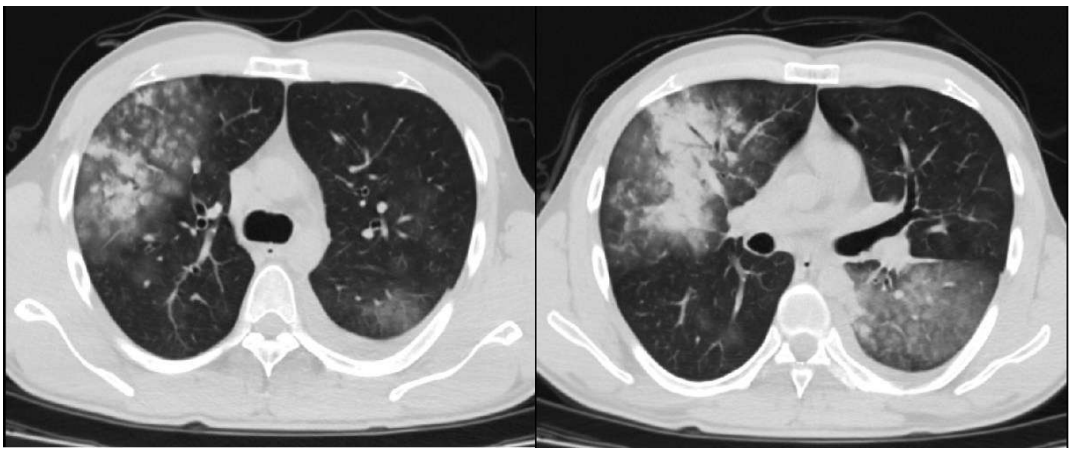

tomography1 tomography2

tomography3



Keywords: Lower lobe pneumonia, Abdominal pain, Referred pain

---

Ref No: 5813

Platelet Distribution Width as an Early Triage Marker for Ruptured Abdominal Aortic Aneurysm in the Emergency Department

Sefer Kaya[1], Metin Onur Beyaz[1]

[1]Hatay Mustafa Kemal Üniversitesi Kalp ve Damar Cerrahisi

Sefer Kaya / Hatay Mustafa Kemal Üniversitesi Kalp ve Damar Cerrahisi

Introduction and Purpose: A rapid, inexpensive biomarker that helps distinguish ruptured abdominal aortic aneurysm (rAAA) from non-ruptured AAA at emergency department presentation would be clinically valuable. We investigated whether admission platelet distribution width (PDW), a routinely available complete blood count parameter reflecting platelet size heterogeneity and activation, is associated with aneurysm rupture in patients presenting with abdominal pain.

Materials and Methods: In this single-center retrospective observational study, we reviewed consecutive adults diagnosed with AAA between January 2020 and December 2025. In line with the study protocol, only patients presenting with abdominal pain and available admission blood count results were included. Patients were classified as rAAA or non-rAAA according to

imaging and/or intraoperative findings. Demographics, vital signs, laboratory values, aneurysm morphology, treatment type, and outcomes were analyzed. PDW was compared between groups, and multivariable logistic regression adjusted for age and maximum aneurysm diameter was used to assess the independent association between PDW and rupture. Receiver operating characteristic analysis evaluated discriminatory performance.

Computed Tomography Findings of Ruptured Abdominal Aortic Aneurysm: Coronal Wiew



Computed Tomography Findings of Ruptured Abdominal Aortic Aneurysm: Axial Wiew



Computed Tomography Findings of Non-Ruptured Abdominal Aortic Aneurysm: Coronal Wiew



Computed Tomography Findings of Non-Ruptured Abdominal Aortic Aneurysm: Axial Wiew



Evolution of Grey Turner Sign Following Ruptured Abdominal Aortic Aneurysm: Day 1 and Day 2 Findings



Results and Conclusion: A total of 221 patients were included; 14 (6.3%) had rAAA. Median PDW was significantly higher in the rAAA group than in the non-rAAA group (16.9 [16.5–17.7] vs 15.3 [14.8–15.9] fL, $p < 0.001$). Ruptured cases also had lower systolic blood pressure, lower hemoglobin levels, lower platelet counts, higher heart rates, and larger aneurysm diameters (all $p < 0.01$). In multivariable analysis, PDW remained independently associated with rupture (adjusted OR 9.24 per 1-fL increase, 95% CI 2.91–29.32; $p < 0.001$), together with maximum aneurysm diameter (adjusted OR 1.09 per mm, 95% CI 1.01–1.17; p=0.026). PDW showed excellent discrimination for rupture (AUC 0.93); an exploratory cutoff of 16.0 fL yielded 92.9% sensitivity and 78.3% specificity.Admission PDW was strongly associated with rupture among AAA patients presenting with abdominal pain. As a rapid and inexpensive biomarker derived from routine blood count testing, PDW may support early risk stratification and triage in the emergency setting.

Keywords: Abdominal aortic aneurysm, Rupture, Platelet distribution width

Ref No: 5830

From dental infection to life-threatening emergency: A case of Ludwig's angina

Dr. Enes YILMAZ[1], Dr. Şamil Emin YALÇIN[1], Asst. Prof. Dr. Mevlana GÜL[1]

[1]Ataturk University Emergency Department

Dr. Şamil Emin YALÇIN / Ataturk University Emergency Department

Introduction and Purpose: Ludwig's angina is a rapidly progressive, life-threatening cellulitis of the floor of the mouth, involving the submandibular, sublingual, and submental spaces. Up to 85% of cases originate from untreated odontogenic infections. Although it is primarily a clinical diagnosis, imaging is vital to assess airway patency and identify abscesses. The objective of this report is to emphasize the clinical recognition of Ludwig's angina triggered by a dental infection to prevent fatal airway obstruction or mediastinal spread.

Materials and Methods: A 45-year-old female patient with a history of hypertension presented to the emergency department (ED) with a primary complaint of neck pain. She reported a dental infection that occurred one week prior to admission. On initial assessment, her vital signs were: blood pressure 148/89 mmHg, pulse rate 104 bpm, oxygen saturation spO2: 96, and body temperature 37.8°C. Physical examination revealed mild edema on the neck upon inspection, with palpable warmth and tenderness. Neurovascular examination was normal. Laboratory tests showed a white blood cell (WBC) count of 16,400/µL with a left shift and a C-reactive protein (CRP) level of 37 mg/dL.

Results and Conclusion: Given the clinical suspicion of deep neck infection and Ludwig's angina, empiric antibiotic therapy was initiated immediately. Computed tomography (CT) imaging was performed to delineate the extent of the infection. The CT scan revealed diffuse edema within and between the affected submandibular, sublingual, and submental spaces, along with the presence of an abscess, confirming the diagnosis of Ludwig's angina. In conclusion, early recognition of Ludwig's angina is critical for emergency physicians. Patients presenting with neck swelling and a recent history of dental procedures or infections require a high index of suspicion. Rapid initiation of antibiotics and advanced imaging such as CT are essential to prevent airway compromise and facilitate surgical intervention when necessary.



tomography1



tomography2

tomography3



Keywords: Ludwig's angina, Deep neck infection, Dental infection

Ref No: 5845

D-Dimer/Albumin Ratio for Predicting Clinical Outcomes in Acute Pancreatitis: A Retrospective Study

Elif Betül Balcı[1], Bahadır Taşlıdere[1], Başar Cander[1]

[1]Bezmialem Vakif University, Faculty of Medicine, Department of Emergency Medicine

Elif Betül Balcı / Bezmialem Vakif University, Faculty of Medicine, Department of Emergency Medicine

Introduction and Purpose: Acute pancreatitis is an inflammatory disease with a wide clinical spectrum, ranging from mild, self-limiting cases to severe forms complicated by organ failure. Approximately 15–20% of patients develop severe disease, highlighting the importance of early risk stratification. Practical and reliable biomarkers are needed to support clinical decision-making. D-dimer reflects activation of coagulation and fibrinolysis and is associated with systemic inflammation and poor outcomes. Albumin, a negative acute-phase reactant, provides information on inflammatory status, nutritional state, and intravascular volume but may be influenced by fluid imbalances such as dehydration and hemoconcentration. The D-dimer/albumin (D/A) ratio has emerged as a composite biomarker integrating these processes. This study aimed to evaluate the prognostic value of D-dimer, albumin, and the D/A ratio for predicting disease severity, intensive care unit (ICU) requirement, and in-hospital mortality.

Materials and Methods: This retrospective study included 220 patients with acute pancreatitis. The predictive performance of D-dimer, albumin, and the D/A ratio for disease severity, ICU admission, and mortality was assessed. Receiver operating characteristic (ROC) analysis was used to determine discriminative ability, and area under the curve (AUC), sensitivity, specificity, and optimal cut-off values were calculated. Multivariable regression analyses were performed to identify independent predictors.

Results and Conclusion: The cohort included 104 males (47.3%) and 116 females (52.7%), with a mean age of 57.97 ± 14.28 years. Severe disease occurred in 30.5% of patients, ICU admission in 10.9%, and mortality in 10.0%. Overall discriminative performance was modest (AUC: 0.428–0.682). The D/A ratio showed the highest performance for predicting ICU requirement (AUC: 0.682) and disease severity, while D-dimer was most strongly associated with mortality. In multivariable analyses, D-dimer and the D/A ratio were independent predictors, whereas albumin was not. Despite statistical significance, discriminative ability remained limited, with no biomarker achieving an AUC above 0.70. The D/A ratio outperformed individual markers, likely reflecting combined pathophysiological processes. High specificity but low sensitivity limits screening utility but may support identification of high-risk patients. D-dimer and the D/A ratio

are independent prognostic markers in acute pancreatitis; however, their standalone clinical utility is limited. The D/A ratio may add value when integrated into established scoring systems such as BISAP, Ranson, and APACHE-II.

Figure 1

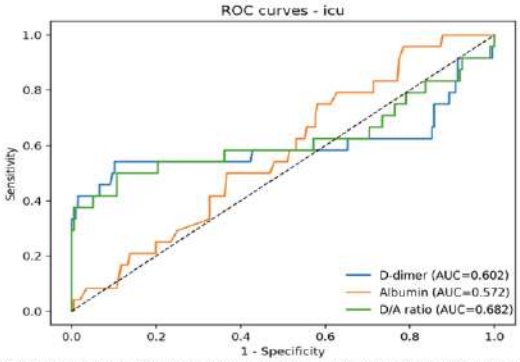

Figure 1: ROC curves of D-dimer, albumin, and D/A ratio for the prediction of intensive care unit requirement.

Keywords: Acute Pancreatitis, Prognosis, D-Dimer/Albumin Ratio

---

Ref No: 5865

Cerebral Hydatid Cyst Cases

Bünyamin Baytemür[1]

[1]Düzce University, Department of Emergency Medicine, Düzce, Türkiye; Private Medical Park Ordu Hospital, Department of Radiology, Ordu, Türkiye

Bünyamin Baytemür / Düzce University, Department of Emergency Medicine, Düzce, Türkiye; Private Medical Park Ordu Hospital, Department of Radiology, Ordu, Türkiye

Introduction and Purpose: Cerebral hydatid cyst is a rare manifestation of cystic echinococcosis caused by Echinococcus granulosus. Although the liver and lungs are the most commonly affected organs, intracranial involvement may occur and lead to serious neurological complications. Early diagnosis is critical, particularly in endemic regions. We aimed to present two patients with giant cerebral hydatid cysts diagnosed by computed tomography (CT) in the emergency department and to emphasize the importance of considering this entity in the differential diagnosis of large intracranial cystic lesions.

Materials and Methods: This study was designed as a two-case report. Clinical presentation, emergency department evaluation, radiological findings, and early management data were reviewed retrospectively from the medical records and imaging findings of two patients diagnosed with cerebral hydatid cyst.

Computed tomography findings of case 1, Computed tomography findings of case 2

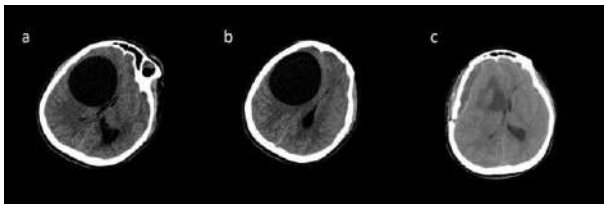

Figure 1. Case 1: Axial brain computed tomography images demonstrate a giant right hemispheric cerebral hydatid cyst with marked mass effect; additional thoracoabdominal images show associated hepatic and pulmonary hydatid cysts. Figure 2. Case 2: Axial brain computed tomography images show a large right frontal cerebral hydatid cyst before surgery and the postoperative appearance after intact cyst removal.

Results and Conclusion: The first patient was a 6-year-old refugee child presenting with headache and altered consciousness. Contrast-enhanced brain CT demonstrated a well-circumscribed 11×10×9 cm cystic lesion occupying the right frontotemporoparieto-occipital region with marked mass effect and ventricular compression. Additional imaging revealed concomitant hepatic and pulmonary hydatid cysts. The second patient was a 25-year-old pregnant Syrian woman admitted after trauma with headache and confusion. Brain CT revealed a giant right frontal cystic lesion compatible with cerebral hydatid cyst. In both patients, the diagnosis was supported radiologically, and the cysts were surgically removed intact without rupture. Cerebral hydatid cyst should be considered in patients with neurological symptoms and large, spherical, well-defined intracranial cystic lesions, especially in endemic areas. CT plays a key role in early recognition and timely neurosurgical referral.

Comparison of the clinical, radiological, and operative findings of the two cases

ParameterCase 1Case 2

Age/Sex6-year-old child25-year-old pregnant woman

PresentationHeadache and altered consciousnessHeadache and confusion after trauma

Nationality/BackgroundRefugee childSyrian pregnant woman

Brain CT findingGiant right frontotemporoparieto-occipital cystic lesionGiant right frontal cystic lesion

Size11 × 10 × 9 cmLarge intracranial cystic lesion

Mass effectMarked mass effect with ventricular compressionSpace-occupying effect present

Additional organ involvementHepatic and pulmonary hydatid cystsNo additional extracranial involvement reported

Treatment/OutcomeSurgical removal without ruptureSurgical removal without rupture

Keywords: Cerebral hydatid cyst; computed tomography; emergency department; echinococcosis; case report

---

Ref No: 5878

Long-term trends of climate-related disasters in Türkiye: an analysis of the EM-DAT database

Mustafa Öcal[1]

[1]Ufuk University Dr Rıdvan Ege Hospital

Mustafa Öcal / Ufuk University Dr Rıdvan Ege Hospital

Introduction and Purpose: Climate-related disasters represent an increasing global environmental and public health challenge. Floods, storms, landslides, wildfires, extreme temperature events, and avalanches can lead to substantial mortality and affect large populations. Due to its diverse geography and climatic characteristics, Türkiye is exposed to multiple climate-related hazards. However, nationwide analyses examining the long-term epidemiology of climate-related disasters remain limited. This study aimed to evaluate the distribution, mortality patterns, affected populations, and temporal trends of climate-related disasters in Türkiye using the Emergency Events Database (Emergency Events Database; EM-DAT).

Materials and Methods: This retrospective descriptive study analyzed all climate-related disasters recorded in Türkiye in the EM-DAT database between 1948 and 2025. Disasters were categorized as floods, storms, landslides, wildfires, extreme temperature events, and avalanches. Extracted variables included disaster type, year of occurrence, number of deaths, and number of

affected individuals. Descriptive statistical methods were used to assess disaster distribution, total mortality, average deaths per event, affected populations, and temporal trends.

Results and Conclusion: A total of 93 climate-related disasters were recorded in Türkiye during the study period. Floods represented the most frequent disaster type and were responsible for the largest number of deaths and affected individuals. Landslides and avalanches were also associated with considerable mortality. When mortality was evaluated on a per-event basis, avalanches demonstrated the highest average number of deaths per disaster, indicating high severity despite their relatively low frequency. Floods affected the largest number of individuals, followed by wildfires. Temporal analysis revealed an increasing trend in the number of climate-related disasters, particularly after the 2000s. These findings highlight the growing importance of strengthening disaster risk reduction strategies, improving flood management, and enhancing early warning systems in Türkiye.

Figure 1. Distribution of climate-related disasters by type in Türkiye.

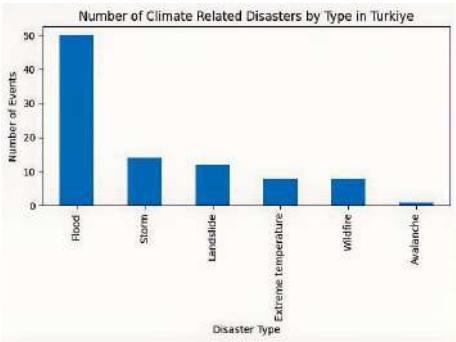

Figure 2. Total deaths by disaster type in Türkiye.

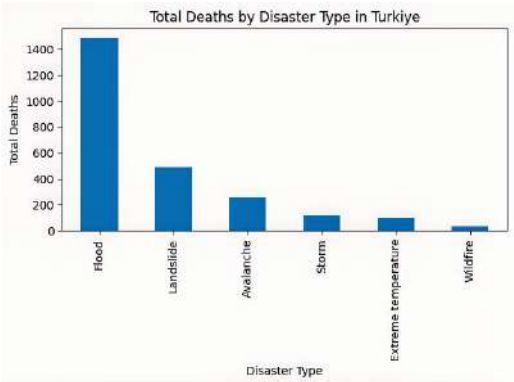

Figure 3. Average deaths per event by disaster type in Türkiye.

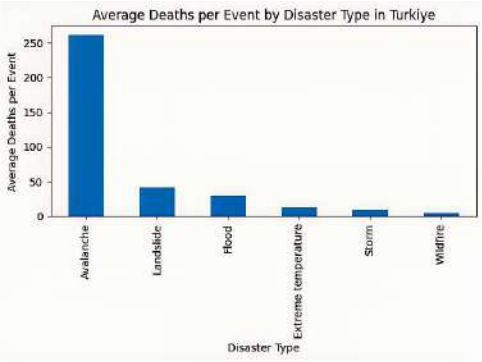

Figure 4. Total affected population by disaster type in Türkiye.

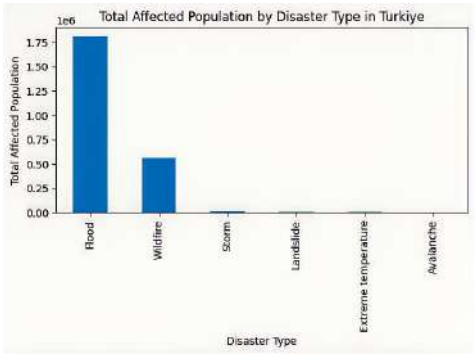

Figure 5. Number of climate-related disasters by year in Türkiye.

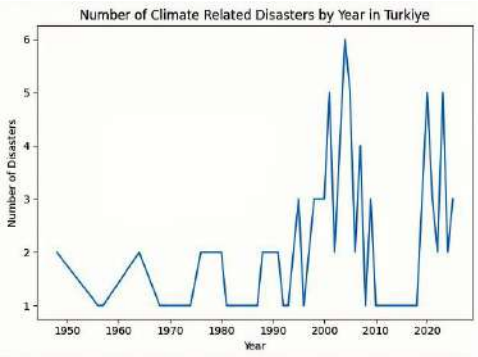

Keywords: Climate-related disasters, EM-DAT, Disaster epidemiology

Ref No: 5941

Septic Embolic Presentation of Enterococcus faecalis Endocarditis in a Hemodialysis Patient

Salih KARAKOYUN[1], Meltem YILMAZ[1]

[1]Düzce University School of Medicine, Department of Emergency Medicine, Düzce, Turkey.

Salih KARAKOYUN / Düzce University School of Medicine, Department of Emergency Medicine, Düzce, Turkey.

Introduction and Purpose: Infective endocarditis (IE) remains a life-threatening condition, particularly in patients undergoing chronic hemodialysis (HD), where the incidence is markedly higher than in the general population. Repeated vascular access, central venous catheter use, and immune dysfunction contribute to increased susceptibility. Although Staphylococcus aureus is the most common causative pathogen, Enterococcus faecalis is increasingly recognized in elderly and comorbid HD patients. This report aims to highlight a rare presentation of right-sided IE involving the tricuspid valve in a non–intravenous drug user undergoing HD.

Materials and Methods: A 71-year-old male patient was admitted to the emergency department with hypotension (80/50 mmHg) and transient loss of consciousness. He had a history of end-stage renal disease and had been on hemodialysis for 2.5 years, with increased dialysis frequency in the preceding two weeks. He reported a one-week history of fever (up to 38°C), fatigue, gait disturbance, and cough. Physical examination revealed stable oxygen saturation (96%) and no remarkable cardiopulmonary findings. Laboratory investigations showed elevated inflammatory markers (CRP: 26.99 mg/L) and troponin (202.3 ng/L). Thoracic and abdominal computed tomography scans did not reveal an infectious focus. Diffusion-weighted brain MRI demonstrated multiple areas of restricted diffusion, suggestive of embolic phenomena. Transthoracic echocardiography revealed a mobile vegetation measuring 25.3 × 12.2 mm on the tricuspid valve, with preserved left ventricular ejection fraction (60%). Blood cultures grew Enterococcus faecalis.

“The areas demonstrating diffusion restriction on diffusion-weighted MRI are shown in the figure.”

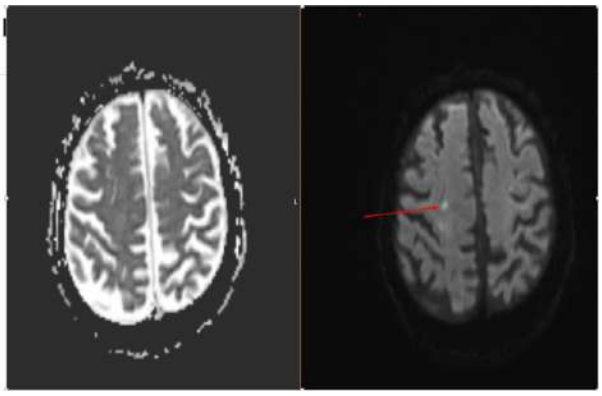

Results and Conclusion: Based on echocardiographic findings and positive blood cultures, the patient was diagnosed with tricuspid valve infective endocarditis, likely secondary to a hemodialysis catheter. The presence of large vegetation and cerebral embolic findings indicated a high-risk clinical course. The patient was admitted to the infectious diseases service, and appropriate intravenous antibiotic therapy along with catheter management was initiated. This case underscores the importance of considering IE in HD patients presenting with nonspecific symptoms such as fever, hypotension, and altered mental status. Early echocardiographic evaluation and prompt microbiological diagnosis are essential for timely treatment and reduction of morbidity and mortality.

Keywords: Infective endocarditis, Hemodialysis, Septic embolism

---

Ref No: 6006

Myofascial Chest Pain That May Be Mistaken for Cardiac Pain in the Emergency Department: A Narrative Review

Muhammet Şahin Elbastı[1], Nevzat Yeşilmen[1], Muhammed Korkmaz[1], Muhammed Ekmekyapar[2]

[1]Department of Physical Medicine and Rehabilitation, Elazığ Fethi Sekin City Hospital, Elazığ, Türkiye
[2]Department of Emergency Medicine, Elazığ Fethi Sekin City Hospital, Elazığ, Türkiye

Muhammed Ekmekyapar / Department of Emergency Medicine, Elazığ Fethi Sekin City Hospital, Elazığ, Türkiye

Introduction and Purpose: A significant proportion of patients presenting to emergency departments (ED) with chest pain are found to have noncardiac chest pain (NCCP) after cardiac causes have been ruled out. Among these patients, musculoskeletal pain, particularly Myofascial Pain Syndrome (MPS), which can mimic angina pectoris, constitutes a clinically significant subgroup. The aim of this review is to present the prevalence of MPS cases mistaken for cardiac origin in ED, the diagnosis and treatment processes, and the critical role of physical examination in differential diagnosis, based on current literature data.

Materials and Methods: This study was designed as a narrative review. Guidelines, systematic reviews, case reports, observational, and randomized controlled trials published between January 2007 and March 2026 were searched in the PubMed/MEDLINE and Google Scholar databases. Selected studies were synthesized based on themes according to the principles of contributing to the initial assessment of chest pain in ED, including MPS diagnostic criteria, and presenting applicable treatment approaches.

Results and Conclusion: The prevalence of musculoskeletal chest pain (MSCP) in ED series appears to be approximately 15-16% in most studies; however, it may vary between centers. Active MTPs in chest wall muscles, such as the pectoral muscles and serratus anterior, can cause referred pain mimicking cardiac ischemia through somatovisceral convergence and autonomic nervous system interactions. The diagnostic approach in the ED relies primarily on rapidly ruling out fatal cardiac conditions using electrocardiography and troponin. Subsequently, the identification of a taut band and hypersensitive focus during a focused examination, and the reproduction of the patient's “familiar/referred pain” with this pressure, supports the diagnosis of MPS. In acute treatment, reassurance, local heat, stretching, and ischemic compression are first-line; trigger point injection and dry needling are alternatives for refractory cases.MPS is not merely a diagnosis of exclusion in the differential diagnosis of chest pain in ED; it is a clinical syndrome that should be actively sought with positive physical examination findings. Accurate diagnosis and management of MPS in ED can improve patient satisfaction by preventing unnecessary cardiac investigations and repeated in ED visits.

Keywords: Chest Pain, Myofascial Pain Syndrome, Referred Pain

Ref No: 6016

Lithium-Induced Diabetes Insipidus and Hypernatremia: A Case Report

Ozan Deniz Keleş[1], Murat Teker[1], İsa Yıldırım[1], Ahmet Melih Savaş[1], Ayhan Aköz[1]

[1]Department of Emergency Medicine, Faculty of Medicine, Aydın Adnan Menderes University, Aydın, Turkey

Ozan Deniz Keleş / Department of Emergency Medicine, Faculty of Medicine, Aydın Adnan Menderes University, Aydın, Turkey

Introduction and Purpose: Lithium is a medication with a high risk of toxicity due to its narrow therapeutic index. Nephrogenic diabetes insipidus is a significant renal side effect of lithium therapy. Lithium-induced diabetes insipidus can lead to severe hypernatremia and impaired consciousness. This case report aims to present the clinical course and treatment management of diabetes insipidus and hypernatremia developing after lithium intoxication.

Materials and Methods: A 70-year-old male patient with a known diagnosis of bipolar disorder was referred to our clinic following a suicide attempt involving the ingestion of a large quantity of his lithium medication. Upon initial physical examination, the patient was conscious, oriented, and cooperative, with other systemic examinations appearing normal.Laboratory tests revealed a serum lithium level of 5.2 mmol/L. Given the lithium intoxication, emergency hemodialysis was planned. The patient, who had a history of chronic lithium use and required dialysis, was admitted to the emergency intensive care unit for monitoring.Although the patient underwent two sessions of dialysis and his lithium levels returned to normal ranges, the expected improvement in his mental state did not occur; instead, a progressive loss of consciousness developed. Central nervous system imaging and lumbar puncture results were evaluated as normal.During clinical follow-up, significant polyuria was detected, and serum sodium levels rose progressively, reaching 160 mmol/L. These clinical and laboratory findings were consistent with lithium-induced diabetes insipidus. Treatment for hypervolemic hypernatremia was initiated, and desmopressin was added to the regimen. Following treatment, serum sodium levels gradually decreased, leading to a marked improvement in the patient's level of consciousness.

Results and Conclusion: In patients with lithium intoxication, hypernatremia and diabetes insipidus must be considered in the differential diagnosis if impaired consciousness persists or worsens, especially in the post-hemodialysis period. Early diagnosis, appropriate fluid management, and desmopressin therapy play a decisive role in clinical recovery and prognosis.

Keywords: Lithium, diabetes insipidus, hypernatremia

Ref No: 6039

Weil's disease presenting with acute hepatorenal failure and severe thrombocytopenia: Early diagnosis saves lives

MELİKE KARATAŞ AYHAN[1], SERDAR DERYA[1], MUSTAFA SAFA PEPELE[1], MAHMUT MURAT[1], RIDVAN SÖNMEZ[1], NESLİHAN YÜCEL[1], ŞÜKRÜ GÜRBÜZ[1], MEHMET EDİZ SARIHAN[1]

[1]INONU UNİVERSITY

SERDAR DERYA / INONU UNİVERSITY

Introduction and Purpose: Leptospirosis is a zoonotic infection caused by Leptospira interrogans, which is prevalent worldwide, particularly in tropical regions. While 90% of cases follow a mild, anicteric course, 5–10% progress to Weil's disease, a severe form characterized by jaundice, acute kidney injury (AKI), thrombocytopenia, and hemorrhagic manifestations, with a reported mortality of approximately 22%. Diagnosis remains challenging in the absence of a classical exposure history. This case highlights the diagnostic pitfalls and life-saving impact of early empirical treatment.

Materials and Methods: We report a 50-year-old male farmer with a 5-day history of myalgia, chills, and subfebrile fever, followed by rapid-onset jaundice, abdominal pain, and oliguria. Physical examination revealed bilateral icteric sclerae and right conjunctival hemorrhage, a characteristic yet underrecognized finding in Weil's disease. No direct rodent contact or well water use was reported; however, occupational soil and irrigation water exposure were considered adequate transmission routes. Laboratory findings demonstrated severe thrombocytopenia (PLT: $6\times10^3/\mu L$), AKI (creatinine: 4.4 mg/dL), and disproportionate hyperbilirubinemia (total bilirubin: 17.86 mg/dL) with only mild-to-moderate transaminase elevation (AST: 414, ALT: 229 U/L), a cholestatic pattern inconsistent with hepatocellular necrosis and highly suggestive of Weil's disease. Markedly elevated creatine kinase (CK) levels (4265 U/L) indicated concurrent myositis, and elevated amylase levels (207 U/L) raised concerns regarding pancreatic involvement. Leptospirosis and Crimean-Congo hemorrhagic fever (CCHF) were considered in the differential diagnosis. Samples were sent to the public health laboratory, and empirical intravenous ceftriaxone was initiated without waiting for polymerase chain reaction (PCR) results.

Results and Conclusion: Leptospirosis PCR returned positive, confirming Weil's disease. Ribavirin was initially added pending CCHF exclusion and discontinued once the diagnosis was confirmed. Multidisciplinary management included hemodialysis for refractory AKI, plasmapheresis for severe hyperbilirubinemia, a debated but increasingly reported adjunctive

approach in refractory icteric leptospirosis, and blood product support. After 10 days in the intensive care unit (ICU) and 25 days of total treatment, the patient was discharged with complete laboratory recovery. This case underscores three critical messages: minimal exposure history does not exclude leptospirosis in farmers, conjunctival hemorrhage is a high-yield, underrecognized early clue, and empirical antibiotic therapy initiated on clinical suspicion, prior to PCR confirmation, is life-saving.

Keywords: Leptospirosis, Weil's disease, thrombocytopenia

Ref No: 6066

Inflammatory Biomarkers and Clinical Outcomes in Intensive Care Unit Pneumonia: The Role of Procalcitonin and Ferritin

Ömer Özcan[1], Hazal Nur Kılıç[2]

[1]Malatya Turgut Özal University, Faculty of Medicine, Department of Emergency Medicine
[2]Department of Anesthesiology and Reanimation, Malatya Training and Research Hospital

Ömer Özcan / Malatya Turgut Özal University, Faculty of Medicine, Department of Emergency Medicine

Introduction and Purpose: Pneumonia remains a significant cause of morbidity and mortality in intensive care units (ICUs), particularly among elderly patients. Inflammatory biomarkers such as procalcitonin (PCT) and ferritin have been increasingly used to evaluate disease severity and prognosis. This study aimed to investigate the relationship between these biomarkers, clinical parameters, and outcomes in ICU patients with pneumonia.

Materials and Methods: In this retrospective study, patients with pneumonia admitted to the reanimation ICU between January 1, 2025, and June 30, 2025, were evaluated. A total of 38 patients were screened, and 33 patients were included after excluding those with non-pneumonia-related mortality or confounding clinical conditions. Statistical analyses were performed using IBM SPSS Statistics 27. Data distribution was assessed with the Shapiro–Wilk test. Parametric variables were analyzed using the Student's t-test, and non-parametric variables were evaluated with the Mann-Whitney U test. Categorical variables were compared using the chi-square test or Fisher's Exact test where appropriate. Correlation analyses were performed using Spearman's test.

Results and Conclusion: The median age of the patients was 74 years, and 66.7% were male. The overall mortality rate was 18.2%. Ferritin levels were significantly higher in male patients. Procalcitonin levels were significantly elevated in non-survivors, and both age and length of hospital stay were higher among patients who died. Although mortality was observed only in male patients, this difference was not statistically significant. Positive correlations were found between age, PCT, ferritin levels, and hospital length of stay. PCT and ferritin levels may serve as useful biomarkers in assessing disease severity and predicting clinical outcomes in ICU patients with pneumonia. The association between increased age, inflammatory markers, and prolonged hospitalization highlights their potential role in clinical decision-making. Larger studies are needed to confirm these findings.

Keywords: Pneumonia, Procalcitonin, Ferritin

Ref No: 6068

Retrospective analysis of conservative and surgical treatment approaches in patients presenting to the emergency department with low back pain

Gökhan Toğuşlu[1], Muhammet Gökhan Turtay[2]

[1]University of Health Sciences, Beyhekim Training and Research Hospital, Clinic of Neurosurgery, Konya, Türkiye.
[2]University of Health Sciences, Beyhekim Training and Research Hospital, Clinic of Emergency Medicine, Konya, Türkiye.

Muhammet Gökhan Turtay / University of Health Sciences, Beyhekim Training and Research Hospital, Clinic of Emergency Medicine, Konya, Türkiye.

Introduction and Purpose: Low back pain (LBP) is among the most frequent reasons for emergency department (ED) visits, encompassing a broad clinical spectrum ranging from simple musculoskeletal spasms to severe spinal pathologies requiring urgent intervention. While the vast majority of this patient population can be managed with medical therapy, only a small subgroup requires surgical intervention. This study aims to retrospectively analyze the distribution of diagnostic groups and the rates of conservative versus surgical treatment among adult patients presenting to the ED with LBP.

Materials and Methods: This retrospective cross-sectional study was conducted at the Emergency Medicine Clinic of University of Health Sciences, Beyhekim Training and Research Hospital, between January 1, 2025, and January 1, 2026. The study included 1674 consecutive adult patients presenting with LBP. Demographic data, etiological diagnoses, and treatment approaches were retrieved via the hospital information management system. Pathologies were categorized into three primary etiological groups: non-specific LBP, spinal surgical pathologies, and other specific pathologies. Patient outcomes in the ED were classified as discharge, hospitalization, or surgical intervention.

Results and Conclusion: Of the 1674 patients included, %52 (n=871) were female and %48 (n=803) were male, with an overall mean age of 44.2 ± 15.1 years. Diagnostic analysis revealed that %75 (n=1256) of patients had non-specific LBP, %16 (n=267) had other specific pathologies, and %9 (n=151) were diagnosed with spinal surgical pathologies. The mean age of the spinal surgical pathology group (52.8 ± 14.6 years) was significantly higher than the other groups. During the ED clinical evaluation, 13% (n=218) of all patients—primarily those with specific neurological findings or requiring advanced investigation—received a Neurosurgery consultation. Regarding patient outcomes, %87.7 (n=1468) were discharged following conservative treatment in the ED, %7.6 (n=128) were hospitalized, and %4.7 (n=78) underwent surgical intervention. The distribution of procedures for the 78 patients with surgical indications was as follows: lumbar microdiscectomy (n=32), spinal decompression + instrumentation (n=25), and kyphoplasty (n=21).The vast majority of patients presenting to the ED with low back pain have non-specific etiologies and can be successfully managed with conservative medical therapy.

Keywords: Emergency, low back pain, lumbar surgery

Ref No: 6080

Comparison of Emergency Physicians' Pneumothorax Diagnosis Performance with Artificial Intelligence Models

Julide Gurbuz[1], Omer Faruk Cakiroglu[3], Bilal Arac[4], Seyma Nur Calisir[2], Elif Betul Balci[1], Bahadir Taslidere[1], Basar Cander[1]

[1]Bezmialem Foundation University Hospital
[2]Basaksehir City Hospital
[3]Kartal City Hospital
[4]Basaksehir State Hospital

Julide Gurbuz / Bezmialem Foundation University Hospital

Introduction and Purpose: Objectives: This study aims to compare emergency physicians' performance with that of general-purpose large language models (LLMs), such as ChatGPT and Gemini, for pneumothorax (PTX) detection on chest radiographs (CXRs).

Materials and Methods: Methods: This single-centre, retrospective study of adults was conducted between January 2015 and February 2025 and included 265 PTX cases and 267 non-PTX controls. Exclusions included diagnoses made only by computed tomography, absence of CXR, initial treatment at another centre or incomplete data. Thirteen emergency physicians independently and blindly reviewed CXRs and recorded a binary decision ChatGPT and Gemini evaluated the same images with a standardised yes/no prompt, with memory cleared between cases to prevent carryover. The primary outcome was LLM diagnostic performance for PTX, while the secondary outcome compared LLMs with physicians.

Patient Flowchart

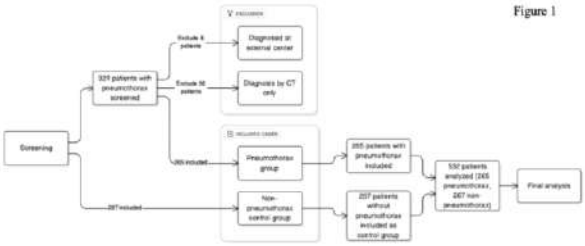

Comparative Chart of AI Models According to Difficulty Level

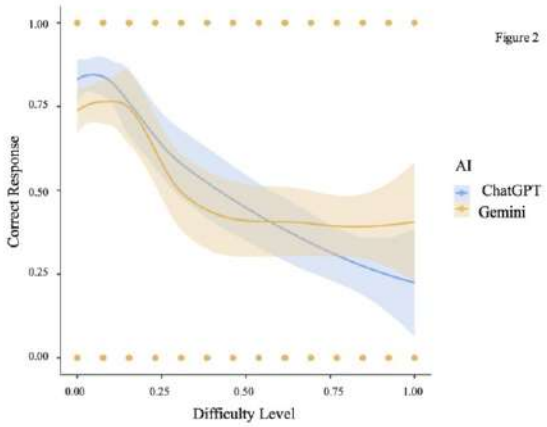

Results and Conclusion: Results: ChatGPT and Gemini exhibited distinct diagnostic performance profiles for pneumothorax detection on chest radiographs. Gemini demonstrated a sensitivity of 52.5%, whereas ChatGPT demonstrated a sensitivity of 44.5%. Conversely,

ChatGPT achieved a specificity of 95.5% and an overall accuracy of 70.1%, while Gemini demonstrated a specificity of 79.0% and an accuracy of 65.8%. Agreement with the reference standard was moderate for ChatGPT, with a kappa value of 0.401, and fair for Gemini, with a kappa value of 0.315. Increasing case difficulty was associated with a reduction in diagnostic accuracy for both models, with correlation coefficients of −0.438 for ChatGPT and −0.274 for Gemini. For contextual clinical comparison, emergency physicians demonstrated a sensitivity of 64.5%, a specificity of 99.6%, and an overall accuracy of 82.1%.Conclusion: This study demonstrates model-specific differences in pneumothorax detection by general-purpose AI systems, with Gemini showing higher sensitivity and ChatGPT superior specificity and accuracy, both declining with increasing case difficulty. Physician performance remained higher but was secondary for context. Despite their accessibility and low cost, these models should be considered only adjunctive tools until task-specific optimization and clinical validation are achieved.

Comparison of Sensitivity, Specificity, Predictive Values and Agreement Coefficients Between Physicians and AI Models in the Diagnosis of PTX and Analysis According to Cohen's Kappa Coefficient

Table 1.

	Physicians (total)	**Resident physicians**	**Specialist physicians**	**ChatGPT**	**Gemini**
Sensitivity	64.5%(CI95%:58.4%-70.3%)	69.1%(CI95%:63.1%-74.6%)	65.3%(CI95%:59.2%-71.0%)	44.5%(CI95%:38.4%-50.7%)	52.5%(CI95%:46.3%-58.6%)
Specificity	99.6%(CI95%:97.9%-100%)	96.6%(CI95%:93.7%-98.4%)	99.6%(CI95%:97.9%-100%)	95.5%(CI95%:92.3%-97.7%)	79.0%(CI95%:73.6%-83.8%)
Accuracy	82.1%(CI95%:78.6%-85.3%)	82.9%(CI95%:79.4%-86.0%)	82.5%(CI95%:79%-85.7%)	70.1%(CI95%:66%-74%)	65.8%(CI95%:61.6%-69.8%)
Prevalence	49.8%(CI95%:45.5%-54.1%)	49.8%(CI95%:45.5%-54.1%)	49.8%(CI95%:45.5%-54.1%)	49.8%(CI95%:45.5%-54.1%)	49.8%(CI95%:45.5%-54.1%)
PPV	99.4%(CI95%:96.8%-100%)	95.3%(CI95%:91.3%-97.8%)	99.4%(CI95%:96.8%-100%)	90.8%(CI95%:84.4%-95.1%)	71.3%(CI95%:64.4%-77.5%)
NPV	73.9%(CI95%:69%-78.4%)	75.9%(CI95%:71.0%-80.3%)	74.3%(CI95%:69.4%-78.8%)	63.4%(CI95%:58.5%-68.2%)	62.6%(CI95%:57.2%-67.8%)
Post-test disease probability	99.4%	95.3%	99.4%	90.8%	71.3%
Post-test	72.7%	75.9%	74.3%	63.4%	62.6%

health probability					
LR+	166	20.5	174	9.91	2.50
LR−	0.379	0.320	0.348	0.581	0.602
Interrater reliability					
Agreement %	82	83	83	70	66
Kappa (unweighted)	0.642(CI95%:0,562-0,720)	0.658 (CI95%:0,576-0,740)	0.650 (CI95%:0,570-0,730)	0.401 (CI95%:0,327-0,475)	0.315 (CI95%:0,233-0,397)
Z	15.8	15.8	16.0	10.7	7.53
p	<.001	<.001	<.001	<.001	<.001

Correlation Between AI Models and Difficulty Level

	ChatGPT	Gemini
r[1]	–0.438	–0.274
df	530	530
p value	<.001	<.001
Point-biserial correlation[1]		

Keywords: Pneumothorax, Artificial Intelligence, Emergency Physicians

Ref No: 6086

Implementing the "3s" approach for surge capacity in a mass casualty incident: lessons from a bus crash

Harun Sandal[1], Mine Kayacı Yıldız[1], Ali Küçükosmanoğlu[1], Yasin Yıldız[1], Mehmet Gül[1]

[1]Emergency Medicine Department, Konya City Hospital, Türkiye

Ali Küçükosmanoğlu / Emergency Medicine Department, Konya City Hospital, Türkiye

Introduction and Purpose: Mass casualty incidents are defined as situations where the existing healthcare system capacity is overwhelmed and the number of patients rapidly exceeds available resources. Surge capacity in mass casualty incidents is classically explained by the "3S" approach (staff, stuff, structure). In this case report, the emergency department management of multiple trauma patients following a collision between a school bus and a passenger bus is evaluated from the perspectives of triage practices and surge capacity.

Materials and Methods: A total of 24 patients were evaluated, consisting of 19 pediatric and 5 adult patients. The trauma area was functionally divided into four zones: the initial reception and physician-led triage area, the monitored critical patient area, the unmonitored observation area, and the ambulatory patient evaluation area. The distribution of duties among physicians and nurses was predetermined, and one physician was assigned as the area coordinator solely to manage the organization and workflow. One of the most prominent elements in this process was the effective implementation of the surge capacity concept. Surge capacity involves not only responding to the patient volume but also the reorganization of existing resources.

Results and Conclusion: While standard disaster preparedness protocols are important, the determining factor in real-world field conditions is the immediate and accurate organization of available resources. In particular, the functional zoning of the area, the structuring of patient flow, and serial clinical reassessments stand out as fundamental elements that enhance patient safety.

Keywords: Mass casualty incidents, Triage, Emergency Department

Ref No: 6090

Can Machine Learning Replace the SYNTAX Score for Predicting Triple-Vessel Disease in Patients with Acute Coronary Syndrome?

Omer Faruk Cakiroglu[2], Julide Gurbuz[1], Abdullah Yaser Guney[3], Batuhan Galip Aydogdu[1], Hussein Alfakeer[4], Esra Danışman[1], Oguzhan Abanoz[1], Basar Cander[1], Bahadir Taslidere[1]

[1]Bezmialem Foundation University, School of Medicine, Department of Emergency Medicine, Istanbul, Turkey
[2]Kartal Dr. Lütfi Kırdar Training and Research Hospital, Department of Emergency Medicine, Istanbul, Türkiye
[3]Başakşehir City Hospital, Department of Emergency Medicine, Istanbul, Turkey
[4]Health Sciences University, Istanbul, Turkey
[5]Bezmialem Foundation University, School of Medicine, Department of Cardiology, Istanbul, Turkey

Batuhan Galip Aydogdu / Bezmialem Foundation University, School of Medicine, Department of Emergency Medicine, Istanbul, Turkey

Introduction and Purpose: In patients with acute coronary syndrome (ACS), identifying triple-vessel coronary artery disease (CAD) early is vital for choosing the right treatment and improving survival. While traditional scoring methods often require invasive procedures, there is a growing need for non-invasive tools that use routine clinical data. This study aimed to develop machine learning (ML) models using standard laboratory and clinical parameters to predict triple-vessel CAD and compare their performance against the traditional SYNTAX score.

Materials and Methods: This retrospective study included ACS patients who underwent coronary angiography. Triple-vessel CAD was defined as > 70% narrowing in three major coronary arteries. We used a dataset containing demographics and derived laboratory markers, such as the hemoglobin-to-creatinine ratio and various inflammation indices. The data was divided into a 70% training set and a 30% test set. Five ML models were developed: Logistic Regression, Random Forest (RF), Support Vector Machine, XGBoost, and Artificial Neural Networks. Performance was evaluated using the Area Under the Curve (AUC), and classification thresholds were optimized using Youden's J statistic. Analyses were performed in Python using libraries such as scikit-learn and XGBoost.

Figure 1. ROC curves of machine learning models and the SYNTAX >22 threshold for predicting triple-vessel disease

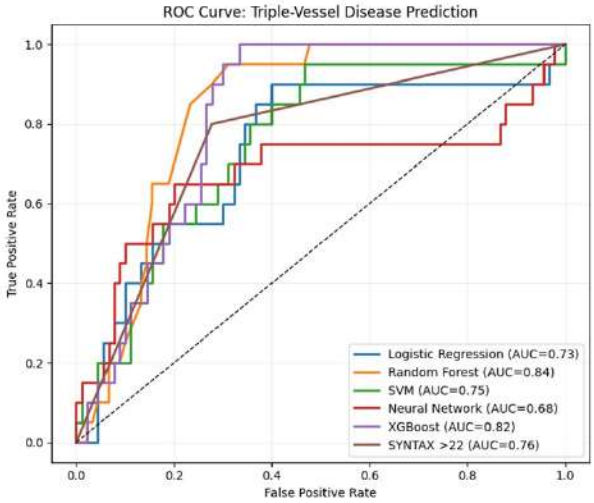

Figure 2. Calibration curves for the Random Forest (Brier = 0.131) and XGBoost (Brier = 0.145) models on the held-out test set.

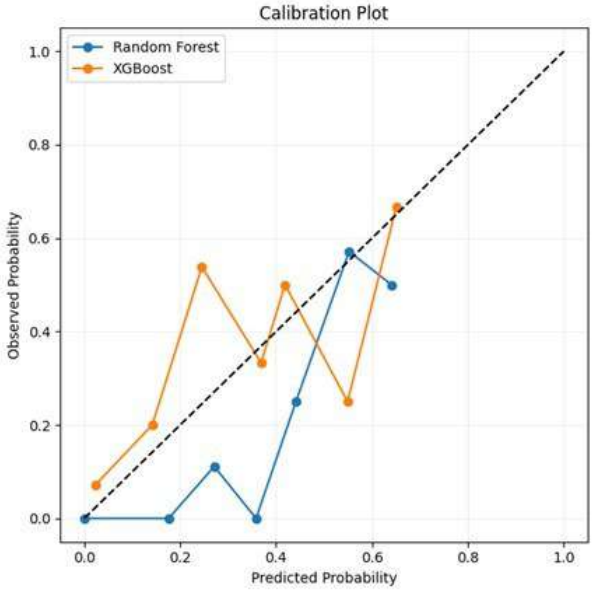

Figure 4. SHAP beeswarm summary plot for the Random Forest model. Features are ranked according to their mean absolute SHAP values. Color indicates the magnitude of the feature value (red = high, blue = low).

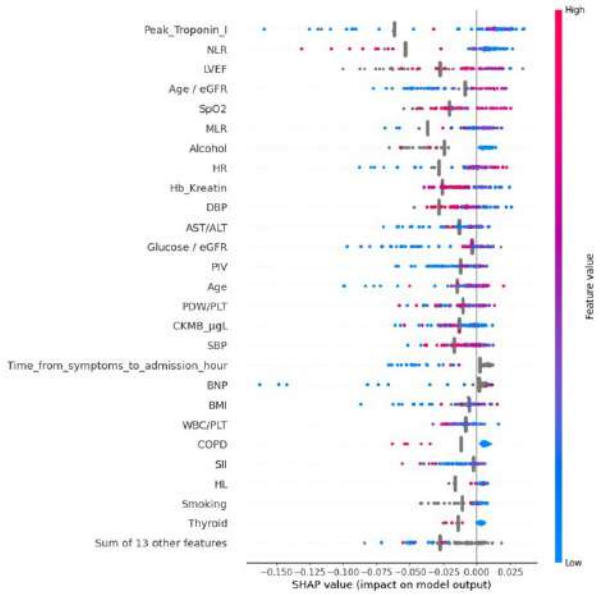

Table 3. DeLong test comparison of AUC values for each machine learning model versus the SYNTAX >22 reference threshold.

Karşılaştırma	AUC (Model)	AUC (SYNTAX >22)	ΔAUC	Z	p-değeri
Random Forest – SYNTAX >22	0.812	0.733	+0.079	1.82	0.069
XGBoost – SYNTAX >22	0.795	0.733	+0.061	1.22	0.224
Lojistik Regresyon – SYNTAX >22	0.745	0.733	+0.011	0.18	0.857
SVM – SYNTAX >22	0.726	0.733	−0.007	−0.13	0.900
Sinir Ağı – SYNTAX >22	0.603	0.733	−0.131	−1.60	0.110

Results and Conclusion: Results: Triple-vessel CAD was present in 27% of the patients. This group showed significantly lower heart function (LVEF) and kidney function (eGFR), alongside higher troponin and BNP levels compared to those without the condition. On the test set, the RF model achieved the highest predictive performance (AUC = 0.812), followed by XGBoost (AUC = 0.795) and the SYNTAX > 22 reference (AUC = 0.733). Although RF performed numerically better than the SYNTAX score, the difference was not statistically significant (p = 0.069). Feature importance and SHAP analyses identified the Hb/Creatinine ratio, peak troponin, white

blood cell-to-platelet ratio, blood pressure, and heart rate as the most influential predictors.Coclusion: Machine learning models, particularly Random Forest, show strong potential for the non-invasive prediction of triple-vessel CAD in ACS patients. While not statistically superior to the SYNTAX score in this cohort, these models offer high sensitivity and can serve as valuable decision-support tools in clinical settings.

Figure 3. Top 10 predictor variables ranked according to Random Forest feature importance scores

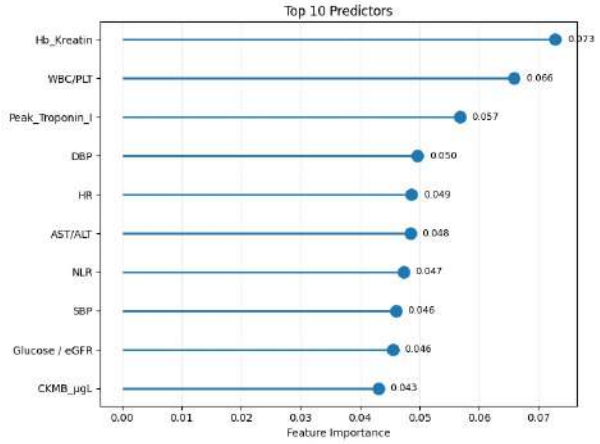

Figure 5. SHAP dependence plots for the top six predictors. Points represent test set patients colored by disease status (pink: triple-vessel; blue: non-triple-vessel). The magenta LOWESS curve indicates the overall trend.

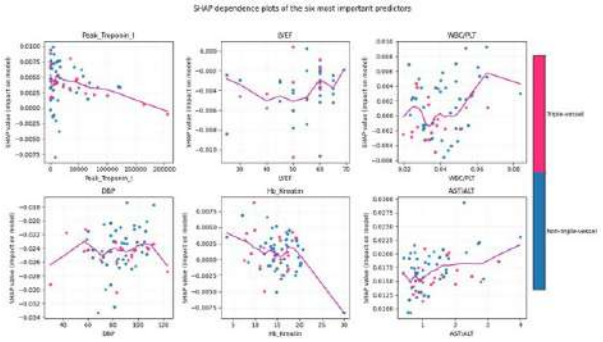

Table 1. Baseline demographic, clinical, and laboratory characteristics of patients with triple-vessel and non-triple-vessel CAD. Data are presented as median (Q1–Q3) for continuous variables and n (%) for categorical variables. *p < 0.05.

Değişken	Üç-Damar Dışı Median (Q1–Q3) / n(%)	Üç-Damar Hastalığı Median (Q1–Q3) / n(%)	p-değeri
Sürekli Değişkenler			
Yaş (yıl)	60.00 (51.00–71.50)	63.00 (54.00–74.00)	0.076
VKİ (kg/m²)	26.85 (24.22–29.18)	27.40 (25.15–29.32)	0.411
SVEF (%)	55.00 (45.00–60.00)	50.00 (40.00–60.00)	**0.013***
Kalp Hızı (atım/dk)	85.00 (74.50–99.50)	87.00 (74.00–105.00)	0.545
SKB (mmHg)	158.00 (140.00–175.00)	155.00 (133.00–176.00)	0.612
DKB (mmHg)	87.00 (76.00–97.00)	84.00 (71.00–98.00)	0.285
SpO_2 (%)	97.00 (96.00–98.00)	96.50 (95.00–98.00)	**0.036***
Killip Skoru	0.00 (0.00–0.00)	0.00 (0.00–0.00)	0.140
GRACE Skoru	100.00 (78.00–127.25)	110.00 (91.25–136.00)	0.062
Pik Troponin I (ng/L)	5373.50 (726.88–21870.03)	9059.30 (1946.20–34620.20)	**0.016***
Laktat (mmol/L)	2.33 (1.44–14.22)	1.90 (1.26–4.42)	0.431
CK-MB (µg/L)	5.05 (2.20–19.00)	6.50 (2.20–17.27)	0.476
AST/ALT oranı	26.00 (20.00–40.00)	28.00 (20.00–49.50)	0.130
Albümin (g/L)	21.00 (16.00–36.00)	27.00 (12.50–36.00)	0.944
BNP (pg/mL)	132.65 (55.35–381.68)	323.95 (162.18–587.33)	**0.001***
eGFR (mL/dak)	81.00 (62.00–95.25)	70.00 (48.50–88.00)	**0.006***
Glukoz (mg/dL)	135.00 (110.00–188.00)	144.00 (110.00–193.75)	0.483
NLR	2.65 (1.60–4.32)	2.45 (1.60–3.92)	0.291
MLR	0.26 (0.19–0.39)	0.25 (0.19–0.34)	0.532
SII	680.34 (409.05–1095.80)	641.55 (382.67–1043.81)	0.694
Hb/Kreatinin oranı	14.76 (12.61–16.98)	13.78 (10.88–17.11)	0.062
Kategorik Değişkenler			
Erkek cinsiyet	209 (%76.0)	75 (%74.3)	0.831
NSTEMI	158 (%58.5)	43 (%43.4)	**0.016***
STEMI	108 (%40.0)	54 (%54.5)	**0.017***
Hipertansiyon	154 (%56.0)	63 (%62.4)	0.321
Diabetes mellitus	92 (%33.5)	40 (%39.6)	0.324
Geçirilmiş MI	81 (%30.5)	37 (%37.0)	0.285

Table 2. Cross-validation and test set performances of all models. Metrics are reported at the Youden-optimal threshold. Acc. = Accuracy; Sens. = Sensitivity; Spec. = Specificity

Model	ÇD-AUC (ort±SS)	AUC	%95 GA	Doğr.	Duyar.	Özgül.	F1
Random Forest	0.728 ± 0.077	0.812	0.743–0.878	0.691	0.933	0.637	0.523
XGBoost	0.710 ± 0.096	0.795	0.722–0.864	0.630	0.967	0.556	0.487
Lojistik Regresyon	0.596 ± 0.084	0.745	0.643–0.838	0.630	0.900	0.570	0.470
SYNTAX >22	0.671 ± 0.051	0.733	0.651–0.810	0.691	0.800	0.667	0.485
SVM	0.668 ± 0.061	0.726	0.634–0.817	0.612	0.933	0.541	0.467
Sinir Ağı	0.522 ± 0.076	0.603	0.476–0.735	0.612	0.733	0.585	0.407

Keywords: Acute Coronary Syndrome, Machine Learning, Triple-Vessel Disease

Ref No: 6128

Constipation in a cancer patient is not always benign: Acute spinal cord compression masked by autonomic dysfunction in a remission myeloma patient

RIDVAN SÖNMEZ[1], SERDAR DERYA[1], MUSTAFA SAFA PEPELE[1], MAHMUT MURAT[1], MELİKE KARATAŞ AYHAN[1], NESLİHAN YÜCEL[1], ŞÜKRÜ GÜRBÜZ[1], MEHMET EDİZ SARIHAN[1]

[1]INONU UNIVERSTY

SERDAR DERYA / INONU UNIVERSTY

Introduction and Purpose: A 46-year-old man with Multiple Myeloma(MM) in remission presented to the emergency department (ED) with constipation and was nearly discharged without a diagnosis for the second time. Malignant spinal cord compression (MSCC) occurs in 10–20% of MM patients and represents an oncologic emergency. Although MSCC typically presents with back pain, motor weakness, and sensory loss, neurogenic bowel dysfunction due to autonomic involvement may be the sole initial manifestation. This case highlights an atypical presentation leading to diagnostic delay, overlooked red flags, and complete neurological recovery achieved through early intervention prior to motor deficit. The key message is that

unexplained constipation in cancer patients should not be overlooked without neurological evaluation.

Materials and Methods: The patient had undergone autologous stem cell transplantation two years earlier and was in remission without active treatment. He presented with one week of refractory constipation and abdominal distension. Five days prior, he had been evaluated at another ED with similar complaints; metabolic tests were normal, and he was discharged after temporary relief with an enema, representing a near-missed diagnosis. At presentation, three red flags were identified: known malignancy, positional back pain worsening in the supine position and relieved by forward flexion, and unexplained constipation without metabolic cause. Laboratory findings, including calcium (8.7mg/dL), electrolytes, and renal function, were within normal limits. Abdominal CT showed no mechanical obstruction. Neurological examination revealed preserved motor strength (5/5) but bilateral hypoesthesia below the T10 dermatome, the key diagnostic finding. Whole-spine CT demonstrated a T8 compression fracture causing spinal canal compromise, along with diffuse lytic lesions consistent with MM relapse.

Results and Conclusion: The patient underwent urgent surgery, including posterior stabilization, laminectomy, decompression, extradural mass excision, corpectomy, and fusion under neuromonitoring. The critical advantage was early timing, as surgery was performed before motor deficit developed. Complete neurological recovery and full mobilization were achieved postoperatively. Consistent with Patchell et al. (2005), which demonstrated the superiority of surgical decompression over radiotherapy, this case emphasizes that early diagnosis preserves neurological function. Clinically, unexplained constipation in cancer patients requires neurological examination and spinal imaging. Neurogenic bowel dysfunction may precede motor deficits, and failure to recognize this window may result in irreversible paraplegia.

Keywords: Multiple myeloma, spinal cord compression, neurogenic constipation

---

Ref No: 6142

Extraperitoneal Free Air After Femoral Hemodialysis Catheterization: Bowel Perforation or Benign Complication?

Ekim Sağlam Gürmen[1], Muhammet İkbal Şaşmaz[1], Sezer Akçalı[1]

[1]Manisa Celal Bayar University School of Medicine, Department of Emergency Medicine, Manisa, Türkiye

Sezer Akçalı / Manisa Celal Bayar University School of Medicine, Department of Emergency Medicine, Manisa, Türkiye

Introduction and Purpose: INTRODUCTIONFemoral hemodialysis catheterization is commonly performed in patients requiring urgent renal replacement therapy, particularly in acute kidney injury superimposed on chronic kidney disease. Although generally safe, mechanical, thrombotic, and infectious complications may occur (1,3). The detection of extraperitoneal free air after femoral vascular access may mimic bowel perforation and pose a diagnostic challenge.

Materials and Methods: A 55-year-old man with diabetes mellitus, hypertension, chronic kidney disease, and coronary artery disease presented with nausea, vomiting, and weakness. Laboratory findings showed glucose 1154 mg/dL, pH 7.15, HCO_3 7.1 mmol/L, potassium 6.79 mmol/L, creatinine 5.93 mg/dL, and hemoglobin 6.7 g/dL, consistent with diabetic ketoacidosis and acute kidney injury on chronic kidney disease.A temporary right femoral hemodialysis catheter was inserted but replaced with a right internal jugular catheter due to malfunction. Persistent abdominal pain prompted non-contrast abdominal CT, which revealed extraperitoneal free air in the right pelvic region with minimal fluid collection. After surgical consultation, contrast-enhanced CT demonstrated no intraperitoneal perforation or extraluminal contrast leakage. The findings were attributed to the catheterization procedure.Hemodialysis was initiated, metabolic parameters improved, and the patient was admitted to the intensive care unit. No surgical intervention was required.

Results and Conclusion: Complications of femoral hemodialysis catheterization include mechanical (arterial puncture, hematoma, retroperitoneal bleeding, malposition), thrombotic, and infectious events (1,3). Rarely, air may dissect along perivascular tissue planes, leading to extraperitoneal free air without visceral perforation.True bowel perforation typically presents with peritoneal signs, hemodynamic instability, and contrast extravasation on imaging. In contrast, procedure-related extraperitoneal air is usually seen in stable patients without progressive abdominal findings (4).In this case, hemodynamic stability, absence of peritoneal irritation, lack of contrast leakage, and stable serial examinations excluded bowel perforation. A multidisciplinary approach prevented unnecessary surgery and enabled conservative management.In conclusion, extraperitoneal free air after femoral hemodialysis catheter placement does not always indicate bowel perforation. Careful clinical assessment, appropriate imaging, and close monitoring are essential for accurate diagnosis and optimal management.

Keywords: Bowel perforation, Extraperitoneal free air, Femoral hemodialysis catheter

Ref No: 6164

Hematologic Emergencies in the Emergency Department: Prognostic Role of Physiological Scoring Systems

Ekim Sağlam Gürmen[1], Berika Şener[1], Muhammet İkbal Şaşmaz[1], Doğuhan Bitlisli[1]

[1]Manisa Celal Bayar University School of Medicine, Emergency Department, Manisa, Turkey

Berika Şener / Manisa Celal Bayar University School of Medicine, Emergency Department, Manisa, Turkey

Introduction and Purpose: Hematologic disorders present a heterogeneous patient population in the emergency department(ED),often with nonspecific symptoms and risk of rapid deterioration.Conditions such as anemia, thrombocytopenia, myeloproliferative disorders, and hematologic malignancies may lead to life-threatening complications including infection, bleeding, and organ failure.Early risk stratification in the ED is therefore critical. Physiological scoring systems are widely used to predict mortality and ICU need (1).Among these, the Modified Early Warning Score(MEWS),Rapid Emergency Medicine Score (REMS)and Shock Index(SI) are commonly applied(2-4). However, their prognostic value in hematologic patients remains limited (5). This study evaluated MEWS, REMS, and SI for predicting short-term mortality and ICU admission in patients presenting to the ED with hematologic conditions.

Materials and Methods: A retrospective study was conducted between June 2021 and June 2024 at a tertiary care center, including 400 patients aged≥18 years with known or newly diagnosed hematologic disorders.Demographics, vital signs, and clinical outcomes were analyzed.MEWS, REMS, and SI were calculated at presentation(3,4).One-month mortality and ICU admission were recorded.Statistical analyses included ROC curves and multivariate logistic regression to identify predictors of poor outcomes.

Results and Conclusion: ResultsThe mean age was 60.1 ± 17.9 years, and overall mortality was3.3%.Mortality was highest among patients with chronic leukemia,myelodysplastic syndromes,myeloproliferative disorders, and acute leukemia. Pneumonia or acute hemorrhage significantly increased mortality risk (5). MEWS demonstrated the highest discriminative ability for predicting mortality, while REMS also performed well. SI was not associated with mortality. For ICU admission, MEWS and REMS were strong predictors, whereas SI showed limited utility.Discussion Hematologic patients in the ED present heterogeneously, and complications such as infection and bleeding strongly influence outcomes (5). MEWS and REMS were reliable predictors of short-term mortality and ICU need (1,2), with MEWS offering the advantages of simplicity and higher discriminative performance (4). SI alone was insufficient, likely due to the multifactorial nature of deterioration in these patients, including infection, immunosuppression,

and organ dysfunction (5). Despite the retrospective, single-center design, these findings support early use of physiological scoring systems to guide risk stratification and clinical decision-making (1). MEWS, in particular, provides a practical tool for early identification of high-risk hematologic patients in ED triage (4).

Keywords: Hematologic Disorders, MEWS, Shock Index

Ref No: 6190

Acute Aortic Intramural Hematoma: A Rare Presentation of Acute Aortic Syndrome

Muharrem Altın[1], Yeşim Işler[1], Halil Kaya[1], Melih Yüksel[1], Mehmet Oğuzhan Ay[1], Umut Ocak[1]

[1]University of Health Science, Bursa Yuksek Ihtısas Training and Research Hospital, Department of Emergency Medicine, Bursa/Türkiye

Muharrem Altın / University of Health Science, Bursa Yuksek Ihtısas Training and Research Hospital, Department of Emergency Medicine, Bursa/Türkiye

Introduction and Purpose: Acute aortic syndrome (AAS) encompasses life-threatening conditions characterized by acute disruption of the aortic wall integrity, including aortic dissection, intramural hematoma (IMH), and penetrating atherosclerotic ulcer. Intramural hematoma is defined as hemorrhage within the aortic media without an identifiable intimal tear. Type A IMH, involving the ascending aorta, carries a high risk of progression and rupture and often requires urgent surgical intervention. We aimed to present a rare case of Type A IMH diagnosed in the emergency department.

Materials and Methods: A 64-year-old male presented to the emergency department with sudden-onset retrosternal chest pain that began after a meal and persisted at rest. His medical history was significant for hypertension and previous gastric cancer surgery in 2018, with remission since 2017. On admission, he was hemodynamically stable, and physical examination revealed no abnormal findings. Electrocardiography and cardiac biomarkers were not suggestive of acute coronary syndrome. Given persistent chest pain and a history of hypertension, contrast-enhanced thoracic and abdominal computed tomography (CT) angiography was performed to evaluate for AAS.

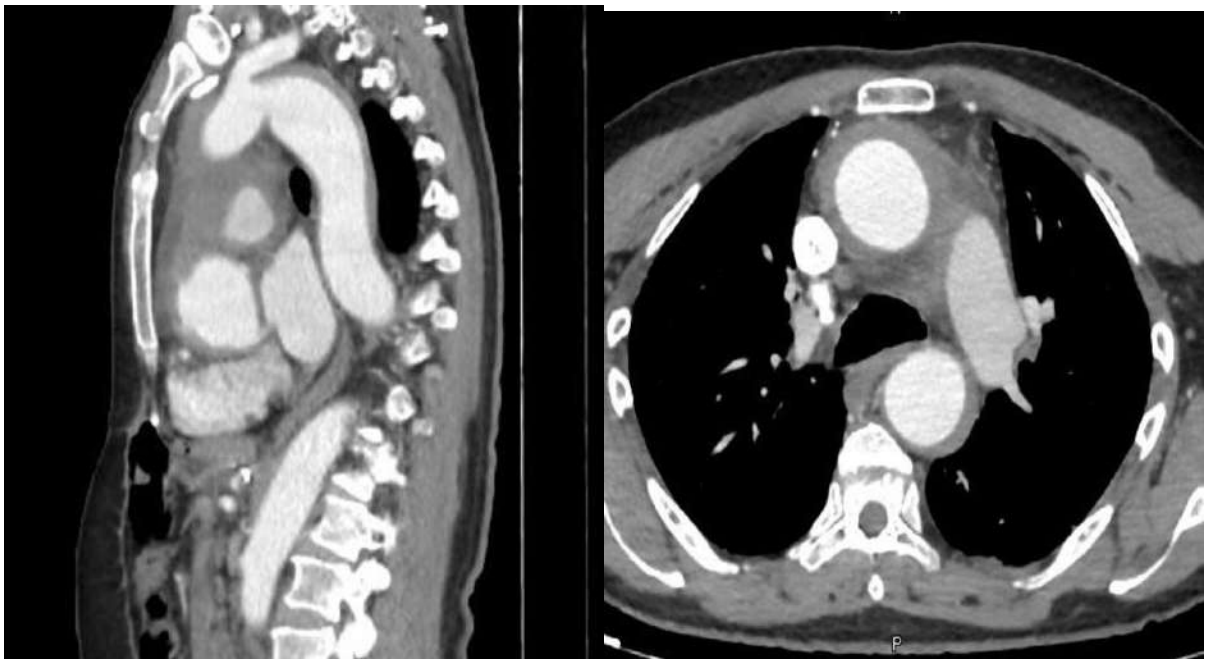

Image 1: blue arrow intramural hematoma
Image 2: blue arrow intramural hematoma

Results and Conclusion: CT angiography demonstrated circumferential aortic wall thickening extending from the ascending aorta and aortic arch to the distal thoracic aorta without evidence of an intimal flap, consistent with acute Type A IMH. The patient was evaluated by the cardiovascular surgery team and admitted to the intensive care unit for close monitoring and blood pressure control. Due to surgical indication during follow-up, a Bentall procedure was performed.AAS is associated with high mortality and requires rapid diagnosis in the emergency setting. IMH may clinically mimic acute coronary syndrome, particularly in elderly hypertensive patients presenting with chest pain. Contrast-enhanced CT angiography remains the imaging modality of choice due to its high sensitivity and specificity. Early clinical suspicion and prompt imaging are critical to improving outcomes in patients with Type A IMH.

Keywords: Acute aortic syndrome; intramural hematoma; Type A aortic disease

Ref No: 6209

Life-Saving Role of Emergency Tube Thoracostomy in a Case of Bilateral Pneumothorax Due to Penetrating Thoracic Trauma

Yakup Sağlam[1], Ayla Mollaoğlu[1], Muhammed Ürgün[1], Ahmet Gümüş[1], Mehmet Gül[1]

[1]Emergency Medicine Department, Konya City Hospital, Türkiye

Ahmet Gümüş / Emergency Medicine Department, Konya City Hospital, Türkiye

Introduction and Purpose: Penetrating thoracic traumas are associated with high mortality and require rapid diagnosis and intervention. Although bilateral pneumothorax is rare, it may lead to respiratory failure and hemodynamic collapse in a short time. The aim of this study is to emphasize the life-saving effect of emergency tube thoracostomy performed without waiting for imaging in a case of penetrating thoracic trauma complicated by bilateral pneumothorax.

Materials and Methods: A 43-year-old male patient was brought to the emergency department hypotensive after penetrating thoracic trauma. On physical examination, breath sounds were absent bilaterally, and bilateral pneumothorax was suspected. Bilateral tube thoracostomy was performed without waiting for imaging. The patient was intubated and stabilized. During follow-up, massive hematuria was observed, and imaging revealed left renal laceration and a subcapsular splenic hematoma. The patient underwent emergency surgery and left nephrectomy was performed.

Results and Conclusion: Bilateral pneumothorax is a rare but life-threatening condition. In hemodynamically unstable patients, tube thoracostomy performed without waiting for imaging is life-savingIn multitrauma patients, a systematic approach and multidisciplinary management determine prognosis. In patients with suspected bilateral pneumothorax, emergency tube thoracostomy should be performed without waiting for imaging. Early intervention reduces mortality.

Keywords: Bilateral pneumothorax, thoracic trauma, tube thoracostomy

Ref No: 6232

Esophageal Rupture

Berk Oral[1], Ali Gür[1] [1]Atatürk University
Berk Oral / Atatürk University

Introduction and Purpose: Spontaneous esophageal rupture, also known as Boerhaave syndrome, is a rare but life threatening condition. It typically occurs after forceful vomiting, leading to a full thickness tear in the esophageal wall. Early recognition is critical, as delayed diagnosis significantly increases mortality.

Materials and Methods: A 38 year old male patient presented to the emergency department with sudden onset of severe chest pain and shortness of breath following repeated episodes of vomiting after alcohol intake. Vital signs revealed hypotension and tachycardia. On physical examination, crepitus was noted in the neck and chest wall, consistent with subcutaneous emphysema. Chest X ray suggested mediastinal air, and CT imaging confirmed esophageal rupture with mediastinal fluid leakage. The patient was immediately referred to the thoracic surgery department and admitted for urgent management.

Results and Conclusion: Boerhaave syndrome should be suspected in patients presenting with acute chest pain after vomiting, especially when accompanied by subcutaneous emphysema or mediastinal air. Prompt diagnosis and surgical intervention are essential to improve survival. A thorough clinical history and rapid multidisciplinary coordination between emergency medicine, radiology, and surgery are key to successful outcomes.

Keywords: Boerhaave

Ref No: 6241

PERSISTENT ORAL EROSIONS: A CASE REPORT OF PRELIMINARY DIAGNOSIS OF PEMPHIGUS VULGARIS

ALARA NERGİZ SOSLU[1], ZEYNEP ÇAKIR[1]

[1]ATATURK UNIVERSITY FACULTY OF MEDICINE, DEPARTMENT OF EMERGENCY MEDICINE

ALARA NERGİZ SOSLU / ATATURK UNIVERSITY FACULTY OF MEDICINE, DEPARTMENT OF EMERGENCY MEDICINE

Introduction and Purpose: Erosive and ulcerative lesions seen in the oral mucosa present a wide range of differential diagnoses in emergency department presentations, from infectious causes to autoimmune diseases. Pemphigus vulgaris is a chronic autoimmune disease characterized by intraepidermal bullae formation affecting the skin and mucosa and can be life-threatening. Early diagnosis is critical in preventing systemic complications.

Materials and Methods: A 61-year-old female patient presented to our emergency department with painful erosions in the mouth that had been ongoing for approximately one month and did not regress. In the patient's medical history, it was learned that the lesions made eating difficult and did not respond to topical treatments. On physical examination, widespread, painful, fragmented erosive areas were detected on the oral mucosa.Since the patient remained stable, dermatology was consulted. Following the evaluation, a mucosal biopsy by the ear, nose, and throat (ENT) department and simultaneous testing of Desmoglein 1 and Desmoglein 3 levels in the blood were planned for a definitive diagnosis. Mycostatin suspension was prescribed to provide symptomatic relief until biopsy and test results were available. The patient was discharged with a follow-up plan for dermatology and ENT outpatient clinics.

ORAL PEMPHIGUS VULGARIS



Results and Conclusion: Autoimmune bullous diseases such as the pemphigus group should be kept in mind in the emergency department for oral erosions lasting longer than one month and showing resistance to conventional treatments. These patients should not only be treated symptomatically but should be directed to advanced diagnostic processes with a multidisciplinary approach (dermatology, ENT). Awareness of the emergency physician is vital as delay in diagnosis may lead to disease progression and serious morbidity.

Keywords: oral erosions, pemphigus vulgaris, autoimmune disease

Ref No: 6250

Traumatic Pisiform Dislocation

Berk Oral[1], Ali Gür[1], Nisa Mındız[1]
[1]Atatürk University
Berk Oral / Atatürk University

Introduction and Purpose: Pisiform dislocation is an uncommon wrist injury, typically resulting from direct trauma or forceful hyperextension of the wrist. Although rare compared to lunate dislocation, it can cause significant pain, instability, and functional impairment if not promptly recognized. Because of its anatomical relationship with the flexor carpi ulnaris tendon, pisiform displacement may also affect grip strength and wrist mechanics.

Materials and Methods: A 24 year old male presented to the emergency department after falling from a ladder onto his outstretched hand. He reported severe wrist pain, swelling, and inability to move the wrist. On examination, there was marked tenderness over the ulnar aspect of the carpal region, swelling, and decreased range of motion. Neurological assessment revealed numbness in the ulnar distribution of the hand, raising concern for nerve involvement. X ray imaging demonstrated dislocation of the pisiform bone from its articulation with the triquetrum. The patient was urgently referred to orthopedic surgery, where closed reduction was attempted, followed by surgical stabilization.

Results and Conclusion: Traumatic pisiform dislocation should be considered in patients with wrist pain and deformity after high energy trauma, particularly when tenderness is localized to the ulnar side. Early diagnosis with radiographs and prompt orthopedic intervention are essential to restore wrist function and prevent chronic instability. Clinicians should maintain a high index of suspicion, as delayed recognition can result in persistent pain, weakness in grip, and long term disability.


X-Ray

Keywords: dislocation, carpals

Ref No: 6377

The Effects of Fragmented QRS on Mortality and Morbidity in Patients with Chronic Obstructive Pulmonary Disease Presenting to the Emergency Department

Ekim Sağlam Gürmen[1], Salih Mert Kalfaoğlu[1], Bülent Demir[1]
[1]Manisa Celal Bayar University School of Medicine, Department of Emergency Medicine, Manisa, Turkey
Salih Mert Kalfaoğlu / Manisa Celal Bayar University School of Medicine, Department of Emergency Medicine, Manisa, Turkey

Introduction and Purpose: The aim of this study was to evaluate the prognostic value of clinical, laboratory, and electrocardiographic parameters in predicting clinical outcomes and mortality in patients presenting with acute exacerbation of chronic obstructive pulmonary disease (COPD). In particular, the relationships of arterial blood gas parameters, the DECAF score, and the presence of fragmented QRS (fQRS) with intensive care unit (ICU) requirement and mortality were investigated.

Materials and Methods: This retrospective observational study included patients diagnosed with COPD who were followed between 01.12.2022 and 01.12.2023 at Manisa Celal Bayar University Faculty of Medicine, Hafsa Sultan Hospital. Demographic characteristics, vital signs, arterial blood gas parameters, biochemical and hematological data, electrocardiographic findings, and DECAF scores were recorded. Clinical outcomes were classified as discharge, ward admission, or ICU admission, and 1-year mortality was also evaluated. The discriminative performance of variables for outcomes was analyzed using statistical tests and receiver operating characteristic (ROC) curve analyses.

Results and Conclusion: A total of 100 patients were included in the study. The 1-year mortality rate was 31%, and 20% of patients required ICU admission. Arterial blood gas parameters, particularly pCO_2 and pH, demonstrated strong discriminative ability for predicting ICU admission. The DECAF score showed robust prognostic performance in predicting clinical outcomes and ICU requirement. Patients who died had lower hemoglobin levels and higher urea and lactate levels. In contrast, no significant association was observed between gender, atrial fibrillation, or the presence of fQRS and clinical outcomes or mortality. Coclusion:Respiratory physiological deterioration and markers of systemic metabolic stress appear to be the main determinants of clinical course in COPD exacerbations. Combined evaluation of arterial blood gas parameters and the DECAF score provides a practical and effective approach for early prediction of ICU need and mortality risk. The presence of fQRS was found to have limited prognostic value in the acute setting. These findings support the importance of physiology-centered comprehensive risk assessment in the clinical management of COPD exacerbations.

Keywords: Chronic obstructive pulmonary disease, fragmented QRS, mortality

Ref No: 6383

Spontaneous Hemoperitoneum Presenting as Acute Abdomen: A Case Report

Elif Yıldız[1], Onur Bozdağ[2], Asel Hale Pilgeci[1], Emre Kalkan[2], Bahadır Taşlıdere[2], Başar Cander[2]

[1]Bezmialem Vakıf University, Medical Faculty.
[2]Bezmialem Vakıf University, Emergency Department.

Onur Bozdağ / Bezmialem Vakıf University, Emergency Department.

Introduction and Purpose: We present a case of spontaneous hemoperitoneum in a previously healthy adult male presenting with acute abdominal pain, in whom no definite bleeding source could be identified despite imaging and surgical exploration. This case highlights the diagnostic challenges and the importance of timely evaluation and management in unexplained intraabdominal bleeding.

Materials and Methods: A 41-year-old male was brought to the emergency department by emergency medical services with the chief complaint of abdominal pain. The pain had started suddenly two hours prior to admission and radiated to the back. There was no history of prior intraabdominal surgery, trauma, pancreatitis, or cholecystitis. Abdominal examination revealed tenderness in both the right and left upper quadrants, with positive guarding and rebound tenderness. Abdominal CT showed high-density (hemorrhagic) free fluid in all peritoneal compartments, including the perihepatic, perisplenic, pelvic regions. During follow-up, the patient's hemoglobin level decreased from 13.8 g/dL to 11.2 g/dL within the same day. The patient was taken to the operating room for diagnostic laparoscopy. During exploration, diffuse intra-abdominal blood and clots were seen, so the procedure was converted to open surgery. Blood and clots were found in all four abdominal quadrants and were removed. The abdomen was washed with warm saline. No active bleeding or injury was found in the liver or spleen. Since no active bleeding was found, two silicone drains were placed—one toward the pelvis and one toward the splenic area. The abdomen was then closed in layers. The patient was discharged after five days of hospitalization.

Results and Conclusion: This case highlights the diagnostic challenges of spontaneous hemoperitoneum presenting as acute abdomen. The patient presented with sudden-onset abdominal pain radiating to the back, accompanied by nausea and vomiting, which initially suggested more common conditions such as acute pancreatitis or gastrointestinal pathology;

however, normal laboratory findings, including pancreatic enzymes, made these diagnoses less likely. Imaging revealed diffuse intraabdominal hemorrhagic fluid, raising suspicion for internal bleeding, yet no definitive source was identified. Despite a significant drop in hemoglobin levels and the development of hypotension, surgical exploration failed to demonstrate active bleeding or solid organ injury, suggesting a possible self-limited or low-pressure bleeding source.

Keywords: Spontaneous Hemoperitoneum, Acute Abdomen, Abdominal Pain

---

Ref No: 6428

Crepitation over uvula edema: diagnostic pitfalls in post-cough facial swelling

Gamze Yıldız[1], Emine Doğan[1], Emrullah Atçı[1], Abdülaziz Doğan[1], Mehmet Gül[1]

[1]Emergency Medicine Department, Konya City Hospital, Türkiye

Gamze Yıldız / Emergency Medicine Department, Konya City Hospital, Türkiye

Introduction and Purpose: Anaphylaxis is a rapid-onset systemic hypersensitivity reaction associated with high mortality. However, certain clinical presentations can mimic anaphylaxis, leading to misdiagnosis and inappropriate management. Rarely, pneumothorax and pneumomediastinum may present with facial and cervical swelling secondary to subcutaneous air tracking. This study aims to present a case referred with a presumptive diagnosis of anaphylaxis, in which an underlying secondary spontaneous pneumothorax and pneumomediastinum were subsequently identified.

Materials and Methods: A 73-year-old male patient was referred from an external center with a preliminary diagnosis of anaphylaxis. The patient's history revealed the sudden onset of swelling in the left periorbital region following two episodes of severe coughing that same night. Suspecting uvular edema, the referring center had administered intramuscular adrenaline. His past medical history was notable for a diagnosis of lung adenocarcinoma, for which he had undergone left upper and lower lobe wedge resections three months prior. Upon presentation to the emergency department, his oxygen saturation was measured at 87%, while his other vital signs remained stable. Physical examination revealed extensive subcutaneous emphysema, palpable crepitus, and pronounced swelling in the left periorbital region. A computed tomography (CT) scan of the thorax demonstrated extensive subcutaneous emphysema, a left-sided pneumothorax, and pneumomediastinum. The patient was subsequently admitted to the thoracic surgery intensive care unit.

Results and Conclusion: Secondary spontaneous pneumothorax exhibits a more severe clinical course in patients with underlying pulmonary disease and frequently presents with hypoxemia. The subcutaneous spread of air can produce dramatic swelling, particularly in the facial region, which can clinically mimic anaphylaxis. However, the presence of palpable crepitus, a history of coughing or previous thoracic surgery, and the absence of systemic allergic manifestations are crucial determinants in the differential diagnosis. In patients presenting to the emergency department with sudden-onset facial swelling, maintaining a high index of suspicion for air leak syndromes is of critical importance to ensure accurate diagnosis and appropriate clinical management.

Keywords: Pneumothorax, subcutaneous emphysema, anaphylaxis

Ref No: 6437

Beyond Venous Thrombosis: A Fatal Case of Trousseau Syndrome Presenting with Multiorgan Arterial Infarction

Nurbanu Akdoğan[1], Adem Boz[1], Damla Anbarlı Metin[1], Mustafa Köksal[1], Büşra Bildik[1], Bora Çekmen[1]

[1]Karabuk University, Faculty of Medicine, Department of Emergency Medicine

Nurbanu Akdoğan / Karabuk University, Faculty of Medicine, Department of Emergency Medicine

Introduction and Purpose: Hypercoagulability in malignancy is primarily caused by procoagulant substances secreted by tumor cells. Trousseau syndrome is a paraneoplastic condition that typically presents with venous thrombosis, though it can also manifest as severe multiorgan arterial infarctions. This case report aims to highlight that gastrointestinal malignancies can present with severe thrombosis and that standard anticoagulant therapy may be insufficient in certain cases.

Materials and Methods: A 56-year-old male patient, who was already on regular direct oral anticoagulant (DOAC) therapy with apixaban for a history of deep vein thrombosis, presented to the emergency room with severe abdominal pain. Initial evaluations included bedside abdominal ultrasonography and laboratory investigations, which showed leukocytosis and elevated D-dimer levels. Due to persistent pain and clinical suspicion, a contrast-enhanced abdominal computed tomography (CT) scan was performed. Following clinical deterioration into an acute abdomen, the patient was taken for an emergency laparotomy.

Results and Conclusion: The initial CT scan revealed diffuse patchy hypodense areas consistent with splenic infarction. During the emergency laparotomy, superior mesenteric artery occlusion, massive mesenteric ischemia, multiple metastatic liver nodules, and an occult 2 cm jejunal mass were identified. The patient subsequently died on postoperative day 3 despite intensive care and inotropic support. This case demonstrates that unexplained, aggressive multiorgan arterial thromboses occurring despite regular DOAC therapy should raise high clinical suspicion for Trousseau syndrome. Clinicians should promptly investigate for occult malignancies in such patients, and low-molecular-weight heparin (LMWH) is considered the preferred and more reliable treatment option for malignancy-associated hypercoagulable states.

Keywords: Trousseau syndrome, Arterial thrombosis, Splenic infarction

---

Ref No: 6451

The deadly progression: autonomic instability as a fatal complication of guillain-barré syndrome

Mustafa Nurullah Çekiç[1], Asiye Müminat Çap[1], Yasin Yağcılar[1], Yasin Yıldız[1], Mehmet Gül[1]

[1]Emergency Medicine Department, Konya City Hospital, Turkiye

Yasin Yağcılar / Emergency Medicine Department, Konya City Hospital, Turkiye

Introduction and Purpose: Guillain-Barré syndrome (GBS) is an acute, inflammatory, and autoimmune-demyelinating polyneuropathy characterized by ascending (bottom-up) symmetrical weakness and areflexia, usually with a rapid and progressive course. Approximately half of GBS cases are severe and require intensive care due to life-threatening respiratory failure or autonomic instability. The purpose of presenting this case is to draw attention to the poor prognosis and complications.

Materials and Methods: A 47-year-old male patient with no known underlying medical conditions presented to the emergency department with complaints of weakness and malaise that began approximately 7 days prior. Three days prior, he presented with numbness and tingling in his upper extremities, followed by progressive weakness in both upper and lower extremities and shortness of breath. Initial vital signs in the emergency department were: blood pressure 130/80 mmHg, SpO2 95%, pulse 90/min, and temperature 37°C. Central imaging studies performed in the emergency department showed no acute neuropathology.On initial examination, the patient was conscious and oriented. Neurological examination revealed muscle strength of 2-3/5 in the proximal upper extremities and 3-4/5 in the distal upper extremities; 2-3/5 in the proximal lower

extremities and 3/5 in the distal lower extremities. Deep tendon reflexes were absent. The patient was admitted to the neurology ward with a preliminary diagnosis of GBS. Lumbar puncture revealed elevated CSF protein levels, and plasmapheresis treatment was initiated.The patient, whose swallowing difficulties were observed to increase, developed a decline in consciousness and tachypneic respiration on the 4th day. The patient, who developed hypotension, was given vasopressor support, and the condition was evaluated as autonomic involvement of GBS. The patient, who was intubated and monitored in the neurology intensive care unit for 54 days, passed away.

Results and Conclusion: Guillain-Barré Syndrome (GBS) is a disease that is difficult to diagnose, especially in its early stages. Literature indicates that GBS can be missed in up to 25% of cases initially. In the presented case, the onset of symptoms with numbness in the upper extremities, rather than the typical ascending course, suggests "atypical GBS" variants. In the emergency department, GBS is a condition that requires rapid diagnosis based on clinical suspicion, even if imaging findings are initially normal.

Keywords: guillain-barré syndrome, emergency, progression

Ref No: 6477

Suspected Recurrent Myocarditis Presenting as Acute Decompensated Heart Failure After Viral Prodrome in a Young Woman: A Case Report

HÜSEYİN GÜRBÜZ[1], AHMET OCAK[1]

[1]Department of Emergency Medicine, Harran University Faculty of Medicine, Şanlıurfa, Türkiye

AHMET OCAK / Department of Emergency Medicine, Harran University Faculty of Medicine, Şanlıurfa, Türkiye

Introduction and Purpose: Myocarditis is an inflammatory disease of the myocardium with a broad clinical spectrum ranging from mild symptoms to fulminant heart failure and cardiogenic shock. Viral infections remain among the most common etiological triggers and may induce myocardial injury through both direct cytotoxic effects and immune-mediated inflammatory mechanisms. This case report aims to highlight recurrent or post-viral myocarditis as an important cause of acute decompensated heart failure in a young patient presenting with dyspnea after a viral prodrome.

Materials and Methods: We report the case of a 28-year-old woman with a previous history of myocarditis who presented to the emergency department with acute onset dyspnea following a recent viral upper respiratory tract infection. On admission, oxygen saturation on room air was 82%, heart rate was 110 beats/min, and blood pressure was 119/70 mmHg. Pulmonary auscultation revealed bilateral fine crackles. Laboratory testing demonstrated markedly elevated troponin levels (11,597 pg/mL), creatinine 2.13 mg/dL, AST 394 U/L, and ALT 442 U/L. Chest radiography demonstrated pulmonary edema. Transthoracic echocardiography revealed severe left ventricular systolic dysfunction with an ejection fraction of 25–30% and segmental wall motion abnormalities.

Results and Conclusion: The patient was diagnosed with acute decompensated heart failure associated with suspected recurrent or post-viral myocardial inflammatory involvement and was admitted to the intensive care unit for further management and close monitoring. The clinical presentation, significantly elevated cardiac biomarkers, pulmonary edema on chest radiography, and markedly reduced left ventricular ejection fraction supported the diagnosis of severe myocardial dysfunction in the setting of recent viral illness.This case highlights the importance of considering myocarditis and myocarditis-related heart failure in the differential diagnosis of acute dyspnea in young patients presenting after a viral prodrome. Early recognition in the emergency department is essential for prompt monitoring, advanced cardiac evaluation, and appropriate intensive care management.

Chest radiograph showing pulmonary edema



Posteroanterior chest radiograph demonstrating bilateral pulmonary edema.

Keywords: Myocarditis, Acute heart failure, Viral infection

Ref No: 6536

INVESTIGATION OF THE PROGNOSTIC VALUE OF THE ONCALL SCORE IN THE CLINICAL DECISION-MAKING PROCESS FOR ONCOLOGY PATIENTS PRESENTING TO THE EMERGENCY DEPARTMENT

Julide Gurbuz[1], Basar Cander[1], Bahadir Taslidere[1]

[1]Bezmialem Foundation University Hospital

Julide Gurbuz / Bezmialem Foundation University Hospital

Introduction and Purpose: The continuity of demand for healthcare services and overcrowding in emergency departments necessitate optimizing early and safe discharge processes for low-risk oncology patients or making rapid admission decisions for high-risk patients. The aim of this study is to develop a scoring system to optimize hospitalization decision-making processes for oncology patients presenting to the emergency department.

Materials and Methods: This retrospective, single-center study was conducted on patients aged 18 and over diagnosed with malignancy who presented to the BVU Emergency Department between January 2021-December 2023. Demographic data, vital signs, treatment histories, and laboratory parameters were recorded, aimed at predicting the risk of hospitalization (ward and intensive care admission) and mortality. In constructing the scoring system, 13 predetermined potential parameters were evaluated first by univariate and then by multivariate logistic regression analyses. As a result of statistical analyses, the multivariate regression model, comprising Oncologic diagnosis type (hematologic/solid), Neutropenia (ANC < 1000/mm³), High Creatinine (> 1.30 mg/dL), Age (≥65 years), Low Blood Pressure, and Last 48h Chemotheapy, was identified as the model with the highest discriminatory power (AUC: 0.720). The model's performance and predictive power were tested using ROC analysis, and all analyses were performed within a 95% confidence interval using MedCalc® software.

Figure 1: ROC Curve Analysis for the ONCALL Score

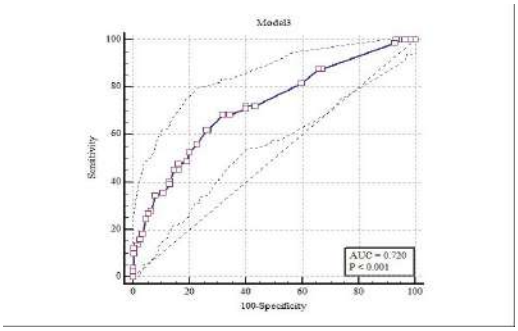

Figure 2: Performance Metrics and Predictive Accuracy of the ONCALL Score (Model 3).

Model 3 - Area under the ROC curve (AUC)

Area under the ROC curve (AUC)	0.720
Standard Error [a]	0.0343
95% Confidence interval [b]	0.663 to 0.771
z statistic	6.404
Significance level P (Area=0.5)	<0.0001

[a] DeLong et al., 1988

[b] Binomial exact

Youden index

Youden index J	0.3647
Associated criterion	>0.22
Sensitivity	68.29
Specificity	68.18

Figure 3: ONCALL Score (Model 3)

O → Oncologic Status (Hematolojik malignite)
N → Neutropenia (ANC <1000)
C → Creatinine High (>1.30 mg/dL)
A → Age ≥65
L → Low Blood Pressure (Hipotansiyon)
L → Last 48h Chemotherapy

Figure 4: Regression Coefficients and Statistical Parameters for the ONCALL Scoring Model.

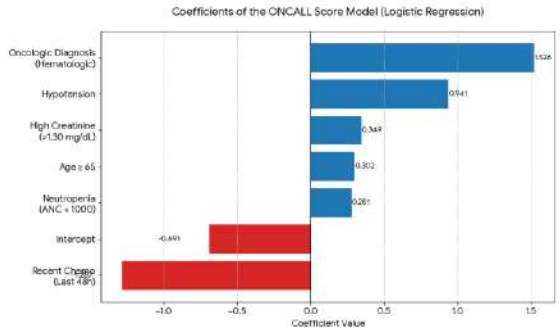

Results and Conclusion: A total of 285 patients with a mean age of 63.8 ± 13.4 years, 55.8% of whom were male, were included in the study. The most common reasons for presentation were gastrointestinal (41.3%) and respiratory (14.5%) symptoms. Digestive (24.9%), respiratory

(22.5%), and hematopoietic (20.4%) system malignancies were prominent among primary diagnoses. A history of metastasis was present in 62% of patients, and additional chronic diseases in 72.5%; hypotension was detected in 19.3% and elevated creatinine in 23.9% at the time of presentation. When clinical outcomes were evaluated, the majority of patients (73.7%) were hospitalized (ward 48.4%, intensive care 25.3%), only 22.5% were discharged, and the total in-hospital mortality rate was 28.4%. The ONCALL score, developed with bedside parameters, is a practical tool for identifying the high-risk group requiring hospitalization among oncology patients presenting to the ED. Multicenter prospective studies are needed to increase the clinical validity and generalizability of the model.

Table 1: Distribution of Demographic Data, Clinical History, and Patient Outcomes.

Cinsiyet	**N**	**%**
Kadın	126	44,2
Erkek	159	55,8
Yaş (yıl)	**Ort ± SS**	**Median (min-maks)**
	63,8 ± 13,4	64 (31-101)
Başvuru Şikayeti/ Durumu	**N**	**%**
Nörolojik	29	10,2
Solunumsal	41	14,5
Kardiyak	9	3,2
Solunumsal + Kardiyak	1	0,4
Solunumsal + GIS	3	1,1
GIS	117	41,3
Kardiyak + Nörolojik	1	0,4
Kardiyak + GIS	1	0,4
Üro - Jinekolojik	11	3,9
Muskuloskeletal	7	2,5
Ağrı - Ateş - Halsizlik	56	19,8
Travma	2	0,7
Komplikasyon	3	1,1
Arrest	1	0,4

GIS + Ağrı-Ateş-Halsizlik	1	0,4
Kronik Hastalıklar	**N**	**%**
Diabetes Mellitus		
Yok	212	74,4
Var	73	25,6
Hipertansiyon		
Yok	159	56
Var	125	44
Diğer		
Yok	78	27,5
Var	206	72,5
Metastaz	**N**	**%**
Yok	108	38
Var	176	62
Kemoterapi Öyküsü	**N**	**%**
Yok	116	41,1
Var	166	58,9
Son 48 Saatte Kemoterapi Öyküsü	**N**	**%**
Yok	261	93,2
Var	19	6,8
Radyoterapi Öyküsü	**N**	**%**
Yok	173	61,6
Var	108	38,4
Cerrahi Öyküsü	**N**	**%**
Yok	120	42,1
Var	165	57,9
Onkolojik Tanısı	**N**	**%**
Sinir sistemi	9	3,2
Kardiyovasküler sistem	0	0
Solunum sistemi	64	22,5
Sindirim sistemi	71	24,9
Hematopoetik ve Lenfatik sistem	58	20,4
Üriner sistem	24	8,4
Deri ve Yumuşak doku	4	1,4

Kas iskelet sistemi	4	1,4
Endokrin sistem	6	2,1
Reprodüktif sistem	45	15,8
Hastane içi mortalite	**N**	**%**
Yok	204	71,6
Var	81	28,4
Sonlanım	**N**	**%**
Taburculuk	64	22,5
Servis yatışı	138	48,4
Yoğun bakım ünitesine yatış	72	25,3
Acilde exitus	11	3,9

Table 2: Parameters Included in the Univariate Analysis for the ONCALL Score.

ONCALL Skoru İçin Tek Değişkenli Analize Dahil Edilen Parametreler	**N**	**%**
Onkolojik tanı		
Hematolojik	58	20,4
Solid	227	79,6
Mutlak Nötrofil Sayısı		
<10 (×10⁹/L)	192	67,4
>10 (×10⁹/L)	93	32,6
Kemoterapi Öyküsü		
Yok	116	41,1
Var	166	58,9
Son 48 saatte Kemoterapi Öyküsü (N=280)		
Yok	261	93,2
Var	19	6,8
Vücut ısısı (°C)		

	<38	264	92,6
	>38	21	7,4
Hipotansiyon			
	Yok	230	80,7
	Var	55	19,3
Hiponatremi			
	Yok	183	64,2
	Var	102	35,8
Hiperkalemi			
	Yok	283	99,3
	Var	2	0,7
Hipokalsemi			
	Yok	276	96,8
	Var	9	3,2
LDH Yüksekliği			
	Yok	99	34,9
	Var	185	65,1
Laktat Yüksekliği			
	Yok	118	57,6
	Var	87	42,4
Kreatinin Yüksekliği			
	Yok	217	76,1
	Var	68	23,9
Yaş >65			
	Yok	145	50,9
	Var	140	49,1
Kronik Hastalık öyküsü			
	Yok	78	27,5
	Var	206	72,5

Keywords: Emergency department, Cancer, Risk Stratification

Ref No: 6538

Impact of emergency department boarding time on intensive care unit clinical outcomes

Muhammed Sezai Bazna[1], Burak Katipoğlu[2]

[1]Ministry of Health Etlik City Hospital Intensive Care Unit
[2]Ministry of Health Etlik City Hospital Emergency Medicine Clinic

Muhammed Sezai Bazna / Ministry of Health Etlik City Hospital Intensive Care Unit

Introduction and Purpose: Delayed transfer of critically ill patients from the emergency department (ED) to the intensive care unit (ICU) is associated with adverse outcomes. Data from high-volume Turkish centers are scarce. This study evaluated the effect of ED boarding time on in-hospital mortality and ICU length of stay (LOS), and identified predictors of delayed transfer.

Materials and Methods: Study included all patients aged ≥18 years admitted to any ICU following an ED visit at Ankara Etlik City Hospital between March 1, 2025 and February 28, 2026. Patients directly transferred from the operating room, those bypassing the ED, and those with incomplete records were excluded. ED boarding time was calculated as the interval between ED registration and ICU admission. Patients were classified as early transfer (< 6 hours) or delayed transfer (≥6 hours) based on the most commonly applied threshold in the literature. The primary outcome was in-hospital mortality; the secondary outcome was ICU LOS. Categorical variables were compared using the chi-square test; continuous variables were compared using the Mann–Whitney U test. Multivariable logistic regression adjusted for ICU type was used to identify independent mortality predictors. Receiver operating characteristic (ROC) curve analysis determined the optimal boarding time cut-off. All analyses were performed with SPSS v.26; $p < 0.05$ was considered statistically significant.

Results and Conclusion: Of 2,029 patients, 2,005 were analyzed. Early transfer: 521 (26.0%); delayed: 1,484 (74.0%). Median boarding time: 18.6 h (interquartile range [IQR]: 8.5–34.2). Overall mortality: 34.5% (n=692), higher in the delayed group (36.0% vs. 30.3%; p=0.016). Median ICU LOS: 5 days (IQR: 2–14) vs. 8 days (IQR: 3–21; $p < 0.001$). A dose-response trend was noted (p=0.028). Boarding ≥6 h was an independent mortality predictor (odds ratio [OR]: 1.46; 95% confidence interval [CI]: 1.18–1.81; p=0.001). ROC yielded area under the curve (AUC) 0.583 (95% CI: 0.558–0.608; $p < 0.001$); optimal cut-off: 11.5 h (sensitivity 64.2%, specificity 51.8%). Boarding time weakly correlated with ICU LOS (Spearman r=0.27; $p < 0.001$). ED boarding ≥6 h independently predicted higher mortality and longer ICU LOS, underscoring the need to minimize boarding. The retrospective single-center design is the main limitation; this study contributes high-volume Turkish data to the literature.

Clinical Outcomes by Group

Gruplara Göre Klinik Sonlanımlar

Parametre	Erken Transfer (<6 saat) n=521	Gecikmiş Transfer (≥6 saat) n=1484	p değeri
Mortalite, n (%)	158 (%30,3)	534 (%36,0)	**0,016**
Ortanca YBÜ yatış süresi, gün (IQR)	5 (2–14)	8 (3–21)	**<0,001**
Ortanca ED bekleme süresi, saat (IQR)	–	–	18,6 (8,5–34,2)

ROC analysis



Mortality Rates by Waiting Time Groups

Bekleme Süresi Gruplarına Göre Mortalite Oranları

Bekleme Süresi	<6 saat	6–12 saat	12–24 saat	≥24 saat	Toplam
Hasta sayısı (n)	521	468	512	504	2005
Mortalite (%)	30,3%	35,9%	36,5%	35,5%	**34,5%**

Keywords: emergency department boarding time, intensive care unit, in-hospital mortality

Ref No: 6598

Hidden danger in blunt chest trauma: traumatic aortic dissection with concomitant thoracic injuries

Hatice Yollar[1], Mine Kayacı Yıldız[1], Furkan Tayiz[1], Mustafa Gülpembe[1], Mehmet Gül[1]

[1]Emergency Medicine Department, Konya City Hospital, Türkiye

Hatice Yollar / Emergency Medicine Department, Konya City Hospital, Türkiye

Introduction and Purpose: Traumatic aortic injuries are the second leading cause of death in blunt thoracic trauma. Early diagnosis and rapid surgical intervention are critical for survival. This report presents a case of traumatic aortic dissection complicated by multiple thoracic injuries

Materials and Methods: A 67-year-old male patient was admitted to the emergency department following an intra-vehicular traffic accident. Imaging studies revealed pericardial effusion, pneumothorax, hemothorax, as well as sternal and multiple rib fractures. Thoracic CT angiography demonstrated an aortic dissection distal to the aortic arch. The patient was emergently taken to surgery by the cardiovascular surgery team.

Results and Conclusion: CT angiography is the gold-standard diagnostic method for traumatic aortic injuries. In our case, the diagnosis was established via CT angiography, leading to immediate surgical referral. The literature emphasizes that early diagnosis and surgical intervention significantly improve survival rates. Traumatic aortic dissection is an emergency condition frequently encountered in blunt thoracic trauma and is associated with high mortality. Although diagnosis becomes more challenging when complicated by multiple thoracic injuries, CT angiography remains critical for early detection. Prompt emergency surgical intervention enhances the chances of survival.

Keywords: traumatic aortic dissection, blunt thoracic trauma, emergency surgery

Ref No: 6607

Normal Imaging, Significant Diagnosis Guillain-Barré Syndrome in the Emergency Department

Yunus Hatipoğlu[1]

[1]Niğde Ömer Halisdemir Training and Research Hospital, Department of Emergency Medicine

Yunus Hatipoğlu / Niğde Ömer Halisdemir Training and Research Hospital, Department of Emergency Medicine

Introduction and Purpose: Guillain-Barré syndrome (GBS) is an acute immune-mediated polyradiculoneuropathy and the most common cause of acute flaccid paralysis worldwide. It typically presents with progressive motor weakness following an antecedent infection; however, its heterogeneous clinical spectrum may lead to delayed recognition in the emergency department, particularly in patients with nonspecific symptoms.This case aims to highlight the importance of clinical evaluation in patients presenting with nonspecific neurological symptoms and to emphasize the need to consider GBS even in the absence of imaging abnormalities.

Materials and Methods: A 48-year-old female presented to the emergency department with progressive weakness and numbness affecting both upper and lower extremities. Her vital signs were stable, and she had no significant past medical history. Neurological examination revealed abnormal cerebellar findings, absence of nystagmus, and isocoric pupils. Muscle strength was decreased to 2/5 in the upper extremities and 4/5 in the lower extremities.Neuroimaging showed no acute pathology. Given the clinical findings, a neurology consultation was obtained. A lumbar puncture was planned, and the patient was admitted to the neurology ward with a preliminary diagnosis of Guillain-Barré syndrome.

Results and Conclusion: Guillain-Barré syndrome should be considered in the differential diagnosis of patients presenting to the emergency department with generalized weakness, even in the absence of abnormal imaging findings. Early recognition based on careful neurological examination is crucial for timely diagnosis and management.

Keywords: Guillain-Barré Syndrome, Emergency Department, Acute Weakness

Ref No: 6688

Thrombosed Coronary Graft Aneurysm: An Atypical Presentation

Sarah SABBAGH SHARIF[1], Hatice Neva BAKİ[1], Ayşe IŞIK GÜVEN[1], Bahadır TAŞLIDERE[1], Başar CANDER[1]

[1]Bezmialem University Hospital
Hatice Neva BAKİ / Bezmialem University Hospital

Introduction and Purpose: Saphenous vein graft (SVG) aneurysms are rare late complications of coronary artery bypass grafting (CABG). They are often asymptomatic and incidentally detected; however, large or thrombosed aneurysms may result in serious complications, including myocardial ischemia, embolization, or rupture. Atypical presentations may delay diagnosis, particularly in emergency settings.

Materials and Methods: A 79-year-old male presented to the emergency department with a three-day history of abdominal pain and constipation. His medical history included hypertension and prior CABG. Notably, three days before admission, he had been evaluated for exertional chest pain, and coronary angiography had been recommended.At presentation, he denied chest pain and was hemodynamically stable. Physical examination revealed no signs of acute abdomen, aside from a reducible abdominal hernia. Laboratory tests showed markedly elevated troponin levels (2400 ng/L) without dynamic electrocardiographic changes.Computed tomography performed for abdominal symptoms demonstrated jejunal loop herniation with mild dilation. Incidentally, a giant aneurysmal dilation along the course of the right coronary artery bypass graft measuring approximately 62 × 55 × 50 mm was identified, with partial thrombosis and mural thickening, consistent with a saphenous vein graft aneurysm. The lesion was adjacent to the right atrium, with a smaller secondary aneurysmal dilation also noted.The patient was admitted to the cardiology service for further evaluation. Transesophageal echocardiography demonstrated an aneurysmal structure near the right atrium with flow directed toward the atrial cavity, raising suspicion for possible communication. Coronary angiography confirmed dysfunction of the right coronary artery graft. Given the patient's stability and comorbidities, conservative management with close monitoring was preferred.

Results and Conclusion: This case highlights a giant, partially thrombosed saphenous vein graft aneurysm presenting with non-specific abdominal symptoms and elevated cardiac biomarkers in the absence of overt ischemic signs. The combination of atypical presentation and discordant findings led to its incidental detection, underscoring the importance of considering graft-related complications in patients with prior CABG.

Keywords: Saphenous vein graft aneurysm, Coronary artery disease, Thrombosis

Ref No: 6838

Ornidazole-Induced Bullous Fixed Drug Eruption: A Rare Case Report

Levent Şahin[1], Mehmet Erdi Yılmaz[1], Alanay Sude Türkmen[1]

[1]Kafkas University, Medical School, Emergency Medicine

Levent Şahin / Kafkas University, Medical School, Emergency Medicine

Introduction and Purpose: Fixed drug eruption (FDE) is a localized cutaneous adverse reaction that recurs at the same site upon re-exposure to a specific drug. While NSAIDs and sulfonamides are common triggers, bullous variants induced by nitroimidazoles like ornidazole are less frequently documented.

Materials and Methods: A 56-year-old woman presented with pruritus and numbness on the left hypothenar eminence six hours after ingesting 500 mg of ornidazole. Within 24 hours, an erythematous, ecchymotic bulla developed at the initial site, followed by ecchymosis on the thenar eminence. There were no systemic symptoms or prior history of similar reactions. Based on the temporal relationship and clinical morphology, a diagnosis of bullous FDE was made. The offending drug was discontinued, and the patient was treated with topical agents.

Figure 1. A well-demarcated, erythematous, ecchymotic bulla on the patient's left hypothenar eminence, consistent with a localized bullous fixed drug eruption.



Results and Conclusion: Clinicians should maintain a high index of suspicion for FDE when evaluating localized bullous lesions following nitroimidazole therapy to prevent future recurrence and potential generalization.

Keywords: Drug eruption, ornidazole, bullous lesion

Ref No: 6899

Traumatic Testicular Retraction After Blunt Trauma: A Case Report

YAVUZ CELİK[1], ULARBEK AKNAZAROV[1], TUNAHAN MESE[1], BAHADİR TASLİDERE[1], BASAR CANDER[1]

[1]Bezmialem Vakif University, Department of Emergency Medicine, Istanbul, Türkiye

ULARBEK AKNAZAROV / Bezmialem Vakif University, Department of Emergency Medicine, Istanbul, Türkiye

Introduction and Purpose: Traumatic testicular retraction is a rare clinical entity resulting from blunt scrotal or inguinal trauma, characterized by displacement of the testis from the scrotum into the inguinal canal or abdomen. Early diagnosis and management are crucial to prevent ischemic complications and long-term sequelae.

Materials and Methods: A 20-year-old male motorcyclist was admitted to the emergency department following a traffic accident at approximately 50 km/h. On presentation, the patient was conscious (Glasgow Coma Scale: 15), oriented, and hemodynamically stable, with no visible external injuries. Vital signs: Blood pressure: 120/70, Temperature: 36.6, Pulse: 90, Respiratory rate: 20, Oxygen saturation: 98, Blood glucose: 116. Physical examination revealed tenderness and a hernia-like swelling in the left inguinal region. Scrotal examination demonstrated absence of the left testis, with only one testis palpable in the scrotum.Computed tomography imaging demonstrated the left testis located within the inguinal canal, measuring approximately 40×27 mm, with no evidence of scrotal positioning. The patient was evaluated by the urology team with a preliminary diagnosis of traumatic testicular retraction. Manual reduction of the testis into the scrotum was successfully achieved.Subsequent Doppler ultrasonography revealed mildly increased vascular flow in both testes, likely secondary to trauma. Laboratory findings included leukocytosis (WBC: 16,000/mm³), while the others were within normal limits.Considering the risk of recurrent displacement and vascular compromise, the patient underwent left orchiopexy. The postoperative course was uneventful, and the patient was discharged in good clinical condition the following day.

Image of the testis in the left inguinal canal on a coronal CT scan



Image of the testis in the left inguinal canal on a axial CT scan

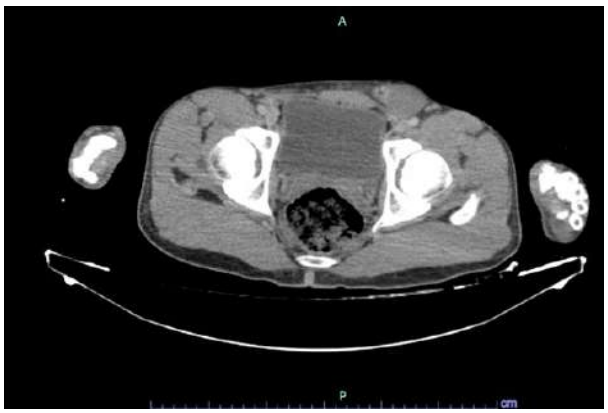

Results and Conclusion: Although rare, traumatic testicular retraction should be considered in patients presenting with inguinal swelling and absent testis after blunt trauma. Careful physical examination supported by imaging modalities facilitates accurate diagnosis. Early intervention, including manual reduction and surgical fixation, is essential for optimal outcomes.

Keywords: Testicular retraction, Orchiopexy, Scrotal trauma

Ref No: 6950

The Role of Lactate, pH, and Creatinine Levels in Predicting Mortality in Patients with Acute Pulmonary Embolism: A Retrospective Single-Center Study

Özhan Özcan[1]

[1]Malatya Turgut Özal Üniversitesi

Özhan Özcan / Malatya Turgut Özal Üniversitesi

Introduction and Purpose: Aim:

Pulmonary embolism (PE) is a serious cardiovascular emergency associated with high mortality. This study aimed to evaluate the relationship between clinical and laboratory parameters and mortality in patients diagnosed with PE.

Materials and Methods:

In this retrospective, cross-sectional, and observational study, patients diagnosed with PE in the Emergency Department of Malatya Training and Research Hospital between September 1, 2025, and December 1, 2025, were analyzed. A total of 41 patients were assessed, and 24 patients who met the inclusion and exclusion criteria were included in the study. Demographic data and laboratory parameters were obtained from hospital records. Statistical analyses were performed using SPSS version 27.0.

Results and Conclusion: Results:

Of the patients, 54.16% were male, and the median age was 68 years. All patients were hospitalized, and the mortality rate was found to be 12.5%. When factors associated with mortality were evaluated, lactate and creatinine levels were significantly higher in patients who died, whereas pH values were significantly lower. No significant relationship was found between other laboratory parameters and mortality. Correlation analysis revealed significant associations among markers of inflammation, acidosis, and renal function.Conclusion:In patients with pulmonary embolism, mortality is more closely associated with tissue perfusion and metabolic status rather than inflammatory parameters. Easily accessible biochemical parameters such as lactate, pH, and creatinine may be valuable for early risk stratification and prognosis prediction.

Mean, SD, median, and IQR values of the variables

Parameters	n	mean	SD	median	IQR 25%	IQR 75%
Age(year)		68	12.8			
Albumin(g/dL)		3.1	0.7			
HOSPITALTY(day)		5	1			
CRP(mg/L)				1.8	0.5	7.4
Neutrophil(×10³/µL)				7.7	5.2	11.5
Lymphocyte(×10³/µL)				1.9	1.1	2.5
Platelet(×10³/µL)	**24**			208	150	259
Hemoglobin(g/dL)				13	12.1	14.2
Monocytes (×10⁹/L)				0.7	0.5	1
Creatinine(mg/dL)				1	0.8	1.4
PH				7.35	7.27	7.41
pCO_2 (mmHg)				42.5	36.5	50
Lactate (mmol/L)				2.3	1.7	5.9

Keywords: pulmonary embolism, mortality, lactate

Ref No: 7040

Bilateral Toe Necrosis Developing After Exposure to Severe Cold: A Case Report with Preserved Major Arterial Flow

Nisa Nur İnal[1], Mustafa Polat[1], Hüseyin Özenç[1], Emin Fatih Vişneci[1], Mehmet Gül[1]
[1]Emergency Medicine Depatment, Konya City Hospital, Türkiye

Nisa Nur İnal / Emergency Medicine Depatment, Konya City Hospital, Türkiye

Introduction and Purpose: Frostbite injuries are cold-related traumatic damages that can lead to severe tissue loss, especially in unprotected and disadvantaged populations. Vasoconstriction, endothelial damage, and microvascular thrombosis play a role in the pathophysiology. The aim of this case report is to discuss a patient who developed bilateral widespread toe necrosis despite preserved major arterial circulation, in the context of the literature.

Materials and Methods: The patient presented with complaints of discoloration in both feet. In the history, it was noted that 15 days ago, the patient was exposed to significant cold outdoors for 1 day, followed by 3 days indoors. After the cold exposure, pain developed, and the patient was hospitalized for 5 days at a state hospital and then discharged. On physical examination: all toes on the right foot and approximately 90% of the toes on the left foot were blackened, with lesions appearing distal to proximal, sharply demarcated, and consistent with dry gangrene. A computed tomography angiography of the lower extremities was performed. Imaging results reported that both main external and internal iliac arteries, both deep and superficial femoral arteries, popliteal arteries, the tibioperoneal trifurcation region, as well as anterior tibial, posterior tibial, and peroneal arteries were patent up to the ankle level and of normal caliber. The patient, preliminarily diagnosed with third-degree frostbite, was consulted with orthopedics and cardiovascular surgery. Both departments reported no acute surgical indication, recommending monitoring and elective surgery.

Results and Conclusion: Freezing injuries are classified as superficial and deep, and in advanced stages, tissue necrosis and gangrene may develop. In this case, the patency of major arterial structures suggests that the pathology develops at the microvascular level. Vasospasm, endothelial damage, and microthrombosis that occur following cold exposure can lead to ischemia and necrosis in distal tissues. Even if macrovacular circulation is preserved in freezing injuries, thrombosis and ischemia developing at the microvascular level can cause distal tissue necrosis. This case demonstrates that patency of large vessels does not guarantee tissue viability. In delayed presentations, it is recommended to determine the demarcation line and plan surgery at the appropriate time. Early diagnosis is critical in reducing morbidity.

Keywords: frostbite, toe necrosis., frostbite injury

Ref No: 7045

A Rare Cause of Massive Hematemesis: Arterioesophageal Fistula Due to Ruptured Subclavian Artery Pseudoaneurysm Following Foreign Body Ingestion

Enes Hamdioğlu[1]

[1]Recep Tayyip Erdoğan University Training and Research Hospital, Emergency Medicine Department, Rize, Türkiye

Enes Hamdioğlu / Recep Tayyip Erdoğan University Training and Research Hospital, Emergency Medicine Department, Rize, Türkiye

Introduction and Purpose: Subclavian artery pseudoaneurysms are rare vascular lesions, most commonly associated with penetrating trauma and iatrogenic injuries. This case aims to present a previously unreported cause of subclavian artery pseudoaneurysm developing after ingestion of a sharp foreign body, leading to life-threatening massive hematemesis, and to emphasize the diagnostic challenges associated with this condition.

Materials and Methods: A 55-year-old female presented to the emergency department with massive hematemesis. Her history revealed that two weeks earlier, she had presented to another emergency department with a sensation of a foreign body in her throat after consuming a chicken-based meal. A non-contrast computed tomography (CT) scan performed at that time showed no pathological findings, and the patient was discharged. In the following days, she experienced intermittent minor episodes of bloody vomiting ("sentinel bleeding") and visited multiple healthcare centers; however, no definitive diagnosis was established. Upon presentation to our emergency department with massive hematemesis (approximately 700 cc), an urgent contrast-enhanced CT angiography (CTA) was performed. Imaging revealed esophageal perforation and a ruptured pseudoaneurysm of the left subclavian artery.

Figure 1

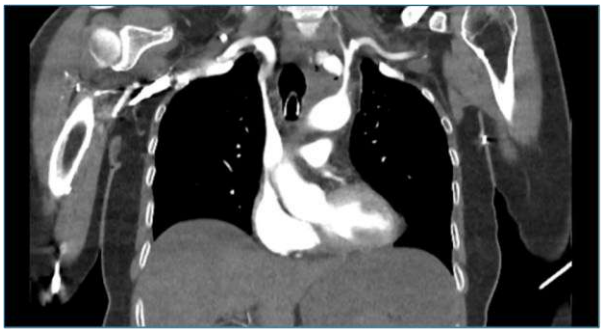

Coronal CT angiography image demonstrating a large pseudoaneurysm arising from the left subclavian artery

Figure 2

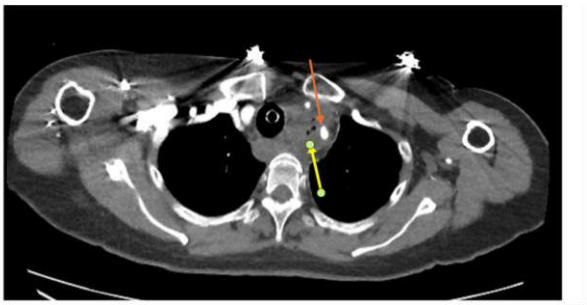

Axial CT angiography image at the level of the upper mediastinum demonstrating a ruptured pseudoaneurysm of the left subclavian artery (arrow), with associated periesophageal gas bubbles

Results and Conclusion: Artery-esophageal communications carry a mortality rate exceeding 70%. Diagnosis is often delayed because initial non-contrast CT scans have low sensitivity (~56%), whereas contrast-enhanced CTA is the gold standard with nearly 100% sensitivity. Ingested sharp foreign bodies carry a high risk of lethal vascular complications. A high index of clinical suspicion and early use of contrast-enhanced CTA are mandatory for any patient presenting with hematemesis and a history of foreign body ingestion to prevent a fatal outcome.

Keywords: subclavian artery pseudoaneurysm, foreign body ingestion, esophageal perforation

---

Ref No: 7048

Low Risk, High Danger: Acute Myocardial Infarction During Hair Transplantation

Mohamad Mukhtar Hamoud[1], Fatma Çakmak[2], Ramazan Güven[2]

[1]Istanbul Atlas University Faculty of Medicine Hospital, Emergency Department,
[2]Istanbul Atlas University Faculty of Medicine, Department of Emergency Medicine,

Mohamad Mukhtar Hamoud / Istanbul Atlas University Faculty of Medicine Hospital, Emergency Department

Introduction and Purpose: Hair transplantation is generally considered a minimally invasive cosmetic procedure with a low complication rate. However, although rare, cardiovascular events occurring during the procedure may be life-threatening. We report a young male patient who developed acute inferoposterolateral ST-elevation myocardial infarction (STEMI) following sudden-onset chest pain during a hair transplantation procedure.

Materials and Methods: A 33-year-old male presented to the emergency department with sudden-onset chest pain lasting for one hour, described as a squeezing sensation, accompanied by dyspnea and diaphoresis, which developed during a hair transplantation procedure. He had no prior history of similar symptoms, chronic illness, regular medication use, smoking, or family history of premature cardiovascular disease.On admission, vital signs were stable (blood pressure: 110/65 mmHg; pulse: within normal limits and regular). Cardiac and pulmonary examinations were unremarkable, with no peripheral edema or jugular venous distention.Electrocardiography demonstrated significant ST-segment elevation in leads II, III, aVF, and V5–V6, with reciprocal changes, consistent with acute inferoposterolateral STEMI.Initial troponin-I level was 6.111 µg/L, rising to 65.325 µg/L. The patient was urgently transferred to the catheterization laboratory for coronary angiography.Coronary angiography revealed 99% stenosis of the right coronary artery (RCA) and 80% stenosis of the left anterior descending artery (LAD). Percutaneous coronary intervention (PCI) was successfully performed using a 6F catheter, with restoration of coronary flow and no procedural complications.Post-procedural transthoracic echocardiography showed hypokinesia in the basal septal and basal inferior segments. Overall left ventricular systolic function was preserved with an ejection fraction of 50%.

Results and Conclusion: Although hair transplantation is generally safe, procedural stress, pain, anxiety, and sympathetic activation may trigger acute coronary events. Most reported cases involve older patients or those with cardiovascular risk factors; however, our patient was young and otherwise healthy.Significant RCA and LAD stenosis suggests previously unrecognized subclinical atherosclerosis. Early recognition and rapid intervention were crucial for successful reperfusion.Acute myocardial infarction may occur even in young, low-risk patients during cosmetic procedures. Prompt diagnosis, rapid referral, and timely PCI are essential for favorable outcomes. Clinicians should remain vigilant for cardiac symptoms during such procedures.

Keywords: Hair transplantation, Myocardial infarction, Percutaneous coronary intervention (PCI)

Ref No: 7060

A RETROSPECTİVE ANALYSİS OF PEDİATRİC VERTEBRAL INJURİES PRESENTİNG TO A TERTİARY EMERGENCY DEPARTMENT

Bilgehan Demir[1]

[1]Malatya Turgut Özal Üniversitesi

Bilgehan Demir / Malatya Turgut Özal Üniversitesi

Introduction and Purpose: Objective: This study aims to examine the effect of injury mechanism and localization on biochemical parameters, systemic stress response, and clinical outcomes in pediatric patients with vertebral fractures.

Materials and Methods: Materials and Methods: This retrospective study included 18 pediatric patients (aged 0-18 years) with radiologically confirmed vertebral fractures who presented to the emergency department between 2021 and 2026. Demographic data, injury mechanisms (fall, traffic accident), vertebral localizations (cervical, thoracic, lumbar, sacral), hospitalization times, and baseline laboratory parameters were analyzed.

Results and Conclusion: Results: Of the 18 patients included in the study, 9 (50%) were male. The most common mechanism of injury was falling (66.6%). Injury localizations were cervical in 4 patients, thoracic in 6, lumbar in 6, and sacral in 2 patients. The median duration of both hospital and intensive care unit stay was 1 day. A statistically significant relationship was found between injury localization and serum urea levels (p=0.017). Urea levels in cases with lumbar fractures were significantly lower than in those with cervical (p=0.002) and thoracic (p=0.032) fractures.Conclusion: Falls are the most frequent cause of pediatric vertebral fractures and are generally associated with a stable clinical course and short hospital stays. The significant increase in serum urea levels in higher-level injuries (cervical and thoracic) reveals the determining effect of anatomic location on metabolic catabolism. Therefore, careful biochemical monitoring is essential in the clinical management of pediatric cases with upper-level spinal injuries.

Table 1. Demographic Characteristics and Baseline Laboratory Parameters of Pediatric Cases with Vertebral Injuries

Table 1. Demographic Characteristics and Baseline Laboratory Parameters of Pediatric Cases with Vertebral Injuries

	n	mean	±sd		n	median	IQR(25-75)

wbc	18	12,3	5,9	lymphocyte	18	2,38	1,86-3,17
hb	18	13,7	1,8	lar	18	0,56	0,39-0,7
hct	18	40,9	5,5	glucose	18	102	94,5-130,5
urea	18	30,5	9,5	ast	18	35	22-40
creatinin	18	0,71	0,14	alt	18	17,5	14-22,2
albumin	18	4,4	0,5	age	18	14	9,75-16
				h-los	18	0,5	0-4,25
				icu-los	18	0	0-2

Data are presented as mean ± standard deviation (SD) for normally distributed variables, and as median (interquartile range [IQR]: 25th-75th percentiles) for non-normally distributed variables.

WBC: White Blood Cell count (10^3/µL), Hb: Hemoglobin, Hct: Hematocrit, LAR: Lymphocyte-to-Albumin Ratio, AST: Aspartate Aminotransferase, ALT: Alanine Aminotransferase, ICU-los: Intensive Care Unit length of stay (days), h-los: hospital lenght of stay, n: Number of cases.

Keywords: Biomarkers, Pediatric Trauma, Vertebral Fractures

Ref No: 7157

Bullous Pemphigoid Mimicking Diabetic Foot Infection

Nevzat HERGÜL[1], Mehmet Hüseyin Feyzullah EREN[1], Sevdegül KARADAŞ[1], Gizem GİZLİ TAN[1]
[1]Van Yuzuncu Yil University Faculty of Medicine

Mehmet Hüseyin Feyzullah EREN / Van Yuzuncu Yil University Faculty of Medicine

Introduction and Purpose: Bullous pemphigoid (BP) is an autoimmune subepidermal blistering disease that primarily affects elderly individuals. Because its clinical presentation may resemble infectious or vascular disorders, diagnosis can be challenging in the emergency setting. In diabetic patients, bullous and erosive lesions of the feet may be misinterpreted as diabetic foot infection, which may result in inappropriate treatment or unnecessary surgical intervention. The aim of this case is to emphasize that BP should be considered in the differential diagnosis of elderly patients presenting with bullae, skin desquamation, and painful foot lesions.

Materials and Methods: A 79-year-old woman presented to the emergency department with a one-week history of painful wounds, bullae, and widespread skin desquamation on both feet (Figure 1). Her medical history included chronic obstructive pulmonary disease, diabetes mellitus, and hypertension. She had been referred from an external center to orthopedics with a preliminary diagnosis of diabetic foot infection and possible amputation.Detailed examination in the emergency department revealed similar lesions on the hands (Figure 2) and trunk (Figure 3). Peripheral pulses were palpable in all extremities. Doppler ultrasonography performed at the external center demonstrated normal arterial circulation and no evidence of deep vein thrombosis. The patient reported that the lesions had initially appeared as fluid-filled bullae and subsequently ruptured. Laboratory findings are summarized in Table 1. Because of the atypical lesion distribution, dermatology consultation was requested. The presence of tense bullae and widespread involvement raised suspicion for BP. The patient was admitted to the dermatology service, and skin biopsy with direct immunofluorescence confirmed the diagnosis.



Figure 1

Clinical appearance of the foot at initial presentation



Figure 2

Similar bullous lesions and desquamation on the dorsal aspect of the hand



Figure 3

Dried bullae on the trunk

Table 1

Parameter	Result	Reference Range
Blood glucose	330mg/dL	70-110 mg/dL
White blood cell count	8.4 x $10^3/\mu L$	4.0-10.0 x $10^3/\mu L$
Hemoglobin	14.9 g/dL	11.0-17.0 g/dL
C-reactive protein	271 mg/L	<5 mg/L

Laboratory values at initial presentation

Results and Conclusion: BP is an autoimmune blistering disorder characterized by tense bullae, erosions, and desquamation, most commonly involving the extremities and trunk. In elderly diabetic patients, prominent foot lesions may mimic diabetic foot infection and lead to misdiagnosis. In this case, widespread lesion distribution, preserved peripheral circulation, and the history of bullae preceding rupture were key clues against an isolated infectious process.BP should be considered in elderly patients presenting with extensive bullae and desquamation, especially when lesions extend beyond the feet. Early recognition is crucial to avoid unnecessary invasive procedures, including amputation, and to ensure appropriate dermatologic management.

Keywords: Misdiagnosis, Bullous Pemphigoid, Diabetic Foot

Ref No: 7165

A rare effect of calendula officınalıs tea: obstructıve jaundıce

Hasan Yıldız[1], Demet Acar[1], Naim Hikmet Kalkan[1], Osman Lütfi Demirci[1], Mehmet Gül[1]

[1]Emergency Medicine Department, Konya City Hospital,Turkiye

Hasan Yıldız / Emergency Medicine Department, Konya City Hospital,Turkiye

Introduction and Purpose: Introduction:Jaundice is an alarm symptom that must always be urgently evaluated and treated, whether encountered in primary care or in the emergency department. Differential diagnoses can be significantly narrowed (hepatocellular, cholestatic, etc.), and careful history taking, clinical examination, and basic laboratory tests may provide important clues regarding the etiology. Due to life-threatening differential diagnoses and complications, exclusion of cholestatic causes is essential.However, medical conditions such as drug- or herbal productinduced acute liver failure may also occur. Rapid intervention in appropriate cases is crucial for both short- and long-term prognosis.

Materials and Methods: Case:The patient had undergone deep brain stimulation surgery for Parkinson's disease four months earlier at Istanbul Medipol University. Although Parkinson-related symptoms had improved, the patient had been experiencing abdominal distension and persistent abdominal pain for the past two months. Previous evaluations at an external medical center did not yield a definitive diagnosis. Upon persistence of symptoms, the patient was advised by relatives to consume Calendula officinalis tea. The patient began drinking the tea nine days prior to admission and developed jaundice five days after initiation. The patient presented to Karaman State Hospital Emergency Department and was referred to our hospital with a preliminary diagnosis of obstructive jaundice and toxic hepatitis. After evaluation and imaging studies at our hospital, the patient was admitted to the intensive care unit under the preliminary diagnosis of obstructive jaundice by the Gastroenterology Department.

Results and Conclusion: Conclusion:When using herbal products for treatment, patients must strictly use them under physician supervision and avoid exceeding recommended doses. Otherwise, herbal products may cause liver injury leading to jaundice, complicate the differential diagnosis of obstructive jaundice, exacerbate the severity of the existing condition, and may even result in death.

Keywords: Obstructive Jaundice, Toxic Hepatitis, Herbal Tea

Ref No: 7167

Ending the "cardiopulmonary ping-pong": a case of HFpEF-induced acute right heart failure

Emrullah Atçı[1], Fatih Cemal Tekin[1], Mithat Furkan Toruk[1], Resul Yollar[1], Mehmet Gül[1]

[1]Emergency Medicine Department, Konya City Hospital, Türkiye

Resul Yollar / Emergency Medicine Department, Konya City Hospital, Türkiye

Introduction and Purpose: The management of geriatric patients presenting to the emergency department with acute dyspnea is one of the challenging areas of emergency medicine practice. Particularly in cases where the findings of acute heart failure and respiratory tract pathologies intertwine, and the left ventricular ejection fraction (LVEF) is preserved, patients often bounce between cardiology and pulmonology departments, a situation that clinically devolves into a "cardiopulmonary ping-pong" process.

Materials and Methods: A 79-year-old female patient with a known history of hypertension presented to the emergency department with complaints of bilateral leg swelling and severe dyspnea. Upon presentation, her blood pressure was 170/100 mmHg, and oxygen saturation was 60% on room air. Although her LVEF was measured at 60% on echocardiography, her NT-proBNP level was 5500 pg/mL, pulmonary artery pressure (PAP) was 96 mmHg, and marked dilation of the right heart chambers was observed. Laboratory tests revealed ALT and AST levels reaching 2000 U/L, indicating severe cardiac hepatopathy secondary to acute right heart failure. Following multidisciplinary evaluations, the patient, who remained in a clinical limbo, was admitted to the Coronary Care Unit (CCU) under the initiative of the emergency medicine specialist.

Results and Conclusion: Preserved LVEF can mislead clinicians into assuming that the primary problem is non-cardiac. However, excessively high NT-proBNP levels, massively elevated liver enzymes, and massive right heart strain on echocardiography provide definitive evidence of primary cardiovascular decompensation and end-organ damage. A holistic clinical, laboratory, and radiological evaluation is of vital importance in cases of interdisciplinary disagreements. A normal LVEF does not rule out severe right heart decompensation, which can lead to fatal consequences.

Keywords: Acute heart failure, Emergency medicine, Cor pulmonale

Ref No: 7198

Cerebral malperfusion and extremity ischemia resulting from type 1 aortic dissection: a case report

Emirhan Ünlü[1], Yavuz Yılmaz[1], Hakkı Yüce[1], Mehmet Kasa[1], Mehmet Gül[1]

[1]Emergency Medicine Department, Konya City Hospital, Türkiye

Emirhan Ünlü / Emergency Medicine Department, Konya City Hospital, Türkiye

Introduction and Purpose: Acute aortic dissection (AD) is a surgical emergency characterized by high mortality and a wide spectrum of clinical presentations. Diagnostic delays often occur in cases where neurological symptoms predominate. This report aims to manage a Type 1 AD case presenting with syncope and stroke-like symptoms following chest pain from an emergency medicine perspective.

Materials and Methods: A 72-year-old female patient with a known history of hypertension (HT) was brought to the emergency department following syncope preceded by a sudden onset of chest and back pain. Upon awakening, a speech disorder and 4/5 motor strength loss in the left arm were detected. Due to the inability to manually palpate bilateral femoral pulses during physical examination, further investigation for AD was initiated. Brain MRI revealed acute infarcts in the cerebellum and occipital regions. Computed Tomography (CT) angiography identified a Type 1 AD involving the aortic arch and the carotid artery, which was found to be completely occluded. The patient was scheduled for an emergency operation by the Department of Cardiovascular Surgery (CVS).

Results and Conclusion: Approximately 5-10% of AD cases present with neurological deficits. In patients presenting with syncope and stroke, vascular examination and pulse control are vital to prevent the omission of aortic pathologies. The coexistence of femoral pulse loss and neurological findings serves as a potent clinical red flag for the diagnosis of dissection.

Keywords: Aortic dissection, Ischemic stroke, Malperfusion syndrome

Ref No: 7217

Temporal Changes and Clinical Significance of Monocyte Levels in Geriatric Patients with Urosepsis

Furkan Korkmaz[1], Ayşe Yılkınç Tekirdaş[2]

[1]Malatya Turgut Özal Üniversitesi
[2]Malatya Eğitim Araştırma Hastanesi

Furkan Korkmaz / Malatya Turgut Özal Üniversitesi

Introduction and Purpose: Urosepsis is a serious clinical condition associated with high morbidity and mortality, particularly in geriatric patients. Although various biomarkers are used to evaluate the inflammatory response during sepsis, the temporal changes in monocyte levels have not been sufficiently elucidated. In this study, we aimed to evaluate the changes in monocyte levels over time in geriatric patients with urosepsis.

Materials and Methods: This retrospective observational study included a total of 63 patients aged 65 years and older who were diagnosed with urosepsis in the emergency department or intensive care unit within the last year. Demographic data and laboratory parameters were obtained from the hospital information management system. Monocyte levels were measured at two different time points and recorded in $\times 10^9$/L units. Statistical analyses were performed using IBM SPSS version 27.0. The distribution of continuous variables was assessed using the Kolmogorov–Smirnov test, and the relationship between the two measurements was analyzed using Pearson or Spearman correlation analysis.

Results and Conclusion: Results:Of the patients included in the study, 50.8% were female, and the mean age was 74 ± 3 years. The mean monocyte level was 0.4832 ± 0.2949 $\times 10^9$/L at the first measurement and 0.6268 ± 0.3710 $\times 10^9$/L at the second measurement. These findings indicate an increasing trend in monocyte levels during follow-up. Correlation analysis revealed a statistically significant and positive relationship between the two measurements ($r = 0.316$, $p < 0.001$).Conclusion:Monocyte levels increase over time in geriatric patients with urosepsis. Dynamic monitoring of monocyte levels may serve as a potential biomarker in the assessment of inflammatory response and clinical follow-up.

Keywords: Urosepsis, Monocyte, Geriatric patient

Ref No: 7232

Recurrent Cardiac Arrest with Prolonged QT Interval in the Postpartum Period Following Cesarean Section: A Case Report

Elif Yeşim Gündaş[1], Şevval Ayan[1], İsa Yıldırım[1], Selçuk Eren Çanakçı[1], Ayhan Aköz[1], Ahmet Melih Savaş[1]
[1]Department of Emergency Medicine, Faculty of Medicine, Aydın Adnan Menderes University, Aydın, Turkey
İsa Yıldırım / Department of Emergency Medicine, Faculty of Medicine, Aydın Adnan Menderes University, Aydın, Turkey

Introduction and Purpose: Cardiac arrest in the postpartum period is rare but associated with high mortality. While pulmonary embolism and peripartum cardiomyopathy are the most common causes, arrhythmogenic channelopathies should not be overlooked. Determining the underlying etiology is particularly challenging in cases without shockable rhythms. We aimed to present a case of recurrent cardiac arrest associated with prolonged QT interval in the early postpartum period.

Materials and Methods: A 21-year-old woman developed sudden loss of consciousness at home shortly after cesarean section. Emergency medical services initiated cardiopulmonary resuscitation (CPR), and return of spontaneous circulation (ROSC) was achieved after 15 minutes. No ventricular tachycardia or fibrillation was documented. The patient was intubated and admitted to the intensive care unit. After extubation on day three, she was transferred to a monitored ward. On the fifth day, a second cardiac arrest occurred; ROSC was achieved after 6 minutes, and she was referred to our center.Upon admission, the patient was intubated (GCS: E3M5Vt). Bedside echocardiography showed preserved ejection fraction (65%) with septal hypokinesia and no pericardial effusion. Electrocardiography demonstrated sinus rhythm with a prolonged QT interval. Laboratory findings included elevated troponin (340 ng/L), D-dimer (25,105 ng/mL), and CRP (77.5 mg/L). Venous Doppler ultrasonography revealed no deep vein thrombosis. Thoracic computed tomography demonstrated consolidation consistent with pneumonia. Magnesium and amiodarone therapy were initiated with a preliminary diagnosis of long QT syndrome, and the patient was transferred to cardiology.

Results and Conclusion: In postpartum patients with recurrent cardiac arrest and preserved ventricular function, arrhythmogenic causes should be strongly considered. Prolonged QT interval is a well-known risk factor for life-threatening arrhythmias such as torsades de pointes. Systemic inflammation due to concurrent pneumonia and hormonal changes in the postpartum period may further predispose to QT prolongation. Long QT syndrome should be included in the differential diagnosis of unexplained recurrent cardiac arrest in the postpartum period. Early recognition and multidisciplinary management are essential to improve outcomes.

Keywords: Long QT syndrome, Postpartum cardiac arrest, Torsades de pointes

---

Ref No: 7272

Is halp score superior to traditional inflammatory markers in predicting outcomes in ileus patients?

Yavuz Celik[1], Ayse Isik Guven[1], Basar Cander[1], Bahadir Taslidere[1]

[1]Bezmialem Vakıf University

Yavuz Celik / Bezmialem Vakıf University

Introduction and Purpose: Inflammatory markers such as neutrophil-to-lymphocyte ratio (NLR) are widely used in emergency settings but may not fully capture the complexity of disease severity. In ileus, both systemic inflammation and nutritional status contribute to clinical outcomes. The hemoglobin, albumin, lymphocyte, and platelet (HALP) score integrates these parameters into a single index. This study aimed to compare the predictive value of HALP score and NLR in patients presenting with ileus.

Materials and Methods: This retrospective study included 216 adult patients diagnosed with ileus. HALP score and neutrophil-to-lymphocyte ratio (NLR) were calculated from initial laboratory values. Their relationships with clinical outcomes, including surgical intervention, malignancy, and length of hospital stay, were analyzed. Correlation analysis between HALP score and NLR was performed.

Results and Conclusion: A strong negative correlation was found between HALP score and NLR ($p < 0.001$), indicating that both markers reflect inflammatory burden from different perspectives. However, lower HALP scores were more consistently associated with clinically relevant outcomes, including increased need for surgical intervention and longer hospital stay. Unlike NLR, HALP score incorporates both inflammatory and nutritional components, providing a broader representation of patient status. This combined approach may offer an advantage in early clinical assessment. HALP score may therefore serve as a more comprehensive biomarker in the evaluation of ileus patients in the emergency department.

Keywords: HALP score, NLR, biomarkers

Ref No: 7331

Detection of ovarian torsion with computed tomography in a patient with a preliminary diagnosis of acute abdomen

Rabia ÇELİKÖZ[1], Mehmet SOYUGÜZEL[2], Mustafa Cihat ÇELİKÖZ[3]

[1]Department of Radiology, Afyonkarahisar State Hospital, Afyonkarahisar, Türkiye
[2]Department of Emergency Medicine, Afyonkarahisar Health Sciences University, Afyonkarahisar, Türkiye
[3]Department of Family Medicine, Afyonkarahisar Health Sciences University, Afyonkarahisar, Türkiye

Mehmet SOYUGÜZEL / Department of Emergency Medicine, Afyonkarahisar Health Sciences University, Afyonkarahisar, Türkiye

Introduction and Purpose: Ovarian torsion is a serious gynecological emergency involving partial or complete rotation of the ovary around its vascular pedicle. Delayed diagnosis may lead to ischemia and ovarian loss. Due to non-specific symptoms, diagnosis is often clinically challenging. Although doppler ultrasonography (USG) is the primary imaging modality, computed tomography (CT) is frequently performed first for differential diagnosis in acute abdomen. While CT lacks pathognomonic findings, increased ovarian size, associated masses, peripheral follicle displacement, and vascular malrotation are key diagnostic indicators.

Materials and Methods: A 14-year-old female presented with sudden, severe right lower quadrant pain, vomiting, and lack of bowel output. Symptoms were unrelated to her menstrual cycle. Physical examination revealed a soft abdomen without defence and rebound. Laboratory results were normal. Following an unresponsive enema for colonic gas distension seen on radiography, contrast-enhanced CT was performed to exclude acute pathologies. In the contrast-enhanced CT, an increase in the size of the right ovary and peripheral displacement of the follicles were observed (Figure 1). Due to suspected ovarian torsion, pelvic Doppler USG was performed. On USG, the right ovarian parenchyma appeared edematous, containing a central cystic area 55 mm in diameter, with the follicles displaced to the periphery. On Doppler ultrasound, flow was only detected at the periphery and was high-resistant. The patient, diagnosed with ovarian torsion, was consulted with the Department of gynecology for emergency surgical planning.

Figure 1

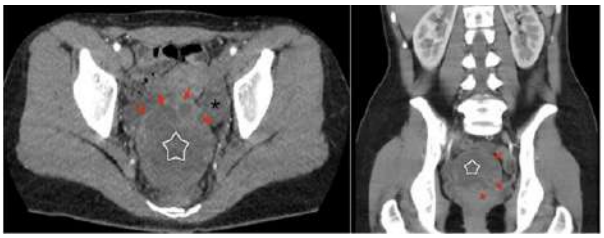

Axial (left) and coronal (right) CT images. Enlarged right ovary (white star). Peripherally displaced follicles in the right ovary (red arrows). Normal left ovary (black asterisk)

Results and Conclusion: Ovarian torsion must be considered in the differential diagnosis of pediatric and adult females with acute abdominal pain. CT is critical for excluding other causes and identifying secondary signs of torsion in uncertain cases. Prompt radiological detection is vital for timely surgical intervention, preserving ovarian reserve, and preventing necrosis.

Keywords: Acute abdomen, CT, Ovarian torsion

Ref No: 7332

Sore throat and critical multi-vessel disease masked by supraventricular tachycardia: A case report

Muhammed Feyizoğlu[1], İlknur Şahin[1], Muhammet Gökhan Turtay[1], Ahmet Çağlar[1], Birsen Ertekin[1], Şükran Rabia Yılmaz[1]

[1]University of Health Sciences, Beyhekim Training and Research Hospital, Clinic of Emergency Medicine, Konya, Türkiye.

Muhammet Gökhan Turtay / University of Health Sciences, Beyhekim Training and Research Hospital, Clinic of Emergency Medicine, Konya, Türkiye.

Introduction and Purpose: In this case report, we describe the management of a rare presentation in which a patient with symptoms suggestive of an upper respiratory tract infection and supraventricular tachycardia was ultimately found to have critical multivessel coronary artery disease.

Materials and Methods: A 59-year-old man with no known comorbidities and a 17-year history of non-smoking presented to the emergency department with a three-day history of sore throat, fatigue, cough, and generalised body aches. On initial examination, the patient had no active chest pain or fever; however, his vital signs revealed a heart rate of 180 beats per minute. Electrocardiography demonstrated supraventricular tachycardia. Following intravenous administration of diltiazem, the heart rate decreased to 83 beats per minute and normal sinus rhythm was restored. Laboratory investigations revealed that the initial troponin I level of 24.40 ng/L increased markedly to 1653.31 ng/L during follow-up. Additional laboratory results included a creatinine level of 1.5 mg/dL, lactate dehydrogenase of 631 IU/L, creatine kinase of 293 U/L, and C-reactive protein of 65.01 mg/L. Posterior–anterior chest radiography demonstrated a non-homogeneous increase in density in the lower lung zones. Due to the significant elevation in cardiac enzymes, the patient was referred for coronary angiography with a diagnosis of non-ST-segment elevation myocardial infarction (NSTEMI). Coronary angiography revealed 95% stenosis of the proximal left anterior descending artery and sequential 90% stenoses in the proximal right coronary artery. The patient was subsequently referred for emergency coronary artery bypass graft surgery.

Results and Conclusion: In patients presenting to the emergency department with isolated sore throat, fatigue, or tachycardia, acute coronary syndromes should be considered in the differential diagnosis, particularly in the presence of cardiovascular risk factors. Atypical symptoms may create a diagnostic trap in high-risk patients and lead to delayed recognition of myocardial injury.

Keywords: Acute coronary syndrome, Sore throat, Supraventricular tachycardia

---

Ref No: 7333

A Rare Cause of Acute Dyspnea: Pneumomediastinum in a Patient with a History of Nasal Surgery

Ekim Sağlam Gürmen1, Sena Zeybek1

1Manisa Celal Bayar University School of Medicine, Emergency Department, Manisa, Turkey

Sena Zeybek / Manisa Celal Bayar University School of Medicine, Emergency Department, Manisa, Turkey

Introduction and Purpose: Pneumomediastinum is a rare condition defined by the presence of free air within the mediastinum and may lead to serious complications if not properly evaluated (1). It is classified as spontaneous or secondary.The most accepted mechanism in spontaneous pneumomediastinum is the "Macklin effect," in which alveolar rupture allows air to dissect along bronchovascular sheaths into the mediastinum (2,3). This process is typically triggered by increased intrathoracic pressure due to coughing, asthma exacerbation, or Valsalva maneuvers.Secondary pneumomediastinum may occur after trauma, mechanical ventilation, esophageal perforation, or surgical procedures (2,4). Although rare, cases following head and neck surgery have been reported, possibly due to air spreading along fascial planes into the mediastinum (4,5).Here, we present a case of pneumomediastinum in a young patient with a history of nasal surgery.

Materials and Methods: A 24-year-old man presented to the emergency department with sudden-onset dyspnea. He reported intermittent dyspnea and productive cough over the previous months, partially relieved by bronchodilators. His history included septorhinoplasty three months earlier and a six pack-year smoking history.On admission, SpO_2 was 85% on room air, heart rate 130 beats/min, blood pressure 115/45 mmHg, and temperature 36.5°C. Lung examination revealed bilateral rhonchi and wheezing. Arterial blood gas analysis showed mild respiratory alkalosis and hypoxemia (pH 7.46, pO_2 50 mmHg). C-reactive protein was 53 mg/L, and electrocardiography demonstrated normal sinus rhythm.Chest radiography was unremarkable. Thoracic CT angiography, performed to exclude pulmonary embolism, revealed no embolism but demonstrated air densities consistent with pneumomediastinum surrounding the left subclavian artery and aortic arch.The patient was evaluated by pulmonology and thoracic surgery and admitted for observation. Oxygen therapy, bronchodilators, and systemic corticosteroids were initiated.

Results and Conclusion: Pneumomediastinum is more common in young males and usually has a benign course; however, serious conditions such as esophageal perforation and pulmonary embolism must be excluded (2,5). Chest radiography may be normal, whereas thoracic CT is more sensitive (2,3,5).In this case, the three-month interval after surgery and the presence of airway symptoms suggest spontaneous pneumomediastinum related to airway hyperreactivity rather than a direct surgical complication.Pneumomediastinum should be considered in young patients presenting with sudden dyspnea, even when chest radiography is normal.

Keywords: Macklin effect, Pneumomediastinum, Septorhinoplasty

Ref No: 7368

SURGICAL STABILIZATION OF RIB FRACTURES: A 3-CASE SERIES

Miktat Arif Haberal[1], Mustafa Tolga ÖZDAL[1], Melih YÜKSEL[1]

[1]Bursa Yüksek İhtisas Eğitim ve Araştırma Hastanesi

Mustafa Tolga ÖZDAL / Bursa Yüksek İhtisas Eğitim ve Araştırma Hastanesi

Introduction and Purpose: Blunt thoracic trauma frequently results in rib fractures, which, particularly in cases of multiple fractures or flail chest, are associated with severe respiratory failure, prolonged mechanical ventilation, and increased mortality. While traditional treatment relies on conservative approaches, Surgical Stabilization of Rib Fractures (SSRF) is increasingly recommended to reduce ventilation duration, intensive care unit stays, and pulmonary complications. This study aims to present the clinical characteristics, surgical indications, and early outcomes of patients who underwent chest wall stabilization due to rib fractures resulting from blunt thoracic trauma

Materials and Methods: This case series evaluates three male patients (aged 42, 45, and 55 years) who presented to the emergency department following blunt thoracic trauma, such as falls and workplace injuries. Clinical and radiological evaluations revealed localized tenderness, dyspnea, multiple displaced rib fractures, significant chest wall deformity, and flail chest characterized by paradoxical respiratory movements. Due to deteriorating respiratory function and chest wall instability, surgical stabilization was indicated. Under general anesthesia, anatomic reduction was achieved, and the fractured rib segments were fixed using titanium plate-and-screw systems at the targeted levels.

Results and Conclusion: Postoperatively, all patients experienced restored chest wall stability and significant improvements in their respiratory parameters. Effective and rapid pain control was achieved, highlighted by a notable reduction in pain scores. All three patients had an uneventful clinical course with no reported complications and were subsequently discharged in stable and good condition.In cases of multiple rib fractures and flail chest resulting from blunt thoracic trauma, SSRF is a safe and effective treatment modality when appropriate patient selection is applied. In the presence of chest wall instability and displaced fractures, surgical stabilization serves as a superior alternative to conservative management by ensuring rapid early pain control, significantly improving respiratory function, enhancing patient comfort, and accelerating functional recovery without complications.



Figure 1



Figure 2



Figure 3

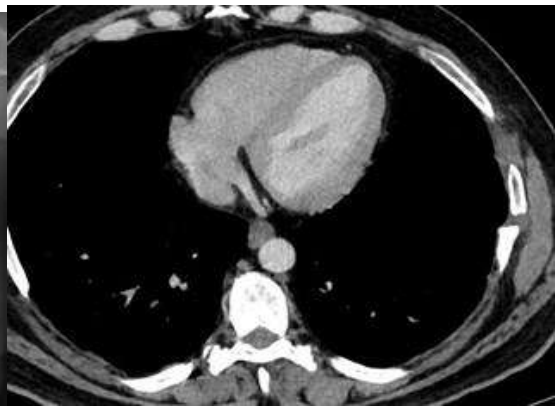

Figure 4

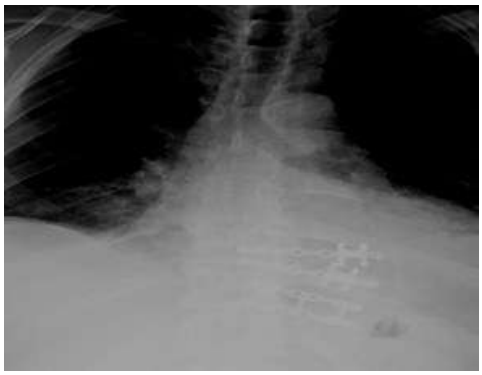

Figure 5

Keywords: Rib Fractures, Flail Chest, Pain Management

Ref No: 7448

Cardiometabolic Indices as Predictors of Adverse Outcomes in Patients with Diabetic Ketoacidosis and Hyperosmolar Hyperglycemic State: A Retrospective Cohort Study

Mete Ucdal[1], Evren Ekingen[1]

[1]Etimesgut Sehit Sait Erturk State Hospital

Evren Ekingen / Etimesgut Sehit Sait Erturk State Hospital

Introduction and Purpose: Diabetic ketoacidosis (DKA) and hyperosmolar hyperglycemic state (HHS) are life-threatening hyperglycemic emergencies associated with considerable morbidity, recurrent emergency department (ED) utilization, and intensive care unit (ICU) resource burden. Insulin resistance and atherogenic dyslipidemia are increasingly recognized as contributors to adverse outcomes in acute metabolic crises. Novel cardiometabolic indices—the triglyceride-glucose index (TyG), TyG-body mass index (TyG-BMI), atherogenic index of plasma (AIP), metabolic score for insulin resistance (METS-IR), and triglyceride-to-HDL-cholesterol ratio (TG/HDL-C)—have shown prognostic value in various critically ill populations; however, their predictive role specifically in hyperglycemic emergencies remains unexplored.

Materials and Methods: This single-center retrospective cohort study enrolled 190 consecutive adult patients (112 DKA, 78 HHS) admitted to the emergency department of a tertiary hospital between January 2021 and December 2025. Five cardiometabolic indices were calculated from admission laboratory values. Primary endpoints were ICU admission and 30-day repeat ED visit. Multivariable logistic regression adjusted for age, sex, Charlson Comorbidity Index, glycated hemoglobin, creatinine, and lactate was performed. Discriminative performance was evaluated by receiver operating characteristic (ROC) analysis with DeLong comparisons.

Results and Conclusion: Among 190 patients (median age 58 years; 52.1% male), ICU admission occurred in 67 (35.3%) and 30-day repeat ED visit in 49 (25.8%). METS-IR showed the strongest association with ICU admission (adjusted odds ratio [aOR] 2.74; 95% CI, 1.68–4.47; $P < 0.001$), followed by TyG-BMI (aOR 2.31; 95% CI, 1.44–3.71; $P < 0.001$), TyG (aOR 1.89; 95% CI, 1.22–2.93; $P = 0.004$), AIP (aOR 1.71; 95% CI, 1.12–2.62; $P = 0.013$), and TG/HDL-C (aOR 1.54; 95% CI, 1.03–2.31; $P = 0.037$). ROC analysis revealed the highest area under the curve for METS-IR (AUC 0.847; 95% CI, 0.790–0.904; sensitivity 82.1%, specificity 74.8%, cut-off 52.3), followed by TyG-BMI (AUC 0.821), TyG (AUC 0.793), AIP (AUC 0.768), and TG/HDL-C (AUC 0.741). METS-IR was significantly superior to TG/HDL-C (DeLong $P = 0.008$) and AIP ($P = 0.031$). For 30-day repeat ED visit, METS-IR (AUC 0.782) and TyG-BMI (AUC 0.759) remained the strongest predictors. Subgroup analysis showed higher discriminative accuracy in HHS than DKA. In conclusion, METS-IR and TyG-BMI, as readily

calculable non-insulin-based surrogate markers, may serve as practical bedside tools for early risk stratification in hyperglycemic emergencies.

ROC curves of cardiometabolic indices for ICU admission in DKA and HHS patients (n = 190).

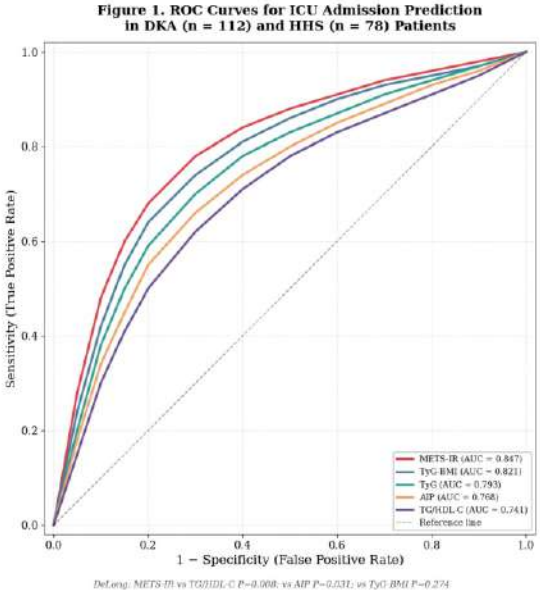

Keywords: diabetic ketoacidosis; cardiometabolic indices; METS-IR

Ref No: 7510

Evaluation of Demographic and Haematological Parameters and the Role of Systemic Inflammatory Response Index (SIRI) in Patients with Acute Pancreatitis

Zeynep Keser[1]

[1]Malatya Turgut Özal University, Faculty of Medicine, Department of Emergency Medicine,

Zeynep Keser / Malatya Turgut Özal University, Faculty of Medicine, Department of Emergency Medicine,

Introduction and Purpose: Acute pancreatitis is a disease characterised by the sudden onset of inflammation of the pancreas, with a clinical course ranging from mild inflammation to severe systemic complications. In recent years, haematological parameters obtained from complete

blood counts have garnered attention as potential biomarkers for evaluating inflammation.This study aimed to evaluate the demographic characteristics and laboratory parameters of patients diagnosed with acute pancreatitis, to examine the relationships between these parameters and gender, and to investigate the possible role of the Systemic Inflammatory Response Index (SIRI), calculated using neutrophil, monocyte, and lymphocyte values, in the inflammatory process.

Materials and Methods: This retrospective study examined patients who presented to the emergency department and were diagnosed with acute pancreatitis. Demographic characteristics and laboratory parameters of the patients were evaluated, and comparisons were made between genders. Additionally, SIRI was calculated using the values of neutrophils, monocytes, and lymphocytes.

Results and Conclusion: In conclusion, this study evaluated demographic characteristics and laboratory parameters in patients diagnosed with acute pancreatitis. In our study, no significant difference was found between genders in terms of most hematological and biochemical parameters.Only haemoglobin levels showed a significant difference.Haemoglobin levels were found to be lower in female patients compared to male patients.This is thought to be related to physiological gender differences. In addition, SIRI values calculated using neutrophil, monocyte, and lymphocyte values obtained from complete blood count appear to be a potential biomarker in evaluating the inflammatory process. However, due to the limited number of patients, further studies in larger patient groups are needed to more clearly reveal the relationship of these parameters with the clinical course and prognosis of acute pancreatitis.

Table2. Relationship between gender and blood parameters.

Table 2: Relationship between gender and blood parameters.

Parameter	Female(mean)	Male (mean)	p value
CRP	21.62	26.53	0.778
Albumin	36.09	38.43	0.408
Neutrophil	9.12	8.89	0.925
Amylase	1472.09	1072.14	0.443
Lipase	489.82	471.43	0.863
Lymphocyte	1.33	1.39	0.881
Platelet	296.45	224.57	0.060
Hemoglobin	**11.79**	**14.14**	**0.017**
Monocyte	0.79	0.71	0.633

Table2. Relationship between gender and blood parameters.

Keywords: Pancreatitis, Systemic inflammatory response index (SIRI), Haematological parameters

Ref No: 7558

Investigation of Mean Arterial Pressure at Emergency Department Admission and Initial NIHSS Score in Acute Ischemic Stroke Patients

Ayşe Büşra Özcan[2], Bahadır Taşlıdere[1], Leyla İbrahim[1]

[1]Bezi-i Alem Vakıf Üniversitesi
[2]Beykoz Devlet Hastanesi

Ayşe Büşra Özcan / Beykoz Devlet Hastanesi

Introduction and Purpose: Mean arterial pressure (MAP) is a reliable indicator of organ perfusion, with a normal rangeof 70-100 mmHg. Adequate cerebral perfusion is vital in stroke patients. This study aimed to investigate therelationship between MAP levels at emergency department admission and initial stroke severity, as assessed bythe National Institutes of Health Stroke Scale (NIHSS), in patients with acute ischemic stroke.

Materials and Methods: This retrospective study included patients aged 18 years and older who presented to the emergencydepartment with acute ischemic stroke between January 1, 2022 and January 1, 2024. MAP and NIHSS scoreswere calculated on admission. Patients were divided into MAP groups and NIHSS scores were compared.Results: A total of 215 patients were evaluated. In the low MAP group (n=47), mean NIHSS was 12.6±4.9; inthe medium MAP group (n=111), 9.9±3.9; and in the high MAP group (n=57), 10.2±5.0. The overall meanNIHSS was 10.6±4.5. The difference between groups was statistically significant (p=0.001). Gender distributionshowed slightly higher rates of low MAP in females (25.3% vs. 19.2%) and higher rates of high MAP in males(27.5% vs. 25.3%), but this was not statistically significant ($p > 0.05$)

Results and Conclusion: Higher NIHSS scores in the low MAP group suggest that hypoperfusion may increase strokeseverity. The similarity of scores in the medium and high MAP groups indicates that MAP values above acertain threshold may not provide additional benefit. These findings suggest that low MAP at presentation isassociated with greater initial stroke severity, highlighting the importance of avoiding hypoperfusion duringearly stroke management.

Keywords: Stroke, mean arterial pressure, NIHSS

Ref No: 7571

A rare case: Postmenopausal ovarian torsion

Elif Yıldız[1], Onur Bozdağ[2], Naz Atila[3], Bahadır Taşlıdere[2], Başar Cander[2]

[1]Bezmialem Vakıf University, Medical Faculty.
[2]Bezmialem Vakıf University, Emergency Department.
[3]Bezmialem Vakıf University, Radiology Department.

Onur Bozdağ / Bezmialem Vakıf University, Emergency Department.

Introduction and Purpose: Ovarian torsion is a process that occurs when the ovary twists over the ligaments that support it in the adnexa . Most ovarian torsion occurs in the reproductive age group, and it is less common in premenarchal girls and postmenopausal women . Additionally, adnexal torsion develops in approximately 2–15% of women with a history of prior surgical intervention for adnexal masses or cysts .This report presents a rare case of adnexal torsion in a perimenopausal woman, emphasizing that torsion can occur at any age and that the presence of an ovarian cyst constitutes a significant predisposing factor regardless of age.

Materials and Methods: A 48-year-old female patient presented to our emergency department with an acute onset of pain in the lower abdominal quadrant of one-day duration, which was gradually progressive. She was diagnosed with an ovarian cyst three years ago. She was gravida 6, para 4, abortus 2. Her menstrual cycles were regular. Abdominal CT showed a 70×62 mm cyst originating from the left adnexa and located anterior to the uterus. Left ovarian stromal edema was present, with a mild increase in size and anterior displacement. The CT scan results were insufficient to explain the patient's pain. Therefore, symptomatic treatment was administered and the patient was placed under observation. Since the patient's pain did not improve with symptomatic treatment, a pelvic Doppler ultrasound was scheduled.Pelvic Doppler ultrasonography showed venous blood flow could not be detected in the left ovary, and its echogenicity was decreased. On abdominal MRI, stromal edema and decreased contrast enhancement were present in the left ovary, and the cyst was displaced anteriorly toward the midline. These findings were evaluated as ovarian torsion. The patient was referred to the gynecology and obstetrics clinic.

Results and Conclusion: Adnexial and ovarian torsions are rare gynecological emergencies that can happen at any age. Although they are more common in reproductive age than perimenopausal age, they should be considered in the differential diagnosis of acute lower abdominal pain in women, particularly in the presence of predisposing factors.

Keywords: Postmenopausal, Ovarian Torsion, Abdominal Pain

Ref No: 7582

Evaluation of occupational accidents presenting to a university hospital emergency department

Sultan Cennet Çakar[1], Şerife Özdinç[1], Mehmet Soyugüzel[1]
[1]Afyonkarahisar Health Sciences University Faculty of Medicine, Department of Emergency Medicine, Afyonkarahisar, Türkiye

Sultan Cennet Çakar / Afyonkarahisar Health Sciences University Faculty of Medicine, Department of Emergency Medicine, Afyonkarahisar, Türkiye

Introduction and Purpose: An occupational accident is defined as an event occurring in the workplace or during the execution of work that results in death or causes physical or psychological impairment. Occupational accidents are the third most common cause of injury and mortality after traffic and domestic accidents and are frequently encountered in emergency departments. This study aimed to evaluate trauma cases presenting to a university hospital emergency department due to occupational accidents.

Materials and Methods: All patients who presented to the emergency department of Afyonkarahisar Health Sciences University Faculty of Medicine between February 1 and February 28, 2026, due to occupational accidents were included in the study. The data were retrospectively obtained from medicolegal records. Sociodemographic distribution of the patients, mechanism and causes of the accidents, injured body regions, interventions and procedures performed in the emergency department, sectoral distribution of accidents, and outcomes were recorded. All data were analyzed using the SPSS statistical software. Descriptive statistics were used for data analysis.

Results and Conclusion: A total of 55 patients were included in the study. The median age of the patients was 32 years (range: 16–64), and the female-to-male ratio was 8/47. It was found that 31 (56.4%) patients presented between 08:00 and 16:00, 28 (50.9%) patients sustained blunt trauma, and 32 (58.2%) patients had extremity injuries.In 30 (54.5%) patients, treatments other than medication were performed in the emergency department. The most common diagnosis was soft tissue injury, including tendon and skin lacerations (36.4%). Additionally, 15 (27.3%) patients were hospitalized in the relevant departments.Occupational accidents may result in serious injuries, permanent disabilities, and even death. As demonstrated in this study, emergency department data can be used to define trauma patterns and workplace Increasing awareness, implementing preventive measures, and providing education may help reduce the incidence of occupational accidents.

Keywords: occupational accident, workplace, injury

Ref No: 7587

Spontaneous Pneumothorax Due To Hydatid Cyst's Pleural Enucleation: A Case Report

Ali Tayyip Kömürcü[1], Birsen Ertekin[1], Gürcan Koşal[2], Gökhan Yılmaz[1], Muhammet Gökhan Turtay[1], Feyza Sandal[1]

[1]University of Health Science Beyhekim Training and Research Hospital, Clinic of Emergency Medicine, Konya, Türkiye.
[2]University of Health Science Beyhekim Training and Research Hospital, Department of Thoracic Surgery, Konya, Türkiye.

Muhammet Gökhan Turtay / University of Health Science Beyhekim Training and Research Hospital, Clinic of Emergency Medicine, Konya, Türkiye.

Introduction and Purpose: In this case report, we reported; 34 years old male person who experienced, spontaneous pneumothorax due to hydatid cyst's pleural enucleation.

Materials and Methods: A 34-year-old man presented to our emergency department with one week history of dyspnea. Has no medical history. Physical examination of the patient who had no complaints other than dyspnea revealed the following: auscultation revealed that breath sounds in the right lung were less frequent than in the left. Other system examinations were normal. A plain chest X-ray revealed a pneumothorax on the right side. And consulted to thoracic surgery. Tube thoracostomy was performed in the emergency department with local anesthesia. Thoracic computed tomography scan of the patient revealed hydatid cysts in both the lung and liver. The patient, diagnosed with spontaneous pneumothorax developing from hydatid cysts, underwent surgery. During the operation, it was determined that the lesion had spontaneously enucleated into the pleural space, causing pneumothorax. The patient was discharged on the 10th day after the operation.

Figure 1. Chest X-ray at the time of admission to the emergency department.



Figure 2. Chest X-ray taken after tube thoracostomy.



Figure 3. Non-contrast thoracic computed tomography scan.

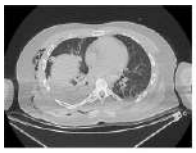

Figure 4. Thoracic magnetic resonance imaging.



Figure 5. Hydatid cyst lesion causing pneumothorax with enucleation into the pleural space.



Results and Conclusion: In secondary spontaneous pneumothorax, which is more common than primary spontaneous pneumothorax, identifying the underlying cause plays a crucial role in the early diagnosis and treatment of the patient. It should be kept in mind that pneumothorax due to hydatid cyst can cause secondary spontaneous pneumothorax.

Keywords: Emergency, Hydatid Cyst, Pneumothorax

Ref No: 7588

Optimal In-Hospital Location of Hyperbaric Oxygen Units Considering Disaster and Emergency Indications

Recep Özkan[1], İbrahim Özlü[2]

[1]Erzurum City Hospital
[2]Atatürk University

İbrahim Özlü / Atatürk University

Introduction and Purpose: Hyperbaric oxygen therapy (HBOT) is a time-critical treatment modality for several emergency conditions, including carbon monoxide poisoning, air embolism, decompression sickness, crush injuries, necrotizing infections, and acute traumatic ischemia.These patients are typically first evaluated and stabilized in emergency departments (EDs), where rapid access to definitive therapy is essential. In Türkiye, 57 HBOT centers operate across 28 provinces; however, the intra-hospital placement of these units has not been systematically planned according to emergency workflow and disaster response principles. This study aims to evaluate the current in-hospital location of HBOT units and discuss optimal placement strategies considering disaster and emergency indications.

Materials and Methods: A national descriptive review was conducted to evaluate the number, provincial distribution, and intra-hospital placement characteristics of hyperbaric oxygen therapy (HBOT) units in Türkiye. Data were obtained from publicly accessible institutional sources, including the official list of licensed HBOT centers published by the Republic of Türkiye Ministry of Health, institutional websites of public and private hospitals hosting HBOT units, and publicly available information from national hyperbaric medicine organizations where applicable. Hospital campus maps and satellite imagery (Google Maps) were used to assess the physical proximity of HBOT units to emergency departments. When publicly available information was insufficient to determine precise intra-hospital location, telephone confirmation was performed with hospital administrative staff or HBOT unit personnel to verify whether the unit was physically integrated within, directly adjacent to, or located separately from the emergency department. The study utilized exclusively publicly available institutional data and did not involve patient-level information; therefore, ethical approval was not required.

Results and Conclusion: Although 57 HBOT centers operate nationwide, available information suggests that only one unit is physically integrated within or directly adjacent to an emergency department. The majority of units are located in separate hospital blocks or independent facilities, requiring interdepartmental transfer after initial stabilization. In time-critical conditions and disaster scenarios, such separation may contribute to treatment delays and increase logistical

complexity, particularly for intubated or hemodynamically unstable patients. Considering the emergency-driven nature of many HBOT indications, hospital infrastructure planning should prioritize proximity to emergency departments to facilitate rapid therapy initiation, improve patient safety during transfer, and enhance multidisciplinary coordination.

Keywords: hyperbaric oxygen therapy, emergency department, hospital planning

---

Ref No: 7636

Evaluation of Clinical and Laboratory Findings in Pediatric Patients with Carbon Monoxide Poisoning: A Single-Center Retrospective Study

Özhan Özcan[1], Emre Baydede[1]

[1]Malatya Turgut Özal Üniversitesi

Özhan Özcan / Malatya Turgut Özal Üniversitesi

Introduction and Purpose: Carbon monoxide (CO) poisoning is a common and potentially life-threatening condition in the pediatric age group. This study aimed to evaluate the demographic, clinical, and laboratory characteristics of pediatric patients diagnosed with CO poisoning and to investigate the relationships between these parameters.

Materials and Methods: This single-center retrospective study included patients under 18 years of age diagnosed with CO poisoning between December 1, 2025, and March 1, 2026. Of 23 evaluated patients, 19 who met the inclusion criteria were analyzed. Demographic data, laboratory parameters, and clinical outcomes were recorded. Continuous variables were presented as mean ± standard deviation or median (IQR). Intergroup comparisons were performed using the Student's t-test and the Mann–Whitney U test. Correlation analyses were assessed using Spearman's correlation test.

Results and Conclusion: Results:Of the 19 patients included in the study, 68.4% were male. The mean age was 11 ± 5.23 years. All patients were discharged in good condition. The median COHb level was 16.3% (1.9–20.4), and the median hospital length of stay was 1.3 (1–2.7) days. No intensive care unit requirement was observed. A moderate positive correlation was found between COHb level and hospital length of stay ($r = 0.533$; $p = 0.019$). A moderate negative correlation was observed between albumin and COHb levels ($r = -0.514$; $p = 0.024$). Additionally, a moderate negative correlation was detected between age and lymphocyte count ($r = -0.475$; $p = 0.040$).Conclusion:Although pediatric carbon monoxide poisoning generally has a

favorable prognosis, certain laboratory parameters may provide additional information regarding clinical course. It is suggested that COHb level alone may not be sufficient, and parameters such as albumin may contribute to clinical evaluation.

Table 1. Mean and SD values of parametric variables

Variables	n	Mean	SD
Age (year)	19	11	5,23
Plt (10^3/uL)		282,47	79,68
Albumine(g/L)		44,13	2,89
Ph		7,39	0,031

Table 2. Median and IQR values of non-parametric variables

			IQR	
Variables	n	Median	25%	75%
Crp (mg/L)	19	0	0.Oca	3.Oca
Neu (10^3/uL)		4,34	3,18	6,36
Laktat		1,8	1,2	4,9
Lym (10^3/uL)		3,3	2,13	4,62
Hgb		12,9	12,2	14,2
Monocyte (×10³/µL)		0,6	0,5	0,81
Cohb		16,3	1,9	20,4
Pco2		41,5	38,6	44,4
Po2		19,4	7,9	48,6
Sat		62,8	43,1	88,5
Hospitalty		1,3	1	2,7
Intensive care		0	0	0

Keywords: Carbon monoxide poisoning, Pediatrics, Carboxyhemoglobin

Ref No: 7643

Heart Attack or Broken Heart?

Özge Güneş[1], Yeşim Işler[1], Halil Kaya[1], Melih Yüksel[1], Umut Ocak[1], Mehmet Oğuzhan Ay[1], Mevlüt Zengin[1]

[1]Department of Emergency Medicine, Bursa Yüksek İhtisas Training and Research Hospital, Bursa, Türkiye

Özge Güneş / Department of Emergency Medicine, Bursa Yüksek İhtisas Training and Research Hospital, Bursa, Türkiye

Introduction and Purpose: Introduction Takotsubo cardiomyopathy (TCM) is a transient left ventricular dysfunction triggered by emotional or physical stress. Patients present with chest pain. Acute coronary syndrome (ACS) is diagnosed based on electrocardiographic (ECG) ST segment changes and mild troponin elevation. This presentation describes a rare case of TCM in a patient who presented with typical chest pain and ST segment elevation in the postpartum period.

Materials and Methods: A 28-year-old female patient presented with severe, constricting chest pain radiating to her left arm and back, which had started one hour prior. She had a history of gestational hypertension and had undergone cesarean section (C/S) a few days prior. Vital signs: Blood pressure: 110/ 70 mmHg, Heart rate: 100 beats/minute, Respiratory rate: 18 breaths/minute, SpO2: 98 %. Cardiac and physical examination were normal. ECG showed ST segment elevation of more than 2 mm in derivations II, III, and aVF, and ST depression in aVL. Troponin T level was 13.9 ng/mL. The patient was referred to cardiology for emergency coronary angiography with a preliminary diagnosis of acute inferior myocardial infarction. Coronary angiography revealed normal coronary arteries with no obstructions.

Figure 1: ECG: ST segment elevation II, III, and aVF, and ST depression in aVL

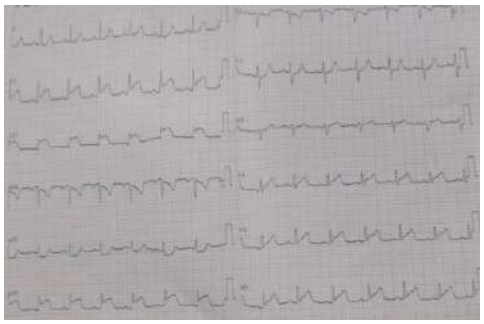

Results and Conclusion: TCM is frequently seen in postmenopausal women; however, it can also occur in younger patients in situations involving intense post-operative stress factors, such as the postpartum period. In this case, the diagnosis of TCM was made due to the patient's postpartum condition and the absence of coronary artery occlusion on angiography.Although patients presenting to the emergency department with chest pain and ST elevation on ECG are primarily evaluated for acute myocardial infarction, TCM should be considered in patients under physical and emotional stress with normal angiographic results. With early supportive treatment and follow-up of complications, the prognosis for these patients is generally good.

Keywords: takotsubo cardiomyopathy, broken heart syndrome, pseudo-infarction

---

Ref No: 7662

Performance of ChatGPT and Gemini Compared with Emergency Physicians in NSTEMI Cases: A Prospective Cross-sectional Study

Mustafa Yorgancıoğlu[1], Ekim Sağlam Gürmen[2], Seçkin Turan[2]

[1]İzmir Torbalı State Hospıtal, Emergency Department, İzmir, Turkey
[2]Manisa Celal Bayar University School of Medicine, Department of Emergency Medicine, Manisa, Türkiye

Seçkin Turan / Manisa Celal Bayar University School of Medicine, Department of Emergency Medicine, Manisa, Türkiye

Introduction and Purpose: Acute coronary syndromes remain a major cause of morbidity and mortality worldwide, and non-ST elevation myocardial infarction (NSTEMI) accounts for a substantial proportion of these cases (1). Diagnosing NSTEMI in emergency departments is challenging because of high patient volume, time pressure, and variable clinical presentation. Artificial intelligence (AI) systems based on large language models (LLMs), such as ChatGPT and Gemini, have recently emerged as potential clinical decision support tools (2). These systems can rapidly process medical information and generate guideline-based responses. This study aimed to evaluate the performance of ChatGPT and Gemini in NSTEMI-related clinical scenarios by comparing their responses with those of emergency physicians.

Materials and Methods: This prospective cross-sectional study was conducted using an online survey between February and April 2025. A total of 1,106 emergency physicians in Turkey participated voluntarily. The questionnaire included demographic questions and ten multiple-choice items related to NSTEMI diagnosis and management based on the 2023 European Society

of Cardiology guidelines (1). The same questions were presented to ChatGPT-4.0 and Gemini-2.5 using identical standardized prompts with temperature set to zero and web access disabled. Physicians' responses were analyzed using descriptive statistics and subgroup comparisons according to professional title, experience, and workplace.

Results and Conclusion: The mean number of correct answers among physicians was 7.62 ± 1.32 out of 10. Both ChatGPT and Gemini answered nine questions correctly (90% accuracy). General practitioners scored 7.48 ± 1.3, residents 7.98 ± 1.1, and specialists 8.19 ± 1.3, showing improved performance with increasing experience. Physicians working in training and research hospitals achieved higher scores than those in state hospitals. Questions related to basic knowledge, such as diagnosis and biomarkers, had high correct response rates (> 90%), whereas questions requiring more complex clinical reasoning showed lower accuracy among physicians (3,4).Conclusion:ChatGPT and Gemini demonstrated higher accuracy than emergency physicians in NSTEMI-related guideline-based questions. These findings suggest that AI may support medical education and clinical decision-making. However, performance in knowledge-based questions does not necessarily reflect real clinical diagnostic ability. Human clinical judgment remains essential, particularly in complex clinical situations.

Keywords: Artificial intelligence, Large language models, Non-ST elevation myocardial infarction

---

Ref No: 7695

More than a medical visit: homelessness as a social emergency in the emergency department

Hakan Akçırahan[1], Fatih Cemal Tekin[1], Rıdvan Tuncer[1], Ayla Mollaoğlu[1], Mehmet Gül[1]

[1]Emergency Medicine Department, Konya City Hospital, Türkiye

Hakan Akçırahan / Emergency Medicine Department, Konya City Hospital, Türkiye

Introduction and Purpose: Homelessness is a significant public health issue that leads to recurrent emergency department (ED) visits, often driven by social rather than medical reasons. These patients may present to EDs to fulfill basic human needs, such as shelter and warmth.

Materials and Methods: A 49-year-old male patient with no known comorbidities presented to the emergency department with a complaint of generalized body pain. Physical examination revealed poor self-care and hygiene. Detailed blood parameters and radiological examinations

demonstrated no acute pathology. A review of his medical records indicated recurrent ED visits with similar complaints. As there was no medical indication for inpatient admission, the patient was planned for discharge; however, upon learning that he was living on the streets and had no relatives, the hospital's social services department was consulted. Due to delays in arranging an appropriate shelter, the patient remained under ED observation for 3-4 days before being transferred to a housing facility under the coordination of social services.

Results and Conclusion: In conclusion, social deprivation plays a pivotal role in the recurrent emergency department visits of homeless patients. For ethical reasons, these individuals cannot be abandoned to the streets. Beyond medical intervention, it is crucial to implement case management programs where the emergency department and social services operate in an integrated manner, ensuring the redirection of these patients to safe environments.

Keywords: Emergency Department, Homelessness, Social services

---

Ref No: 7714

Bibliometric and conceptual analysis of the point-of-care ultrasonography literature in Türkiye

Bora CEKMEN[1], Dicle BULAK[1], Bahri Ogulcan TABAK[1], Hamza Alp Eren KORKUT[1], Burcu Simge EROGLU[1], Busra BILDIK[1]

[1]Karabuk University, Faculty of Medicine, Department of Emergency Medicine

Burcu Simge EROGLU / Karabuk University, Faculty of Medicine, Department of Emergency Medicine

Introduction and Purpose: Point-of-care ultrasonography (POCUS) is an increasingly adopted imaging modality that supports diagnostic and interventional processes across multiple clinical settings, particularly in emergency medicine. Evaluating the scientific output in this field is important for identifying research trends,thematic concentrations, and areas requiring further development. This study aimed to assess the bibliometric characteristics of POCUS-related publications from Türkiye with Turkish corresponding authors, to identify research trends, and to visualize the conceptual structure of the literature.

Materials and Methods: This descriptive bibliometric study searched PubMed using the terms “point-of-care ultrasound,” “POCUS,” “bedside ultrasound,” “emergency ultrasound,” “focused ultrasound,” and “point of care ultrasonography.” Eligible POCUS-related publications with

Turkish corresponding authors were included. Studies were analyzed by publication year, study design, topic, and journal Scientific Journal Rankings (SJR) quartile. Keyword co-occurrence analysis was performed using VOSviewer to evaluate thematic clustering and temporal trends.

Results and Conclusion: A total of 67 POCUS-related publications were identified. Scientific output increased markedly after 2020; publications from 2023–2026 accounted for 41.8% of all studies, while those from 2020–2022 represented 28.4%. Most studies were observational in design (79.1%), whereas reviews accounted for 14.9%, and bibliometric and interventional studies each represented 3.0%. Musculoskeletal POCUS was the most frequently studied topic (25.4%), followed by abdominal POCUS (13.4%) and lung POCUS (11.9%). Procedural, vascular, and education/epidemiology-focused studies were also regularly represented, whereas cardiac POCUS and protocol-based publications remained limited (Table 1). Overall, 74.7% of the publications were published in Q1–Q2 journals, suggesting strong international visibility in this field. In the VOSviewer analysis, the keywords "point-of-care ultrasound" and "ultrasound" occupied central positions in the network. The dominant cluster was organized around musculoskeletal applications, emergency department practice, and diagnostic performance, while a second major cluster was associated with lung POCUS and respiratory diseases. Additional clusters reflected abdominal, pediatric, procedural, and vascular applications. Overlay visualization showed a recent shift toward pediatric applications, abdominal POCUS, and advanced ultrasound techniques (Figure 1). These findings demonstrate that POCUS research in Türkiye has not only grown quantitatively but has also shown substantial diversification and maturation across clinical application areas; however, greater emphasis on cardiac POCUS, standardized protocols, and multicenter studies with higher levels of evidence is still needed.

Figure 1. Keyword co-occurrence network of POCUS-related publications from Türkiye.

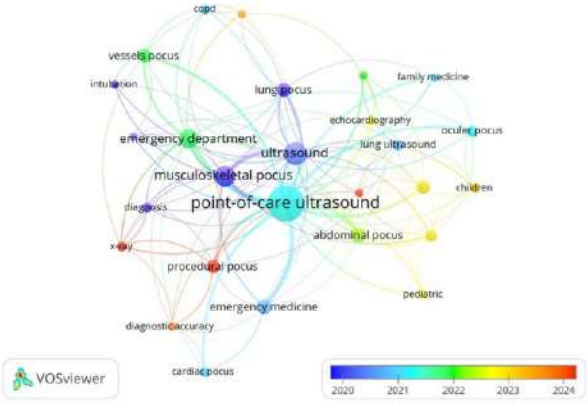

Node size represents the frequency of keyword occurrence, while the thickness of the connecting lines indicates the strength of co-occurrence between keywords. Colors reflect the average

publication year, with warmer colors (yellow–red) indicating more recent research topics and cooler colors (blue–green) representing earlier studies.

Table 1: Study Characteristics

Characteristic	**n (%)**
Publication year	
2005-2012	0 (0.0%)
2013-2016	11 (16.4%)
2017-2019	9 (13.4%)
2020-2022	19 (28.4%)
2023-2026	28 (41.8%)
Study design	
Observational	53 (79.1%)
Review	10 (14.9%)
Bibliometric	2 (3.0%)
Interventional	2 (3.0%)
Topic	
Musculoskeletal POCUS	17 (25.4%)
Abdominal POCUS	9 (13.4%)
Lung POCUS	8 (11.9%)
Procedural POCUS	7 (10.4%)
Education / Epidemiology	7 (10.4%)
Vessels POCUS	7 (10.4%)
Oculer POCUS	5 (7.5%)
Cardiac POCUS	4 (6.0%)
Protocol	2 (3.0%)
Topic: Other POCUS	1 (1.5%)
Journal SJR quartile	
Q1	30 (44.8%)
Q2	20 (29.9%)
Q3	15 (22.4%)
Q4	2 (3.0%)

Keywords: Point-of-care ultrasound, Bibliometric analysis, Türkiye

Ref No: 7738

Gender Disparity within The Family Medicine Academy

Aybala Cebecik[1], Bora Çekmen[1]

[1]KARABUK UNIVERSITY

Bora Çekmen / KARABUK UNIVERSITY

Introduction and Purpose: The issue of gender disparity in academic medicine is a subject that has been debated for many years. Despite an increase in the number of female physicians, there is still reported underrepresentation of women in senior academic positions and administrative roles. The purpose of this study is to examine the gender distribution according to academic titles in family medicine, as well as the gender distribution among family medicine department heads at various universities and hospitals in Türkiye.

Materials and Methods: This cross-sectional study examined the academic staff in family medicine data of various universities and hospitals in Türkiye. The distribution of male and female faculty members according to their professor, associate professor and assistant professor titles was evaluated, as was the gender of department heads. The relationship between gender and academic title was analysed using the chi-square test, and a statistical significance level of $p < 0.05$ was accepted.

Results and Conclusion: Results:A total of 89 family medicine clinics were examined. Of the 258 faculty members, 136 (53.1%) were women. In professor positions, 38 (41.8%) of the subjects were female and 53 (58.2%) were male; in associate professor positions, 48 (59,3%) were female and 33 (40,7%) were male; and in assistant professor positions, 50 (58,1) were female and 36 (41,9%) were male. A significant relationship was identified between gender and academic title ($p = 0.034$). As shown in Table 1, the professor level was the one most frequently represented by male faculty members. By contrast, the levels of associate professor and assistant professor were more often represented by female faculty members. The gender distribution among department heads was 40 women (46%) and 47 men (54%), with no statistically significant difference observed ($p=0.453$).Conclusion:Despite the preponderance of women in the overall number of academics, men are more represented in professorship positions. Nevertheless, the finding that the number of women exceeds the number of men in associate professorship and assistant professorship positions suggests that the proportion of women in professorship positions will also be high in the future. The development of policies that support gender equality in academic medicine is of significant importance.

Gender Distribution by Academic Title

Academic title	Women n(%)	Men n(%)
Professor	38 (41,8%)	53 (58,2%)
Associate professor	48 (59,3%)	33 (40,7%)
Assistant Professor	50 (58,1%)	36 (41,9%)

$\chi^2 = 6.79\ p=0.034$

Keywords: gender disparity, family Medicine

Ref No: 7747

When Stroke Is Not Stroke: Central Nervous System Involvement of Langerhans Cell Histiocytosis in an Elderly Patient

Fatma Çakmak[1]

[1]İstanbul Atlas Universty Faculty of Medicine, Department of Emergency Medicine

Fatma Çakmak / İstanbul Atlas Universty Faculty of Medicine, Department of Emergency Medicine

Introduction and Purpose: Histiocytoses are rare disorders characterized by the accumulation of cells derived from the mononuclear phagocyte system in various tissues and organs, affecting both children and adults. Langerhans Cell Histiocytosis (LCH) is defined by the infiltration of histiocytes that exhibit features similar to epidermal dendritic Langerhans cells but arise from the aberrant differentiation of myeloid dendritic cell precursors. Although bone involvement is the most common manifestation, other frequently affected sites include the lungs, skin, liver, spleen, and lymph nodes. The clinical presentation of LCH is highly variable, ranging from systemic symptoms such as fever and weight loss to organ-specific manifestations including bone pain,

mucocutaneous lesions, lymphadenopathy, and cytopenias. Herein, we report an elderly patient presenting with acute neurological deficit.

Materials and Methods: An 84-year-old male was referred to the emergency department with sudden-onset weakness in the left arm and leg. His medical history was notable only for hypertension. On admission, vital signs were stable. Neurological examination revealed 3/5 muscle strength in the left upper and lower extremities without additional neurological deficits.Initial cranial CT demonstrated loss of gray–white matter differentiation in the left hemisphere along with a hypodense area consistent with chronic subdural hematoma. Diffusion-weighted magnetic resonance imaging (DWI-MRI) showed no evidence of acute ischemia. Due to the discrepancy between clinical findings and imaging results, contrast-enhanced brain MRI was performed. This revealed enhancing lesions in the right hemisphere consistent with LCH, which were considered responsible for the patient's symptoms.

Results and Conclusion: LCH predominantly affects children, and its incidence in adults is extremely low, particularly in the elderly population. Central nervous system involvement is rare and typically presents in tumoral or neurodegenerative forms. In this case, the acute onset of focal motor deficit suggested the tumoral form. The mismatch between left-sided CT findings and left hemiparesis indicated that the CT abnormalities were likely chronic and unrelated to the acute presentation. Contrast-enhanced MRI was crucial in establishing the correct diagnosis.In elderly patients presenting with acute neurological deficits, initial CT imaging may be misleading. When diffusio weighted MRI is normal and clinicoradiological mismatch exists, contrast-enhanced MRI plays a critical role in identifying rare diagnoses such as LCH and preventing misdiagnosis.

Keywords: Langerhans Cell Histiocytosis, Central Nervous System, Stroke

---

Ref No: 7765

Laboratory Evaluation of Meningiomas in the Emergency Department: A Retrospective Analysis

İlyas Daşkıran[1] [1]Malatya Turgut Ozal University

İlyas Daşkıran / Malatya Turgut Ozal Universit

Introduction and Purpose: AbstractObjective: This study aimed to retrospectively evaluate the relationship between demographic characteristics, presenting symptoms, and laboratory parameters of patients with meningioma who were admitted to the emergency department.

Materials and Methods: Materials and Methods: The data of 49 patients who presented to the emergency department between January 2020 and January 2024 and were diagnosed with intracranial meningioma were retrospectively analyzed. Patients' age, sex, presenting symptoms, and laboratory parameters—including serum calcium, lactate dehydrogenase (LDH), and arterial blood gas pH values—were recorded and statistically analyzed.

Results and Conclusion: Results: Of the patients included in the study, 67.3% were female and 32.7% were male. The most common presenting symptom was headache. While no significant differences were observed between sexes in terms of serum calcium and pH values, serum lactate dehydrogenase (LDH) levels were found to be significantly higher in female patients.Conclusion: Patients with meningioma most commonly present to the emergency department with nonspecific symptoms. Serum LDH levels may serve as a potential biomarker reflecting tumor metabolism, whereas calcium and pH values appear to have limited discriminative value. The combined use of laboratory parameters with clinical evaluation may contribute to the diagnostic process.

Keywords: meningioma; emergency department; lactate dehydrogenase

---

Ref No: 7805

Colchicine-Induced Massive Rhabdomyolysis and Acute Kidney Injury Complicated by Aspiration Pneumonia: A Case Report

Ahmet Gümüş[1], Nazlı Kenan Karakuş[1], Tunay Arıcı[1], Mine Kayacı Yıldız[1], Mehmet Gül[1]

[1]Emergency Medicine Department, Konya City Hospital, Türkiye

Ahmet Gümüş / Emergency Medicine Department, Konya City Hospital, Türkiye

Introduction and Purpose: Colchicine has a narrow therapeutic index and carries a high risk of mortality, particularly in elderly patients with comorbidities such as chronic kidney disease (CKD) and diabetes mellitus (DM). In this case, we present a severe intoxication characterized by massive rhabdomyolysis, anuric acute kidney injury (AKI), and aspiration pneumonia following standard-dose colchicine use.

Materials and Methods: Case: A 72-year-old female patient with known diagnoses of gout, DM, hypertension (HT), and CKD was hospitalized in an internal medicine ward at an external center for the treatment of a gout attack. Despite hydration, her creatinine and creatine kinase (CK) levels progressively increased, and her clinical condition deteriorated. The patient, who

developed complete anuria, aspirated gastric contents during severe vomiting episodes in the early phase of colchicine toxicity, leading to respiratory failure and subsequent intubation. Upon admission to our hospital, laboratory findings were as follows: creatinine 4.8 mg/dL, CK 37,000 U/L, LDH 2234 U/L, phosphorus 7.1 mg/dL, pH 7.2, bicarbonate 18 mmol/L, and lactate 4 mmol/L. Her baseline creatinine had been 1.2 mg/dL prior to initiation of colchicine for gout treatment. On the third day of therapy, creatinine was 2.2 mg/dL and CK was 25,000 U/L. The patient was intubated and underwent emergency hemodialysis. Although renal and muscle parameters improved following dialysis, aspiration pneumonia showed radiological progression.

Results and Conclusion: Colchicine toxicity leads to systemic collapse by disrupting microtubule function at the cellular level. By binding to microtubule proteins (tubulin), colchicine impairs intracellular transport and cytoskeletal integrity, initiating direct cellular lysis in tissues with high protein turnover. In this case, the presence of underlying CKD and DM significantly altered the pharmacokinetic profile of the drug. Severe gastrointestinal distress observed in the early phase of colchicine toxicity triggered uncontrollable vomiting episodes, markedly increasing the risk of aspiration.In conclusion, reduced colchicine clearance on the background of CKD accelerated the toxic process. The aspiration event, triggered by severe gastrointestinal symptoms (colchicine-induced diarrhea), became the primary factor worsening the prognosis despite metabolic improvement. In elderly patients with CKD and DM, careful dose adjustment and close monitoring are crucial when prescribing colchicine, even if baseline creatinine levels are within normal limits.

Keywords: colchicine, Acute kidney injury, aspiration pneumonia

---

Ref No: 7810

Bee Sting-Induced Acute Coronary Syndrome: A Case of Type I Kounis Syndrome in a Young Patient

ÖMER SERDAR MAMUR[1]

[1]Malatya Turgut Özal Üniversitesi

ÖMER SERDAR MAMUR / Malatya Turgut Özal Üniversitesi

Introduction and Purpose: Introduction: Kounis syndrome is an acute coronary syndrome caused by an allergic reaction. Type I Kounis syndrome occurs in patients with completely normal coronary arteries due to coronary vasospasm. It is an important and frequently underdiagnosed cause of MINOCA (Myocardial Infarction with Non-Obstructive Coronary

Arteries). This report presents a young male patient who developed a STEMI (ST-Elevation Myocardial Infarction) like clinical picture following a bee sting.

Materials and Methods: Case Report: A 19-year-old male with no known chronic illness, drug use, or allergy history presented to the emergency department with sudden pressure-like chest pain and shortness of breath. These symptoms began approximately 45 minutes after he was stung by a bee. Physical examination revealed widespread urticaria on his trunk and extremities; however, he was normotensive and had no signs of angioedema. An electrocardiogram (EKG) demonstrated ST-segment elevation in the inferior leads (II, III, aVF) and reciprocal ST depression in leads I, aVL, and V1-V2. The patient was treated with H1 and H2 blockers along with intravenous corticosteroids (methylprednisolone). Urgent coronary angiography (CAG) revealed completely normal coronary arteries with no obstructive lesions, confirming the diagnosis of Type I Kounis Syndrome. Following the regression of his allergic and cardiac symptoms, the patient was discharged with full recovery approximately 36 hours later.

Figure 1: The patient's electrocardiogram in the emergency department

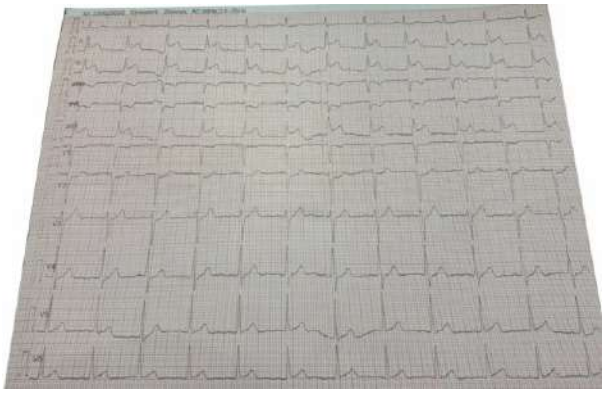

Results and Conclusion: Conclusion: Severe allergic reactions can trigger STEMI-like conditions even in young patients with zero cardiovascular risk factors.Kounis syndrome must be considered in the differential diagnosis for patients presenting with acute chest pain and concurrent allergic symptoms, such as widespread urticaria, even in the absence of angioedema.Early recognition of this syndrome is vital for identifying the underlying etiology of MINOCA cases and ensuring the rapid administration of targeted allergy-specific therapies alongside standard cardiac care.

Keywords: Kounis Syndrome, Acute Coronary Syndrome, Bee Sting

Ref No: 7832

The Return of the "Forgotten Disease": From Simple Pharyngitis to Septic Shock

AHMET CELAL ÖZSOY[1]

[1]University of Health Sciences, Sanliurfa Mehmet Akif Inan Training and Research Hospital, Department of Emergency Medicine

AHMET CELAL ÖZSOY / University of Health Sciences, Sanliurfa Mehmet Akif Inan Training and Research Hospital, Department of Emergency Medicine

Introduction and Purpose: ABSTRACTIntroduction: Lemierre syndrome (LS), frequently called the "forgotten disease," is a rare but life-threatening complication of bacterial pharyngitis. It is characterized by the extension of an oropharyngeal infection into the lateral pharyngeal spaces, resulting in septic thrombophlebitis of the internal jugular vein (IJV) and the subsequent dissemination of septic emboli. While the incidence of LS declined with the widespread use of penicillin, cases have risen since the late 1970s, potentially due to more restrictive antibiotic prescribing patterns. The condition predominantly affects healthy adolescents and young adults, with Fusobacterium necrophorum being the most common pathogen.

Figure 1: Internal jugular vein thrombosis (red arrow)

Figure 1: Internal jugular vein thrombosis (red arrow)



Figure 1: Internal jugular vein thrombosis (red arrow)

Materials and Methods: Case Presentation: A 23-year-old male presented to the emergency department with fever, neck pain, and shortness of breath. He reported an untreated sore throat seven days prior. Physical examination revealed a temperature of 39.2°C, tachycardia,

hypotension, and notable tenderness and swelling along the right sternocleidomastoid (SCM) muscle. Laboratory investigations showed leukocytosis (18,000/µL) and significantly elevated C-reactive protein and procalcitonin. Contrast-enhanced computed tomography (CT) identified a filling defect in the right IJV and bilateral cavitary pulmonary nodules consistent with septic emboli. Blood cultures confirmed Fusobacterium necrophorum. The patient was managed in the intensive care unit with intravenous piperacillin-tazobactam, metronidazole, and anticoagulation therapy.

Results and Conclusion: Conclusion: LS remains a high-morbidity clinical entity that requires a high index of suspicion. Clinicians should consider "post-anginal sepsis" if a patient develops high fever and SCM tenderness shortly after a pharyngeal infection. Early diagnosis via contrast-enhanced CT—the gold standard for diagnosis—and prompt initiation of aggressive antibiotic therapy are critical to reducing mortality.

Keywords: Lemierre syndrome, Fusobacterium necrophorum, Internal jugular vein thrombosis

---

Ref No: 7851

Severe burns, respiratory deterioration, and cardiopulmonary resuscitation: A case report discussing extracorporeal membrane oxygenation

Fırat Okta[1], Alten Oskay[1], Mert Özen[1], Atakan Yılmaz[1], Murat Seyit[1]

[1]Pamukkale University, School of Medicine, Department of Emergency Medicine

Alten Oskay / Pamukkale University, School of Medicine, Department of Emergency Medicine

Introduction and Purpose: Burns are serious traumas that cause the death of more than 300,000 people each year. Severe burns are defined as second-degree or higher burns involving more than 20% of the total body surface area and, in addition to skin lesions, may also lead to multiple organ failure. One of the organs most frequently affected after severe burns is the lungs. In the lungs, disruption of the alveolar-capillary membrane due to both fluid therapy administered during resuscitation and various inflammatory mediators may cause severe impairment of ventilation across a spectrum ranging from pulmonary edema to acute respiratory distress syndrome (ARDS). This mechanism gives rise to the hypothesis that, during cardiopulmonary resuscitation (CPR) in patients with severe burns, ventilation may not be adequately achieved with endotracheal intubation (ETI). This case report aims to discuss the potential use of extracorporeal membrane oxygenation (ECMO) in patients with severe burns through pathophysiological mechanisms.

Materials and Methods: A 52-year-old male textile factory worker presented after a boiler containing 70–80°C water and acetic acid spilled over him. Examination showed extensive second-degree burns involving nearly the entire body except the feet and ankles. Initial lung auscultation was clear, but laryngoscopy revealed marked vocal cord edema. Vital signs are shown in Table 1. Because of impending airway compromise, endotracheal intubation (ETI) was performed 20 minutes after admission. He simultaneously received intravenous Ringer's lactate, broad-spectrum antibiotics, analgesics, and tetanus prophylaxis. Ten minutes after ETI, he developed in-hospital cardiac arrest. Despite repeated cardiopulmonary resuscitation (CPR) for six consecutive arrest episodes, he eventually died. Approximately 600 mL hemorrhagic fluid was aspirated from the endotracheal tube during the fifth and sixth cycles (Figure 1).

Figure 1. Approximately 600 mL of hemorrhagic fluid aspirated from the endotracheal tube during the fifth and sixth cardiopulmonary resuscitation cycles.

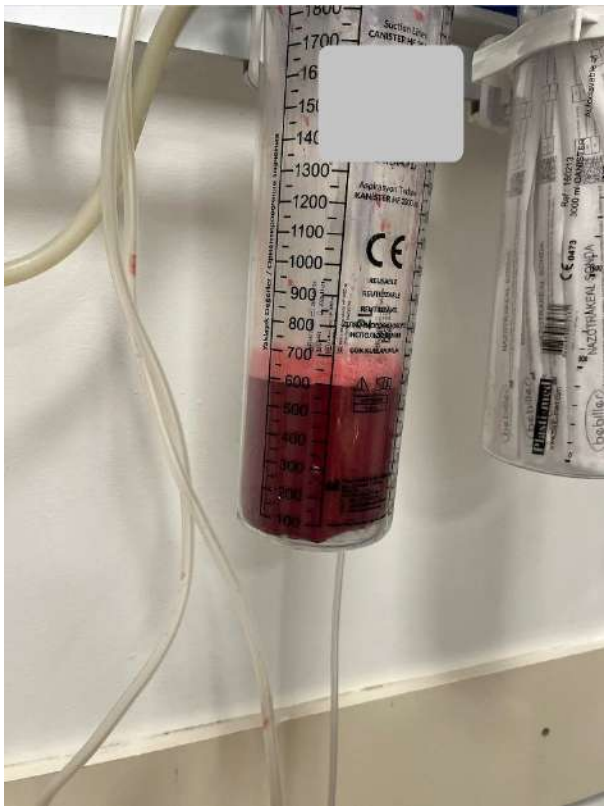

Table 1. The patient's documented vital signs on arrival

Blood Pressure	Heart Rate	Body Temperature	Fingertip Oxygen Saturation	Respiratory Rate
124/73 mmHg	87 beats/min	36.1 °C	93 %	26 breaths/min

Results and Conclusion: There is no clear consensus in the literature regarding the use of ECMO in burn patients. Nevertheless, mortality rates have been reported to be high in patients with severe burns who undergo ECMO for respiratory failure. However, mortality is also extremely high in patients who require CPR after severe burns. Therefore, whether ECMO can be considered a rescue treatment option in patients requiring CPR after severe burns constitutes an important area of debate.

Keywords: Acute respiratory distress syndrome, extracorporeal membrane oxygenation, in-hospital cardiac arrest

---

Ref No: 7856

Takotsubo Cardiomyopathy Following Acute Emotional Stress Mimicking Acute Coronary Syndrome: A Case Report

AHMET DURSUN DEMİR[1], HIZIR UFUK AKDEMİR[1]

[1]Department of Emergency Medicine, Ondokuz Mayıs University Faculty of Medicine, Samsun, Türkiye

AHMET DURSUN DEMİR / Department of Emergency Medicine, Ondokuz Mayıs University Faculty of Medicine, Samsun, Türkiye

Introduction and Purpose: Takotsubo cardiomyopathy is a transient cardiac syndrome characterized by acute left ventricular systolic dysfunction, typically triggered by intense emotional or physical stress. It frequently mimics acute coronary syndrome (ACS) with similar clinical presentation, electrocardiographic changes, and elevated cardiac biomarkers, making differentiation challenging in the emergency setting. Definitive diagnosis requires exclusion of obstructive coronary artery disease and identification of characteristic regional wall motion abnormalities.

Materials and Methods: A 54-year-old female presented to the emergency department with acute onset dyspnea and bilateral arm numbness following intense emotional stress after attending a funeral. Notably, she did not report chest pain. Her medical history included type 2 diabetes mellitus and hypothyroidism. On admission, she was hemodynamically stable, and physical examination was unremarkable.Electrocardiography demonstrated sinus rhythm with nonspecific repolarization abnormalities and QT interval prolongation, without ST-segment elevation. High-sensitivity troponin I levels were elevated with minimal dynamic change (124 ng/L and 126 ng/L; reference range 0–46.47 ng/L), while CK-MB levels remained within normal limits. Transthoracic echocardiography revealed a mildly reduced left ventricular ejection fraction (45–50%) with hypokinesia involving the apical and mid-anterior segments, accompanied by relatively preserved basal contractility.Given the initial suspicion of acute coronary syndrome, urgent coronary angiography was performed, which demonstrated no significant stenosis or obstruction in the epicardial coronary arteries. Based on the presence of emotional stress as a trigger, modest troponin elevation, characteristic echocardiographic findings, and the absence of obstructive coronary artery disease, a diagnosis of Takotsubo cardiomyopathy was established according to InterTAK diagnostic criteria.

ECG

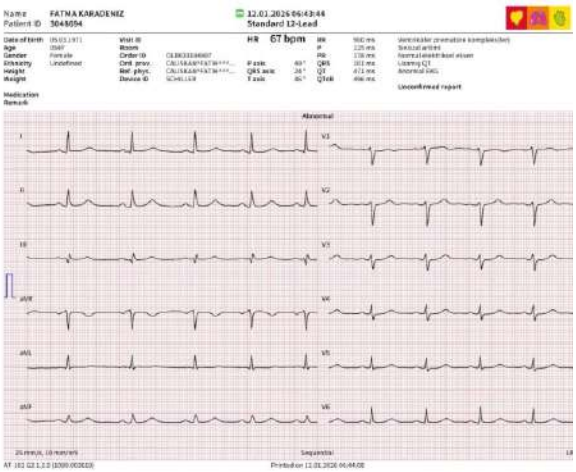

CAG 1



CAG 2



CAG 3

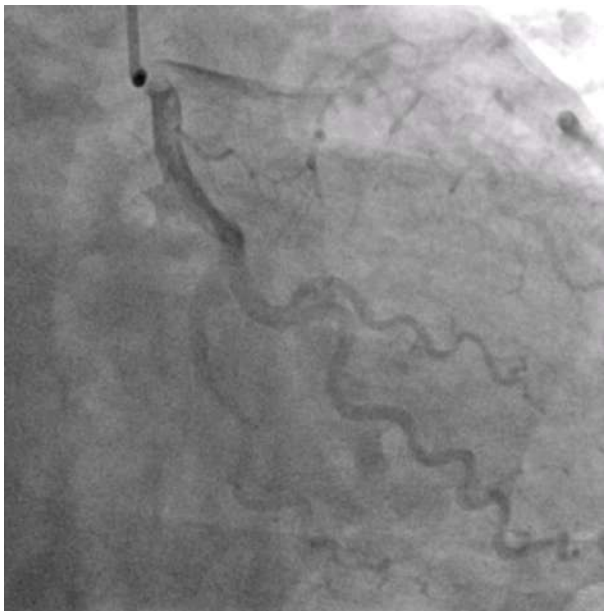

CAG 4

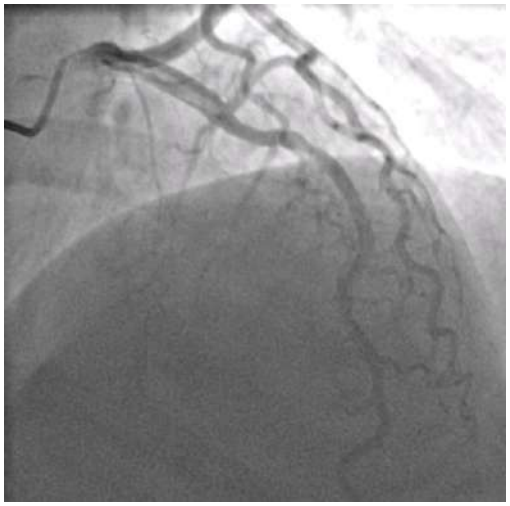

Results and Conclusion: Takotsubo cardiomyopathy should be considered in patients presenting with acute coronary syndrome-like features, particularly in the presence of recent emotional stress and atypical symptoms such as dyspnea without chest pain. Recognition of this condition in the emergency department is essential to guide appropriate management and avoid unnecessary invasive interventions.

Keywords: Takotsubo cardiomyopathy, Acute coronary syndrome, Coronary angiography

Ref No: 7860

Don't forget the electrolytes: hypokalemic periodic paralysis as a cause of acute quadriparesis

Zeynel Emre BAL[1], Nurser MUTLU[1], İsmail CEYLAN[1], Emirhan Ünlü[1], Mehmet Gül[1]

[1]Emergency Medicine Department, Konya City Hospital, Türkiye

Emirhan Ünlü / Emergency Medicine Department, Konya City Hospital, Türkiye

Introduction and Purpose: Hypokalemic periodic paralysis (HPP) is a rare but treatable neuromuscular disorder characterized by sudden-onset episodes of muscle weakness. This study aims to present a case of HPP presenting with acute quadriparesis and to highlight its significance in the differential diagnosis.

Materials and Methods: A 27-year-old male patient with no significant past medical history presented to the emergency department with complaints of sudden-onset weakness and numbness in all four extremities. The patient's vital signs were stable, and his Glasgow Coma Scale (GCS) score was 15. Neurological examination revealed a motor strength of 2/5 in all extremities. Laboratory investigations were unremarkable except for the presence of hypokalemia. Based on the clinical presentation and laboratory findings, the patient was admitted to the neurology inpatient service for observation and follow-up with a presumptive diagnosis of hypokalemic periodic paralysis.

Results and Conclusion: In the present case, the absence of any known systemic disease and the presentation with an initial episode suggest the possibility of primary HPP. Nevertheless, the exclusion of secondary etiologies is crucial for the clinical management. The differential diagnosis includes Guillain-Barré syndrome, myasthenia gravis, acute myopathies, and other electrolyte imbalances. While Guillain-Barré syndrome is primarily characterized by a progressive clinical course and areflexia, myasthenia gravis typically presents with fatigable muscle weakness. In contrast, HPP is distinguished by sudden-onset, generally painless muscle weakness associated with hypokalemia. Hypokalemic periodic paralysis should be considered in the differential diagnosis of patients presenting with acute-onset generalized muscle weakness. Rapid clinical recovery can be achieved with prompt diagnosis and appropriate electrolyte replacement therapy.

Keywords: Hypokalemic periodic paralysis, hypokalemia, acute paralysis

Ref No: 7861

Salicylate intoxication following ingestion of topical ointments: A case report

Nezime Beyza Yıldırım[1], Betül Babagil[1], Muhammet Gökhan Turtay[1], Gökhan Yılmaz[1], Bekir Kılıç[1], Ceren Efsane Kellecioğlu[1]

[1]University of Health Sciences, Beyhekim Training and Research Hospital, Clinic of Emergency Medicine, Konya, Türkiye.

Muhammet Gökhan Turtay / University of Health Sciences, Beyhekim Training and Research Hospital, Clinic of Emergency Medicine, Konya, Türkiye.

Introduction and Purpose: In this case report, we aimed to present a 28-year-old male who developed salicylate intoxication after ingesting multiple topical ointments in a suicide attempt.

Materials and Methods: A 28-year-old male with a known diagnosis of schizophrenia presented to the emergency department stating that he had ingested several tubes of ointment in a suicide attempt. According to information obtained from his relatives, the patient had ingested Klo-sal lotion© (0.05% clobetasol 17-propionate), Momesalic lotion© (mometasone furoate and salicylic acid), Betasalic lotion© (betamethasone dipropionate), Hametan cream© (Hamamelis virginiana), two tubes of Advantan cream© (methylprednisolone aceponate), Üresal Forte cream© (urea [carbamide] and salicylic acid), Fucidin cream© (fusidic acid), and Duoderm solution© (salicylic acid–lactic acid). It was determined that the patient had ingested more than 6.5 g of salicylic acid–containing preparations, corresponding to a toxic dose. The measured serum salicylate level was 10.4 mg/dL. Following supportive treatment, the control salicylate level decreased to 5.6 mg/dL. After completion of intoxication monitoring and clinical improvement, a psychiatric consultation was requested. On the fourth day of intensive care unit follow-up, the patient was transferred to a hospital with a closed psychiatric ward.

Results and Conclusion: In patients who ingest large amounts of topical ointments with suicidal intent, the possibility of life-threatening salicylate intoxication should be considered.

Keywords: Emergency, Salicylate intoxication, Topical agents

Ref No: 7865

EASIX Score in Predicting Mechanical Ventilation in Pneumonia

Rabia Hande AVCI[1], Büşra BİLDİK[2]

[1]Department of Chest Diseases, Faculty of Medicine, Karabuk University
[2]Department of Emergency Medicine, Faculty of Medicine, Karabuk University

Büşra BİLDİK / Department of Emergency Medicine, Faculty of Medicine, Karabuk University

Introduction and Purpose: Pneumonia is associated with high mortality, particularly in patients requiring admission to the intensive care unit (ICU). Identifying simple and reliable biomarkers that can predict prognosis and the need for mechanical ventilation is important in the early management of these patients. The Endothelial Activation and Stress Index (EASIX) is a laboratory-based score reflecting endothelial dysfunction and systemic stress.

Materials and Methods: This retrospective study included patients admitted to the ICU from the emergency department with a diagnosis of pneumonia. The association between the EASIX score and 28-day mortality and mechanical ventilation (MV) requirement was investigated. Demographic characteristics, comorbidities, radiological findings, and laboratory parameters including CRP, creatinine, albumin, platelet count, and LDH were evaluated. Continuous variables were analyzed using the t-test or Mann–Whitney U test, and categorical variables using the chi-square or Fisher's exact test. Predictors of MV requirement were evaluated using univariable and multivariable logistic regression analyses.

Results and Conclusion: A total of 211 patients were retrospectively analyzed. There were no statistically significant differences in age and gender within the study population. The 28-day mortality rate was 14.7%. The median EASIX score did not differ significantly between survivors and non-survivors. Mekanik ventilasyon was required in 59 patients (28%). Patients requiring MV had significantly higher levels of CRP, urea, creatinine, and LDH, and lower levels of hematocrit and albumin. The EASIX score was also significantly higher in the MV group. In multivariate analysis, the EASIX score and albumin level were identified as independent predictors of the need for MV. The EASIX score can be used as a simple and accessible biomarker to predict the need for mechanical ventilation in critically ill patients with pneumonia. However, larger prospective studies are needed to confirm its clinical utility.

Keywords: EASIX, Pneumonia, Mechanical ventilation

Ref No: 7888

POINT PREVALENCE STUDY: STRESS RATE BY SPECIALTY DURING A SINGLE WORKING DAY

Sana Khedher[1], Hani Mohammed Al Khalaf[2], Fadwa Nairi[3], Mohammed AL safty[1], Hazim Yassin[1], Mahmoud Teleb[1]
[1]intensif care unit. Armed Forces Hospital . Wadi Addawassir. Saudi Arabia
[2]Medical Director.Armed Forces Hospital . Wadi Addawassir. Saudi Arabia
[3]Nursing Administration. Armed Forces Hospital.Wadi Addawassir. Saudi Arabia

Sana Khedher / intensif care unit. Armed Forces Hospital . Wadi Addawassir. Saudi Arabia

Introduction and Purpose: Background: Occupational stress among healthcare professionals is influenced by workload and clinical environment. Single-day assessments provide a practical measure of real-time psychological burden and help identify high-risk specialities that may benefit from targeted organisational interventions.Objective: To determine the point prevalence of moderate-to-high stress among healthcare professionals on a single working day and to compare stress prevalence across specialities.

Materials and Methods: We conducted a point-prevalence cross-sectional study of 61 healthcare professionals on active duty during a single working day. Stress was measured using the 10-item Stress Scale (SSP-10) and categorised as low (0–13), moderate (14–26), or high (27–40). Prevalence of moderate-to-high stress was assessed overall and compared by speciality, profession, sex, and years of experience.

Results and Conclusion: Results:The overall mean SSP-10 score was 17.0. Females had slightly higher mean stress than males (17.4 vs 16.8), with no clinically meaningful difference. Nurses exhibited higher stress than physicians (17.9 vs 16.5). Stress varied significantly by speciality, with the highest levels observed among Emergency Department nurses (mean 24.6), Emergency Room physicians (mean 21.5), Pediatrics (mean 20.3), Operating Room (mean 19.7), and Pharmacy (mean 19.4). Lower stress levels were seen in Internal Medicine (12.0), Orthopedics (11.8), General Surgery (13.3), and ICU (14.4). Years of experience showed a weak negative correlation with stress ($r = -0.19$), indicating a modest decrease in stress with increasing experience.Conclusion:Perceived stress among healthcare professionals is primarily determined by speciality and professional role, with nurses and emergency-related services at the highest risk. Sex has minimal influence, and experience exerts only a modest mitigating effect. These findings underscore the need for speciality-specific stress reduction and occupational support programs, particularly in high-acuity clinical settings.

Keywords: Occupational Stress; Stress Measurement; Point-Prevalence Study.

Ref No: 7917

The Relationship Between Anatomical Localisation and Demographic Characteristics in Proximal Femur Fractures

Fatma Tortum[1], Şamil Emin Yalçın[1]

[1]Atatürk University

Fatma Tortum / Atatürk University

Introduction and Purpose: This study aimed to evaluate the relationship between the anatomical location of proximal femur fractures with age, gender, height, weight, and body mass index (BMI) in patients presenting to the emergency department.

Materials and Methods: This prospective study was conducted in the emergency department of a tertiary care hospital. Patients diagnosed with proximal femur fractures between 01.01.2026 and 01.03.2026 were included in the study. Fractures were classified according to their anatomical location as femoral head, femoral neck, intertrochanteric, and subtrochanteric. Patients' age, gender, height, weight, and BMI values were recorded. Statistical analyses were performed using IBM SPSS Statistics 20.0 software. ANOVA or Kruskal-Wallis tests were used to compare continuous variables according to their distribution characteristics, and $p < 0.05$ was considered statistically significant.

Results and Conclusion: patients were male, and the average age was 70.5±18.4 years. The most common fracture type was femoral neck fracture (45.9%). A statistically significant relationship was found between the anatomical location of the fracture with age and height ($p=0.013$ and $p=0.025$, respectively). Femoral neck and intertrochanteric fractures were found to be more common in the older age group. No statistically significant relationship was found between gender, weight, BMI, and fracture location.ConclusionThe anatomical location of proximal femur fractures appears to be associated with demographic factors, particularly age and height. Femoral neck and intertrochanteric fractures are more common in older age groups. These findings suggest that demographic characteristics may be associated with the occurrence of proximal femoral fractures.

Table 1: Patients' age, gender, height, weight and BMI values

Variables				
Gender Female (n) Male (n)	**(45.9%) 17** **(54.1%) 20**			
	Mean	**Std. Deviation**	**Minimum**	**Maximum**
Age (year)	70.5	18.4	19	94
Weight (cm)	166.5	7.6	150.0	180.0
Height (kg)	72.1	10.6	55.0	93.0
BMI (kg/m^2)	26.1	3.7	20.8	36.3

Table 2: Relationship between patients' age, gender, height, weight, and BMI with the anatomical location of the fracture

Variabels	Femoral head fracture (n=4, 10.8%)	Femoral neck fracture (n=17, 45.9%)	Intertrochanteric fracture (n=11, 29.7%)	Subtrochanteric fracture (n=5,13.5%)	P Value
Age (Year)	52.024.7 (30-81)	79.3±9.3 (55-94)	74.3±11.3 (57-93)	47.2±23.2 (19-81)	**0.013**
Gender Female	4 (100%)	6 (35.3%)	7 (63.6%)	3 (60.0%)	0.106
Weight (cm)	161.8±3.9 (157.0-165.0)	170.4±7.1 (160.0-180.0)	161.7±6.8 (150.0-170.0)	167.6±6.2 (160.0-175.0)	**0.025**
Height (kg)	82.0±11.2 (70.0-93.0)	73.7±8.3 (60.0-92.0)	67.2±10.9 (55.0-85.0)	69.4±10.7 (60.0-85.0)	0.118
BMI (kg/m^2)	31.3±4.1 (27.5-36.3)	25.4±2.6 (20.8-31.2)	25.7±3.7(21.5-31.2)	24.7±3.8 (21.9-31.2)	0.066

Keywords: Proximal femur fracture, emergency department, demographic characteristics

Ref No: 7921

Vertebral Artery Dissection : Case Report

Muhammed Haldun Gökçe[1], Yusuf Ertuğrul Aslan[1], Emre Bülbül[1]
[1]Erciyes University Faculty of Medicine, Department of Emergency Medicine

Muhammed Haldun Gökçe / Erciyes University Faculty of Medicine, Department of Emergency Medicine

Introduction and Purpose: Vertebral artery dissection (VAD) is a rare and often overlooked component of the etiology of ischemic stroke, especially in young and middle-aged individuals. Its atypical presentations can make diagnosis difficult for physicians. Vertebral artery dissection can develop spontaneously or as a result of trauma to the craniocervical region, severe coughing, sneezing, or Valsalva maneuver. The clinical condition showing the strongest correlation with this condition is fibromuscular dysplasia (1).

Materials and Methods: A 30-year-old male patient presented to our emergency department with complaints of dizziness, nausea, and numbness in his left arm and leg, which started 3-4 hours prior. There were no abnormalities in the patient's vital signs. Physical examination revealed minimal weakness in the left upper and lower extremities. The patient's blood parameters showed no pathology. Computed tomography showed no acute pathology. Diffusion magnetic resonance imaging showed diffusion restriction in the right medial medulla consistent with acute infarction (Figure -1).The patient was consulted with neurology, and a brain and neck computed tomography angiography scan was ordered to evaluate the etiology of this ischemic stroke. The imaging revealed findings consistent with dissection of the right vertebral artery (Figure 2). The patient was admitted to the neurology ward for treatment.

Figure 1

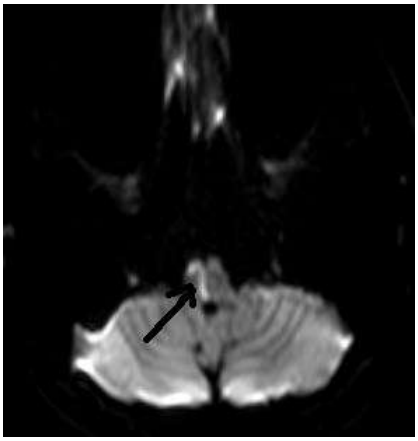

The black arrow indicates the infarct area.

Figure 2:

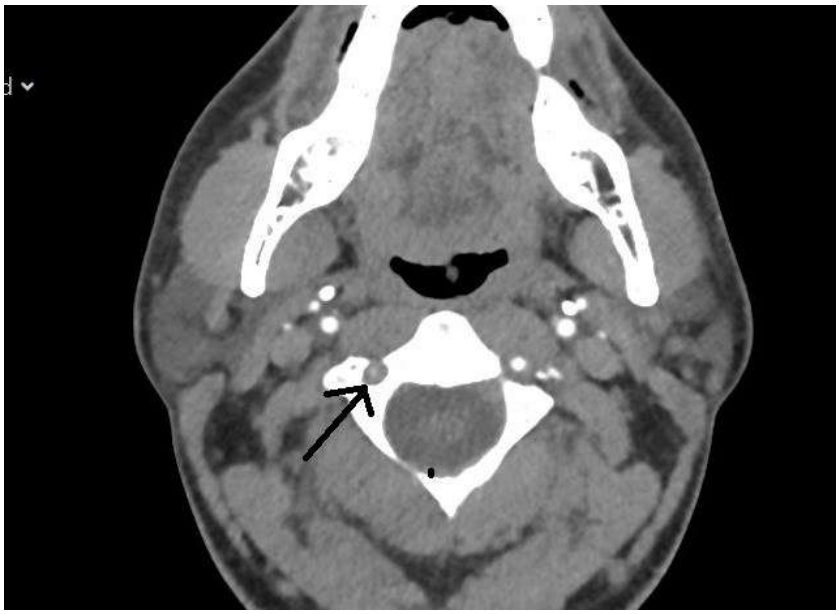

The black arrow indicates the dissection area.

Results and Conclusion: Clinical suspicion is the most decisive step in diagnosis. Especially in young patients, even without risk factors (hypertension, diabetes, hyperlipidemia), symptoms such as sudden onset headache, nausea, and dizziness should not be underestimated, and the possibility of vertebral artery dissection should always be kept in mind. In terms of treatment modalities, a definitive hierarchy of superiority between antiplatelet and anticoagulant approaches has not yet been fully standardized in the literature. In our case, the neurology clinic treated the patient with low molecular weight heparin.Vertebral artery dissection is a rare but important condition that can easily be overlooked given the current workload in emergency departments, and if missed, can lead to morbidity and medico-legal problems. Furthermore, a normal computed tomography scan does not rule out the diagnosis.

Keywords: Vertebral artery dissection, Ischemic stroke, Young stroke.

Ref No: 8008

Spontaneous Isolated Celiac Artery Dissection: A Rare Case Demonstrating Regression Under Conservative Management

Ekim Sağlam Gürmen[1], Kaan Erdaş[1]
[1]Manisa Celal Bayar University School of Medicine, Department of Emergency Medicine, Manisa, Turkey
Kaan Erdaş / Manisa Celal Bayar University School of Medicine, Department of Emergency Medicine, Manisa, Turkey

Introduction and Purpose: The celiac trunk, arising from the anterior abdominal aorta at T12, supplies arterial blood to the upper abdominal organs (1). While aortic dissections are relatively common, isolated visceral artery dissections are rare. Among them, superior mesenteric artery involvement is most frequent; isolated celiac artery dissection is extremely uncommon (2). We present a case of spontaneous isolated celiac artery dissection with regression under conservative management.

Materials and Methods: A 60-year-old female presented with acute, tearing epigastric pain of one-day duration. She reported no vomiting, fever, diarrhea, or melena. Her history included hyperlipidemia and prior breast cancer, treated with tamoxifen and atorvastatin. On examination, vital signs were normal and abdominal findings unremarkable. Laboratory workup revealed elevated D-dimer (~1500 ng/mL), with other results within normal limits.Suspicion for aortic pathology prompted thoracoabdominal CT angiography, which revealed a dissection flap at the celiac trunk origin and a 2.5 cm segment with 12 mm aneurysmal dilatation. No additional vascular or organ abnormalities were noted.Given the aneurysm size (< 15 mm) and stable hemodynamics, conservative management was chosen, including blood pressure control and lifestyle modification. Endovascular stenting was discussed but declined by the patient. Follow-up CT at six months showed ~1 mm regression in aneurysm diameter, and continued medical management was recommended.

Results and Conclusion: Isolated celiac artery dissection is rare, often asymptomatic, and may present with epigastric or back pain (3). Risk factors include hypertension, atherosclerosis, connective tissue disorders, and pregnancy (4). CT angiography is the diagnostic gold standard (5).Management depends on hemodynamic stability, dissection extent, and aneurysm presence. In stable patients, conservative treatment with radiologic monitoring is usually sufficient; intervention is reserved for progression, rupture risk, or organ ischemia (6). In our case, conservative management was safe and effective, with regression at six months.Clinicians should consider visceral artery dissection in patients presenting with acute severe postprandial epigastric pain, despite its rarity (7).

Keywords: Aneurysm, Celiac Artery Dissection, Spontaneous

Ref No: 8053

Right Lower Quadrant Pain Is Not Always Appendicitis: A Case of Suspected Appendiceal Neoplasm

Berat Dilaver[1], İsmail Ataş[1]
[1]Recep Tayyip Erdoğan University Training and Research Hospital, Emergency Medicine Department, Rize, Türkiye

Berat Dilaver / Recep Tayyip Erdoğan University Training and Research Hospital, Emergency Medicine Department, Rize, Türkiye

Introduction and Purpose: Right lower quadrant pain is one of the most common causes of emergency room visits and the most common etiology is acute appendicitis. However, appendiceal neoplasms are rare pathologies and are found in approximately 0.5-1% of all appendectomy materials. Since they often present clinically similar symptoms to acute appendicitis, the diagnosis is often made by postoperative pathologic examination.

Materials and Methods: A 26-year-old male patient was admitted to the emergency department with abdominal pain which was diffuse in the beginning and localized to the right lower quadrant over time. Abdominal examination revealed marked tenderness in the right lower quadrant. However, no signs of defense and rebound were observed. Laboratory tests revealed an elevated leukocyte count of $18.18\times10^3/\mu L$. Abdominal ultrasonography showed that the appendix did not respond to compression and was approximately 15 mm in diameter. Contrast-enhanced abdominal-pelvis tomography also showed a 15 mm appendix. Although these findings were compatible with acute appendicitis, appendiceal neoplasia was also considered suspicious because of the marked increase in the diameter of the appendix. The patient was operated by general surgery and the final diagnosis was appendiceal neoplasm.

Figure 1

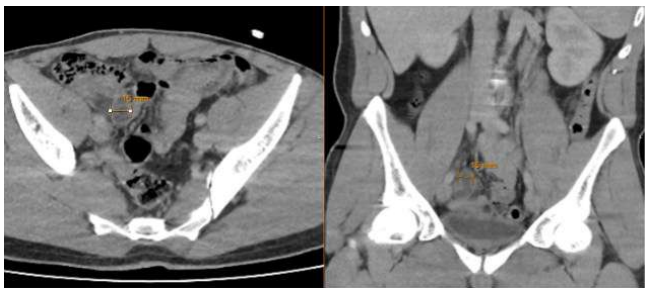

Dilated (≈15 mm) appendix in the right lower quadrant on abdominal CT axial and coronal section

Results and Conclusion: Preoperative diagnosis of appendiceal neoplasms is very difficult and most cases are diagnosed by pathologic examination after surgery with a prediagnosis of acute appendicitis. Findings such as marked increase in appendiceal diameter, luminal dilatation, wall irregularity or peripheral mass appearance, especially on ultrasonography and computed tomography examinations, may be a warning sign for malignancy. Although acute appendicitis is the most common etiology in patients presenting to the emergency department with right lower quadrant pain, appendiceal neoplasms, although rare, may be included in the differential diagnosis.

Keywords: appendiceal neoplasm, acute abdomen, appendicitis

Ref No: 8083

ADHD Symptoms Among Children Presenting With Trauma To The Pediatric Emergency Department

Ekim Sağlam Gürmen[1], Fulya Sağlam[1]
[1]Manisa Celal Bayar University Faculty of Medicine, Department of Emergency Medicine, Manisa, Türkiye

Fulya Sağlam / Manisa Celal Bayar University Faculty of Medicine, Department of Emergency Medicine, Manisa, Türkiye

Introduction and Purpose: Attention-Deficit/Hyperactivity Disorder (ADHD) is one of the most common neurodevelopmental disorders of childhood and is characterized by significant dysfunction in attention, impulse control, and motor activity levels. Consequently, children may exhibit developmentally inappropriate inattention, hyperactivity, and impulsivity (1,2). Since untreated ADHD may adversely affect a child's psychological, social, and academic development, early diagnosis and multidisciplinary follow-up are of critical importance. Due to increased impulsivity and risk-taking behaviors, children with ADHD are reported to present more frequently with trauma and emergency department (ED) visits. This suggests that trauma may represent a clinical manifestation of ADHD symptoms (3,4).This study aimed to evaluate the potential role of ADHD as a risk factor among children aged 5–12 years presenting to the ED with trauma and to investigate the relationship between childhood trauma and ADHD.

Materials and Methods: This prospective, cross-sectional study was conducted at a tertiary care center between January 1, 2024 and January 1, 2025. Children aged 5–12 years who presented to the ED due to trauma, whose parents provided written informed consent, and who completed the assessment scales were included. Parents completed the "Turgay DSM-IV Based Disruptive Behavior Disorders Rating Scale-1995." In addition, demographic characteristics, parental

education level, trauma history within the previous year, screen exposure, and the child's social relationships were evaluated.

Results and Conclusion: Of the 200 children included, 63% were male, and the mean age was 9.07 years. Attention deficit symptoms were significantly more frequent in children with trauma exposure within the previous year. Hyperactivity rates were significantly higher in children who had lost their fathers and in those with parental psychiatric history. Increasing screen exposure was significantly associated with higher rates of attention deficit. Conclusion;This study demonstrated that ADHD symptoms are clinically relevant among children presenting to the emergency department with trauma (2). A significant relationship was identified particularly between prior trauma exposure, screen time, and ADHD symptoms (3). These findings suggest that early recognition of ADHD symptoms in pediatric trauma patients in the emergency setting may be important for appropriate referral and preventive interventions.

Keywords: Attention-Deficit/Hyperactivity Disorder, Pediatric Emergency, Screen Time

---

Ref No: 8084

Atypical Presentation of Pulmonary Embolism With Isolated Back and Right Upper Quadrant Pain

Nevzat HERGÜL[1], ABDULHALİM AKTUĞ[1], Sevdegül KARADAŞ[1]

[1]Van Yuzuncu Yil University Faculty of Medicine

Nevzat HERGÜL / Van Yuzuncu Yil University Faculty of Medicine

Introduction and Purpose: Pulmonary embolism (PE) is a potentially life-threatening condition with a broad spectrum of clinical presentations. Although dyspnea, pleuritic chest pain, and tachycardia are the most common symptoms, atypical manifestations may delay diagnosis. Lower lobe embolic involvement and pulmonary infarction adjacent to the diaphragm may present with abdominal or back pain, mimicking hepatobiliary or other intra-abdominal disorders. Such unusual presentations may lead to diagnostic uncertainty in the emergency department. The aim of this case is to emphasize that PE should be considered in the differential diagnosis of patients presenting with isolated back pain and right upper quadrant pain, even in the absence of respiratory distress.

Materials and Methods: A 52-year-old woman presented to the emergency department with a one-week history of back pain and right upper quadrant pain. She also reported intermittent cough without significant respiratory distress. Her medical history included multiple myeloma, asthma, and prior cholecystectomy. On admission, blood pressure was 120/85 mmHg, body

temperature 37°C, heart rate 102 beats/min, oxygen saturation 95%, and blood glucose 130 mg/dL. She was conscious, oriented, and cooperative. Respiratory examination revealed rales in the right basal lung field, whereas abdominal examination showed no guarding or rebound tenderness. Laboratory findings are summarized in Table 1. Thoracic computed tomography demonstrated increased density in the posteromedial basal segment of the right lower lobe adjacent to the pleura, with minimal pleural effusion, raising suspicion for pulmonary infarction, atelectasis, or a mass lesion (Figure 1). Pulmonary CT angiography revealed a filling defect in the segmental branch of the right pulmonary artery, confirming PE (Figure 2). The patient was admitted to the chest diseases department for further evaluation and treatment.

Figure 1



Thoracic CT image obtained at admission demonstrating increased density in the posteromedial basal segment of the right lower lobe adjacent to the pleura.

Figure 2



Pulmonary CT angiography demonstrating a filling defect in the segmental branch of the right pulmonary artery consistent with pulmonary embolism.

Table 1

Parameter	Result	Reference Range
WBC(White blood cells)	6 x 10^3/µL	4.0-10.0 x 10^3/µL
Hemoglobin	8.6 g/dL	11-17g/dL
Platelet count	176 x 10^3/µL	150-450 x 10^3/µL
C-reactive protein	104 mg/L	<5 mg/L

Laboratory findings of the patient

Results and Conclusion: This case demonstrates that PE may present with isolated back pain and right upper quadrant pain rather than typical respiratory symptoms. Diaphragmatic pleural irritation and lower lobe pulmonary infarction may explain this atypical pain distribution. In patients with unexplained upper abdominal or back pain, particularly when abdominal examination is unremarkable, PE should remain in the differential diagnosis. Careful clinical assessment supported by thoracic imaging is essential for timely diagnosis. Early recognition of such atypical presentations may prevent diagnostic delay and improve patient outcomes.

Keywords: back pain, Pulmonary embolism, right upper quadrant pain

---

Ref No: 8129

Fulminant necrotizing fasciitis following a scorpion sting in a patient with chronic kidney disease: a case report

Ayşe Göksu[1], Hilal Çıralıoğlu[1], Muhammed Fatih Düzyol[1], Yasin Yıldız[1], Mehmet Gül[1]

[1]Emergency Medicine Department, Konya City Hospital, Türkiye

Ayşe Göksu / Emergency Medicine Department, Konya City Hospital, Türkiye

Introduction and Purpose: Necrotizing fasciitis is a rapidly progressive soft tissue infection with a high mortality rate. Diagnosis may be delayed due to the non-specific nature of clinical findings in the early stages. While scorpion stings generally follow a benign course, they can rarely predispose patients to systemic toxicity and secondary infections. This study aims to present a patient with chronic kidney disease who developed a fulminant clinical course consistent with necrotizing fasciitis following a suspected scorpion sting

Materials and Methods: A 42-year-old male patient with known chronic kidney disease, undergoing hemodialysis three times a week, presented with pain, swelling, and ecchymosis in the left lower extremity. The patient described a sudden sharp pain and a stinging sensation in his left leg one day prior, suggesting a possible scorpion sting. Physical examination revealed extensive ecchymotic areas, tenderness, and edema extending from the left thigh to the knee. Vital signs showed hypotension (70/50 mmHg) and tachycardia (140 bpm). Laboratory findings included CRP: 260 mg/L, potassium: 5.8 mmol/L, and blood gas analysis showed pH: 7.3 and bicarbonate: 15 mmol/L. A preliminary diagnosis of necrotizing fasciitis was made based on the rapid progression of clinical findings, systemic instability, and severe pain. The patient was admitted to the intensive care unit; however, he succumbed (exitus occurred) before surgical intervention could be performed.

Results and Conclusion: Necrotizing fasciitis is a disease with high mortality when not recognized early. Severe pain, rapid progression, systemic instability, and elevated inflammatory markers should serve as critical red flags for diagnosis. This case demonstrates that an apparently innocent onset, such as a scorpion sting, can underlie a fatal condition like necrotizing fasciitis.

Keywords: Scorpion sting, chronic kidney disease, necrotizing fasciitis

---

Ref No: 8130

Superior vena cava syndrome due to mediastinal mass presenting with extensive upper extremity thrombosis

Adnan HOCAOGLU[1], Mehmet Murat OKTAY[1], Mustafa BAC[1], Remzi ERKOL[1]
[1]Gaziantep City Hospital
Adnan HOCAOGLU / Gaziantep City Hospital

Introduction and Purpose: Superior vena cava (SVC) syndrome is a life-threatening condition caused by obstruction of venous return from the upper body, most commonly due to malignancy. It may present with subtle findings but can rapidly progress to significant morbidity. We aimed to present a case of SVC syndrome associated with a large mediastinal mass and extensive venous thrombosis.

Materials and Methods: A 40-year-old female with no known chronic disease presented to the emergency department with left arm swelling and chest pain. She had a recent history of mediastinal mass biopsy with pending pathology results. Physical examination revealed asymmetric upper extremity swelling, more prominent on the left side

Mediastinal Mass on Chest CT



Results and Conclusion: Electrocardiography showed sinus tachycardia. Laboratory tests revealed elevated inflammatory markers (CRP: 207 mg/L, WBC: 14,000/mm³) with normal troponin levels. Thoracic computed tomography demonstrated a large heterogeneous mediastinal mass (approximately 112 × 59 × 140 mm) extending to the paracardiac region, surrounding the aorta, and causing intermittent compression of the superior vena cava. Bilateral pleural effusions (right dominant, up to 6 cm) and moderate pericardial effusion (up to 28 mm) were observed. Upper extremity venous Doppler ultrasonography revealed extensive thrombosis involving the left jugular, subclavian, axillary, brachial, ulnar, and radial veins, as well as superficial veins (cephalic and basilic), consistent with deep vein thrombosis and thrombophlebitis. Echocardiography suggested possible metastatic pericardial involvement.This case highlights that SVC syndrome may present with unilateral upper extremity swelling due to extensive venous thrombosis. In patients with mediastinal masses, early recognition of SVC compression and associated thrombotic complications is critical. Multidisciplinary management including oncology, radiology, and emergency medicine is essential to prevent life-threatening deterioration.

Keywords: Superior vena cava syndrome; mediastinal mass; upper extremity thrombosis

Ref No: 8143

Distribution of Causative Substances and Treatment Approaches in Intentional Poisonings: A Retrospective Analysis

Asiye ÖZKAN[1]
[1]Malatya Turgut Özal University, Faculty of Medicine, Department of Emergency Medicine
Asiye ÖZKAN / Malatya Turgut Özal University, Faculty of Medicine, Department of Emergency Medicine

Introduction and Purpose: Acute intoxications are a major cause of emergency department visits worldwide and are associated with serious morbidity and mortality. Suicidal drug and toxic substance ingestions, in particular, are among the clinical situations frequently encountered in emergency departments and require rapid assessment. The clinical picture in these patients can vary widely depending on the type and dose of the substance ingested and the patient's comorbidities. Recent studies show that intentional poisoning cases are more common in young adults and women, and are mostly associated with drugs such as analgesics, antidepressants, and antipsychotics. Furthermore, a significant proportion of intentional poisoning cases presenting to the emergency department may require intensive care and develop serious complications . Therefore, evaluating the epidemiological and clinical characteristics of intoxication cases is important for early diagnosis and determining appropriate treatment strategies.

Materials and Methods: This retrospective study evaluated adult patients who presented to the emergency department of Malatya Training and Research Hospital with suicidal drug or toxic substance ingestion between January 1 and December 31, 2023. Patients were selected from cases recorded in the hospital information system with the ICD-10 diagnostic code X44. Demographic characteristics, type of toxic substance ingested, treatment methods applied, and clinical outcomes were examined. Statistical analyses were performed using IBM SPSS Statistics 27.0 software.

Results and Conclusion: Sixty patients meeting the inclusion criteria were evaluated. 86.7% of the patients were female. The most frequent occurrences were in winter (38.3%) and autumn (28.3%). The most common causative agent was psychiatric medications (45%), followed by multiple drug use (15%) and analgesics (15%). Less frequently, corrosive substances, pesticides, antibiotics, and alcohol consumption were detected. 48.3% of the patients received supportive treatment, while some cases involved activated charcoal, gastric lavage, N-acetylcysteine, and specific antidote treatments. 50 patients were followed in the wards, 10 in the intensive care unit, and all patients were discharged after recovery.Conclusion: Suicidal ingestion of toxic substances is a common clinical situation in the emergency department. Early assessment, appropriate supportive treatment, and careful clinical monitoring play a significant role in achieving positive clinical outcomes in patients.

Keywords: intoxication, suicide, drug

Ref No: 8147

Isolated traumatic splenic laceration following blunt abdominal trauma: A case report

Ceren Efsane Kellecioğlu[1], Müslüme Kasa[1], Berra Kalkavan Doğan[1], Gökhan Yılmaz[1], Muhammet Gökhan Turtay[1], Harun Yahya Yıldırım[1]

[1]University of Health Science, Beyhekim Training and Research Hospital, Clinic of Emergency Medicine, Konya, Türkiye.

Muhammet Gökhan Turtay / University of Health Science, Beyhekim Training and Research Hospital, Clinic of Emergency Medicine, Konya, Türkiye.

Introduction and Purpose: In this case report, we aimed to emphasize that conservative management may be an appropriate treatment strategy in a patient with isolated splenic injury whose trauma mechanism was consistent with the radiological findings, in light of the current literature.

Materials and Methods: A patient with a history of falling while skiing was referred to our emergency department for further evaluation and management after a traumatic splenic laceration had been detected during assessment at an outside medical centre. Physical examination revealed tenderness in the lumbar region and pain with tenderness in the left upper quadrant of the abdomen. Based on the clinical findings, the patient was considered hemodynamically stable. Laboratory investigations performed in our hospital revealed no pathological abnormalities except for a decrease in haemoglobin of two units compared with the values measured at the outside centre. Abdominal ultrasonography revealed disruption of the splenic contour adjacent to the left kidney and approximately 3–4 mm of free fluid within the abdominal cavity. Thoracic computed tomography (CT) demonstrated displaced fractures of the left posterior 10th, 11th, and 12th ribs and non-displaced fractures of the left anterior 6th and 7th ribs. Based on the clinical and radiological findings, the patient was diagnosed with an isolated splenic injury. Since the patient was hemodynamically stable, conservative management was planned. After consultation with the departments of general surgery and thoracic surgery, the patient was admitted to emergency medicine clinic's intensive care unit. The patient was managed conservatively and discharged without complications.

Results and Conclusion: Hemodynamic stability is the key factor determining the treatment approach in isolated splenic injuries following blunt trauma. In stable patients, nonoperative management can be successfully applied with careful clinical monitoring and serial evaluations.

Keywords: Blunt trauma, Conservative management, Splenic injury

---

Ref No: 8149

Simulation-Based Comparative Workflow Analysis of Emergency Department Processes: Impact of ChatGPT-Assisted Decision Support on Door-to-Needle Time

İlker Kaçer[1]
[1]Department of Emergency Medicine, Aksaray University, Faculty of Medicine, 68100, Aksaray, Turkey
İlker Kaçer / Department of Emergency Medicine, Aksaray University, Faculty of Medicine, 68100, Aksaray, Turkey

Introduction and Purpose: In emergency departments, treatment delays in time-critical conditions directly impact morbidity and mortality. The potential of artificial intelligence–based decision support systems to accelerate clinical workflows is increasingly recognized. This study evaluated a simulation-based comparative analysis of different emergency department workflow models and the effect of ChatGPT as a decision-support tool on door-to-needle time (DTN).

Materials and Methods: This study was designed as a simulation-based comparative workflow analysis. Twenty standardized clinical scenarios representing time-critical conditions in adult emergency medicine (including ischemic stroke, acute coronary syndrome, sepsis, and other emergencies) were used. Each scenario was evaluated under three different workflow models: the standard emergency workflow, the optimized workflow, and the ChatGPT-assisted decision-support workflow.The primary outcome was simulated door-to-needle time (DTN, minutes). Data were analyzed using a repeated-measures framework. Group comparisons were performed using the Friedman test. When appropriate, pairwise comparisons were conducted using Wilcoxon signed-rank tests. Effect size was calculated using Kendall's W.

Results and Conclusion: Across 20 scenarios, mean DTN times were 72.2 ± 16.3, 51.3 ± 12.1, and 40.3 ± 10.2 minutes for the standard, optimized, and ChatGPT-assisted workflows, respectively. A statistically significant difference was observed among workflow models (Friedman test, $\chi^2(2)=38.6$; $p < 0.001$). Post-hoc analyses revealed statistically significant differences in all pairwise comparisons (all $p < 0.05$). The ChatGPT-assisted workflow achieved a 44.2% reduction in DTN compared with the standard workflow and a 21.3% reduction

compared with the optimized workflow. A large effect size was observed (Kendall's W=0.68).This simulation-based study demonstrates that a ChatGPT-assisted workflow may significantly reduce door-to-needle time in time-critical emergency department processes. These findings support the potential role of AI-based systems in accelerating clinical decision-making pathways. However, as the results are based on simulated data, external validation in real clinical settings is required.

Table 1. Workflow models and mean door-to-needle (DTN) times

Workflow	Mean DTN (min)	SD
Standard	72.2	16.3
Optimized	51.3	12.1
ChatGPT-assisted	40.3	10.2

This table presents the mean simulated door-to-needle times across three workflow models. The ChatGPT-assisted workflow demonstrated the lowest DTN, indicating the fastest performance.

Table 2. Relative reduction in DTN

Comparison	% Reduction
Optimized vs Standard	28.9% ↓
ChatGPT vs Standard	44.2% ↓
ChatGPT vs Optimized	21.3% ↓

This table shows the relative percentage reduction in door-to-needle time between workflow models. The greatest reduction was observed in the ChatGPT-assisted workflow compared with the standard model.

Table 3. Post-hoc Wilcoxon signed-rank tests

Comparison	p-value	Interpretation
Standard vs Optimized	<0.01	Significant
Standard vs ChatGPT	<0.001	Highly significant
Optimized vs ChatGPT	0.02	Significant

Post-hoc Wilcoxon signed-rank tests were used to assess pairwise differences between workflow models. All comparisons (Standard vs Optimized, Standard vs ChatGPT-assisted, and Optimized vs ChatGPT-assisted) were statistically significant ($p < 0.05$).

Keywords: Emergency Department; Simulation-Based Study; Door-to-Needle Time

---

Ref No: 8151

Beyond Acute Appendicitis: Crohn's Disease as a Mimicker of Right Lower Quadrant Pain

Ümmü Öksüz Apıdan[1], Ayla Mollaoğlu[1], Hilal Türk[1], Fadime Özyiğit Gök[1], Mehmet Gül[1]
[1]Emergency Medicine Department, Konya City Hospital, Türkiye
Fadime Özyiğit Gök / Emergency Medicine Department, Konya City Hospital, Türkiye

Introduction and Purpose: Acute abdominal pain is one of the most common reasons for emergency department admissions. Although acute appendicitis is primarily considered in cases of right lower quadrant pain, inflammatory bowel diseases should also be included in the differential diagnosis. Crohn's disease may present in the early stage with nonspecific clinical and radiological findings, and imaging studies may appear normal. This can lead to a delay in diagnosis.

Materials and Methods: Case:A 35-year-old male patient with a known history of hypertension presented with right lower quadrant pain and fever. On physical examination, defense and rebound tenderness were positive, and body temperature was 38°C. Laboratory evaluation revealed a leukocyte count of 15,000/mm³ and a C-reactive protein (CRP) level of 110 mg/L. Abdominal ultrasonography and computed tomography performed at an outside center had been reported as normal. In repeat imaging performed at our clinic, the appendix appeared normal, and no pathological findings were detected except for a few reactive lymph nodes at the level of the cecum. Since no acute surgical pathology was considered by the general surgery team, the patient was discharged. Three days later, the patient re-presented with hematochezia, and colonoscopy revealed diffuse aphthous ulcers in the colon. The findings were considered compatible with Crohn's disease or infectious colitis.

Results and Conclusion: Crohn's disease may clinically mimic acute appendicitis due to involvement of the terminal ileum and cecum. In the early stage, radiological findings may be minimal, and only elevated inflammatory markers may be observed. Even when imaging studies are normal, inflammatory bowel diseases should be considered in the differential diagnosis in the presence of a significant inflammatory response, and patients should be closely monitored.

Keywords: Crohn's disease, acute abdomen, inflammatory bowel disease

Ref No: 8155

Metformin-Associated Lactic Acidosis at Therapeutic Dosing

Liljana Isik[1], Banu Arslan[1]
[1]Basaksehir Cam and Sakura City Hospital
Liljana Isik / Basaksehir Cam and Sakura City Hospital

Introduction and Purpose: Background:Metformin is the main first-line medication for the treatment of type 2 diabetes mellitus (DM) and used daily by over 200 million patients worldwide. Metformin-associated lactic acidosis (MALA) is a rare but life-threatening complication typically linked to overdose or severe renal impairment. However, it may also occur at therapeutic doses, particularly during acute illness. Its diagnosis in the ED is challenging due to nonspecific symptoms and overlap with other causes of high anion gap metabolic acidosis (HAGMA).

Materials and Methods: Case Presentation:A 66-year-old woman presented to the ED with three days of nausea, vomiting, and anuria. Her medical history included hypertension and type 2 DM, treated with atenolol/chlorthalidone, amlodipine, gliclazide, and metformin at standard doses. She had no known chronic renal failure.On arrival, she was hypotensive (95/48 mmHg) and bradycardic (41–49 bpm), appearing critically ill and dehydrated. She was semi-oriented with a GCS of 14. Examination revealed dry mucous membranes and confirmed anuria via catheter. Cardiovascular exam showed bradycardia with weak peripheral pulses and delayed capillary refill. Respiratory, abdominal, and neurological examinations were otherwise unremarkable.Laboratory findings demonstrated markedly elevated urea, creatinine, potassium, and lactate levels. Initial arterial blood gas (ABG) analysis was unreadable for 14 hours due to severe derangement. Subsequent ABG revealed profound metabolic acidosis: pH 6.75, bicarbonate 2.7 mmol/L, pCO_2 19.7 mmHg, lactate 19 mmol/L, and base excess −32.5 mmol/L. Toxic alcohol levels were normal. Blood and urine cultures indicated no significant bacteria. The patient received aggressive IV fluids, vasopressor support for persistent hypotension, and intravenous sodium bicarbonate. Despite treatment, she remained oliguric with refractory acidosis and hyperlactatemia. She was admitted to the intensive care unit and underwent continuous renal replacement therapy (CRRT). However, her condition deteriorated, and she died three days later.

Results and Conclusion: Discussion:This case highlights that MALA can occur at therapeutic dosing, especially in the presence of acute kidney injury and dehydration, even without prior renal disease. Although renal replacement therapy aids lactate clearance, it does not guarantee survival.Conclusion:MALA should be suspected in metformin-treated patients presenting with unexplained HAGMA and elevated lactate. Early recognition, discontinuation of metformin, correction of underlying triggers, and timely renal support are critical to improving outcomes.

Keywords: MALA, metformin, EMERGENCY

Ref No: 8179

Concomitant diabetic ketoacidosis and cerebrovascular event: A case report

Harun Yahya Yıldırım[1], Betül Babagil[1], Muhammet Gökhan Turtay[1], Ahmet Çağlar[1], Gökhan Yılmaz[1], Birsen Ertekin[1]

[1]University of Health Sciences, Beyhekim Training and Research Hospital, Clinic of Emergency Medicine, Konya, Türkiye.

Muhammet Gökhan Turtay / University of Health Sciences, Beyhekim Training and Research Hospital, Clinic of Emergency Medicine, Konya, Türkiye.

Introduction and Purpose: This case report aims to emphasize that a concomitant cerebrovascular event should be considered in patients with diabetic ketoacidosis (DKA) presenting with altered consciousness.

Materials and Methods: A 69-year-old patient with known diabetes mellitus and hypertension was brought to the emergency department by relatives with complaints of confusion that had started six hours earlier, inability to recognize family members, and markedly elevated capillary blood glucose levels. Laboratory analysis revealed a blood glucose level of 592 mg/dL, potassium level of 5.2 mmol/L, and urine ketone positivity (2+). Arterial blood gas analysis showed a pH of 7.00 and a bicarbonate level of 6.2 mmol/L. Diffusion-weighted magnetic resonance imaging, obtained due to altered consciousness, demonstrated diffusion restriction in the left occipital region consistent with an infarction. Despite appropriate medical management, the patient developed severe metabolic acidosis and respiratory failure due to the coexistence of DKA and acute stroke and died on the seventh day of intensive care unit follow-up.

Results and Conclusion: The coexistence of acute ischemic stroke and DKA may have a fatal course, particularly in elderly diabetic patients. In patients diagnosed with DKA, the possibility of a concomitant cerebrovascular event should always be considered when altered consciousness is present.

Keywords: Cerebrovascular event, Diabetic ketoacidosis, Emergency

Ref No: 8211

Combined evaluation of halp score and sodium levels in ileus patients presenting to the emergency department

Elif Yaren Gundogdu[1], Ayse Isik Guven[1], Elif Betul Balci[1], Bahadir Taslidere[1], Basar Cander[1]

[1]Bezmialem Vakif University

Elif Yaren Gundogdu / Bezmialem Vakif University

Introduction and Purpose: Ileus is a common condition in emergency practice and its clinical course may vary from conservative follow-up to surgery. Early assessment of disease severity is therefore important. The hemoglobin, albumin, lymphocyte, and platelet (HALP) score reflects inflammatory and nutritional status, while serum sodium may also change in more severe clinical states. In this study, we aimed to evaluate the relationship between HALP score and serum sodium levels in patients diagnosed with ileus and to examine their clinical significance together.

Materials and Methods: This retrospective single-center study included 216 adult patients diagnosed with ileus between January 2019 and December 2024. Demographic data, laboratory findings, treatment characteristics, and clinical outcomes were recorded. HALP score was calculated from admission laboratory values. Serum sodium levels were analyzed, and the correlation between sodium and HALP score was assessed. Their relationship with clinical outcomes, including surgical treatment and length of hospital stay, was also evaluated.

Results and Conclusion: A weak but statistically significant positive correlation was found between serum sodium levels and HALP score (Spearman's rho = 0.250, $p < 0.001$). Lower sodium levels were associated with lower HALP values. Patients with low HALP scores and hyponatremia had a more severe clinical course, with higher surgical treatment rates and longer hospital stay. In addition, subgroup evaluation suggested that patients presenting with both electrolyte imbalance and impaired HALP parameters required closer monitoring and more frequent clinical reassessment during emergency department follow-up, supporting their role as combined indicators of clinical severity. These findings suggest that sodium level and HALP score may reflect related aspects of disease severity in ileus patients. Although sodium is not a component of the HALP score, evaluating these two parameters together may provide additional clinical information during the initial assessment in the emergency department.

Keywords: HALP score, sodium, hyponatremia

Ref No: 8226

Sick sinus syndrome presenting with recurrent symptomatic bradycardia: A case report

Şükran Rabia Yılmaz[1], Fatih İkiz[1], Muhammet Gökhan Turtay[1], Ahmet Çağlar[1], Birsen Ertekin[1], Muhammed Feyizoğlu[1]

[1]University of Health Sciences, Beyhekim Training and Research Hospital, Clinic of Emergency Medicine, Konya, Türkiye.

Muhammet Gökhan Turtay / University of Health Sciences, Beyhekim Training and Research Hospital, Clinic of Emergency Medicine, Konya, Türkiye.

Introduction and Purpose: In this report, we aimed to describe the diagnostic and management processes of sick sinus syndrome in a patient presenting with recurrent bradycardia.

Materials and Methods: A 41-year-old male patient presented to the emergency department complaining of sweating and the sensation of a slowed pulse. The patient had no known comorbidities. His medical history revealed that he had presented to another medical centre with similar complaints approximately two months earlier and had undergone coronary angiography, which demonstrated no significant coronary artery stenosis. The patient reported using acetylsalicylic acid. At presentation to the emergency department, his vital signs were as follows: oxygen saturation 97%, heart rate 61 beats/min, temperature 36.3°C, and blood glucose level 107 mg/dL. Electrocardiography demonstrated sinus rhythm. A detailed medical history revealed that the patient had presented to different emergency departments several times with similar complaints and had been discharged after evaluation revealed no acute pathology. The patient was placed under monitoring and laboratory tests were ordered. During monitoring, a sudden decrease in heart rate to approximately 20 beats/min was observed. During the bradycardia episodes, the patient exhibited marked somnolence and confusion. Based on the clinical findings and monitoring results, the preliminary diagnoses of sinus bradycardia and sick sinus syndrome were considered. The patient was referred to an external centre for further evaluation and assessment of the need for permanent pacemaker implantation. Laboratory test results that became available after the patient's referral showed that electrolyte levels and cardiac biomarkers, including troponin, were within normal limits.

Results and Conclusion: Sick sinus syndrome should be considered in the differential diagnosis of patients presenting with recurrent symptomatic bradycardia. Permanent pacemaker therapy significantly improves the prognosis in appropriately selected patients.

Keywords: Bradycardia, Pacemaker, Sick sinus syndrome

Ref No: 8244

Cardiac Arrest Across Three Settings: Duration of Cardiopulmonary Resuscitation and Clinical Outcomes in Home, Ambulance, and In-Hospital Cases

Ömer Faruk Çakıroğlu[1], Abdullah Yaser Güney[2], Jülide Gürbüz[3], Şeyma Nur Çalışır[2], Liljana Işık[2], Emre Kalkan[3], Ömer Faruk Öz[3], Elif Betul Balcı[3], Onur Bozdağ[3], Batuhan Galip Aydogdu[3], Hussein Alfakeer[5], Seda Koçak[4], Başar Halbuni[4], Sevil Kuşku Kıyak[4], Mehmet Koşargelir[2], Serap Biberoğlu[4], Bahadır Taşlıdere[3], Seda Özkan[4], Başar Cander[3]

[1]Kartal Dr Lutfi Kirdar Training and Research Hospital
[2]Basaksehir City Hospital
[3]Bezmialem Vakif University
[4]İstanbul Cerrahpasa University
[5]Health Sciences University

Şeyma Nur Çalışır / Basaksehir City Hospital

Introduction and Purpose: Cardiac arrest is a critical clinical condition characterized by the sudden loss of effective mechanical cardiac activity, leading rapidly to death if not promptly treated. Current guidelines recommend continuing advanced life support on scene rather than prioritizing immediate transport. This study aimed to investigate the impact of cardiopulmonary resuscitation (CPR) and advanced life support performed in different settings (home, ambulance, and hospital) on clinical outcomes and return of spontaneous circulation (ROSC).

Materials and Methods: This prospective multicenter cohort study included adults with in-hospital or out-of-hospital cardiac arrest who received CPR. Traumatic arrests, pregnant patients, and cases with missing data were excluded. CPR duration was defined as the time from the first chest compression to sustained return of spontaneous circulation. Clinical and resuscitation data were recorded prospectively. The primary outcome was 30-day survival, and the secondary outcome was neurological status at discharge. Outcomes were compared across home, ambulance, and hospital settings using appropriate statistical methods.

Results and Conclusion: In this multicenter prospective study, the median age of patients was 73 years (63.75–86.25), and the most common comorbidity was hypertension (52.2%). Arrest was witnessed in 84.8% of cases; however, the rate of bystander CPR remained low at 30.4%. Cardiac etiology accounted for 56.5% of arrests, 58.7% occurred at home, and 62.2% presented with non-shockable rhythms (asystole/pulseless electrical activity). The median CPR duration was 48.5 minutes, and the median total administered adrenaline dose was 10 mg. ROSC was achieved in 45.7% of patients. The 30-day mortality rate was 63.2%, while in-hospital mortality reached 70.7%.Statistical analyses demonstrated that CPR duration ($p < 0.001$), total adrenaline

dose (p=0.003), cardiac etiology (p < 0.001), history of coronary artery disease (p=0.004), and systolic/diastolic blood pressure at admission were significantly associated with ROSC. In contrast, arrest location (p=0.196) and the presence of ROSC did not show a statistically significant effect on 30-day mortality. Despite successful resuscitation, the high mortality rates likely reflect challenges in managing post-resuscitation complications, including multi-organ failure.

Keywords: resuscitation

Ref No: 8354

Recurrent Hemorrhagic Pericarditis and Cardiac Tamponade Associated with Mesalazine: An Immune-Mediated Adverse Drug Reaction

AHMET DURSUN DEMİR[1], YAVUZ ALPEREN SAYAR[1], LATİF DURAN[1]

[1]Department of Emergency Medicine, Ondokuz Mayıs University Faculty of Medicine, Samsun, Türkiye

YAVUZ ALPEREN SAYAR / Department of Emergency Medicine, Ondokuz Mayıs University Faculty of Medicine, Samsun, Türkiye

Introduction and Purpose: Mesalazine (5-aminosalicylate) is a cornerstone therapy in the management of inflammatory bowel diseases and is generally considered well tolerated. Nevertheless, rare but clinically significant immune-mediated cardiac adverse effects, including pericarditis, myocarditis, and pericardial effusion, have been described. Progression to hemorrhagic pericardial effusion and cardiac tamponade represents an exceptionally uncommon but potentially life-threatening manifestation.

Materials and Methods: A 24-year-old male with a known diagnosis of ulcerative colitis presented to the emergency department with a one-week history of progressively worsening dyspnea and chest pain. His past medical history was notable for a previous episode of pericardial effusion during mesalazine therapy two years earlier, which had resolved with medical management. On admission, he was tachycardic (123 bpm) and hypotensive (99/64 mmHg), while oxygen saturation remained normal. Physical examination revealed distant heart sounds. Laboratory investigations demonstrated elevated inflammatory markers with normal cardiac troponin levels.Bedside transthoracic echocardiography revealed a large circumferential pericardial effusion with right atrial collapse, consistent with cardiac tamponade. Emergency pericardiocentesis was performed, and 570 mL of hemorrhagic pericardial fluid was evacuated.

Fluid analysis demonstrated an exudative pattern according to Light's criteria, with high protein and lactate dehydrogenase levels. Microbiological cultures and cytological analysis were negative for infection and malignancy.Following discontinuation of mesalazine and initiation of colchicine-based anti-inflammatory therapy, the patient experienced rapid clinical improvement, with resolution of symptoms and a decline in inflammatory markers. The development of peripheral eosinophilia and recurrence of pericardial involvement upon prior exposure strongly supported an immune-mediated drug reaction and suggested a rechallenge phenomenon.

ECG

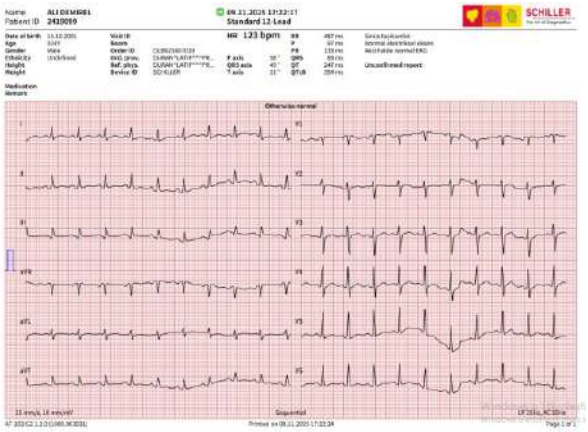

CT 1



CT 2



CT 3



CT 4



Results and Conclusion: Although uncommon, mesalazine may lead to severe cardiac complications such as recurrent hemorrhagic pericarditis and cardiac tamponade. Clinicians should maintain a high index of suspicion for drug-induced cardiotoxicity in patients with ulcerative colitis presenting with unexplained pericardial effusion. Early recognition, prompt discontinuation of the offending agent, and timely intervention are critical to prevent life-threatening outcomes.

Keywords: Mesalazine, Cardiac tamponade, Ulcerative colitis

Ref No: 8376

Cyanide intoxication: Three case reports

Feyza Sandal[1], Muhammet Gökhan Turtay[1], Fatih İkiz[1], Gökhan Yılmaz[1], Birsen Ertekin[1], Muhammed Feyizoğlu[1]

[1]University of Health Sciences, Beyhekim Training and Research Hospital, Clinic of Emergency Medicine, Konya, Türkiye.

Muhammet Gökhan Turtay / University of Health Sciences, Beyhekim Training and Research Hospital, Clinic of Emergency Medicine, Konya, Türkiye.

Introduction and Purpose: In this case series, we aim to present three patients who were exposed to cyanide gas following a fire at a recycling facility.

Materials and Methods: Three men, aged 18, 19, and 21, presented to our emergency department after being exposed to cyanide gas and carbon monoxide following a fire at a recycling facility. All three reported noticing a strange odor. Decontamination was performed in the Chemical, Biological, Radiological, and Nuclear (CBRN) unit. All patients were admitted to the toxicology intensive care unit. They received supportive treatment and hydroxocobalamin as an antidote. After 48 hours of observation, all patients, whose symptoms had subsided, were discharged in good health.

Results and Conclusion: It should be remembered that in patients presenting with hemodynamic instability and arrhythmias after fire/smoke inhalation, early decontamination, intensive supportive care, and early administration of hydroxocobalamin in appropriately selected patients, along with a high clinical suspicion, are crucial in the treatment of cyanide poisoning.

Keywords: Cyanide, Hydroxocobalamin, Intoxication

Ref No: 8438

Systemic Botulinum Toxin Toxicity After Endoscopic Intragastric Injection for Weight Loss

Ekim Sağlam Gürmen[1], Egecan Duman[1], Muhammet İkbal Şaşmaz[1]

[1]Manisa Celal Bayar University School of Medicine, Emergency Department, Manisa, Türkiye

Egecan Duman / Manisa Celal Bayar University School of Medicine, Emergency Department, Manisa, Türkiye

Introduction and Purpose: Botulinum toxin, the most potent biological toxin known, has become an important therapeutic agent in a wide range of clinical applications (1). It is increasingly used as a minimally invasive alternative for weight loss in patients with obesity. Although most adverse effects are mild and localized, systemic effects such as generalized weakness distant from the injection site have been reported (2). While botulinum toxin type A (BTX-A) therapy is generally considered safe and well tolerated, its short-term efficacy in obesity remains variable (3). This case aims to highlight a rare but clinically significant complication following endoscopic intragastric administration.

Materials and Methods: A 60-year-old female was admitted with dyspnea, diplopia, dysphagia, and generalized weakness after undergoing endoscopic intragastric botulinum toxin injection for weight loss. The procedure had been performed 10 days earlier, and her symptoms progressively worsened thereafter.Neurological examination revealed muscle strength of 4/5 proximally and 5/5 distally in the upper extremities. In the lower extremities, strength was 2/5 proximally and 4/5 distally. Laboratory tests and central nervous system imaging showed no significant abnormalities. Based on the clinical findings and recent history of botulinum toxin administration, systemic botulinum toxin effect was suspected.The patient was admitted to the intensive care unit for close monitoring and received botulinum antitoxin therapy.

Results and Conclusion: Systemic toxicity following endoscopic intragastric botulinum toxin injection is extremely rare. However, high doses, deep-layer injections, or inadvertent injection near vascular structures may increase the risk of systemic dissemination. In this case, as the procedure was performed at an external center, the precise mechanism of systemic involvement could not be determined.This case highlights that endoscopic intragastric botulinum toxin injection, although considered minimally invasive, may result in clinically significant systemic toxicity. Careful patient selection, appropriate dosing, and close post-procedural monitoring are essential to prevent delayed recognition of potentially life-threatening complications.

Keywords: Botulinum toxin, Intragastric injection, Obesity

Ref No: 8446

Clinic Outcomes of Plate-Screw Fixation in Open Forearm Fractures

Yener Yoğun[1], Hasan Emre Özsoy[2]

[1]Ankara Bilkent City Hospital, Department of Hand Surgery
[2]Ankara Bilkent City Hospital, Department of Orthopaedics and Traumatology

Hasan Emre Özsoy / Ankara Bilkent City Hospital, Department of Orthopaedics and Traumatology

Introduction and Purpose: Open forearm fractures are complex injuries typically resulting from high-energy trauma and are associated with complications such as infection, nonunion, and soft tissue defects. Although external fixation is commonly preferred as a temporary treatment, definitive management with plate-screw internal fixation may be considered when adequate debridement and soft tissue coverage can be achieved. This study aimed to evaluate the clinical and radiological outcomes of three cases with open forearm fractures treated with internal fixation.

Materials and Methods: Three patients with Gustilo-Anderson Type III open forearm fractures treated with plate-screw fixation between 2023 and 2025 were included. One patient, previously treated at another center with external fixation for an open radial shaft fracture, presented with infection and bone exposure (5×5 cm soft tissue defect). Following initial debridement, a two-stage Masquelet induced membrane technique (MIMT) was planned. After the first stage (antibiotic cement placement and plate fixation), soft tissue coverage was achieved with a groin flap. In the second stage, the flap was separated, the cement spacer removed, and iliac crest cancellous bone grafting was performed. The second patient, also referred with an external fixator and open wound infection, underwent debridement followed by the first stage of MIMT. After debridement fixation with plate-screw and antibiotic cement was performed, and coverage was achieved with a split-thickness skin graft. Approximately 5 weeks later, the second stage was completed. The third patient presented with a Type IIIB open fracture and underwent immediate open reduction and internal fixation. After soft tissue closure over the plate, skin grafting was performed. All patients were followed for soft tissue healing, union, and complications.

Figure 1



Clinical image demonstrating an open forearm fracture with a large soft tissue defect, and wound infection.

Figure 2



Anteroposterior radiograph of the forearm demonstrating comminuted open radius and ulna fractures with an external fixator performed as temporary stabilization.

Figure 3



Intraoperative image showing extensive debridement of devitalized bone and soft tissues. Postoperative radiograph demonstrating plate-screw fixation following antibiotic cement placement.

Table 1

Patient no	Age	Gender	Injury Mechanism	Follow up (month)	Complication
1	40	Male	High-energy fall	24	Superficial infection
2	36	Male	Press machine	12	
3	32	Female	Press machine	6	

Clinical and demographic characteristics of patients

Results and Conclusion: Bone union and soft tissue healing were achieved in all patients. One patient developed a superficial infection, which was successfully managed with two debridement procedures. No nonunion, deep infection, or implant-related complications were observed in the remaining patients.In open forearm fractures, internal fixation can be a safe and effective definitive treatment when adequate debridement and soft tissue coverage are achieved. With appropriate patient selection, successful outcomes can be obtained even in Gustilo-Anderson Type III injuries, potentially shortening the overall treatment duration.

Figure 4



Anteroposterior and lateral radiographs of the forearm demonstrate union of both the radius and ulna (red arrows).

Figure 5



Soft tissue healing is observed.

Keywords: Open forearm fractures, Internal fixation, Plate-screw fixation

Ref No: 8449

A bayesian diagnostic perspective in aortic dissection: a 12-year retrospective analysis of low-risk phenotypes using ADD-RS

Reşad Beyoğlu[1] [1]Onyedi Eylul University Faculty of Medicine

Reşad Beyoğlu / Onyedi Eylul University Faculty of Medicine

Introduction and Purpose: Aortic dissection is a life-threatening condition with high mortality, where early diagnosis remains challenging due to variable clinical presentation. Although sudden chest or back pain is considered a typical feature, a significant proportion of patients may present with less specific findings, leading to delayed diagnosis. The Aortic Dissection Detection Risk Score (ADD-RS) is commonly used to estimate pretest probability. However, the distribution of low-risk phenotypes among confirmed cases is not well defined. This study aimed to evaluate the retrospective distribution of ADD-RS in confirmed aortic dissection patients and to interpret diagnostic findings within a Bayesian framework.

Materials and Methods: This retrospective single-center study included 178 patients diagnosed with aortic dissection between October 2014 and October 2026. ADD-RS was calculated retrospectively based on available clinical data. During the same period, 12,036 patients underwent thoracoabdominal computed tomography angiography (CTA), and those without aortic dissection constituted the control pool. From this pool, 356 patients were randomly selected at an approximate 1:2 ratio to form the comparison group. Diagnostic performance measures, including sensitivity, specificity, and likelihood ratios, were calculated. Clinical findings and D-dimer results were further interpreted using a Bayesian diagnostic approach.

Results and Conclusion: The mean age was 61.2 years, and 71% of patients were male. Sudden chest and/or back pain was present in 74.3% of cases. D-dimer was elevated in 90.4% of patients. According to the Stanford classification, 58.4% were type A and 34.3% were type B dissections. In-hospital mortality was 27%. Retrospective ADD-RS analysis showed that 6.7% of patients had a score of 0, 37.6% had a score of 1, and 55.6% had a score greater than 1. Overall, 44.4% of confirmed cases fell into the low-to-intermediate risk group. D-dimer demonstrated high sensitivity (90.4%) and moderate specificity (64.9%), with a positive likelihood ratio of 2.58 and a negative likelihood ratio of 0.15. The combination of clinical risk assessment and D-dimer improved diagnostic performance. These findings suggest that a considerable proportion of aortic dissection patients may initially appear to be at low clinical risk. A Bayesian approach integrating clinical evaluation and biomarkers may enhance diagnostic accuracy and reduce missed diagnoses.

Keywords: Aortic dissection; Bayesian approach; D-dimer; ADD-RS

Ref No: 8454

Anaphylaxis or Endocrine Crisis? A Case of Pheochromocytoma Presenting with Shock

Enes Akınci[1], Sultan Tuna Akgöl Gür[1] [1]Atatürk University Research Hospital

Enes Akınci / Atatürk University Research Hospital

Introduction and Purpose: Anaphylaxis is a common and life-threatening emergency characterized by hypotension, tachycardia, and multisystem involvement. However, certain endocrine emergencies can present with similar clinical features, leading to potential misdiagnosis and inappropriate treatment.

Materials and Methods: A 38-year-old female was brought to the emergency department with complaints of sudden onset palpitations, severe headache, dizziness, and near-syncope. The symptoms started abruptly while she was at rest. Shortly after arrival, the patient developed hypotension and tachycardia, raising suspicion for anaphylactic shock. There was no history of recent drug intake, food exposure, or insect sting.On initial examination, the patient was anxious and diaphoretic. Blood pressure was 85/50 mmHg, and heart rate was 130 beats per minute. Oxygen saturation was 97% on room air. Physical examination revealed no urticaria, no angioedema, and no signs of airway compromise. Despite the absence of typical allergic findings, empirical treatment for anaphylaxis, including intravenous fluids and intramuscular epinephrine, was initiated.Following epinephrine administration, the patient's condition paradoxically worsened. She developed severe hypertension (220/110 mmHg), worsening headache, and persistent tachycardia. This unexpected response prompted reconsideration of the initial diagnosis.Further history revealed that the patient had experienced recurrent episodes of headache, palpitations, and sweating over the past several months, which had not been previously investigated. This triad raised suspicion for an underlying catecholamine-secreting tumor.Laboratory investigations and subsequent imaging studies supported the diagnosis of Pheochromocytoma, a rare endocrine tumor that can present with episodic or sustained hypertension and mimic various emergency conditions.The patient was managed with alpha-adrenergic blockade followed by beta-blockade under close monitoring. She was admitted to the intensive care unit and later referred for definitive surgical management.

Results and Conclusion: In conclusion, not all hypotension is due to anaphylaxis. Atypical features and paradoxical responses to treatment should prompt clinicians to reassess the diagnosis. Early recognition of pheochromocytoma is essential, as inappropriate management may lead to severe complications or fatal outcomes.

Keywords: Pheochromocytoma, anaphylaxis

Ref No: 8460

Case Report: Acute Ischemic Stroke with The Hyperdense MCA Sign

Onur Bozdağ[1], Elif Yıldız[2], Safiye Serra Erzurumluoğlu[3], Bahadır Taşlıdere[1], Başar Cander[1]

[1]Bezmialem Vakıf University. Emergency Department.
[2]Bezmialem Vakıf University, Medical Faculty.
[3]Bezmialem Vakıf University, Neurology Department.

Onur Bozdağ / Bezmialem Vakıf University. Emergency Department.

Introduction and Purpose: We present a case of acute ischemic stroke in a patient with a permanent pacemaker, where MRI could not be performed, and the diagnosis of MCA occlusion was established based on the hyperdense MCA sign and CT angiography findings. This case highlights the critical role of CT imaging in the early identification and management of large vessel occlusion when MRI is contraindicated.

Materials and Methods: A 65-year-old male patient presented to our emergency department with acute-onset vomiting while eating, followed by decreased level of consciousness, inability to hold his head up, and collapse to the left side. A permanent pacemaker was implanted 15 years ago, with generator replacement performed every five years.Neurological examination revealed a Glasgow Coma Scale (GCS) score of 9. Pupils were isochoric and reactive to light bilaterally. The oculocephalic reflex was present. There was no forced gaze deviation. A flattening of the left nasolabial fold was noted. The right extremities demonstrated spontaneous movements, whereas the left extremities showed early drift on motor examination. The National Institutes of Health Stroke Scale (NIHSS) score was 17. Brain CT showed no evidence of intracranial hemorrhage; however, a hyperdense artery sign was observed in the right MCA M1 segment. On CT angiography, occlusion of the right MCA M1 segment was confirmed. MRI could not be performed due to the patient's permanent pacemaker. As the timing of the patient's last warfarin dose was unknown, intravenous thrombolysis with tPA was not administered. After consultation with interventional radiology, a decision was made to proceed with thrombectomy.

Results and Conclusion: This case highlights the critical role of non-contrast CT in the early diagnosis of acute ischemic stroke, especially in patients with a permanent pacemaker in whom MRI cannot be performed. In acute stroke, rapid imaging is essential for timely treatment decisions. In this patient, the hyperdense MCA sign on the initial CT scan was an early and important finding that suggested large vessel occlusion. Careful evaluation of early CT findings is essential, as recognition of the hyperdense MCA sign can directly affect patient outcomes.

Keywords: Acute ischemic stroke, Hyperdence MCA sign, Thrombectomy

Ref No: 8466

Sepsis in the emergency department, procalcitonin, rapid diagnosis paradigm: Report on the literature

Merih Şimşek[1], Levent Şahin[2]
[1]Afyonkarahisar Health Sciences University, Faculty of Medicine, Department of Medical Microbiology, Afyon, Turkey
[2]Kafkas University, Faculty of Medicine, Department of Emergency Medicine, Kars, Turkey
Merih Şimşek / Afyonkarahisar Health Sciences University, Faculty of Medicine, Department of Medical Microbiology, Afyon, Turkey

Introduction and Purpose: In severe sepsis cases, a clinical picture resulting in death can be seen, accompanied by septic shock along with at least one organ dysfunction and hyperfusion. In sepsis, various defense mechanisms are activated in the bloodstream, leading to an inflammatory response. Immune cells secrete inflammatory proteins, and thus the clinical picture progresses to tissue damage and organ failure. In rapid diagnosis, procalcitonin (PCT) is an important biomarker for blood infections and inflammatory response. In this context, the aim of this study is to evaluate the role and accuracy of PCT as a biomarker in the diagnosis of septic patients in emergency departments (EDs).

Materials and Methods: A retrospective worldwide literature review revealed that many biomarkers are used in the rapid diagnosis of sepsis. An electronic database search showed that PCT ranked first in rapid diagnosis.

Results and Conclusion: In the diagnosis of sepsis, pathogenic antigens to be serologically tested in blood are important biomarkers. Among the biomarkers of host response are CRP, lactate, and PCT. However, since CRP and lactate can show significant increases in different complications, it has been emphasized that PCT is relatively more useful. Worldwide studies have reported high PCT levels as a significant indicator of bacterial infections. The rate and degree of PCT increase provide important clues to the emergency room physician about which patient will die and which patient will be admitted to intensive care. PCT provides the opportunity to create a sepsis management algorithm in ED. While bacterial and host response biomarkers alone do not provide a definitive diagnosis for sepsis, they play a guiding role in the rapid diagnosis and treatment of the disease. A definitive diagnosis of sepsis should be made by evaluating the patient's history, physical examination, and multiple diagnostic tests. Therefore, blood cultures should always be taken for sepsis diagnosis, and two or more biomarkers should be used in conjunction with them. Among biomarkers, PCT is a good option for aiding in rapid diagnosis. It is thought that the use of PCT, especially in critical care settings such as emergency departments where assessments are repeated, would be beneficial as a stepping stone to rapid diagnosis.

Keywords: Procalcitonin, sepsis, rapid diagnosis

Ref No: 8470

More than Just a name: implementing "John Doe" protocols in a critically injured patient

Mithat Furkan Toruk[1], Fatih Cemal Tekin[1], Hasan Yıldız[1], Nazlı Karakuş Kenan[1], Mehmet Gül[1]

[1]Emergency Medicine Department, Konya City Hospital, Türkiye

Hasan Yıldız / Emergency Medicine Department, Konya City Hospital, Türkiye

Introduction and Purpose: Emergency departments are the initial point of presentation for "unidentified patients" (John/Jane Doe) who lack identification cards, have uncertain social security, and are unable to communicate. In these cases, it is of vital importance that bureaucratic processes do not supersede medical intervention.

Materials and Methods: Male patient, estimated to be approximately 35-years old, was transferred to our emergency department by emergency medical services (EMS) from the scene following a fall from a height. The medical management of the patient, who had no identification documents on his person and from whom a sufficient anamnesis could not be obtained, was initiated within seconds under "unidentified patient" protocols. Upon initial clinical evaluation, his Glasgow Coma Scale(GCS) score was 15, and his hemodynamic parameters were stable. However, a detailed physical examination revealed a 4-cm laceration extending to the bone in the right frontal region, diffuse abrasions in the right zygomatic area, and a significant deformity disrupting anatomical integrity accompanied by local tenderness in the right wrist.In accordance with the multitrauma protocol, all laboratory and radiological examinations were ordered simultaneously using a temporary barcode, without waiting for the patient's identification to be established. The patient was found to have an inner table fracture of the right frontal bone, minimal pneumocephalus indicating intracranial air accumulation, T3-T4 spinous process fractures, and a displaced fracture of the distal right radius. After an 8-day clinical observation period postoperatively, the patient achieved stability; his basic needs were met in coordination with the Psycho-Social Support unit, and he was safely discharged.

Results and Conclusion: Lack of identification is not a reason for delay but an alarm that heightens ethical sensitivity. Not delaying medical care is the most fundamental factor in preventing mortality. In conclusion, an unidentified status does not constitute an indication to postpone medical care. The "blank space in the file" is, medically speaking, merely the absence of a name, and this absence must never be allowed to act as a barricade against the patient's

sacrosanct "right to life." The successful coordination in this case serves as an ethical exemplar, demonstrating that even an unidentified individual can fully benefit from all the resources of modern medicine.

Keywords: Emergency Department, Unidentified Patient, Multitrauma; Ethics

---

Ref No: 8516

Open-Book Pelvic Fracture in a Severe Polytrauma Patient Following a Fall from Height: A Case Report

Asel Hale Pilgeci[1], Onur Bozdağ[2], Elif Yıldız[1], Bahadır Taşlıdere[2], Başar Cander[2]

[1]Bezmialem Vakıf University, Medical Faculty.
[2]Bezmialem Vakıf University, Emergency Department.

Onur Bozdağ / Bezmialem Vakıf University, Emergency Department.

Introduction and Purpose: We present a case of a young female patient with severe multiple traumas following a fall from height, highlighting the presence of an open-book pelvic fracture with profound hemodynamic instability and a complex ICU course with delayed in-hospital mortality.

Materials and Methods: A 32-year-old female was admitted to our emergency department with multiple trauma following a fall from a fourth-floor window. On arrival, the patient was in critical condition with unstable vital signs and impaired consciousness. Neurological examination revealed a Glasgow Coma Scale (GCS) score of 3. Pupils were anisocoric with reduced light reflex (IR −2/−3). Initial vital signs indicated severe hemodynamic instability with blood pressure (BP) ranging from 40–110/20–61 mmHg, heart rate between 120–145 beats per minute, and oxygen saturation was 98–99% under mechanical ventilation. Cranial CT revealed pneumocephalus, subarachnoid hemorrhage and multiple craniofacial fractures. Radiological findings were also consistent with diffuse cerebral edema, including sulcal effacement, ventricular compression, and approximately 7 mm midline shift. Abdominopelvic CT revealed an approximately 2 cm mesenteric hematoma and minimal intra-abdominal free fluid within the pelvis and the Retzius space.Pelvis CT findings were consistent with an Open Book Pelvic Fracture, including symphysis pubis diastasis, widening of the right sacroiliac joint, and displaced fractures of the right superior and inferior pubic rami. The patient was managed in the intensive care unit. Due to severe traumatic brain injury and multisystem trauma, surgical intervention was not performed by neurosurgery and orthopedics teams. Conservative

management included sedation, mechanical ventilation, and antibiotic therapy. Importantly, a hammock sling traction was applied as a non-invasive method for stabilization of the open-book pelvic fracture and reduction of pelvic volume.Despite intensive care management, on hospital day 12, the patient developed cardiac arrest with absence of pulse and blood pressure. Cardiopulmonary resuscitation was initiated with chest compressions, however the patient could ot be resuscitated and was pronounced dead.

Results and Conclusion: In this case, the patient presented with profound hypotension and severe metabolic acidosis, consistent with shock physiology in the setting of major polytrauma. Although the pelvic fracture likely contributed to the initial instability, severe traumatic brain injury, bilateral pneumothorax, and multiple fractures indicate a multifactorial clinical course.

Keywords: Multiple Trauma, Open-Book Pelvic Fracture, Hemodynamic Instability

---

Ref No: 8534

Chest Pain and Elevated Troponin in Pregnancy: Diagnostic Challenges of Mild Pericarditis

Tunay Arıcı[1], Saniye Göknil Arı[1], Hakan Ateş[1], Yasin Yıldız[1], Mehmet Gül[1]

[1]Emergency Medicine Depatment, Konya City Hospital, Türkiye

Hakan Ateş / Emergency Medicine Depatment, Konya City Hospital, Türkiye

Introduction and Purpose: Pericarditis during the second trimester of pregnancy is a rare condition, and its management requires consideration of both maternal and fetal safety. In this case report, we present a 26-year-old patient at 16 weeks of gestation who was admitted with chest pain following an upper respiratory tract infection.

Materials and Methods: Case: A 26-year-old woman at 16 weeks of gestation presented to the emergency department with a 5-day history of chest pain, which worsened when lying down. She had no dyspnea, cough, or fever, but reported a recent upper respiratory tract infection. Vital signs were as follows: blood pressure 107/73 mmHg, heart rate 85 beats/min, SpO_2 99%, and temperature 36.7°C. Physical examination was unremarkable. Laboratory findings showed elevated troponin levels (initially 66 ng/L, then 64 ng/L, and subsequently 38 ng/L; upper limit: 14 ng/L), CRP 7 mg/L (upper limit: 5), WBC 15,000/µL, and hemoglobin 9.2 g/dL. ECG demonstrated normal sinus rhythm. In imaging and consultations: Cardiology evaluation revealed an ejection fraction of 65% on echocardiography, with normal right heart and valvular

structures; a preliminary diagnosis of pericarditis was considered. Obstetrics evaluation showed no pathological findings; daily fetal heart rate monitoring was recommended. In management and follow-up, no medical therapy was initiated due to teratogenic risk. The patient's symptoms improved during observation, and she was discharged with recommendations.

Results and Conclusion: Pericarditis in pregnancy is rare, and diagnosis—especially in the second trimester—can be challenging. Viral pericarditis generally has a mild course and may respond to medical therapy. However, in pregnancy, nonsteroidal anti-inflammatory drugs and other treatments may carry teratogenic risks. Therefore, in mildly symptomatic cases, a conservative approach with close follow-up may be a safe option. Elevated troponin levels reflect the inflammatory response, and the patient's hemodynamic stability influenced the treatment decision. This case demonstrates that mild probable viral pericarditis in the second trimester of pregnancy can be managed with close monitoring without the need for medical therapy. A multidisciplinary approach is essential in pregnant patients presenting with cardiac symptoms. Our case suggests that a conservative approach may be safe in the management of mild pericarditis during pregnancy.

Keywords: pregnancy, Pericarditis, troponin

Ref No: 8610

Perimyocarditis

Tulay Oskay[1], Mert Ozen[2]

[1]Denizli State Hospital, Cardiology Division
[2]Pamukkale University, School of Medicine, Department of Emergency Medicine

Mert Ozen / Pamukkale University, School of Medicine, Department of Emergency Medicine

Introduction and Purpose: Perimyocarditis is the inflammation of both the pericardium and myocardium, most commonly caused by viral infections. Its diagnosis is largely based on clinical suspicion. Electrocardiographic ST-segment elevation and elevated troponin levels can mimic acute myocardial infarction (MI), particularly in young male patients. Early recognition is crucial to avoid unnecessary invasive interventions.

Materials and Methods: A 19-year-old male presented to the emergency department with stabbing, pressure-like chest pain that woke him from sleep. During his first visit, his Troponin T level was significantly elevated (10 times normal) and rising, but his symptoms resolved, and he was discharged. Approximately 10 hours later, he returned with recurrent chest pain. His

physical examination and medical history were unremarkable, with no cardiovascular risk factors. Vital signs were stable: blood pressure 127/79 mmHg, heart rate 86 bpm, and oxygen saturation 98%. Laboratory tests showed elevated Troponin T (1140–1302 ng/L), CRP (36 mg/L), and LDH (275 U/L). While his initial ECG was normal, the repeat ECG demonstrated non-reciprocal ST elevation in leads D1-AVL (Figure 1). Echocardiography revealed normal ejection fraction and no wall motion abnormalities. Coronary angiography was normal, leading to a diagnosis of perimyocarditis.

Figure 1. Patient's ECG

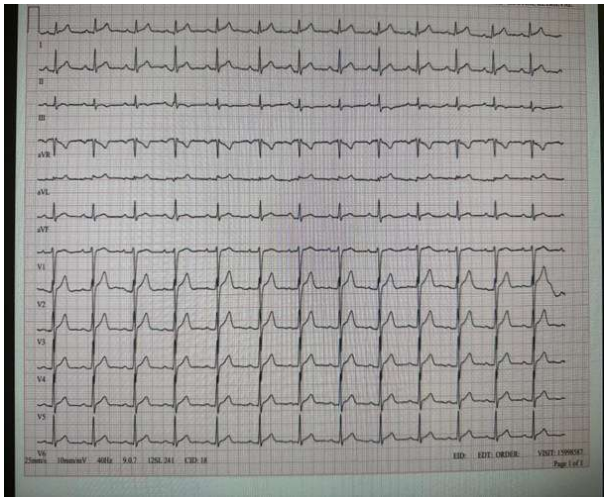

Results and Conclusion: Perimyocarditis can closely resemble acute MI, especially in young individuals, making differential diagnosis challenging. Although ST elevation and elevated troponin levels often suggest MI, factors such as young age, absence of risk factors, diffuse ECG changes, and normal coronary arteries support perimyocarditis. Cardiac MRI findings, including myocardial edema, late gadolinium enhancement, pericardial thickening, and lack of correlation with coronary artery territories, further confirm the diagnosis. Treatment typically includes nonsteroidal anti-inflammatory drugs, colchicine, and physical activity restriction. The condition is usually benign but may lead to complications such as arrhythmias, heart failure, or sudden death.In young patients presenting with chest pain, ST elevation does not always indicate MI. Considering perimyocarditis and using cardiac MRI for diagnosis can help prevent unnecessary invasive procedures like thrombolytic therapy and coronary angiography.

Keywords: chest pain, emergency department, perimyocarditis

Ref No: 8631

Wellens syndrome ıdentified through atypical presenting complaints: A case report

Fırat Okta[1], Alten Oskay[1]

[1]Pamukkale University, Faculty of Medicine, Department of Emergency Medicine

Alten Oskay / Pamukkale University, Faculty of Medicine, Department of Emergency Medicine

Introduction and Purpose: Wellens syndrome is an electrocardiographic pattern defined by biphasic or deeply symmetric T-wave inversions detected on electrocardiography (ECG), particularly in the precordial leads, most commonly in V2 and V3, and is most often associated with a recent history of resolved chest pain. These findings are clinically important because they suggest the presence of critical stenosis in the left anterior descending artery (LAD). In the European Society of Cardiology (ESC) Acute Coronary Syndrome guideline, Wellens syndrome is considered within the spectrum of acute coronary syndromes without persistent ST-segment elevation or other findings of acute coronary occlusion. Although the underlying mechanism is thought to be spontaneous reperfusion following transient occlusion of the LAD, the restored coronary perfusion is unstable. Therefore, these patients are at high risk for advanced ischemia and extensive anterior myocardial infarction and require an invasive approach.

Materials and Methods: A 67-year-old man presented to the emergency department at 05:30 with sore throat, weakness, and bilateral upper extremity weakness. Two days earlier, he had visited his family physician for an upper respiratory tract infection, but reported no improvement despite treatment. Notably, the area he described as throat pain corresponded to the infraglottic region. Vital signs at presentation are shown in Table 1. Because he was hypertensive and distressed, an electrocardiography (ECG) was obtained. The initial ECG is presented in Figure 1. As the findings were considered potentially compatible with Wellens syndrome, cardiology consultation was requested. A follow-up ECG obtained during observation is shown in Figure 2. Serial ECG changes were interpreted by the cardiology team in favor of ST-segment elevation myocardial infarction (STEMI), and coronary angiography was recommended. Owing to full occupancy of our hospital's coronary intensive care unit, the patient was transferred to another center for angiography.

Figure 1. Initial electrocardiogram

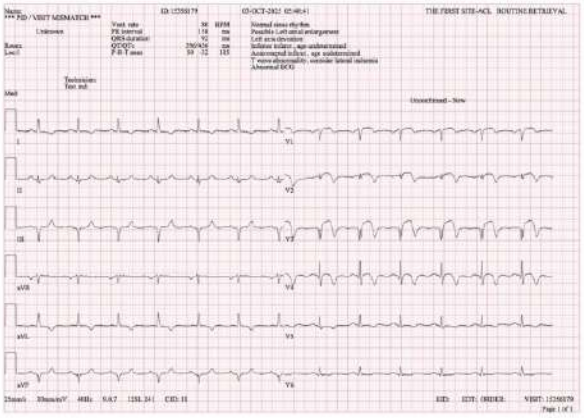

Figure 2. Follow-up electrocardiogram

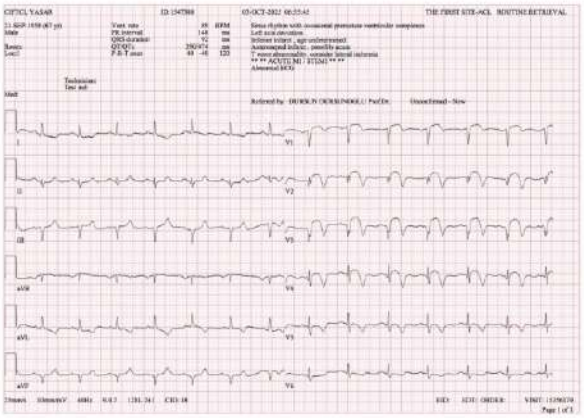

Table 1. The patient's vital signs on arrival

Blood Pressure	Heart Rate	Body Temperature	Fingertip Oxygen Saturation	Respiratory Rate
219/141 mmHg	84 beats/min	36.1 °C	97 %	*** breaths/min

Results and Conclusion: In elderly patients, detailed history-taking and careful physical examination are of fundamental importance in the diagnostic evaluation process. This case demonstrates that, particularly in patients presenting with atypical complaints, a holistic

assessment of the depth of history-taking together with physical examination findings may be lifesaving in reaching the correct diagnosis and planning appropriate treatment in a timely manner.

Keywords: Wellens syndrome, Acute coronary syndrome, Atypical symptom

---

Ref No: 8649

Evaluation of Clinical and Laboratory Findings in Pediatric Electrical Injuries: An Emergency Department-Based Retrospective Study

İsmail Akçalı[1]

[1]Malatya Turgut Özal University, Faculty of Medicine, Department of Emergency Medicine

İsmail Akçalı / Malatya Turgut Özal University, Faculty of Medicine, Department of Emergency Medicine

Introduction and Purpose: Electrical injuries in children, although relatively uncommon, can lead to significant morbidity and occasionally life-threatening complications. Most cases are caused by low-voltage household exposure, while high-voltage injuries are associated with more severe outcomes. Clinical presentation may be variable, and some patients can remain asymptomatic at initial evaluation despite the risk of delayed complications. This study aimed to evaluate the association between demographic characteristics, clinical features, and laboratory findings with hospitalization status in pediatric patients presenting with electrical injuries.

Materials and Methods: This retrospective observational study included 37 patients under 18 years of age who presented to the emergency department between January 2025 and January 2026. Demographic data, hospitalization status, and laboratory parameters, including albumin, amylase, C-reactive protein (CRP), complete blood count components, and inflammatory indices such as CRP/albumin ratio (CAR) and lymphocyte/albumin ratio (LAR), were recorded. Statistical analyses were performed to compare hospitalized and non-hospitalized patients.

Results and Conclusion: Of the patients, 75.7% were male, and 59.5% required hospitalization. Age was significantly lower in hospitalized patients ($p=0.044$). No significant differences were observed between groups regarding laboratory parameters, including CRP, albumin, WBC, platelet count, or inflammatory indices ($p > 0.05$). Hemoglobin levels were lower in hospitalized patients; however, this difference did not reach statistical significance ($p=0.065$).Younger age appears to be associated with an increased likelihood of hospitalization in pediatric electrical

injuries, whereas routine laboratory parameters show limited prognostic value. These findings highlight the importance of careful clinical assessment and close monitoring rather than relying solely on laboratory results in the management of such patients.

Keywords: Pediatric electrical injury, Hospitalization, Prognosis

---

Ref No: 8692

Massive pulmonary embolism in a patient with glioblastoma multiforme: Clinical presentation and management

Ceren Efsane Kellecioğlu[1], Betül Babagil[1], Muhammet Gökhan Turtay[1], Gökhan Yılmaz[1], Birsen Ertekin[1], Harun Yahya Yıldırım[1]
[1]University of Health Science, Beyhekim Training and Research Hospital, Clinic of Emergency Medicine, Konya, Türkiye.
Muhammet Gökhan Turtay / University of Health Science, Beyhekim Training and Research Hospital, Clinic of Emergency Medicine, Konya, Türkiye.

Introduction and Purpose: In this case report, we present a case of massive pulmonary embolism that developed in a patient diagnosed with glioblastoma multiforme.

Materials and Methods: A patient who had undergone surgery for glioblastoma multiforme and was receiving chemotherapy presented to our emergency department with complaints of right leg swelling and acute dyspnea. Physical examination revealed pretibial oedema in both legs, with the right leg more swollen than the left and a noticeable difference in circumference. Laboratory results were as follows: C-reactive protein 92.4 mg/L, procalcitonin 0.09 ng/mL, D-dimer 3.170 µg/mL, urea 35 mg/dL, creatinine 0.51 mg/dL, and glomerular filtration rate 108 mL/dak/1.73 m^2. Arterial blood gas analysis showed pH 7.544, pO2 70 mmHg, pCO_2 29.9 mmHg, HCO_3 25.2 mEq/L, and lactate 2.72 mmol/L. Computed tomography pulmonary angiography was performed. It demonstrated a saddle-type massive pulmonary embolism extending into all lobar and segmental branches of the bilateral distal pulmonary arteries, partially obstructing blood flow. Based on these clinical findings and diagnostic results, the patient was consulted with the pulmonology department and admitted to the pulmonary intensive care unit.

Results and Conclusion: Patients with glioblastoma multiforme represent a high-risk group for venous thromboembolism. Pulmonary embolism should always be considered and ruled out in the presence of sudden dyspnea and extremity swelling.

Keywords: Dyspnea, Glioblastoma multiforme, Pulmonary embolism

Ref No: 8709

Contribution of emergent ultrasonography protocol to diagnose in cases considered COVID-19

Resmiye Nur Okudan Kıldan[1]

[1]Health Sciences University, Antalya Training and Research Hospital

Resmiye Nur Okudan Kıldan / Health Sciences University, Antalya Training and Research Hospital

Introduction and Purpose: The pathological changes seen in COVID-19 are particularly suitable for evaluation with focused bedside ultrasonography (FBUSG) due to their peripheral and peripleural location. Studies have shown that the "focused 6-zone imaging protocol (F6ZIP)" is rapid and prioritizes reducing transmission due to the practitioner-patient position. Therefore, we decided to test the validity of this protocol in our own clinic. In this protocol, unlike other protocols, the patient sits with their back to the practitioner. The main point is to reduce contact and droplet exposure thanks to this position.The primary outcome was the diagnostic value of F6ZIP. The secondary outcome was the consistency between FBUSG and computed tomography (CT) and/or Real Time Polymerase Chain Reaction (RT-PCR) test results for COVID-19 diagnosis. We applied an emergent ultrasonography protocol (EUP), in which the patient is sitting position and the lung parenchymal tissue is evaluated from only 6 different regions, to reduce the risk of droplet transmission to the practitioner.

Materials and Methods: This prospective observational clinical study included 50 patients who presented to the ED suspected of COVID-19. All participants underwent thorax CT, EUP and RT-PCR test, but the reference diagnostic method was determined as thorax CT.

Results and Conclusion: According to EUP, 52% of the patients (n=26) were evaluated as COVID-19 pneumonia. However, EUP was found to be false positive in 2 patients and false negative in 3 patients. Accordingly, the sensitivity of EUP was calculated as 96.3%, specificity as 89.6%, positive predictive value as 94%, and negative predictive value as 86.6%. EUP performed in the ED for suspected COVID-19 diagnosis has high sensitivity and specificity, and EUP application may preferred.

Some imaging examples of COVID-19 patients.

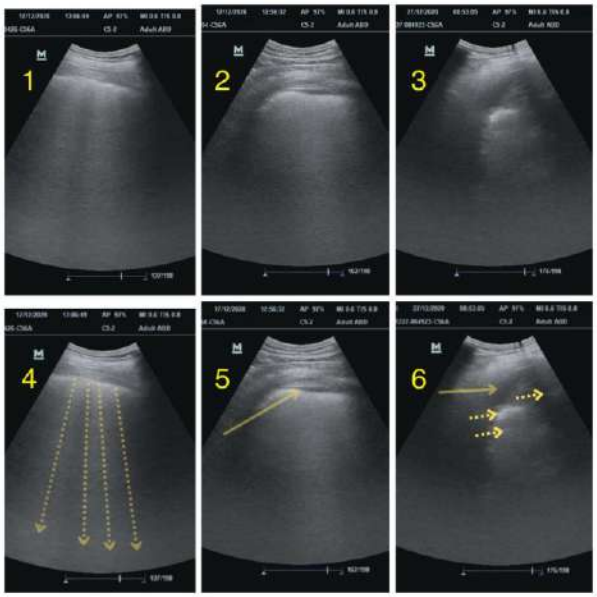

(1, 4) Dashed yellow arrows indicate the increase in B lines. (2, 5) The yellow continuous arrow indicates subpleural consolidation. (3, 6) Solid yellow arrows indicate consolidation, while multiple dashed yellow arrows indicate air bronchograms.

Anatomy and scanning technique for Bedside Ultrasonography (B-USG) in patient with suspected COVID-19.

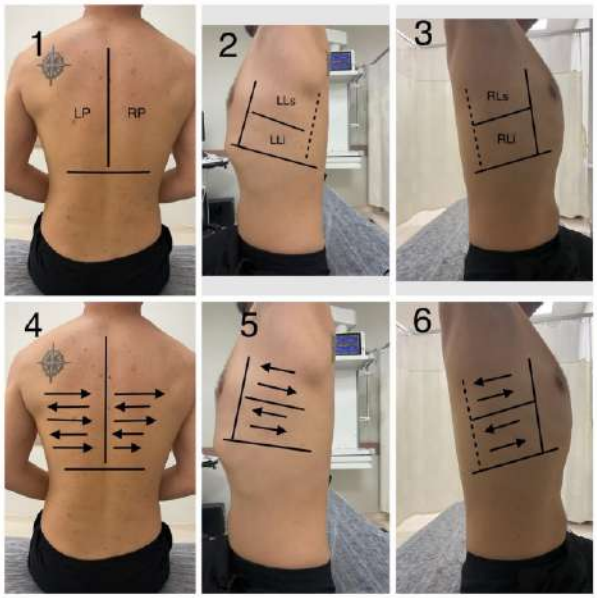

(1) Landmarks for scanning include the inferior thorax at the level of the diaphragm, the spine, the scapula, and the posterior axillary line. Lung zones to be scanned include the areas under the scapula border known as the right posterior (RP) and left posterior (LP) zones. Laterally, landmarks include the posterior axillary line to the anterior axillary line. Lateral lung zones to be scanned include the right lateral superior (RLs) and (3) right lateral inferior (RLi), and on the left include the left lateral superior (LLs), and (2) left lateral inferior (LLi). (4) To obtain scans, position a linear or curvilinear probe sagittal with probe marker cranially to the patient and slide the probe across the posterior surfaces. Repeat this technique in the (6) right and (5) left lateral zones.

Findings on FL-USG lung for COVID-19 pneumonia

Finding	n (%)
Pleural thickening	43 (86%)
Pleural irregularity	38 (76%)
Increase/convergence of B lines	37 (74%)
Subpleural consolidation	26 (52%)
Pleural effusion	18 (36%)
Hepatization	8 (16%)
Absence of pleural sliding movement	4 (8%)
Air bronchograms	3 (6%)

FL-USG: Focused Lung Ultrasonography, n: number

Test characteristics of FL-USG in diagnosing COVID-19 pneumonia.

	Value	95% CI
Sensitivity	96,3	81,30-99,91%
Specificity	89,6	86,60-94,20%

Positive likelihood ratio	0,03	0,01-,028
Negative likelihood ratio	5,54	3,7-9,4
Positive predictive value	94	84,40-98,20%
Negative predictive value	86,6	79,10-90,30%

FL-USG: Focused Lung Ultrasonography, CI: Confidence Interval

Keywords: COVID-19, diagnose, ultrasonography

Ref No: 8782

Hemostatic resuscitation in proximal upper extremity amputations: The critical role of REBOA and XABCDE approach

Türkan Yıldız[1]

[1]Niğde Ömer Halisdemir University Training and Research Hospital, Department of Emergency Medicine

Türkan Yıldız / Niğde Ömer Halisdemir University Training and Research Hospital, Department of Emergency Medicine

Introduction and Purpose: Proximal upper extremity amputations, particularly at the axillary level, present a significant challenge in trauma management as they occur in non-compressible junctional zones where standard tourniquets cannot be applied. In pediatric patients, high physiological reserves may mask the severity of "silent bleeding" until sudden exsanguination occurs. This case study aims to emphasize the life-saving importance of prioritizing the XABCDE algorithm over traditional ABC and the potential role of REBOA (Zone 1) in proximal injuries.

Axillary Amputation



Materials and Methods: A case of a 15-year-old male worker whose right arm was amputated after being caught in a plastic crushing machine was retrospectively analyzed. Clinical data, pre-hospital intervention, and the emergency department resuscitation process were evaluated in the light of Tintinalli's Emergency Medicine and ATLS 10th Edition guidelines.

Results and Conclusion: The patient arrived intubated and in asystole following one hour of CPR at an external center. Physical examination revealed a total axillary amputation with the arterial stump retracted deep into the pectoral muscles, rendering external compression ineffective. Despite aggressive packing (X), O Rh (-) blood replacement, and advanced cardiac life support, the patient was declared dead due to "empty heart" syndrome. This outcome underscores that chest compressions are futile without achieving hemostasis in massive hemorrhage. In junctional traumas where external control is impossible due to anatomical retraction, REBOA (Resuscitative Endovascular Balloon Occlusion of the Aorta) serves as an "endovascular tourniquet" to redirect volume to the brain and heart. For patients with high salvage potential, aggressive vascular control—either through REBOA or resuscitative thoracotomy for aortic clamping—must be initiated immediately to fill the "empty tank" before standard ACLS protocols.

Keywords: Axillary Amputation, REBOA, XABCDE

Ref No: 8784

Analysis of Clinical, Neurological, and Imaging Findings in Vertigo Patients in the Emergency Department

ÖMER TURALİOĞLU[1], ERDAL TEKİN[1] [1]Atatürk University
ERDAL TEKİN / Atatürk University

Introduction and Purpose: Differentiating peripheral and central causes in patients presenting to the emergency department with dizziness is a critical step that directly influences clinical management. However, especially under the demanding conditions of a busy emergency department, central pathologies may be overlooked. The aim of this study is to identify the key parameters predicting central vertigo by analyzing the clinical characteristics, neurological examination findings, vestibular test results, and imaging data of patients presenting to the emergency department with vertigo.

Materials and Methods: In this prospective observational study, a total of 140 patients presenting to the emergency department with acute vertigo were included. Patients were divided into two groups according to the final diagnosis: peripheral vertigo (n=86) and central vertigo (n=54). All cases were evaluated in terms of age, sex, vital signs, presenting complaints, physical examination findings, neurological assessment, vestibular tests, and diffusion MRI results. In particular, the diagnostic contributions of gait disturbance, speech impairment, cerebellar findings, Dix–Hallpike test results, and neurological deficits were analyzed.

Results and Conclusion: A total of 140 patients presenting to the emergency department with acute vertigo were included in the study. Of these, 86 patients (61.4%) were classified as peripheral vertigo and 54 patients (38.6%) as central vertigo. In the clinical comparison, gait disturbance, speech impairment, focal neurological deficits, ataxia, dysmetria, and other cerebellar findings were significantly more frequent in the central vertigo group. In particular, an ataxia rate of 42.6% and a neurological deficit rate of 20.4% emerged as strong distinguishing indicators of central pathologies. In addition, vertical nystagmus was more common in the central group, whereas horizontal nystagmus predominated in peripheral vertigo.In the peripheral vertigo group, tinnitus, ear fullness, positive Dix–Hallpike test results, and response to the Epley maneuver were significantly more frequent. Notably, a Dix–Hallpike positivity rate of 45.3% ($p < 0.001$) provided strong diagnostic support for peripheral vestibular pathologies. These findings support the importance of vestibular maneuvers in diagnosing peripheral vertigo, although they are not sufficient alone to exclude central causes. Tinnitus, ear fullness, and a positive Dix–Hallpike test favored peripheral etiology, whereas gait disturbance, ataxia, speech impairment, and focal neurological deficits strongly predicted central pathology.

Keywords: acute vertigo, central vertigo, clinical predictors

Ref No: 8796

Conceptualization of AI at the emergency department: Thematic Analysis of Focus Group Discussions with Emergency Professionals (The ARISE Project Phase 1)

Gülden Sayılan[1], Sevilay Vural[2]
[1]Ankara Yıldırım Beyazıt University
[2]Yozgat Bozok University

Sevilay Vural / Yozgat Bozok University

Introduction and Purpose: As Artificial Intelligence (AI) integration accelerates in Emergency Medicine (EM), the lack of validated instruments to measure clinician perspectives remains a critical gap. Phase 1 of the global ARISE (Artificial Intelligence Survey Among Emergency Department Professionals) project aims to explore the multicultural perceptions, perceived benefits, and systemic barriers regarding AI among EM physicians to facilitate scale construction.

Materials and Methods: A qualitative design was employed using focus group discussions (FGDs) with multidisciplinary EM teams in Turkey and the Netherlands. Data were analyzed using thematic analysis to identify recurring themes and cultural/generational nuances.

Results and Conclusion: The analysis revealed that the findings are categorized under four thematic blocks, each encompassing specific themes. Potential Barriers were characterized by the themes of the 'Responsibility Labyrinth' (i.e., legal ambiguity) and 'Algorithmic Imperialism,' reflecting fears that global datasets may overlook local clinical nuances. Conversely, the Potential Benefits block positioned AI as a 'Prosthetic Assistant' capable of mitigating triage errors caused by clinician fatigue. This duality fosters Emotional Ambivalence, where technological optimism is countered by the theme of 'Cognitive Atrophy'—the feared loss of traditional examination skills. Ultimately, Perceived Responsibility is governed by the 'Final Signature Doctrine'; physicians insist on decision-making autonomy while advocating for a diffusion of legal liability toward developers and institutions. The analysis also revealed a generational divide: Senior physicians view AI as a "barrier" to the human touch, whereas younger specialists see it as a "shield" against the cognitive overload of the ED. In conclusion, EM physicians view AI with profound ambivalence: an operational savior, but also an existential threat to professional identity. Successful integration requires addressing the "Moral Crumple Zone"—where clinicians bear the burden of systemic AI errors—and establishing "Meaningful Human Control." These insights provide the foundational framework for the forthcoming global ARISE survey.

Keywords: Artificial Intelligence, Emergency Medicine, Thematic Analysis

Ref No: 8829

A Diagnostic Pitfall in Trauma Management: Incidental Acute Cholangitis

Mikail Kuşdoğan[1], Emre Gökçen[1], Levent Albayrak[1], Sevilay Vural[1], Şeyda Tuba Savrun[2], Atakan Savrun[3], Deniz Tanrıverdi[4]

[1]Yozgat Bozok University, Department of Emergency Medicine, Yozgat, Turkey.
[2]Ankara 112 Provincial Ambulance Service, Command and Control Center, Ankara, Turkey.
[3]Sincan Training and Research Hospital, Department of Emergency Medicine, Ankara, Turkey.
[4]Iğdır State Hospital, Department of Emergency Medicine, Iğdır, Turkey.

şeyda tuba savrun / Ankara 112 Provincial Ambulance Service, Command and Control Center, Ankara, Turkey.

Introduction and Purpose: In emergency medicine, Computed Tomography (CT) is a cornerstone for identifying both traumatic injuries and incidental findings. Non-traumatic pathologies are observed in 30% to 50% of trauma-indicated CT scans, with 5% to 15% requiring urgent intervention. In this report, we present a case of acute cholangitis that was incidentally identified during the diagnostic workup of a multi-trauma patient.

Materials and Methods: A 62-year-old male patient presented to our emergency department following an intra-vehicular traffic accident. The patient's Glasgow Coma Scale (GCS) score was 15, and vital signs were within normal limits. Physical examination revealed crepitus and tenderness consistent with subcutaneous emphysema in the right thoracic region. Additionally, right upper quadrant tenderness was noted, though it was initially unclear whether this was secondary to trauma or an underlying biliary pathology. Imaging and laboratory investigations were initiated. Thoracic CT revealed fractures of the right 9th, 10th, 11th, and 12th ribs along with subcutaneous emphysema. Although no hepatic hematoma or laceration was detected on abdominal imaging, significant ectasia of the bile ducts and thickening of the ductal walls were identified(Figures 1). The patient was admitted to the Thoracic Surgery department due to multiple rib fractures and subcutaneous emphysema; a tube thoracostomy was subsequently performed during follow-up. A General Surgery consultation was requested regarding the cholangitis findings, and the patient underwent further etiological investigation and management concurrently with his thoracic stabilization. Following the initial trauma stabilization, the patient was admitted for observation. During the inpatient follow-up, MRCP imaging was performed, which confirmed the diagnosis of acute cholangitis secondary to choledocholithiasis. The biliary tree was notably affected, with marked dilatation of the intrahepatic bile ducts. The common bile duct (CBD) was significantly distended, measuring 16 mm at its maximum diameter, and contained multiple calculi (stones), providing a clear etiology for the clinical presentation(Figure 2).

Axial CT scan showing concomitant right-sided rib fractures and subcutaneous emphysema , alongside incidental ectasia of the biliary tree.



Axial CT image demonstrating multiple rib fractures on the right hemithorax with associated subcutaneous emphysema. Contrast-enhanced abdominal CT showing significant dilatation of the intrahepatic bile ducts and thickening of the ductal walls, suggestive of acute cholangitis.

MRCP image confirming acute cholangitis secondary to multiple calculi within a dilated (16 mm) common bile duct.



Results and Conclusion: The use of CT in emergency departments is of critical importance not only for diagnosing traumatic injuries but also for detecting incidental pathologies that may be life-threatening.While focusing on a patient's mechanical injuries in the ER, it is essential to maintain a systematic screening approach to ensure that concomitant pathologies are not overlooked.

Keywords: Computed Tomography, rib fracture, cholangitis

Ref No: 8928

Acute Inferior Myocardial Infarction After Turkish Bath: A Rare Clinical Presentation

ÖMER FARUK ÖZ[1], EMRE KALKAN[1], MALICK TOURE[1], BASAR CANDER[1]
[1]BEZMIALEM VAKIF UNIVERSITY

ÖMER FARUK ÖZ / BEZMIALEM VAKIF UNIVERSITY

Introduction and Purpose: The Turkish bath is a traditional practice characterized by high temperature and humidity. Prolonged exposure to this environment can lead to physiological changes such as vasodilation, tachycardia, hypotension, and fluid loss. These changes can increase the risk of myocardial ischemia, particularly in individuals with atherosclerotic cardiovascular disease. Acute myocardial infarction (AMI) usually develops as a result of atherosclerotic plaque rupture and thrombosis, but environmental stressors can also play a triggering role. This case presents a rare case of inferior myocardial infarction that developed after a Turkish bath visit.

Materials and Methods: A 72-year-old male patient was brought to the emergency room by ambulance due to presyncope and bradycardia following a Turkish bath. The patient has chronic diseases including hypertension and diabetes. The patient has never smoked and has no history of angiography. When the patient was admitted to the emergency room, GCS was 14 and he was bradycardic. When the patient arrives at the cricital care unit vital signs were; fever:36,10C, pulse:40/min, oxygen saturation(SpO2):96%, respiratory rate:18/min, arterial blood pressure:154/72 mmHg.The patient was treated with 1 mg of intravenous atropine for symptomatic bradycardia. The patient's ECG revealed inferior STEMI (ST elevation myocardial infarction). The patient was immediately given oral treatment of 300 mg of acetylsalicylic acid and 600 mg of clopidogrel. The patient underwent brain CT scanning to rule out intracranial hemorrhage. Following a brain CT scan, the patient was urgently admitted to the coronary angiography unit. Following coronary angiography, stenosis was detected in the patient's right coronary artery, and a stent procedure was performed.

ECG shows inferior myocardial infarction

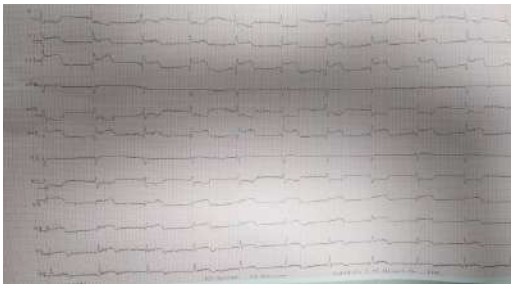

Results and Conclusion: In environments exposed to high temperatures, such as Turkish baths, body temperature increases, leading to peripheral vasodilation. This situation leads to a decrease in systemic vascular resistance. Furthermore, dehydration resulting from excessive sweating can lead to hemoconcentration and an increased thrombogenic tendency.These pathophysiological changes can trigger acute coronary syndrome through the following mechanisms:•Increased myocardial oxygen consumption•Decreased coronary perfusion pressure•Hemoconcentration and tendency for thrombus formation•Endothelial dysfunction Although cases of myocardial infarction following sauna and hot bath use have been reported in the literature, cases associated with Turkish baths are quite rare.

Keywords: inferior myocardial infarction, turkish bath, stemi

---

Ref No: 8947

The Relationship Between Routine Laboratory Parameters, Clinical Outcomes, and Nursing Care in Patients with Acute Appendicitis: A Retrospective Study

Ömer Faruk Yetkin[1], Nihal Dolanbay[2]

[1]Malatya Turgut Özal Üniversitesi Tıp Fakültesi
[2]SANKO University Faculty of Nursing, Department of Surgical Nursing

Ömer Faruk Yetkin / Malatya Turgut Özal Üniversitesi Tıp Fakültesi

Introduction and Purpose: Objective: The aim of this study was to assess the relationship between routine laboratory parameters and clinical outcomes, particularly the length of hospital stay, in patients diagnosed with acute appendicitis.

Materials and Methods: Materials and Methods:This study was conducted retrospectively in patients who presented to the emergency department and were diagnosed with acute appendicitis. Patients under the age of 18 and those with incomplete or inaccessible data were excluded. The obtained data were analyzed using appropriate statistical methods.

Results and Conclusion: Results:A total of 29 patients were included in the study, and the mean age of the patients was within the young adult group. While no significant differences were observed in most parameters according to sex, hemoglobin levels were found to be lower in female patients. A positive correlation was identified between neutrophil and monocyte counts, whereas a negative correlation was observed between neutrophil and lymphocyte counts. A positive association was found between C-reactive protein levels and length of hospital stay.

Additionally, a decrease in lymphocyte and platelet levels was associated with a longer hospital stay.Conclusion:Routine laboratory parameters in acute appendicitis are important not only for diagnosis but also for predicting disease severity and clinical course. The combined evaluation of these parameters may contribute to the clinical decision-making process.

Keywords: acute appendicitis; C-reactive protein; neutrophil-to-lymphocyte ratio

---

Ref No: 8976

Percutaneous tracheostomy in the intensive care unit: a single-center retrospective analysis of technique, timing and clinical outcomes

Tuğba Yıldırım[1], Mesut Bala[1], Fatih Tanrıverdi[2], Atakan Savrun[2]

[1]Ankara Sincan Training and Research Hospital, Department of Anesthesiology and Reanimation, Intensive Care Unit
[2]Ankara Sincan Training and Research Hospital, Department of Emergency Medicine

Fatih Tanrıverdi / Ankara Sincan Training and Research Hospital, Department of Emergency Medicine

Introduction and Purpose: Tracheostomy is frequently performed in intensive care units (ICU) for patients requiring prolonged mechanical ventilation. Percutaneous dilatational tracheostomy (PDT) has become widely preferred over surgical tracheostomy because it can be performed at the bedside and is associated with shorter procedure time and low complication rates. Among the various PDT techniques, the Griggs and Ciaglia Blue Rhino techniques are commonly used. n the Griggs technique, tracheal dilation is performed using guidewire dilating forceps, whereas in the Ciaglia Blue Rhino technique the trachea is dilated gradually with a single conical dilator.This study aimed to evaluate the timing, technical characteristics and clinical outcomes of percutaneous tracheostomy procedures performed in the ICU.

Materials and Methods: In this single-center retrospective study, 40 patients who underwent elective percutaneous tracheostomy in the ICU between December 1, 2024 and March 6, 2026 were analyzed. Patient demographics, ICU admission diagnoses, timing of tracheostomy, technique used (Griggs or Ciaglia Blue Rhino), bronchoscopy use, complications, length of hospital stay and hospital mortality were recorded. The relationship between tracheostomy timing, technique, bronchoscopy use and complication development was analyzed using Fisher's exact test.

Results and Conclusion: The median age was 74.5 years (18–92), and 60% of patients were male. The most common ICU admission causes were cerebrovascular events and intracranial hemorrhage (each 17.5%). Neurological causes were the most frequent overall (45%), followed by respiratory and other causes such as malignancy and trauma.The median time to tracheostomy was 21 days (9–90). The Griggs technique was used in 75% of patients and the Ciaglia Blue Rhino technique in 25%. Bronchoscopy was used in 35% of procedures.The overall complication rate was 12.5%, including late bleeding in three patients, tracheoesophageal fistula in one patient and granulation tissue-related tracheal stenosis in one patient. The median hospital stay was 59.5 days (13–195) and hospital mortality was 80%. No statistically significant relationship was found between tracheostomy timing, technique, bronchoscopy use and complication development ($p > 0.05$).Percutaneous tracheostomy appears to be a safe bedside procedure with acceptable complication rates in ICU patients.

Keywords: Percutaneous tracheostomy, intensive care unit, complication

---

Ref No: 8996

Pneumatosis intestinalis due to mesenteric ischemia: a case presentation with acute abdomen

Tuba Arslan[1], Ayla Mollaoğlu[1], Nurettin Özkan[1], Yasin Yıldız[1], Mehmet Gül[1]

[1]Emergency Medicine Department, Konya City Hospital, Türkiye

Tuba Arslan / Emergency Medicine Department, Konya City Hospital, Türkiye

Introduction and Purpose: Pneumatosis intestinalis (PI) is characterized by the presence of gas within the layers of the intestinal wall. It is a rare but clinically critical radiological finding. Depending on the underlying cause, PI may follow a benign course; however, when associated with mesenteric ischemia, it is linked to very high mortality rates.

Materials and Methods: A 66-year-old woman presented to the emergency department with increasing abdominal pain and inability to defecate for two days. Her medical history included hypertension and cardiac arrhythmia (consistent with atrial fibrillation). On admission, vital signs were: blood pressure 100/60 mmHg, pulse 80/min, and temperature 36.6°C. Physical examination revealed diffuse abdominal tenderness and distension. Severe tissue hypoperfusion was evident (Lactate: 9.8 mmol/L, pH: 7.31, Potassium: 6.8 mmol/L, AST: 600 U/L, ALT: 94 U/L, LDH: 961 U/L, Amylase: 910 U/L, WBC: 14.03x10^3/µL, CRP: 130 mg/L, Creatinine: 2.37 mg/dL) Contrast-enhanced abdominal CT revealed dilated small bowel loops, widespread gas

collections within the intestinal wall (PI), pelvic free fluid, and most importantly, total occlusion (thrombosis/embolism) of the abdominal aorta just proximal to the bifurcationThe patient received aggressive intravenous fluid resuscitation and medical treatment for hyperkalemia. Following surgical consultation, she was admitted to the intensive care unit with a preliminary diagnosis of mesenteric ischemia. Despite all interventions, she developed hemodynamic instability and multiple organ failure, and unfortunately died.

Results and Conclusion: PI develops due to disruption of intestinal wall integrity, increased intraluminal pressure, or invasion by gas-producing microorganisms. Arterial thrombosis or embolism are among the most common causes. PI, especially when accompanied by hyperlactatemia and vascular occlusion in elderly patients with vascular risk factors, is a strong indicator of mesenteric ischemia requiring urgent surgical intervention. Early diagnosis and a multidisciplinary approach are critical to reducing mortality.

Keywords: Pneumatosis intestinalis, Acute abdomen, Aortic occlusion

---

Ref No: 9011

A case of intramural hematoma of the ascending aorta

HASAN KUMRU[1]
[1]Niğde Ömer Halisdemir Training and Research Hospital, Department of Emergency Medicine

HASAN KUMRU / Niğde Ömer Halisdemir Training and Research Hospital, Department of Emergency Medicine

Introduction and Purpose: Aortic Intramural Hematoma (IMH) is an important type of acute aortic syndrome that can be life-threatening. It presents with symptoms and a clinical course similar to aortic dissection. Unlike aortic dissection, it is characterized by the development of a hematoma within the media layer following hemorrhage, without the presence of an intimal tear or flap. It may cause a crescent-shaped or circumferential thickening appearance in the aortic wall. Aortic intramural hematoma can be detected more easily in recent years with the routine use of diagnostic methods such as Magnetic Resonance Imaging (MRI), Computed Tomography (CT), and Transesophageal Echocardiography (TEE). Since IMH located in the ascending aorta has very high mortality and morbidity, early surgical treatment is recommended. In contrast, in uncomplicated IMH located in the descending aorta, medical treatment with antihypertensive agents is generally recommended, and if pain and progression of the hematoma can be controlled in these typically elderly patients, mortality and morbidity are reported to be lower. In this case

report, we presented a patient with ascending aortic intramural hematoma who was admitted to our emergency department.

Materials and Methods: A 76-year-old male patient was brought to the emergency department by the 112 emergency medical team after he lost consciousness while shaving at home. During history taking, it was learned that he had also been experiencing back pain recently as an additional symptom. On admission, the patient's vital signs were as follows: Glasgow Coma Scale (GCS) 15, temperature 36.7 °C, pulse 89 bpm, blood pressure 80/50 mmHg, oxygen saturation 93%, respiratory rate 16/min.In laboratory tests, troponin was 17 and D-dimer was 853. Imaging studies revealed an ascending aortic diameter of 57 mm and an intramural hematoma in the ascending aorta. Tomography reports indicated that there was no dissection. The patient was consulted to cardiovascular surgery and was taken to emergency operation. The patient died during surgery.

Intramural Hematoma Imaging

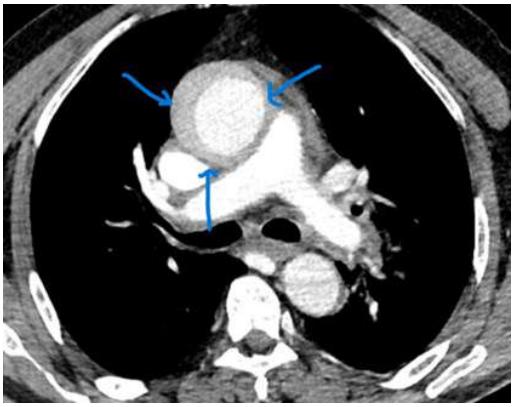

Intramural Hematoma Imaging

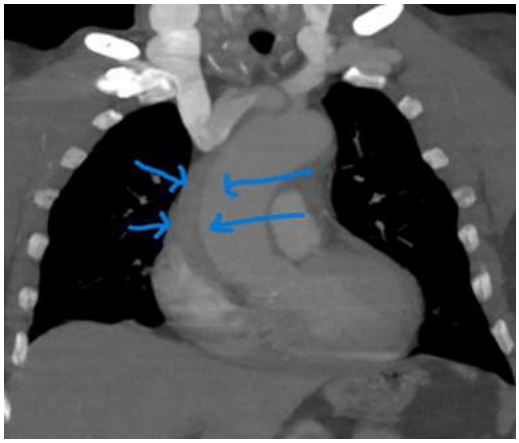

Results and Conclusion: In elderly patients presenting to the emergency department with syncope, the differential diagnosis should be kept broad, and aortic pathologies should also be considered.

Keywords: Aorta, Syncope, Backache

Ref No: 9030

Experience Does Not Equal Expertise: Educational Gaps in Resuscitation Knowledge

Cansu Doğan[1], Halil Özgün Kerem[1]
[1]Harran University

Cansu Doğan / Harran University

Introduction and Purpose: Basic life support (BLS) and advanced life support (ALS) are fundamental components of resuscitation care. Although emergency department (ED) experience is often presumed to improve resuscitation competence, the relative contribution of clinical exposure versus structured training to objective knowledge remains uncertain, particularly when BLS and ALS are evaluated separately. With this study, we aimed to contribute to education planning by completing this lack of knowledge

Materials and Methods: This cross-sectional, questionnaire-based study included healthcare professionals from multiple disciplines. Demographic characteristics, ED experience, training modality, and self-perceived competence were recorded. Objective resuscitation knowledge was assessed using 25 multiple-choice questions, generating separate BLS (12 items), ALS (13 items), and total scores. High knowledge level was determined using receiver operating characteristic analysis, and independent predictors were identified through multivariable logistic regression.

Results and Conclusion: A total of 237 participants were analyzed. The median total knowledge score was 68 (IQR 60–76). BLS scores were significantly higher than ALS scores within the same individuals (median 36 vs 32, $p < 0.001$). ED experience was not associated with higher BLS, ALS, or total knowledge scores ($p > 0.05$). Participation in structured, certified life support training was independently associated with high knowledge level (OR 10.78; 95% CI 1.74–66.84; $p = 0.011$). Self-perceived competence showed only moderate correlation with objective knowledge. Structured training demonstrated a stronger association with objective knowledge than clinical exposure alone. These findings highlight the distinction between experiential familiarity and measurable cognitive competence in resuscitation care.In critical care and

emergency settings, healthcare professionals are expected to maintain high competence in both basic and advanced life support. Routine ED experience alone should not be considered a surrogate for resuscitation competence. Structured, certified training and periodic competency-based refresher programs—particularly focused on advanced pharmacology and post–resuscitation care—may enhance preparedness, reduce knowledge gaps, and improve patient safety and clinical outcomes.

Keywords: Advanced Cardiac Life Support, Cardiopulmonary Resuscitation, Emergency Department

---

Ref No: 9079

Hypocalcemia associated with chronic alcohol use: a case report of a patient presenting with tetany-like clinical features

Mustafa Yasin Duran[1], Nazire Belgin Akıllı[1], Ayşe Göksu[1], Berke Yıldırım[1], Mehmet Gül[1]

[1]Emergency Medicine Department, Konya City Hospital, Türkiye

Ayşe Göksu / Emergency Medicine Department, Konya City Hospital, Türkiye

Introduction and Purpose: Hypocalcemia is characterized by increased neuromuscular irritability and may present with tetany, muscle spasms, and seizure-like clinical findings. Chronic alcohol use can cause hypocalcemia through nutritional deficiencies, electrolyte imbalances, and metabolic changes.

Materials and Methods: A 26-year-old male patient presented to the emergency department with complaints of nausea, vomiting, and muscle spasms in the extremities. At the time of presentation, the patient was in good general condition, alert, and cooperative. On physical examination, the abdomen was soft, with no tenderness or rebound tenderness. No additional pathological findings were noted during cardiovascular and respiratory system examinations. During the neuromuscular evaluation, the patient reported significant muscle spasms and cramps, particularly in the extremities. A history of chronic alcohol use was obtained from the patient's family, and it was learned that he had consumed alcohol prior to presentation. Laboratory tests revealed low serum calcium levels (hypocalcemia). When clinical findings and laboratory results were evaluated together, the current presentation was interpreted as consistent with tetany resulting from hypocalcemia. The patient was placed under observation with a plan for electrolyte replacement therapy. During the treatment process, the patient's clinical findings were closely monitored. Clinical follow-up revealed a significant improvement in the patient's

complaints of muscle spasms and cramps, and the patient's general condition was assessed as stable.

Results and Conclusion: Hypocalcemia is one of the most common electrolyte disorders encountered in the emergency department and is characterized by increased neuromuscular irritability. Tetany is one of the most prominent clinical manifestations of hypocalcemia and may present as muscle spasms, carpopedal spasms, paresthesias, and, in severe cases, seizures. In this case, the patient's history of chronic alcohol use and the detection of hypocalcemia in laboratory findings suggest that alcohol plays a significant role in the etiology. Similarly, studies have reported that the coexistence of hypocalcemia and hypomagnesemia is common in individuals with chronic alcohol use and that this leads to neuromuscular symptoms. Chronic alcohol use can lead to tetany-like symptoms associated with hypocalcemia. In patients presenting to the emergency department with muscle spasms and neuromuscular irritability, electrolyte imbalances and a history of alcohol use must be thoroughly evaluated.

Keywords: Hypocalcemia, chronic alcohol use, electrolyte imbalance

---

Ref No: 9101

High-Pressure Grease Gun Injury Leading to Transmetacarpal Amputation: A Rare Case Report

Hasan Emre Ozsoy[1], Niyazi Erdem Yasar[1]

[1]Ankara Bilkent City Hospital, Department of Orthopaedics and Traumatology

Hasan Emre Ozsoy / Ankara Bilkent City Hospital, Department of Orthopaedics and Traumatology

Introduction and Purpose: High-pressure injection injuries are rare but devastating surgical emergencies with a high risk of tissue necrosis and amputation. Although grease is traditionally considered less harmful than organic solvents, it may still cause severe vascular compromise. This study aims to present a case of high-pressure grease gun injury resulting in transmetacarpal amputation despite early surgical intervention, highlighting the unpredictable clinical course of these injuries.

Materials and Methods: A 50-year-old male presented to the emergency department 10 hours after sustaining a high-pressure grease gun injury to his left hand. Examination revealed a puncture wound at the proximal phalanx of the second finger, with edema, poor capillary refill,

and sensory loss. Initial management included saline irrigation, tetanus prophylaxis, and intravenous (IV) antibiotics. Urgent surgical exploration revealed extensive grease infiltration extending along the flexor tendon sheath (Figure 1). Wide debridement was performed with proximal extension of the incision (Figure 2).

Figure 1: Brunner incision for surgical exploration



Intraoperative view of the second digit demonstrating a Brunner incision extending along the volar aspect. Diffuse grease infiltration is observed within the subcutaneous tissues and along the flexor tendon sheath, indicating proximal and distal spread from the injection site.

Figure 2. Intraoperative view following debridement of grease-contaminated tissues.



Exposure of the flexor tendon sheath demonstrates extensive soft tissue infiltration and disruption of normal anatomical planes. Debridement was extended proximally to achieve adequate removal of the infiltrated material.

Results and Conclusion: Despite early intervention, progressive ischemia and necrosis developed, necessitating transmetacarpal amputation one week later. Digital necrosis with a clear demarcation line was observed (Figure 3). Transmetacarpal amputation was subsequently performed (Figure 4). Postoperative radiographs demonstrated second ray resection at the metacarpal level (Figure 5). During reconstruction, the adductor pollicis muscle was transferred to the third metacarpal to preserve hand function. Full wound healing was achieved by week six, and the patient returned to work by week eight. At one-year follow-up, full range of motion and complete grip strength recovery were observed.

Figure 3. Digital necrosis with demarcation line formation.



Clinical image demonstrating advanced ischemia of the second digit with well-defined demarcation and black necrotic tissue.

Figure 4. Intraoperative view of transmetacarpal amputation.



Surgical exposure demonstrating oblique osteotomy at the metacarpal level with preparation of soft tissues for closure. Necrotic changes of the involved digit are evident.

Figure 5. Postoperative radiograph after transmetacarpal amputation.



Anteroposterior and oblique views demonstrating second ray resection at the metacarpal level without additional osseous abnormalities.

Keywords: Amputation, Debridement, Hand Injuries

Ref No: 9103

AN UNUSUAL CAUSE OF ACUTE ABDOMEN: MASSIVE ASCITES ASSOCIATED WITH SJOGREN'S SYNDROME

Rümeysa Düşünceli[1], Nevzat HERGÜL[1], Sevdegül KARADAŞ[1]

[1]Yuzuncu Yil University, Faculty of Medicine, Departments of Emergency Medicine, Van, Türkiye

Nevzat HERGÜL / Yuzuncu Yil University, Faculty of Medicine, Departments of Emergency Medicine, Van, Türkiye

Introduction and Purpose: Sjögren's syndrome(SS) is a chronic and systemic autoimmune disease characterized by lymphocytic infiltration of the exocrine glands. While it primarily presents with dry eyes and dry mouth, a significant proportion of patients may exhibit extraglandular involvement affecting multiple organs, including the skin, lungs, kidneys, and gastrointestinal system. Diagnostic methods include the Schirmer test for dry eyes or parotid gland scintigraphy.Among the extraglandular involvements in SS, massive ascites in the abdomen is a rare and complex condition. This usually occurs secondary to severe hypoalbuminemia resulting from protein-losing gastroenteropathy (PLGE) associated with SS.Here, we present a case of SS with preserved liver and kidney function, PLGE, and massive ascites.

Materials and Methods: A 40-year-old female patient presented to the emergency department with complaints of increasing abdominal pain and nausea/vomiting for two days.Her blood pressure was 160/80 mmHg, and other vital signs were stable. Physical examination revealed tenderness in the upper abdominal quadrants; there was no rebound tenderness or guarding. Other system examinations were normal. Laboratory parameters were within normal limits except for the values presented in the table. Abdominal ultrasonography revealed widespread free fluid in the perihepatic, perisplenic, and lower abdominal quadrants, measuring up to 10 cm at its deepest point. Further investigation included abdominal CT scan, which showed marked edematous thickening and widespread free fluid in the jejunal and duodenal regions (Figure 1). The patient, initially suspected of having acute abdomen, was referred to the internal medicine rheumatology department and started on high-dose methylprednisolone. Rapid clinical improvement was achieved during follow-up, and the patient was discharged with a recommendation for outpatient follow-up.

Figure 1: Abdominal contrast-enhanced CT; widespread free fluid

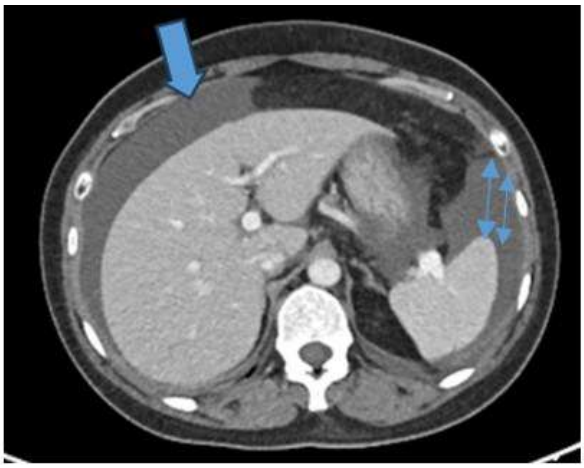

Table 1: Blood parameters.

Parameters	Result	Normal Range
WBC (White Blood Cell) (10^3/uL)	9.9	3.91-10.9
HGB (Hemoglobin) (g/dl)	10.4	13-16.9
Hct (%)	30.6	36,6 - 50
MCV (fL)	83.4	81,8 - 95,5
Neutrophil (10^3/uL)	7.52	1.8-6.98
Lymphocyte (10^3/uL)	1.45	1,26 - 3,35
C-reactive protein (mg/dl)	8.1	0-5
Creatinine	1.02	0.57 -1.11
Albumin	27.80	35 - 52
Sedimentation	140	3 - 20

Tablo 2 : Urine Analysis parameters

Parameters	Result	Normal Range
Density	1.015	1015 - 1025
Glucose	Neg.	Negatif
Ketone	Neg.	Negatif
Protein	+2	Negatif

Bilirubin	Neg.	Negatif
Urobilinogen	Norm.	Negatif
Nitrite	Neg.	Negatif
Leukocyte (Strip)	8	Negatif
Erythrocyte (Strip)	9	Negatif
Non-Squamous Epithelium (/hpf)	1	Negatif

Results and Conclusion: The widespread ascites and intestinal edema observed in the presented case is a vasculitic condition rarely reported in the literature but potentially life-threatening in SS patients. This condition arises due to the developing severe hypoalbuminemia. Furthermore, the presence of proteinuria indicates that the patient's kidneys are also affected by this inflammatory process. In SS patients with relatively stable liver and kidney function, sudden onset of ascites should always be considered in the differential diagnosis of PLGE and mesenteric vasculitis.

Keywords: Sjögren's syndrome, Ascites, Emergency Medicine

Ref No: 9181

Triple Abdominal Wall Muscle Hematoma Associated with Low-Molecular-Weight Heparin Use

Burak YAŞAR[1], Nevzat HERGÜL[1], Gizem GİZLİ TAN[1]
[1]Yuzuncu Yil University, Medical School Hospital, Van, Türkiye
Burak YAŞAR / Yuzuncu Yil University, Medical School Hospital, Van, Türkiye

Introduction and Purpose: Rectus sheath hematoma is an uncommon but important cause of acute abdominal pain, particularly in patients receiving anticoagulant therapy. Although it typically involves the rectus abdominis muscle alone, extension to other abdominal wall muscles is rare. We present a patient who developed an extensive abdominal wall hematoma involving three abdominal wall muscles during low-molecular-weight heparin therapy.

Materials and Methods: A 60-year-old man presented to the emergency department with abdominal swelling, abdominal distension, and severe abdominal pain that began on the morning of admission. His medical history included hypertension, pulmonary embolism, and obstructive lung disease. He was receiving low-molecular-weight heparin (Clexane). On admission, he was conscious, oriented, and cooperative. Vital signs were stable, with a blood pressure of 110/70 mmHg, pulse rate of 80 beats/min, body temperature of 36.9°C, and oxygen saturation of 92%

with oxygen support. Physical examination revealed abdominal distension and a palpable swelling in the upper abdominal quadrant. Laboratory findings are presented in Table 1. Abdominal computed tomography demonstrated a hematoma within the right rectus abdominis muscle, with diffuse intramuscular hemorrhage extending into the right transversus abdominis and internal oblique muscles. These findings indicated an extensive abdominal wall hematoma involving three abdominal wall muscles. The computed tomography findings are shown in Figure 1. The hematoma was considered secondary to low-molecular-weight heparin therapy. The patient was admitted for observation and managed conservatively with close clinical monitoring.

Figure 1

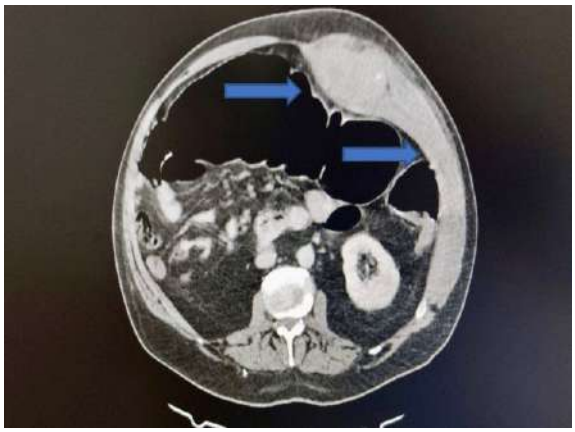

Abdominal computed tomography images demonstrating an extensive abdominal wall hematoma involving the right rectus abdominis, transversus abdominis, and internal oblique muscles. The arrows indicate the areas of hematoma.

Table 1

Parameter	Result	Reference Range
Hemoglobin	13.9 g/dL	13–17 g/dL
Hematocrit	51 %	40–50 %
White Blood Cell	11×10³/µL	4–10 ×10³/µL
Platelet	261 ×10³/µL	150–400 ×10³/µL
INR(International Normalized Ratio)	1.1	0.8-1.2

C-reactive protein	14.7 mg/L	0–5 mg/L
aPTT	26s	25-35s

Laboratory Findings at Admission

Results and Conclusion: Abdominal wall hematoma should be considered in patients receiving anticoagulant therapy who present with acute abdominal pain and abdominal swelling. Although rectus sheath hematoma usually remains confined to the rectus muscle, simultaneous involvement of multiple abdominal wall muscles may occur and may mimic other causes of acute abdomen. Computed tomography is highly valuable for confirming the diagnosis, defining the extent of hemorrhage, and supporting appropriate management. Early recognition of this rare presentation may help avoid unnecessary surgical intervention and allow safe conservative follow-up in selected patients.

Keywords: abdominal wall hematoma, Rectus sheath hematoma, low-molecular-weight heparin

---

Ref No: 9250

From acute abdomen to digoxin intoxication: A case report

Feyza Sandal[1], Muhammet Gökhan Turtay[1], Müslüme Kasa[1], Berra Kalkavan Doğan[1], Gökhan Yılmaz[1], Birsen Ertekin[1]

[1]University of Health Sciences, Beyhekim Training and Research Hospital, Clinic of Emergency Medicine, Konya, Türkiye.

Muhammet Gökhan Turtay / University of Health Sciences, Beyhekim Training and Research Hospital, Clinic of Emergency Medicine, Konya, Türkiye.

Introduction and Purpose: In this case, we aimed to present a patient who was initially transferred with a presumptive diagnosis of acute abdomen due to gastrointestinal complaints, but was ultimately diagnosed with digoxin intoxication because of severe bradycardia, hypotension, altered mental status, atrial fibrillation with a slow ventricular response on electrocardiography, and ST-segment changes.

Materials and Methods: The patient presented to the emergency department of another hospital with nausea, vomiting, abdominal pain, and altered consciousness. Based on the initial assessment, the patient was considered to have an acute abdomen and was referred to our

emergency department. Past medical history revealed digoxin use for atrial fibrillation. According to information obtained from relatives, the patient had experienced influenza-like symptoms for one week and had been using antibiotics for two days. On arrival, the patient's blood pressure was 80/40 mmHg and heart rate was 33 beats/min, with diffuse abdominal tenderness on examination. The electrocardiography showed atrial fibrillation with a slow ventricular response, along with T-wave inversion and ST-segment depression. Atropine 1 mg IV bolus was administered. As bradycardia and hypotension persisted despite atropine, a transcutaneous external pacemaker was applied. The patient received 20 mg of DigiFab®, followed by a second dose due to ongoing bradycardia and hypotension. Subsequently, the patient's clinical status and electrocardiography findings improved, and the patient was discharged on the third day of intensive care unit admission.

Results and Conclusion: In patients presenting with an acute abdomen, careful evaluation of clinical findings and thorough review of medications are essential, as these may be critical for diagnosing potentially fatal digoxin intoxication.

Keywords: Digoxin intoxication, Abdominal pain, Transcutaneous external pacemaker

---

Ref No: 9251

When imaging fails to detect paralysis: a case of adult SCIWORA in the emergency department

Mustafa Arar[1], Demet Acar[1], Nisa Nur İnal[1], Abdülaziz Doğan[1], Mehmet Gül[1]
[1]Emergency Medicine Department, Konya City Hospital,Türkiye
Nisa Nur İnal / Emergency Medicine Department, Konya City Hospital,Türkiye

Introduction and Purpose: SCIWORA (Spinal Cord Injury Without Radiographic Abnormality) is the presence of clinical signs of spinal cord injury despite the absence of fracture or dislocation on direct radiography and computed tomography (CT). This presentation describes a rare case of adult SCIWORA with normal radiography but quadric paresis following high-energy trauma.

Materials and Methods: Case: A 23-year-old male patient was brought to our emergency department following a car accident (passenger in the back seat, vehicle rolling down an embankment). His medical history revealed no known chronic diseases, medication use, or previous surgery. On physical examination, his vital signs at admission were: BP: 110/70 mmHg, Pulse: 72/min, Temperature: 36.8°C, SpO2: 98%. Glasgow Coma Scale (GCS): 15. The patient was oriented and cooperative. No lacerations, hematomas, or significant external trauma lesions were found throughout the body. Neurological examination revealed 0/5 motor function in all four extremities (plegic) and sensory loss in all dermatomes (quadriparesis). Deep tendon

reflexes were absent. Laboratory and imaging findings were within normal limits. All spinal (cervical, thoracic, lumbar) computed tomography and direct radiography examinations revealed no fractures, dislocations, or significant bone pathologies. Despite radiological findings, the patient was given a preliminary diagnosis of SCIWORA due to neurological deficit, and spinal immobilization was performed. The patient was admitted to the Neurosurgery clinic for further investigation (spinal MRI) and non-surgical management/follow-up.

Results and Conclusion: SCIWORA is a condition that is difficult to diagnose and can mislead clinicians. In the literature, it is explained by mechanisms such as transient stretching of the spinal canal or disruption of vascular supply. In our case, the absence of an external lesion despite high-energy trauma and the completely normal CT scan could have been misleading. However, the quadric paresis on physical examination overshadowed the radiological finding and guided the diagnosis. In these patients, a "normal CT" finding is not a sufficient criterion for mobilization. Although SCIWORA is generally seen in the pediatric population, it can also present with severe neurological deficits in adults. A normal CT scan does not rule out spinal injury; further neurological evaluation and MRI are essential in these patients.

Keywords: : SCIWORA, spinal cord injury, trauma

Ref No: 9287

A case of isolated headache and possible subarachnoid hemorrhage: Sinus venous thrombosis

Ahmet Muhammet Şahingeri[1], Fatih İkiz[1], İlknur Şahin[1], Muhammet Gökhan Turtay[1], Feyza Sandal[1], Birsen Ertekin[1]

[1]University of Health Sciences, Beyhekim Training and Research Hospital, Clinic of Emergency Medicine, Konya, Türkiye.

Muhammet Gökhan Turtay / University of Health Sciences, Beyhekim Training and Research Hospital, Clinic of Emergency Medicine, Konya, Türkiye.

Introduction and Purpose: This case presentation aims to highlight the necessity of considering sinus venous thrombosis in the differential diagnosis of headache in emergency medicine practice.

Materials and Methods: A 60-year-old female patient presented to the emergency department with a one-week history of headache that had worsened over the past two days. The patient

reported no improvement in her headache despite the use of non-steroidal anti-inflammatory drugs. Vital signs were stable on presentation. . His pupils were isochoric, and light reflexes were bilaterally positive. Neurological examination revealed no lateralised findings. Cerebellar tests were normal. Cranial nerve examination was normal. Pathological reflexes were negative. Other systemic examinations were normal. Laboratory values showed no significant pathological findings. Non-contrast cranial tomography revealed a hyperdense appearance in the right transverse sinus tract. The tomography showed a suspicious image for bleeding. Magnetic resonance venography was performed. The magnetic resonance venography revealed loss of flow consistent with acute thrombosis in the right transverse sinus, sigmoid sinus, and right internal jugular vein. The patient was admitted to the neurology ward with a diagnosis of sinus vein thrombosis. Low-molecular-weight heparin therapy was initiated. No neurological deterioration was observed in the patient during twelve days of ward follow-up. The patient was discharged on oral anticoagulant therapy.

Figure 1. Brain computed tomography image of our patient

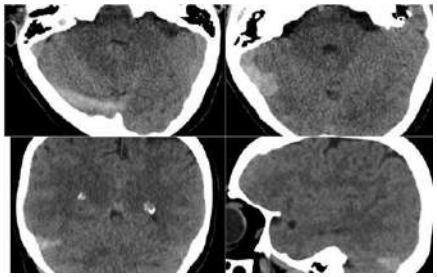

Figure 2. Magnetic resonance venography and brain image of our patient.

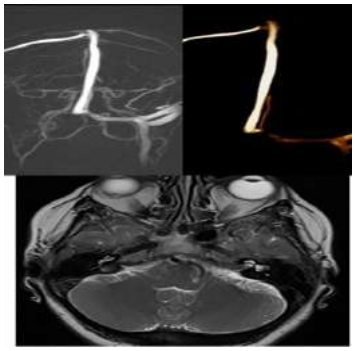

Results and Conclusion: Sinus venous thrombosis should be considered in patients with sudden, severe headache and a normal neurological examination.

Keywords: Headache, Magnetic resonance, Sinus vein thrombosis

Ref No: 9297

The Impact of FAST Protocol on Computed Tomography Utilization and Clinical Outcomes in Patients with Suspected Abdominal Injury After Traffic Accidents

CEMRE AKDOĞAN[1], HAYDAR UĞUR DİLİBAL[1], BUSE BETÜL KÜÇÜKKAYA GÜNDOĞDU[1], BÜŞRA BİLDİK[1], BORA ÇEKMEN[1]

[1]Karabuk University, Faculty of Medicine, Department of Emergency Medicine

BUSE BETÜL KÜÇÜKKAYA GÜNDOĞDU / Karabuk University, Faculty of Medicine, Department of Emergency Medicine

Introduction and Purpose: Focused Assessment with Sonography for Trauma (FAST) is a rapid, bedside ultrasound technique used to detect free fluid or hemorrhage in the abdominal, thoracic, and cardiac regions, particularly in trauma patients. This study aimed to evaluate the effect of FAST utilization on abdominal computed tomography (CT) use and clinical outcomes in patients presenting to the emergency department with suspected abdominal injury following traffic accidents.

Materials and Methods: This retrospective observational study included patients presenting to the emergency department due to traffic accidents who were evaluated for possible blunt or penetrating abdominal injury based on trauma mechanism, symptoms, or physical examination findings. Demographic characteristics, accident type, FAST utilization, abdominal CT use, CT findings, hospital admission, surgical intervention, mortality, and length of hospital stay were analyzed. Categorical variables were compared using the chi-square or Fisher's exact test, while continuous variables were analyzed using the Mann–Whitney U test. A p-value < 0.05 was considered statistically significant.

Results and Conclusion: A total of 389 patients were included. FAST was performed in 323 patients (83.0%), while 66 patients (17.0%) did not undergo FAST. The rate of abdominal CT utilization was significantly lower in patients who underwent FAST compared to those who did not (42.7% vs. 100%, $p < 0.001$), corresponding to an approximately 57% relative reduction (RR=0.43).Abdominal CT pathology was detected in 7 patients (1.8%) in the overall cohort. Eleven patients (2.8%) were hospitalized, and 3 (0.8%) required surgical intervention. Emergency department mortality occurred in 2 patients (0.5%), and in-hospital mortality in 3 patients (0.8%).Among hospitalized patients, the median length of hospital stay was 49 days (Q1–Q3: 5.5–121.5). FAST-positive patients had significantly higher rates of hospitalization (80.0% vs. 1.9%, $p < 0.001$), surgical intervention (20.0% vs. 0.3%, p=0.031), and mortality (20.0% vs. 0%, p=0.016), as well as longer hospital stays. In trauma patients presenting to the emergency department, the FAST protocol is a rapid, cost-effective, and easily applicable

bedside tool that significantly reduces abdominal CT utilization without compromising diagnostic accuracy. Additionally, FAST positivity is strongly associated with worse clinical outcomes, suggesting its value as both a diagnostic and prognostic tool.

Keywords: FAST, trauma, abdominal injury

Ref No: 9410

High-Energy Open Segmental Both-Bone Forearm Fracture-Dislocation with Distal Radioulnar Joint Disruption: A Case Report

Mustafa Yasin Hatipoglu[1], Hasan Emre Ozsoy [2]

[1]Ankara Bilkent City Hospital, Department of Orthopaedics and Traumatology
[2]Ankara Bilkent City Hospital, Hand Surgery Clinic

Mustafa Yasin Hatipoglu / Ankara Bilkent City Hospital, Department of Orthopaedics and Traumatology

Introduction and Purpose: High-energy forearm injuries involving both bony structures and joint stability are challenging to manage and are not always adequately represented in standard classification systems. Particularly, segmental both-bone forearm fractures combined with distal radioulnar joint (DRUJ) disruption are rare and complex. This report aims to present a high-energy open segmental forearm fracture-dislocation and to emphasize the importance of biological fixation principles.

Materials and Methods: A 17-year-old male patient was admitted to the emergency department after an in-vehicle traffic accident. Initial evaluation revealed a pelvic fracture and a Gustilo-Anderson type II open forearm fracture. After initial management and pelvic surgery, the patient was referred for definitive treatment of the forearm injury. Physical examination demonstrated three separate skin lacerations, located dorsally at the wrist and over the ulnar head (Figure 1). Radiographic evaluation showed segmental fractures of both the radius and ulna, with severely comminuted fractures at the distal level, associated with distal radioulnar joint disruption (Figure 2). Surgical treatment was planned. During the operation, special attention was paid to preserving soft tissue integrity and periosteal blood supply. Fractures were stabilized using multiple plates and screws.

Figure 1. Preoperative Clinical Appearance of the Open Forearm Wound



Gustilo-Anderson type II open forearm injury with extensive soft tissue damage, multiple lacerations, and exposed underlying structures over the dorsal forearm and wrist region. The wound demonstrates significant contamination and periosseous soft tissue disruption consistent with a high-energy mechanism.

Figure 2. Preoperative radiographic evaluation of the forearm



Anteroposterior and lateral radiographs showing segmental fractures of both the radius and ulna. The distal segments exhibit severe comminution, accompanied by disruption of the distal radioulnar joint (DRUJ), indicating a high-energy injury pattern.

Results and Conclusion: No postoperative complications were observed. At the 4-month follow-up, complete fracture union was achieved (Figure 3–4). This injury can be best described as a high-energy segmental both-bone forearm fracture associated with severely comminuted distal radius–ulna fractures and distal radioulnar joint disruption, which does not fit into standard classification systems. In such complex cases, respecting soft tissue, preserving periosteal circulation, and applying stable fixation are critical for successful healing, even in highly comminuted and segmental fracture patterns.

Figure 3. Postoperative AP Radiograph — Dual-Plate Fixation of Radius and Ulna



Anteroposterior radiograph of the forearm obtained following definitive surgical fixation. Both the radius and ulna have been stabilized with anatomical locking plates and screws. The construct demonstrates appropriate alignment across all fracture levels, with multiple fixation points bridging the segmental comminuted zones while respecting biological principles.

Figure 4. Postoperative Lateral Radiograph — Plate Fixation and Fracture Alignment



Figure 4. Postoperative Lateral Radiograph — Plate Fixation and Fracture Alignment Lateral view radiograph at postoperative follow-up confirming satisfactory sagittal alignment of the forearm bones. The plate-and-screw construct provides stable fixation across the segmental fracture pattern. Progressive periosteal callus formation is consistent with ongoing biological healing at 4 months.

Keywords: forearm fracture-dislocation, segmental fracture, distal radioulnar joint

---

Ref No: 9438

Emergency management of pisiform dislocation: A case report

Harun Yahya Yıldırım[1], Fatih İkiz[1], Muhammet Gökhan Turtay[1], Ahmet Çağlar[1], Gökhan Yılmaz[1], Birsen Ertekin[1]

[1]University of Health Sciences, Beyhekim Training and Research Hospital, Clinic of Emergency Medicine, Konya, Türkiye.

Muhammet Gökhan Turtay / University of Health Sciences, Beyhekim Training and Research Hospital, Clinic of Emergency Medicine, Konya, Türkiye.

Introduction and Purpose: This case report aims to emphasize that rare carpal injuries may occur in wrist trauma and that careful patient evaluation is essential to avoid missing such injuries.

Materials and Methods: A 16-year-old male presented to the emergency department with pain and swelling in his right wrist after falling onto his hand. Physical examination revealed tenderness in the right wrist, while the neurovascular examination was normal. Two-view radiographs demonstrated pisiform bone subluxation and a non-displaced fracture of the scaphoid bone. Closed reduction was performed in the emergency department, followed by immobilization with a short arm splint. The patient was discharged without complications.

Figure 1. Pisiform subluxation at initial presentation



Figure 2. After closed reduction of the pisiform dislocation



Results and Conclusion: Pisiform subluxation should be considered in the differential diagnosis of trauma patients presenting with wrist tenderness and swelling after a fall. Careful physical examination and radiological evaluation are crucial to prevent overlooking pisiform subluxation and concomitant injuries.

Keywords: Dislocation, Emergency, Pisiform

Ref No: 9517

Can AI Replace the Classroom? A Randomized Study of Podcast-Based Learning in ACLS Training

Şafak Çomurlu[1]
[1]Ataturk University, School of Medicine, Department of Emergency Medicine,

Şafak Çomurlu / Ataturk University, School of Medicine, Department of Emergency Medicine,

Introduction and Purpose: This study aims to compare the effects of traditional didactic teaching and a dynamic podcast format generated entirely from source texts by artificial intelligence on knowledge level and clinical decision-making processes of intern doctors (ID) during Advanced Cardiac Life Support (ACLS) training.

Materials and Methods: This prospective, randomized study was conducted in the emergency department of a tertiary care hospital. A total of 30 ID undergoing their emergency medicine rotation were included. Participants were randomly divided into two equal groups: Group 1 (n=15) received traditional face-to-face training under the supervision of an emergency medicine specialist, while Group 2 (n=15) listened to an AI-generated audio dialogue (podcast) created from the same medical references (Rosen, Tintinalli, AHA guidelines). Following the training,

both groups were assessed using a 5-question multiple-choice test based on clinical scenarios and algorithmic knowledge. Statistical data were recorded electronically and analyzed.

Results and Conclusion: Analysis of the results from 30 ID showed that the overall correct response rate was 81.3% (61/75) in Group 1 and 74.7% (56/75) in Group 2. In questions involving conceptual clinical scenarios, both groups demonstrated similarly high success rates ranging from 73.3% to 100%. However, in Question 4, which assessed synchronization of specific algorithms and numerical data (ventilation rate after advanced airway placement), success rates decreased to 53.3% (8/15) in Group 1 and 40.0% (6/15) in Group 2.ConclusionThe AI-based podcast application yielded results comparable and satisfactory to traditional teaching in terms of storytelling clinical scenarios and facilitating understanding of physiological mechanisms. However, traditional visual/auditory methods demonstrated a clear advantage in memorizing precise numerical data and algorithmic guideline steps. Rather than replacing conventional methods, AI-based audio tools should be considered a powerful asynchronous complementary educational resource in emergency medicine training.

Table: Comparison of Clinical Scenario–Based Performance Between Traditional Teaching and AI-Based Podcast Training in ACLS Education

Variables (Clinical scenarios)	Group 1: Traditional Education (n=15)	Group 2: NotebookLM Podcast (n=15)	p Value
Question 1 (CPR quality and recoil)			
Correct Answer, n (%)	13 (%86.7)	12 (%80.0)	1.000*
Incorrect Answer, n (%)	2 (%13.3)	3 (%20.0)	
Question 2 (Post-Defibrillation Approach)			
Correct Answer, n (%)	13 (%86.7)	11 (%73.3)	0.651*
Incorrect Answer, n (%)	2 (%13.3)	4 (%26.7)	
Question 3 (Non-shockable Rhythm and Early Epinephrine)			
Correct Answer, n (%)	12 (%80.0)	13 (%86.7)	1.000*
Incorrect Answer, n (%)	3 (%20.0)	2 (%13.3)	
Question 4 (CPR–Ventilation Synchronization)			
Correct Answer, n (%)	8 (%53.3)	6 (%40.0)	0.715*
Incorrect Answer, n (%)	7 (%46.7)	9 (%60.0)	

Question 5 (Obstructive Shock / Tension Pneumothorax)			
Correct Answer, n (%)	15 (%100.0)	14 (%93.3)	1.000*
Incorrect Answer, n (%)	0 (%0.0)	1 (%6.7)	
Overall Success Rate (Total 5 Questions)			
Correct Answer, n (%)	61 (%81.3)	56 (%74.7)	0.430**

Note: Due to expected cell frequencies being below 5, the *Fisher's Exact Test was used for question-based analyses, while the **Pearson Chi-Square Test was used for the overall success rate. Statistical significance was accepted as $p < 0.05$.

Keywords: NotebookLM, Advanced Cardiac Life Support (ACLS), medical podcast.

Ref No: 9574

Perceptual Biases, Pattern Analysis And The Contribution Of Digital–Artistic Approaches To Forensic Evaluation In Pediatric Trauma

Emine Ozdemir Kacer[1], Pelin Erol[2]

[1]Aksaray University, Faculty of Medicine, Department of Pediatrics, Division of Child Health and Diseases, Aksaray, Türkiye
[2]Aksaray University Faculty of Medicine, Department of Forensic Medicine, Aksaray, Türkiye

Emine Ozdemir Kacer / Aksaray University, Faculty of Medicine, Department of Pediatrics, Division of Child Health and Diseases, Aksaray, Türkiye

Introduction and Purpose: Diagnostic evaluation in pediatric trauma frequently relies on initial visual impressions, which are inherently susceptible to perceptual biases. Such biases may lead to misinterpretation, particularly in the differentiation between accidental injuries and abuse. This study aims to examine the impact of perceptual biases on diagnostic accuracy, to highlight the role of pattern analysis in forensic assessment, and to emphasize the importance of age-specific anatomical knowledge. In addition, the potential contribution of digitally generated artistic models to this process is explored. In this context, common cognitive biases such as anchoring and confirmation bias may influence early clinical judgment and subsequent decision-making. Furthermore, variability in clinician experience can contribute to inconsistencies in interpretation of similar injury patterns. A systematic approach integrating visual assessment

with analytical frameworks may help reduce such variability. Therefore, combining clinical expertise with structured evaluation tools is essential to improve diagnostic reliability in pediatric trauma cases.

Materials and Methods: A conceptual framework based on visual and analytical evaluation was employed for pediatric trauma cases. Clinical and forensic decision-making processes were examined within three principal domains: perceptual biases, pattern analysis, and anatomical considerations. Traumatic findings were represented using ethically constructed and anonymized digital models (AJ-1 to AJ-5) to ensure both confidentiality and visual clarity. Furthermore, a structured diagnostic algorithm was developed to support a more standardized approach to clinical assessment.

Digital Ethical Representation of Traumatic Facial Deformation



In the blunt trauma model, the visualization of color distribution, edema lines, and contusion areas through abstracted light maps enhanced both forensic interpretability and ethical representation.

Fragmented JusticeDigital Sculpting of Broken Bone Forms



Reconstruction of fracture orientations and tissue tension lines in a digital sculptural form revealed the parallel between classical anatomical sensitivity and forensic observation.

Results and Conclusion: Perceptual biases were observed to be a significant source of diagnostic error, particularly in cases involving suspected non-accidental injury. Pattern analysis provided a robust framework for forensic interpretation, especially when lesion distribution, localization, and morphology were systematically evaluated. Age-related anatomical differences were found to play a decisive role in accurate interpretation. The use of digital–artistic models facilitated the ethical visualization of injury patterns, offering added value for both educational purposes and forensic documentation. The proposed algorithm may contribute to improved standardization in clinical evaluation and enhance early identification of potential forensic cases.

Comparative Forensic–Artistic Analysis of Digital Models (AJ-1 to AJ-5)

Code	Trauma Type	Visual Technique	Technique Score (0–5)	Forensic Suitability	Description
AJ-1	Blunt trauma	3D modeling, artificial rendering	5	High	Anonymous facial representation; soft tissue abstraction while preserving forensic characteristics
AJ-2	Vitreous/secondary injury	Light mapping, transparent layering	4	High	Light-based visualization enhances depth perception and interpretability
AJ-3	Fracture trauma	Digital sculpture	5	High	Fracture lines emphasized with anatomically coherent structure
AJ-4	Data-based anatomy	SPSS-based 3D color mapping	4	Moderate	Limited anatomical clarity; reduced interpretative strength
AJ-5	Postmortem change	Color gradient modeling	5	High	Represents livor mortis and postmortem color transitions while preserving forensic sensitivity

Keywords: Pediatric trauma, forensic medicine, digital modeling

Ref No: 9601

Extensive Subcutaneous Emphysema with Bilateral Pneumothorax After Blunt Trauma: A Case Report

ULARBEK AKNAZAROV[1], YAVUZ CELİK[1], HANDENUR AKBAYRAK[1], BAHADİR TASLİDERE[1], BASAR CANDER[1]

[1]Bezmialem Vakif University, Department of Emergency Medicine, Istanbul, Türkiye

ULARBEK AKNAZAROV / Bezmialem Vakif University, Department of Emergency Medicine, Istanbul, Türkiye

Introduction and Purpose: Blunt thoracic trauma can result in serious complications, including pneumothorax and subcutaneous emphysema. We report a 45-year-old male who developed extensive subcutaneous emphysema, bilateral pneumothorax, and liver laceration following a fall from height. Prompt recognition and appropriate management led to clinical stabilization.

Materials and Methods: A 45-year-old male was admitted to the emergency department after falling from a height of approximately 1.5 meters. On arrival, he was conscious, oriented, and hemodynamically stable (GCS: 15; blood pressure: 117/69 mmHg; heart rate: 82/min; oxygen saturation: 96% on room air). Laboratory findings were within normal limits. Physical examination revealed tachypnea, decreased breath sounds on the left hemithorax, and palpable subcutaneous emphysema over the left thoracic region.During follow-up, the patient developed progressive dyspnea and widespread subcutaneous emphysema involving the face, neck, and scrotum. Thoracic computed tomography demonstrated extensive subcutaneous emphysema, pneumomediastinum, left pneumothorax (50 mm), right pneumothorax (15 mm), multiple rib fractures (4th–5th ribs), pulmonary contusions, and left-sided hemothorax. Abdominal CT revealed a subcapsular liver laceration (segment IV) with minimal perihepatic fluid.Due to extensive subcutaneous air, FAST examination was non-diagnostic. Subcutaneous emphysema was managed with skin incisions for decompression. A chest tube was inserted into the left hemithorax, yielding hemorrhagic drainage. The patient received supplemental oxygen, and respiratory status improved during follow-up.Consultations with urology and general surgery did not indicate the need for immediate surgical intervention. The patient was admitted to the intensive care unit for close monitoring.

Axial chest CT scan showing bilateral pneumothorax, multiple rib fracture on the left, and widespread subcutaneous emphysema

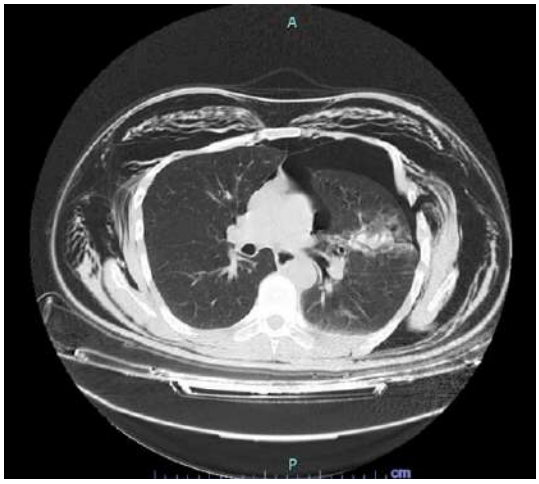

Results and Conclusion: Extensive subcutaneous emphysema with bilateral pneumothorax is a rare but potentially serious consequence of blunt trauma. Early diagnosis and timely intervention are critical to prevent respiratory compromise and ensure favorable outcomes.

Keywords: Subcutaneous emphysema, Pneumothorax, Blunt thoracic trauma

---

Ref No: 9617

Analysis of earthquake victim cases presenting to the emergency department of Inonu University Turgut Ozal Medical Centre following the 2023 Kahramanmaraş earthquakes and subsequent events

Hüseyin Yıldırım[1], Muhammet Gökhan Turtay[2], Harun Kürşat Şahingil[3]

[1]Besni State Hospital, Adıyaman, Türkiye.
[2]University of Health Sciences, Beyhekim Training and Research Hospital, Clinic of Emergency Medicine, Konya, Türkiye.
[3]Hasan Çalık State Hospital, Yeşilyurt, Türkiye.

Muhammet Gökhan Turtay / University of Health Sciences, Beyhekim Training and Research Hospital, Clinic of Emergency Medicine, Konya, Türkiye.

Introduction and Purpose: Objective: To examine the cases of earthquake victims who presented to the Emergency Department of Turgut Ozal Medical Centre (TOTM) at Inonu University following the 2023 Kahramanmaraş earthquakes and subsequent events.

Materials and Methods: Materials and Methods: In our study, we retrospectively examined the medical data of 467 patients who were brought to or admitted to TOTM emergency department due to the earthquakes centred in Kahramanmaraş. We analysed the patients' admission times, diagnoses, length of hospital stay, demographic data, triage codes, medical interventions, blood tests, haemodialysis needs, limb amputations, crush syndrome, discharge, and mortality rates. This information was recorded on patient evaluation forms. Subsequently, statistical analyses were conducted to determine the relationships between these data.

Results and Conclusion: Results: In our study, a total of 467 earthquake victims were admitted to the emergency department of our hospital. The mean age was 43.38±20.61, and the median age was 42 years. 73.7% of the patients arrived by their own means, and 25.1% by ambulance. Of the cases, 15.2% were diagnosed with crush injury, 11.3% with pneumothorax, 4.9% with acute renal failure, 4.3% with lower extremity fracture, 3.9% with hemothorax, 1.7% with vascular injury, 1.3% with upper extremity fracture, 1.3% with spinal cord injury, 0.9% with acute abdomen, 0.4% with pelvic hemorrhage, and 0.2% with intracranial hemorrhage, while 71.9% received other diagnoses. Of the cases that underwent intervention, 22.35% had fasciotomy, 15.08% had plaster casts/splints, 13.97% had central venous catheterization, 11.73% had fixation, 10.61% had reduction, 5.59% had suturing, 5.59% had hemodialysis, 3.91% had thoracotomy, 3.35% had tube thoracostomy, 3.35% had cardiopulmonary resuscitation, 2.79% had amputation, 1.12% had other interventions, and one patient underwent craniotomy. 63.6% of the cases were discharged, 28.3% were hospitalized, 3.4% died, 2.4% underwent emergency surgery, and 2.4% were referred to another hospital.Conclusion: Based on the findings of this study, hospital conditions should be thoroughly inspected to prepare for potential disasters, equipment and tools should be improved, personnel should be trained to be prepared for such disasters, and healthcare services should always be prepared.

Keywords: Crush syndrome, Disaster, Emergency

Ref No: 9632

Missed Pneumothorax Presenting as Cardiac Symptoms in a 92-Year-Old Patient

YAVUZ ÇELİK[1], HATİCE NEVA BAKİ[1], BAHADIR TAŞLIDERE[1], BAŞAR CANDER[1]

[1]Bezmialem Vakif University, Department of Emergency Medicine, Istanbul, Türkiye

HATİCE NEVA BAKİ / Bezmialem Vakif University, Department of Emergency Medicine, Istanbul, Türkiye

Introduction and Purpose: Spontaneous pneumothorax may present with atypical symptoms in very elderly patients, potentially leading to delayed diagnosis. We present a 92-year-old patient with cardiac-like symptoms and delayed diagnosis of pneumothorax.

Materials and Methods: A 92-year-old patient with a history of asthma, hypertension, chronic kidney disease, anemia, and multiple cardiac pacemaker replacements presented to the emergency department with chest tightness radiating to the back and left arm, hot flashes, and dyspnea. The patient had previously been evaluated at another center without a definitive diagnosis. Vital signs were notable for hypertension 174/87 mmHg, tachycardia 108/min, hypoxia (SpO_2: 79%) and respiratory rate of 22/min. ECG showed a ventricular paced rhythm, limiting assessment of ischemia. Laboratory findings included elevated urea, creatinine, CRP, and mildly elevated troponin I of 40.6 ng/L. Given the strong cardiac history, a cardiac etiology was initially suspected. Serial Troponin measurements demonstrated a plateau pattern rather than a dynamic rise and fall, supporting a non-acute coronary etiology. However, physical examination revealed decreased breath sounds in the left lower lung field. CT imaging subsequently confirmed a left-sided pneumothorax. A chest tube was inserted, resulted in complete re-expansion of the lung. The patient was admitted to ward for further management.

Figure 1: Left pneumothorax on a lung CT scan

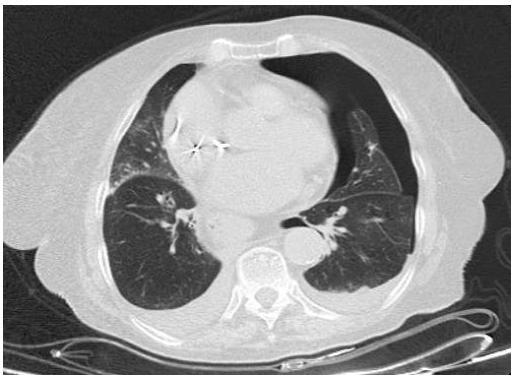

Figure 2: Chest X-ray after chest tube placement

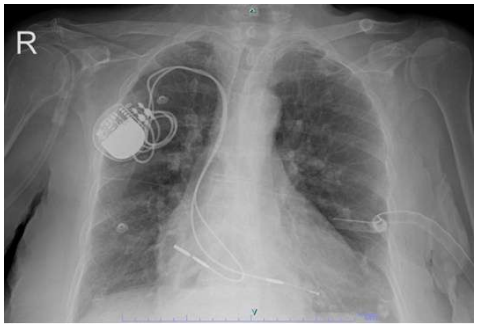

Results and Conclusion: This case highlights the diagnostic challenges of pneumothorax in elderly patients with multiple comorbidities. Symptoms may be nonspecific and easily attributed to cardiac causes, particularly in patients with pacemakers. Pneumothorax should be considered in the differential diagnosis of chest pain and dyspnea in elderly patients. Careful physical examination and timely imaging are essential to prevent delayed diagnosis.

Keywords: Spontaneous pneumothorax, Diagnostic delay, Elderly patient

---

Ref No: 9639

Predictors of Hospital Length of Stay in Patients with Pneumothorax: A Retrospective Study

Egemen Döner[1], Veli Görkem Pala[1], Erhan Durceylan[1], Cüneyt Arıkan[2]

[1]Eskişehir Osmangazi University Faculty of Medicine, Department of Chest Surgery, Eskişehir, Izmir
[2]Dokuz Eylul University Faculty of Medicine, Department of Emergency Medicine, Izmir, Turkey

Cüneyt Arıkan / Dokuz Eylul University Faculty of Medicine, Department of Emergency Medicine, Izmir, Turkey

Introduction and Purpose: Pneumothorax is a common emergency condition requiring hospitalization, often associated with variable clinical courses. Identifying factors that influence hospital length of stay (LOS) is essential for optimizing patient management and resource utilization. This study aimed to evaluate the LOS of patients admitted from the emergency department (ED) to the thoracic surgery service with a diagnosis of pneumothorax and to determine the clinical factors affecting LOS.

Materials and Methods: This retrospective cross-sectional study included 90 patients hospitalized with pneumothorax between 2024-2025. Demographic characteristics, clinical findings, and LOS were analyzed. Continuous variables were expressed as mean±standard deviation and median (minimum–maximum). Normality of distribution was assessed, and as data were non-normally distributed, non-parametric tests were applied. Group comparisons were performed using the Mann–Whitney U test and Kruskal–Wallis test. A multivariable linear regression model was constructed to identify independent predictors of LOS. A p-value < 0.05 was considered statistically significant.

Results and Conclusion: The mean age of patients was 54.26±20.81 years, with a median age of 58.5 (19–99) years. Of the patients, 70(77.8%) were male and 20(22.2%) were female. LOS ranged from 1 to 23 days, with a mean of 6.71±4.35 days and a median of 6.0 days. Patients who developed complications, particularly subcutaneous emphysema and infection, had significantly longer LOS ($p=0.044$ and $p < 0.001$, respectively). LOS was also significantly prolonged in patients who underwent tube thoracostomy, had prolonged air leak, presented with dyspnea, or experienced recurrent pneumothorax (all $p < 0.05$).In multivariable linear regression analysis, the model was statistically significant ($R^2=0.624$), explaining 62.4% of the variance in LOS. Independent predictors of increased LOS included the presence of complications ($\beta=0.404$; $p < 0.001$), tube thoracostomy ($\beta=0.255$; $p < 0.001$), prolonged air leak ($\beta=0.294$; $p < 0.001$), and recurrence of pneumothorax ($\beta=0.236$; $p=0.003$). Age, sex, and presenting symptoms were not significantly associated with LOS ($p > 0.05$). Hospital LOS in patients admitted with pneumothorax is significantly influenced by complications, need for tube thoracostomy, prolonged air leak, and recurrence. Among these, infection and prolonged air leak are particularly important contributors to extended hospitalization. Early identification of high-risk patients and targeted management strategies may help reduce LOS and improve clinical outcomes.

Table 1. Baseline Clinical and Demographic Characteristics of Patients

Variable	Category	n	%
Presenting Complaint	Dyspnea	36	40.1
	Pleuritic chest pain	21	23.3
	Cough	18	20.0
	Back pain	13	14.4
	Syncope	2	2.2
Type of Pneumothorax	Iatrogenic	20	22.2
	Spontaneous	55	61.1
	Traumatic	15	16.7
Side	Left	37	41.1
	Right	53	58.9
Location on CT	Apical	19	21.1
	Basal	23	25.6
	Lateral	31	34.4
	Total	17	18.9
Comorbidities	None	49	54.4

	Malignancy	17	18.9
	Rib fracture	15	16.7
	Bulla	6	6.7
	Hemothorax	4	4.4
	Empyema	2	2.2
	Other (unspecified)	5	5.5
Complications	None	79	87.8
	Infection	7	7.8
	Subcutaneous emphysema	4	4.4
Tube Thoracostomy	No	25	27.8
	Yes	65	72.2
Prolonged Air Leak	No	84	93.3
	Yes	6	6.7
Surgery due to Prolonged Air Leak	No	84	93.3
	Yes	6	6.7
Recurrent Pneumothorax	No	80	88.9
	Second episode	9	10.0
	≥3 episodes	1	1.1

Keywords: Pneumothorax, Length of stay, Tube thoracostomy

Ref No: 9741

Isolated Hyperammonemia Induced by Deferasirox Use: A Case Report

İsa Yıldırım[1], Ozan Deniz Keleş[1], Murat Teker[1], Selçuk Eren Çanakçı[1], Ayhan Aköz[1]

[1]Department of Emergency Medicine, Faculty of Medicine, Aydın Adnan Menderes University, Aydın, Turkey

İsa Yıldırım / Department of Emergency Medicine, Faculty of Medicine, Aydın Adnan Menderes University, Aydın, Turkey

Introduction and Purpose: Hyperammonemia is a critical clinical condition characterized by altered consciousness, typically developing due to liver failure, metabolic disorders, or specific drug toxicities. Deferasirox is an agent used in iron chelation therapy and may rarely lead to metabolic side effects. While similar cases have been previously identified in pediatric populations, this report aims to present a case of an adult patient presenting with isolated hyperammonemia thought to be induced by deferasirox use.

Materials and Methods: A 62-year-old female patient presented to the emergency department with confusion. Upon admission, her vital signs were stable; however, she was confused with impaired orientation to time and place, and her Glasgow Coma Scale was evaluated as 10. Neurological examination revealed bilateral isochoric pupils and active movement in all four extremities. The patient's medical history included deferasirox use for hemosiderosis.Laboratory tests showed liver and kidney function tests within normal limits, but isolated elevated ammonia levels were detected. Central nervous system imaging revealed no pathological findings, and central nervous system infection was excluded via lumbar puncture.Consultations were held with hematology and gastroenterology; acute hepatic pathology was ruled out. Based on clinical and laboratory findings, the patient was diagnosed with isolated hyperammonemia due to deferasirox. Deferasirox treatment was discontinued, and supportive therapy was initiated. Following three days in intensive care and two days of ward follow-up, the patient showed significant clinical improvement and was discharged.

Results and Conclusion: Isolated hyperammonemia is a rare cause in patients presenting with altered consciousness, and drug-related etiologies must be considered. Although hyperammonemia due to deferasirox is rare, clinical recovery can be achieved through early diagnosis and immediate discontinuation of the drug.

Keywords: Hyperammonemia, confusion, deferasirox

Ref No: 9780

Anatomical Location and Clinical Importance of the Superficial Sensory Branch of the Radial Nerve in De Quervain Tenosynovitis Surgery

Erdinç ACAR[1], Tevfik Onur ÖZDEMİR[1], Hasan Emre ÖZSOY[2], Olcayto OCAK[1]

[1]Ankara Bilkent City Hospital Department of Orthopedics and Traumatology Hand and Upper Limb Surgery Unit
[2]Ankara Bilkent City Hospital Department of Orthopedics and Traumatology

Erdinç ACAR / Ankara Bilkent City Hospital Department of Orthopedics and Traumatology
Hand and Upper Limb Surgery Unit

Introduction and Purpose: De Quervain tenosynovitis, first described by Fritz de Quervain, is a condition caused by the entrapment of the abductor pollicis longus (APL) and extensor pollicis brevis (EPB) tendons within the first extensor compartment. The aim of this study was to evaluate the anatomical location and clinical significance of the superficial sensory branch of the radial nerve in patients undergoing surgery for De Quervain tenosynovitis.

Materials and Methods: Five adult patients (4 females, 1 male) who underwent surgical treatment for De Quervain tenosynovitis between January 2025 and July 2025 were retrospectively analyzed. Diagnosis was based on patient history, physical examination (including Finkelstein and Eichhoff tests), and ultrasonography (USG). An oblique incision was used in all cases. The superficial sensory branch of the radial nerve was identified in all patients (Figure 1). The mean age of the patients was 32 years (range: 24–40), and the mean follow-up duration was 6 months (range: 8–10 months). Recurrence and patient satisfaction rates were evaluated. Particular attention was given to postoperative nerve injury complications.

Results and Conclusion: No recurrences were observed, and all patients reported satisfaction with the surgical outcomes. Due to its proximity to the surgical incision site, the superficial sensory branch of the radial nerve was anatomically identified and preserved in all cases (Figure 1). No complications were observed.In De Quervain tenosynovitis surgery, careful identification and preservation of the superficial sensory branch of the radial nerve, which is anatomically located near the incision site, along with adequate release of the first extensor compartment (Figure 2), enhances surgical success rates and reduces the risk of complications.

Figure 1



Figure 2



Keywords: Anatomy; De Quervain tenosynovitis; Superficial sensory branch of the radial nerve

---

Ref No: 9835

Association Between Platelet-to-Lymphocyte Ratio and Mortality in Patients with Urosepsis

Emre Oğur[1], Hacı Osman Toplu[2]

[1]Malatya Turgut Özal University, Faculty of Medicine, Department of Emergency Medicine
[2]Malatya Training and Research Hospital, Department of Anesthesiology

Emre Oğur / Malatya Turgut Özal University, Faculty of Medicine, Department of Emergency Medicine

Introduction and Purpose: Urosepsis is a serious clinical condition associated with high mortality, particularly in patients requiring intensive care. In this study, we aimed to evaluate the association between platelet-to-lymphocyte ratio (PLR), lymphocyte count, platelet count, and mortality in patients with urosepsis admitted from the emergency department to the intensive care unit.

Materials and Methods: This retrospective observational study included patients who presented to the emergency department and were admitted to the intensive care unit with a diagnosis of urosepsis between August 10, 2025, and January 10, 2026. A total of 34 patients who met the inclusion and exclusion criteria were enrolled in the study. Demographic characteristics and laboratory parameters at admission, including lymphocyte (×10⁹/L), platelet (×10⁹/L), and PLR values, were analyzed. Statistical analyses were performed using SPSS version 27.

Results and Conclusion: The mean age of the patients was 59.35±21.91 years, and the mortality rate was 17.6%. PLR values were significantly higher in the non-survivor group compared to the survivor group ($p < 0.001$). Although lymphocyte levels were lower in the non-survivor group, this difference did not reach statistical significance ($p=0.052$). No significant association was found between platelet count and mortality ($p=0.206$).PLR may be associated with mortality in patients with urosepsis and could serve as a practical marker for early risk stratification. However, further large-scale prospective studies are needed to validate these findings.

Keywords: Urosepsis, platelet-to-lymphocyte ratio, mortality

Ref No: 9855

Hypertrophic Cardiomyopathy presenting with Syncope

Enes Akınci[1], sultan tuna akgöl gür[1]

[1]atatürk university research hospital

Enes Akınci / atatürk university research hospital

Introduction and Purpose: Hypertrophic cardiomyopathy (HCM) is a often genetically inherited heart disease characterized by an abnormal thickening of the heart muscle (usually the left ventricle). It leads to stiffening of the heart muscle and makes it difficult for it to pump blood. It can increase the risk of sudden cardiac death in young people. Symptoms include shortness of breath, chest pain, fainting, and palpitations.

Materials and Methods: A 32-year-old male presented to the emergency department after a sudden episode of syncope that occurred during exercise. The loss of consciousness lasted approximately 30 seconds and resolved spontaneously without intervention. The patient reported mild chest pain and palpitations prior to the event. He had no known chronic illnesses and was not taking any medications.On physical examination, his blood pressure was 110/70 mmHg, heart rate was 96 beats per minute, and oxygen saturation was 98% on room air. Cardiovascular

examination revealed a mild systolic murmur. The remainder of the physical examination was unremarkable.Initial evaluation included an electrocardiogram, which showed normal sinus rhythm with non-specific ST segment changes. Cardiac troponin levels were within normal limits. At first glance, the presentation appeared consistent with a benign cause of syncope. However, the presence of syncope during exertion, accompanying chest pain, and a systolic murmur raised suspicion for a cardiac etiology.Given these high-risk features, bedside echocardiography was performed. The examination revealed septal hypertrophy and left ventricular outflow tract obstruction.Based on these findings, the patient was diagnosed with Hypertrophic Cardiomyopathy, a condition known to be one of the leading causes of sudden cardiac death in young adults. The patient was admitted for close monitoring, initiated on beta-blocker therapy, and referred for cardiology consultation. Further evaluation for implantable cardioverter-defibrillator placement was planned.

Results and Conclusion: In conclusion, not all syncope is benign. Emergency physicians must remain vigilant for underlying cardiac causes, as early recognition of hypertrophic cardiomyopathy can be life-saving and may prevent sudden cardiac death.

Keywords: hipertrophic cardiomyopathy, syncope

Ref No: 9870

Not just an adult emergency: traumatic penile fracture in a 4-year-old boy

Yasin Yağcılar[1], Yavuz Yılmaz[1], Ali Küçükosmanoğlu[1], Abidin Baran[1], Mehmet Gül[1]

[1]Emergency Medicine Department, Konya City Hospital, Türkiye

Yasin Yağcılar / Emergency Medicine Department, Konya City Hospital, Türkiye

Introduction and Purpose: Although penile trauma is rare in the pediatric age group, it may require early diagnosis and appropriate surgical management. Penile fracture, characterized by the disruption of the tunica albuginea, is more frequently reported in adults, with a limited number of cases in childhood. This case aims to present the clinical and imaging findings of a patient with a suspected penile fracture following trauma from a massage device.

Materials and Methods: A 4-year-old male patient presented with swelling and ecchymosis, which, according to the parents' statement, developed after a massage device was applied to the penis. Physical examination revealed diffuse edema, a subcutaneous hematoma extending to the suprapubic area, and partial penile deformity. Ultrasonography demonstrated a hematoma

reaching approximately 12 mm in thickness and an inability to visualize the full-thickness continuity of the tunica albuginea in the mid-shaft of the penis. There was no gross hematuria. The patient was admitted to the pediatric surgery department for surgical intervention and follow-up.

Results and Conclusion: Pediatric penile fracture is a rare urological emergency. The literature suggests that early surgical intervention improves functional and cosmetic outcomes. While ultrasonography aids in the diagnosis, clinical evaluation is the determining factor in the surgical decision-making process. Although the absence of gross hematuria reduces the likelihood of an associated urethral injury, careful monitoring is still required. Pediatric genital trauma caused by household appliances is a rare but potentially severe condition. Early presentation, careful physical examination, appropriate imaging, and a multidisciplinary approach are of critical importance in preventing complications.

Keywords: Pediatric Genital Trauma, Penile Fracture, Household Device Injury.

Ref No: 9924

Stroke Mimic: Carbon Monoxide Poisoning Presenting with Focal Neurological Deficit

Enes Akınci[1], Sultan Tuna Akgöl Gür[1]

[1]Atatürk University Research Hospital

Enes Akınci / Atatürk University Research Hospital

Introduction and Purpose: Acute onset speech disturbance and focal neurological deficits are commonly suggestive of cerebrovascular events in the emergency department, often prompting rapid activation of stroke protocols. However, certain toxicological conditions may closely mimic stroke, leading to potential misdiagnosis and inappropriate management if not carefully considered.

Materials and Methods: A 45-year-old male was brought to the emergency department with complaints of sudden onset speech difficulty and weakness in the right upper extremity. According to his relatives, the symptoms began upon waking in the morning. The patient also reported a mild headache and dizziness. His past medical history was unremarkable except for active smoking, and he was not on any regular medications.On initial evaluation, the patient was conscious with a Glasgow Coma Scale score of 15. Vital signs were within normal limits, with a blood pressure of 130/85 mmHg and a heart rate of 88 beats per minute. Neurological

examination revealed 3/5 muscle strength in the right upper extremity and mild dysarthria. These findings were highly suggestive of an acute ischemic stroke, and a stroke code was activated.An emergent non-contrast brain computed tomography scan was performed and revealed no acute pathology. While the initial imaging did not support a definitive diagnosis of stroke, the clinical suspicion remained high. However, during observation in the emergency department, the patient developed increasing agitation and mild confusion. Notably, a relative accompanying the patient also reported experiencing a headache.This additional history raised suspicion for a possible environmental or toxic exposure. Arterial blood gas analysis was obtained, which revealed a significantly elevated carboxyhemoglobin level of 28%.Based on these findings, the patient was diagnosed with Carbon Monoxide Poisoning, a well-known but often under-recognized cause of neurological symptoms that can mimic acute stroke. The patient was immediately treated with high-flow 100% oxygen therapy, and hyperbaric oxygen therapy was considered. Individuals sharing the same environment were also evaluated for exposure.

Results and Conclusion: In conclusion, although stroke is a critical diagnosis that requires rapid intervention, clinicians must remain cautious of mimics such as carbon monoxide poisoning. Early recognition is essential, as timely treatment can be life-saving and prevent serious neurological sequelae.

Keywords: Carbon Monoxide Poisoning, stroke

Ref No: 9927

Acute bilateral anterior shoulder dislocation developing during sports activity

Bekir Kılıç[1], Gökhan Yılmaz[1], Muhammet Gökhan Turtay[1], Ali Tayyip Kömürcü[1], Onur Metin[1], Nezime Beyza Yıldırım[1]
[1]University of Health Sciences, Beyhekim Training and Research Hospital, Clinic of Emergency Medicine, Konya, Türkiye.
Muhammet Gökhan Turtay / University of Health Sciences, Beyhekim Training and Research Hospital, Clinic of Emergency Medicine, Konya, Türkiye.

Introduction and Purpose: In this case report, we aimed to describe the diagnosis and management of bilateral shoulder dislocations that occurred during resistance exercise in a gymnasium.

Materials and Methods: A male patient in his thirties presented to the emergency department with sudden pain and loss of movement in both shoulders as a result of the weight accelerating upwards uncontrollably during a lat pulldown exercise in the gymnasium. A prominent epaulet sign was observed in both shoulders. The loss of deltoid contour and the prominence of the

acromion were remarkable. There was a severe limitation in both active and passive ranges of motion. Distal pulses were palpable, and motor and sensory examination findings were within normal limits; axillary nerve function was also preserved. As a result of clinical and radiological evaluation, the patient was diagnosed with bilateral anterior shoulder dislocation. Under monitoring, appropriate sedation and analgesia were administered. Bilateral closed reduction manoeuvres were performed successfully. Post-reduction pain decreased significantly, and the range of motion was regained. The post-reduction neurovascular examination was evaluated as normal. No complications developed. Shoulder immobilization was recommended for the patient, and he was referred to the orthopaedics outpatient clinic for follow-up.

Figure 1. Clinical anterior view of bilateral anterior shoulder dislocation (epaulet sign)



Figure 2. Chest X-ray showing anterior glenohumeral dislocation in both the right and left shoulders



Figure 3. Chest X-ray images after reduction of the right and left shoulders

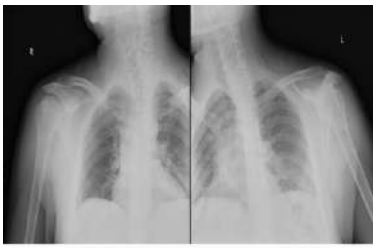

Results and Conclusion: It should be kept in mind that sudden overloads during resistance exercises can, although rare, lead to bilateral anterior shoulder dislocation.

Keywords: Bilateral shoulder dislocation, Anterior dislocation, Sports injuries

Ref No: 9932

Pulmonary embolism presenting with right upper quadrant pain: A case report

Şükran Rabia Yılmaz[1], Fatih Altunay[1], Muhammet Gökhan Turtay[1], Feyza Sandal[1], Birsen Ertekin[1], Onur Metin[1]
[1]University of Health Sciences, Beyhekim Training and Research Hospital, Clinic of Emergency Medicine, Konya, Türkiye.
Muhammet Gökhan Turtay / University of Health Sciences, Beyhekim Training and Research Hospital, Clinic of Emergency Medicine, Konya, Türkiye.

Introduction and Purpose: In this report, we present a case of pulmonary embolism presenting with right upper quadrant abdominal pain and emphasise the importance of considering atypical presentations in the differential diagnosis.

Materials and Methods: A 73-year-old female patient presented to the emergency department with complaints of right upper quadrant abdominal pain and cough that had persisted for two days. At the time of admission, her vital signs were as follows: oxygen saturation 95%, heart rate 83 beats/min, temperature 36.3 °C, and respiratory rate 15 breaths/min. On physical examination, rales were detected in the right hemithorax. Abdominal examination revealed tenderness in the right upper quadrant, and Murphy's sign was positive. Laboratory investigations revealed an elevated C-reactive protein level of 128 mg/L, whereas other laboratory parameters were within normal limits. Hepatobiliary system and abdominal ultrasonography findings were reported as normal. Due to the persistence of symptoms, contrast-enhanced abdominal computed tomography was performed. Although no intra-abdominal pathology was detected, an appearance compatible with a Hampton hump was observed in the basal lung sections included within the imaging field. Based on this finding, pulmonary embolism was suspected and pulmonary computed tomography (CT) angiography was planned. Pulmonary CT angiography demonstrated filling defects consistent with emboli in the pulmonary artery branches of the right middle and lower lobes. The patient was admitted to the Department of Chest Diseases. Treatment was initiated with low-molecular-weight heparin and acetylsalicylic acid. Venous Doppler ultrasonography of the lower extremities did not reveal deep vein thrombosis. Echocardiography demonstrated normal right heart chambers. After six days of hospitalisation, the patient was discharged with oral warfarin therapy.

Results and Conclusion: In patients presenting with right upper quadrant abdominal pain, pulmonary embolism should be considered in the differential diagnosis after hepatobiliary pathologies have been excluded.

POSTER PRESENTATIONS

Ref No: 1030

The importance of glucose measurement, even in trauma patients

Ali Ümit Arıgüloğlu[1], Murat Seyit[1], Mert Özen[1], Alten Oskay[1], Atakan Yılmaz[1], İbrahim Türkçüer[1]
[1]Pamukkale University Faculty of Medicine

Murat Seyit / Pamukkale University Faculty of Medicine

Introduction and Purpose: Routine capillary blood glucose measurement in the emergency department is rapid, inexpensive, and potentially life-saving, particularly in patients with known or suspected diabetes.

Materials and Methods: A 29-year-old male presented to the emergency department with a 2.5 cm laceration on the distal phalanx of the left fifth finger caused by a utility knife. He had been diagnosed with Type 2 Diabetes Mellitus one month earlier but reported irregular medication adherence. After the injury, he visited three external medical centers due to concerns about possible hand surgery; however, no intervention was performed. During this period, he developed nausea, vomiting, and fatigue. These symptoms were interpreted as hypoglycemia triggered by vasovagal reaction to the injury, and he received intravenous fluids and oral sugar supplementation without capillary blood glucose measurement or metabolic evaluation.Due to worsening symptoms, he presented to our emergency department. Vital signs were within normal limits, yet he appeared clinically ill. Given his diabetic history, bedside capillary glucose testing was immediately performed and revealed a blood glucose level of 390 mg/dL. Laboratory investigations demonstrated severe hyperglycemia, metabolic acidosis on arterial blood gas analysis, and positive urinary ketones. The finger examination showed a 2.5 cm laceration without active bleeding or neurovascular compromise, and no urgent surgical intervention was required.Based on clinical and laboratory findings, the patient was diagnosed with diabetic ketoacidosis (DKA). He was admitted for close monitoring and managed with intravenous hydration and appropriate metabolic correction. The laceration was sutured under sterile conditions. Over 12 hours of follow-up, metabolic parameters improved, ketonuria resolved, and the patient achieved clinical stabilization. He was subsequently referred for diabetes management and education.

Materials and Methods: This case highlights that minor traumatic presentations may mask life-threatening metabolic emergencies. Routine capillary blood glucose measurement in the emergency department is rapid, inexpensive, and potentially life-saving, particularly in patients with known or suspected diabetes.

Keywords: Capillary blood glucose, Emergency department, Type 2 Diabetes Mellitus

Ref No: 1039

Diagnostic Challenge of Acute Mesenteric Ischemia in a Young Patient

Erdem Zeki Karabulut[1], Mevlana Gül[1], Murteza Zafer[1]

[1]Ataturk University

Erdem Zeki Karabulut / Ataturk University

Introduction and Purpose: Acute mesenteric ischemia (AMI) is a rare but life-threatening condition with high mortality rates if diagnosis is delayed. It is typically associated with elderly patients and known vascular risk factors. However, atypical presentations in young patients without comorbidities can lead to diagnostic challenges in emergency settings.

Materials and Methods: A 29-year-old previously healthy male presented to the emergency department with sudden-onset, severe, diffuse abdominal pain. The pain was disproportionate to physical examination findings, with only minimal abdominal tenderness and no signs of peritonitis. Vital signs were within normal limits. Initial laboratory investigations revealed elevated serum lactate (4.6 mmol/L), while complete blood count and biochemical parameters were largely unremarkable. Abdominal ultrasonography did not reveal any significant pathology. Given persistent severe pain and elevated lactate, contrast-enhanced computed tomography angiography (CTA) was performed, which demonstrated a segmental thrombus in the superior mesenteric artery. Further workup, including thrombophilia screening, did not reveal an underlying cause.

Results and Conclusion: The patient underwent urgent endovascular thrombectomy with successful revascularization and favorable outcome. This case highlights that AMI may occur even in young patients without identifiable risk factors. Persistent severe abdominal pain disproportionate to examination findings and elevated lactate levels should raise suspicion. Early use of advanced imaging is crucial for timely diagnosis and improved survival.

Keywords: Mesenteric ischemia, abdominal pain, lactate

Ref No: 1043

Hemoptysis and Diffuse Alveolar Hemorrhage After Rituximab Therapy in a Patient with Myelofibrosis

Salih Necati İlhan[1], Murat Seyit[1], Mert Özen[1], Alten Oskay[1], Atakan Yılmaz[1], İbrahim Türkçüer[1]

[1]Pamukkale University Faculty of Medicine

Murat Seyit / Pamukkale University Faculty of Medicine

Introduction and Purpose: Hemoptysis is a potentially life-threatening condition that requires rapid evaluation and management. Diffuse alveolar hemorrhage (DAH) may occur secondary to hematologic malignancies, thrombocytopenia, autoimmune disorders, or rarely monoclonal antibody therapies such as Rituximab. Myelofibrosis is associated with cytopenias and thrombohemorrhagic complications. We present a case of acute hemoptysis with radiologically confirmed alveolar hemorrhage shortly after rituximab administration.

Materials and Methods: A 25-year-old male with known myelofibrosis and prior deep vein thrombosis presented to the emergency department with hemoptysis occurring one day after rituximab therapy. He reported approximately 100 mL of fresh blood expectoration within two hours. Vital signs revealed blood pressure 100/54 mmHg, respiratory rate 29–30/min, oxygen saturation 90% on 2–3 L/min oxygen, and pulse 112/min. He was alert (GCS 15). Lung auscultation demonstrated bilateral coarse crackles. Laboratory findings showed hemoglobin 7.3 g/dL, platelet count 71,000/µL, white blood cell count 18,000/µL, D-dimer 0.39 µg/mL, and INR 1.16. Thoracic computed tomography demonstrated bilateral ground-glass opacities consistent with diffuse alveolar hemorrhage.

CT Scan



Materials and Methods: The patient was treated with intravenous erythrocyte suspension, tranexamic acid, intravenous codeine, and inhaled adrenaline, resulting in clinical improvement. He was admitted to the pulmonology ward for close monitoring. In patients with hematologic malignancies, acute hemoptysis following rituximab therapy should raise suspicion for DAH. Early recognition and supportive management are essential to prevent respiratory deterioration.

Keywords: Hemoptysis, rituximab, thrombocytopenia

Ref No: 1076

Carbon monoxide poisoning

Merve Bulut[1], Ekrem Bulut[1], Mevlana Gül[1]
[1]Atatürk University Faculty of Medicine

Merve Bulut / Atatürk University Faculty of Medicine

Introduction and Purpose: Carbon monoxide (CO) poisoning is a leading cause of toxicological morbidity and mortality worldwide. It results in tissue hypoxia by impairing oxygen delivery and utilization. Neurological involvement is common and may lead to both acute and delayed complications. Early recognition and appropriate treatment, including consideration of hyperbaric oxygen therapy, are critical.

Materials and Methods: A 20-year-old male was found unconscious in an auto repair shop and brought to the emergency department. The exposure was suspected to have occurred in a poorly ventilated indoor environment.On admission, the patient had altered mental status with a Glasgow Coma Scale (GCS) score of 10 (E3V3M4). Vital signs were stable. Initial laboratory evaluation revealed a carboxyhemoglobin (COHb) level of 30%.Neurological examination was limited due to decreased consciousness, but no obvious lateralizing motor deficit was identified.Diffusion-weighted magnetic resonance imaging (MRI) of the brain demonstrated multiple punctate areas of diffusion restriction, consistent with acute hypoxic-ischemic injury.The patient was immediately treated with high-flow 100% oxygen. Given the elevated COHb level, loss of consciousness, and radiological evidence of cerebral involvement, hyperbaric oxygen therapy was considered and initiated.The patient was admitted to the intensive care unit for close monitoring and further management.

Materials and Methods: Carbon monoxide poisoning should be suspected in patients found unconscious in enclosed or poorly ventilated environments. Diffusion MRI is valuable in detecting early cerebral injury. Indications such as loss of consciousness, high COHb levels, and

neurological involvement should prompt consideration of hyperbaric oxygen therapy to reduce the risk of long-term neurological sequelae.

Keywords: Carbon monoxide poisoning, hyperbaric oxygen therapy, hypoxic-ischemic injury

---

Ref No: 1113

Antimicrobial Dynamics in Emergency Medicine: A Review of the Literature

Merih Şimşek[1], Levent Şahin[2]

[1]1Afyonkarahisar Health Sciences University, Faculty of Medicine, Department of Medical Microbiology, Afyon, Turkey
[2]2Kafkas University, Faculty of Medicine, Department of Emergency Medicine, Kars, Turkey

Merih Şimşek / 1Afyonkarahisar Health Sciences University, Faculty of Medicine, Department of Medical Microbiology, Afyon, Turkey

Introduction and Purpose: Currently, challenges persist in translating the rational use of antibiotics (ABs) into clinical practice, particularly in emergency medicine. Emergency departments (EDs) are interfaces in the relationship between individuals and hospital services. In particular, EDs are an important environment for addressing the problem of inappropriate AB prescribing and the accompanying antimicrobial resistance. The aim of this study is to provide practical recommendations for important strategies and methods that can be applied in EDs, based on existing evidence.

Materials and Methods: A retrospective worldwide literature review revealed statistically significant data and developed AB management systems in this area.

Results and Conclusion: According to the literature, appropriate EU usage should be established through local navigation. The American Infectious Diseases Society primarily recommends macrolides for community-acquired pneumonia, nitrofurantoin for uncomplicated cystitis, ciprofloxacin for pyelolephritis, clindamycin for skin abscesses, and cephalexin for cellulitis. The recommended duration of antibiotic use ranges from 3 to 7 days on average. According to the literature, various management systems exist regarding the use of antimicrobial drugs in AS. These include patient and physician education, the development of clinical treatment algorithms, the presence of an emergency department pharmacist in the emergency department, the use of antibiotic prescribing forms completed by the emergency physician and consulted by a pharmacist/infectious disease specialist, evaluation of drug use based on patient clinical and microbiology data 48-72 hours after antibiotic treatment, increased use of molecular and rapid diagnostic tests in the decision-making phase of antibiotic treatment in the emergency

department, antibiotic dose optimization, antibiogram applications, and the presence of computer-aided clinical decision support systems that consider patient history and local sensitivities related to the emergency department during the prescription phase, can recommend drugs, and provide feedback on treatment success. In conclusion, since not all antimicrobial strategies are suitable for all emergency departments, these strategy programs should be developed among stakeholders such as hospital administrators, pharmacists, local communities, and infectious disease specialists. However, the emergency department physician is the most critical expert in deciding on the correct antimicrobial treatment, possessing the ability to determine the most effective strategies taking into account all local sensitivities.

Keywords: Antibiotic, emergency department, antimicrobial treatment

---

Ref No: 1135

Hemolysis mimicking hemorrhage: an atypical presentation of cold agglutinin disease

Esra Elif Turğut, Nazire Belgin Akıllı, Hakan Akçırahan, Asiye Müminat Çap, Mehmet Gül

[1]Emergency Medicine Department, Konya City Hospital, Türkiye

Hakan Akçırahan / Emergency Medicine Department, Konya City Hospital, Türkiye

Introduction and Purpose: Cold agglutinin disease (CAD) is a rare subtype of autoimmune hemolytic anemia characterized by complement-mediated erythrocyte destruction. It is often a self-limiting condition that does not typically cause significant hemolysis. In this report, we aim to present a diagnostically challenging case of CAD that developed following an upper respiratory tract infection and presented with atypical findings initially mimicking active hemorrhage.

Materials and Methods: A patient with a medical history of hypertension, coronary artery disease, and a prior gastric ulcer presented to the emergency department (ED) with hematemesis and hematuria. These symptoms emerged following a one-week history of an upper respiratory tract infection. Upon admission, the patient's vital signs were stable. A nasogastric (NG) tube was inserted, yielding approximately 100 cubic centimeters (cc) of bloody gastric content. Concurrently, urinary catheterization drained approximately 600 cc of frankly hematuric urine. Laboratory investigations revealed an elevated total bilirubin level of 4.44 milligrams per deciliter (mg/dL), with a predominance of the indirect fraction. The lactate dehydrogenase (LDH) level was markedly elevated at 5321 units per liter (U/L), and haptoglobin was notably low.

Materials and Methods: Results and Conclusion:The direct Coombs test was positive, and the indirect Coombs test was strongly positive (+4). A peripheral blood smear demonstrated prominent erythrocyte agglutination, strongly supporting the diagnosis of CAD. The patient was admitted to the tertiary intensive care unit (ICU) for targeted therapy. While CAD typically presents with non-specific symptoms, presentations mimicking macroscopic gastrointestinal and urinary bleeding can rarely occur. This clinical picture can complicate the diagnostic process, particularly when confounded by comorbidities like gastric ulcers. CAD must be considered in the differential diagnosis for patients presenting with atypical bleeding-like symptoms, especially when accompanied by definitive biochemical markers of hemolysis.

Keywords: Cold agglutinin disease, hematemesis, hematuria

Ref No: 1157

Acute Aphasia Following Intravenous Contrast Administration: Stroke or Encephalopathy?

Ahmet Dursun DEMİR[1], Hızır Ufuk AKDEMİR[1]

[1]Department of Emergency Medicine, Ondokuz Mayıs University Faculty of Medicine, Samsun, Türkiye

Ahmet Dursun DEMİR / Department of Emergency Medicine, Ondokuz Mayıs University Faculty of Medicine, Samsun, Türkiye

Introduction and Purpose: Contrast-induced encephalopathy (CIE) is a rare and typically reversible neurological complication associated with the intravascular administration of iodinated contrast agents. Its clinical presentation may closely mimic acute cerebrovascular events, posing a significant diagnostic challenge in emergency settings and potentially leading to inappropriate therapeutic interventions.

Materials and Methods: A 49-year-old female with a history of hypertension and bladder tumor presented to the emergency department with acute onset of meaningless speech and behavioral changes following contrast-enhanced abdominal computed tomography. The patient was admitted approximately 12 hours after symptom onset. On neurological examination, she was conscious but demonstrated impaired speech output and inability to follow simple commands. Cranial nerve examination was normal, with no facial asymmetry or motor deficit. The National Institutes of Health Stroke Scale (NIHSS) score was estimated to be 3.Vital signs were stable. Laboratory investigations revealed mild leukocytosis, normal renal function, and a C-reactive

protein level of 3.2 mg/L. Arterial blood gas analysis demonstrated respiratory alkalosis. Brain computed tomography showed no acute abnormalities. Diffusion-weighted and susceptibility-weighted magnetic resonance imaging revealed no evidence of ischemia or hemorrhage. Electroencephalography findings were within normal limits.Based on clinical and radiological findings, contrast-induced encephalopathy was suspected, and the patient was closely monitored in the emergency department. Neurology consultation supported the diagnosis. During follow-up, neurological symptoms gradually improved and completely resolved within approximately 24 hours from symptom onset.

CT 1



CT 2



CT 3



MRI 1

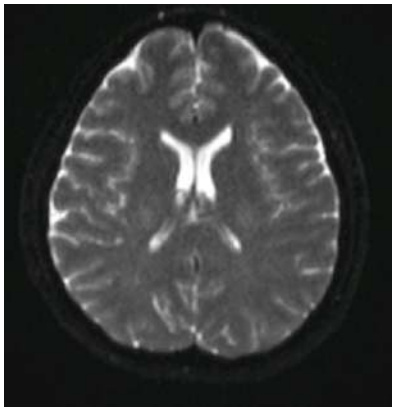

MRI 2

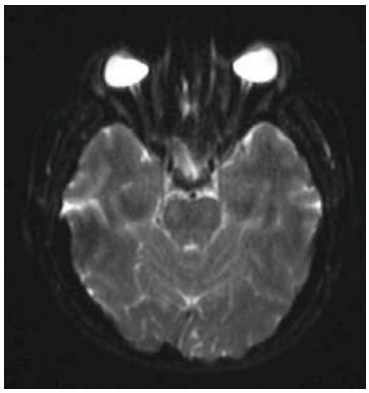

Materials and Methods: CIE should be considered in the differential diagnosis of acute neurological deficits following contrast exposure, particularly when neuroimaging findings are unremarkable. The absence of diffusion restriction and hemorrhagic changes, combined with rapid clinical recovery, are key diagnostic features. Early recognition of this condition is essential to avoid unnecessary and potentially harmful interventions, such as thrombolytic therapy. Increased clinical awareness may facilitate prompt diagnosis and appropriate management of stroke mimic cases.

Keywords: Contrast-induced encephalopathy, Acute aphasia, Stroke

---

Ref No: 1198

Massive Pulmonary Embolism In A Young Adult: A Case Report

Oğuz Yılmaz[1], Murat Seyit[1], Mert Özen[1], Alten Oskay[1], Atakan Yılmaz[1], İbrahim Türkçüer[1]

[1]Pamukkale University Faculty of Medicine

Murat Seyit / Pamukkale University Faculty of Medicine

Introduction and Purpose: Pulmonary embolism (PE) is a potentially fatal condition that can occur even in young individuals without known comorbidities. Early recognition and prompt reperfusion therapy are essential, particularly in cases with right ventricular dysfunction.

Materials and Methods: A 26-year-old male patient presented to the emergency department with shortness of breath. His symptoms had begun one week prior and included exertional dyspnea and pleuritic chest pain. He had no known chronic illnesses and was not taking any regular medications. The patient was an active smoker. His height was 170 cm and weight was 80 kg. Physical Examination and Vital Signs: On admission, vital signs were as follows: blood pressure 130/65 mmHg, heart rate 150 bpm, respiratory rate 20/min, oxygen saturation 95%, and body temperature 36.4°C. Physical examination revealed normal breath sounds with no additional pathological findings. Diagnostic Evaluation: Computed tomography pulmonary angiography demonstrated thromboembolic filling defects in both main pulmonary arteries, consistent with bilateral pulmonary embolism. Transthoracic echocardiography revealed right ventricular dilation and interventricular septal deviation, indicating right heart strain. Diagnosis and Treatment: The patient was diagnosed with massive pulmonary embolism associated with right ventricular dysfunction. Systemic thrombolytic therapy with alteplase was administered. Following treatment, the patient was admitted to the pulmonary intensive care unit for close monitoring.

Materials and Methods: This case highlights that pulmonary embolism should be considered in young patients presenting with dyspnea and pleuritic chest pain. The presence of right ventricular dysfunction warrants aggressive management, including thrombolytic therapy when indicated.

Keywords: Pulmonary Embolism, Thrombolytic Therapy, Right Ventricular Dysfunction

---

Ref No: 1207

Can celandine (Chelidonium majus) treat eye problems?

Bülent Kavuşturan[1], Halil Kaya[1], Yeşim Işler[1], Mehmet Oğuzhan Ay[1], Melih Yüksel[1], Umut Ocak[1], Neslihan Parmak Yener[2]

[1]University of Health Sciences, Bursa Yüksek İhtisas Training and Research Hospital, Department of Emergency Medicine, Bursa/Türkiye
[2]University of Health Sciences, Bursa Yüksek İhtisas Training and Research Hospital, Department of Ophthalmology, Bursa/Türkiye

Bülent Kavuşturan / University of Health Sciences, Bursa Yüksek İhtisas Training and Research Hospital, Department of Emergency Medicine, Bursa/Türkiye

Introduction and Purpose: The genus name comes from the Ancient Greek word for swallowwort. Swallows bring this plant to their nests if their young are blind. The Turkish name for the genus, "kırlangıçotu" (swallowwort), is also connected to this information. Wideley used in pubic herbal treatments. The leaves are consumed after cooking. It is poisonous. Contact with the eyes should be avoided. In addition, it has been used externally in the treatment of warts. The upper parts are applied to wounds, warts, boils, skin disorders, eczema, and eye problems.

Materials and Methods: A 54-year-old woman presented to the emergency room with complaints of redness, swelling, and blurred vision in her eyes. When asked if she was taking any medication, she stated that she had been using Kırlangıç otu fluid directly to the eye. When asked, she explained that she had read on social media that they reduced her need for glasses, and that she had gone to the countryside to collect them and applied them directly. An eye consultation revealed significant corneal damage, and she was placed under close observation. During treatment, autologous serum was also used. After one month of treatment, she achieved complete recovery.

Figure 1



Figure 2

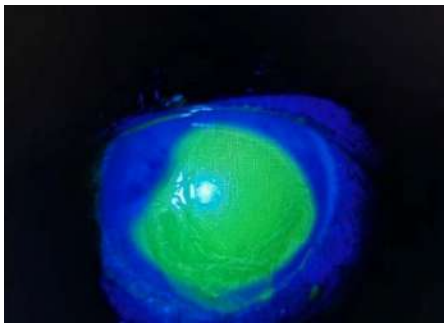

Figure 3

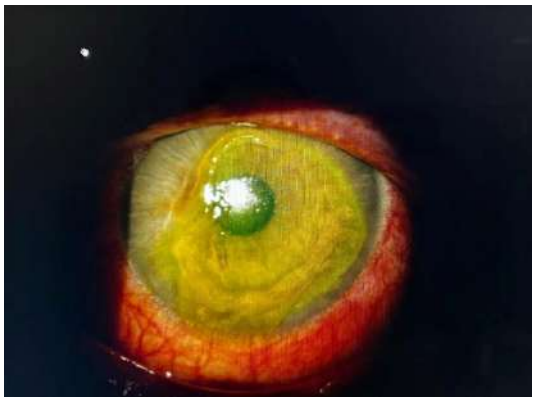

Results and Conclusion: Regarding the application of celandine liquid to the eye, "The plant known as 'glasses-breaking' among the public is heavily advertised. These drops are applied to the eye in non-sterile environments. Due to the toxic substances they contain, they can cause irritation, infections, and allergic reactions in a sensitive organ like the eye. These applications can lead to irreversible blindness or corneal transplantation. There is no study in the literature regarding any benefit of celandine in the eye. Our citizens need to be very careful. They should absolutely not do these things by following social media trends. They should definitely consult ophthalmologists.

Keywords: Chelidonium majus on eye problems, Herbal eye treatments, Swallowwort

---

Ref No: 1238

A Potentially Overlooked Cause of Dyspnea in Winter Tourism Centers: High-Altitude Pulmonary Edema (HAPE) Diagnosed via Point-of-Care Ultrasound (POCUS)

Muhammed Emin Akgün[1], Zeynep Çakır[1]

[1]Atatürk University

Muhammed Emin Akgün / Atatürk University

Introduction and Purpose: High-Altitude Pulmonary Edema (HAPE) is a potentially life-threatening form of non-cardiogenic pulmonary edema that typically develops following rapid ascent to altitudes exceeding 2500 meters. Patients presenting with dyspnea and cough to emergency departments situated within high-altitude winter tourism centers are frequently misdiagnosed with pneumonia, acute coronary syndrome, or decompensated heart failure. This report aims to describe a young patient who developed acute respiratory failure during a skiing vacation, where POCUS played a critical role in excluding cardiogenic causes, enabling a timely diagnosis of HAPE and successful management.

Materials and Methods: A 35-year-old male patient with no significant past medical history presented to the emergency department reporting progressive dyspnea, a dry cough, and pink frothy sputum. Symptoms began 48 hours after arriving at a high-altitude ski resort (~3100 meters) from a city at sea level. On physical examination, the patient appeared moderately distressed, tachypneic (respiratory rate 32/min), and tachycardic (heart rate 115/min), with an initial oxygen saturation (SpO2) of 75% on room air. Auscultation revealed diffuse crackles over the bilateral middle and lower lung fields. A bedside lung ultrasound performed by the emergency physician demonstrated diffuse, coalescent B-lines in both hemithoraces. Concurrent

focused transthoracic echocardiography (FoCUS) revealed normal left ventricular systolic function (ejection fraction 65%), no valvular pathology, and a normal inferior vena cava (IVC) diameter with inspiratory collapse of > 50%. Cardiogenic pulmonary edema was ruled out, and a diagnosis of HAPE was established. Immediate management included high-flow oxygen and non-invasive mechanical ventilation (CPAP), supplemented by oral nifedipine for its pulmonary vasodilatory effects. Within four hours, the patient's SpO2 improved to 94%.

Materials and Methods: Emergency physicians practicing in high-altitude regions and winter sports resorts must maintain a high index of suspicion for HAPE in tourists presenting with dyspnea, mandating a thorough recent travel history. Integrated lung and cardiac POCUS serves as an invaluable diagnostic tool, enabling rapid differentiation between cardiogenic and non-cardiogenic pulmonary edema within seconds. This rapid assessment is crucial for preventing inappropriate and potentially harmful therapies, such as empiric diuretic administration, in patients suffering from altitude-related pulmonary edema.

Keywords: POCUS, dsypne, pulmonary edema

Ref No: 1280

A Rare Cause of Acute Abdomen: Spontaneous Superior Mesenteric Artery (SMA) Dissection Diagnosed with POCUS

MUHAMMED EMİN AKGÜN[1], ZEYNEP ÇAKIR[1]

[1]ATATURK UNIVERSTY

MUHAMMED EMİN AKGÜN / ATATURK UNIVERSTY

Introduction and Purpose: Spontaneous isolated superior mesenteric artery (SMA) dissection is a rare but highly mortal cause of acute abdomen that develops in the absence of trauma or aortic dissection. It classically presents with severe abdominal pain, yet laboratory findings are frequently nonspecific. This report highlights the diagnostic power of point-of-care ultrasound (POCUS) in the rapid and specific diagnosis of acute abdominal pain, a condition that often poses a challenge in the differential diagnosis.

Materials and Methods: A 52-year-old male patient with a medical history notable only for hypertension presented to the emergency department (ED) with sudden-onset, severe abdominal pain radiating from the epigastrium to the back, accompanied by nausea, which began shortly after a meal. The abdominal examination revealed no guarding or rebound tenderness, and the

serum lactate level was within normal limits. Given the sudden onset and agonizing severity of the pain, the emergency physician performed an abdominal POCUS (focusing on the aorta and its major branches). While no dissection was observed in the abdominal aorta, an intimal flap (double-lumen sign) was detected approximately 2 cm distal to the SMA ostium in the epigastric region. An emergent contrast-enhanced abdominal CT angiography confirmed an isolated type 2 spontaneous SMA dissection. The patient, who showed no clinical or radiological evidence of bowel ischemia, was admitted by the cardiovascular surgery (CVS) department for conservative medical management, including anticoagulation and antihypertensive therapy.Discussion: Mesenteric ischemia remains one of the frequently missed diagnoses in the ED. Spontaneous SMA dissection closely mimics mesenteric embolism with its classic clinical presentation of "pain out of proportion to physical examination findings." As noted in Tintinalli's Emergency Medicine, although CT angiography is the gold standard, the utilization of POCUS by a proficient emergency physician can reduce the time to diagnosis to mere minutes.

Materials and Methods: POCUS serves as the modern emergency physician's stethoscope, capable of identifying not only free intra-abdominal fluid or gallstones but also critical major vascular pathologies. Screening the SMA via POCUS should become a life-saving, reflexive practice when evaluating patients presenting with atypical, agonizing abdominal pain.

Keywords: Superior Mesenteric Artery, AORTİC DİSSECTİON., POCUS

Ref No: 1330

DISRUPTED STABILITY

Nisa Mındız[1], İBRAHİM ÖZLÜ[1], EKREM BULUT[1]

[1]ATATÜRK UNIVERSITY EMERGENCY MEDICINE

Nisa Mındız / ATATÜRK UNIVERSITY EMERGENCY MEDICINE

Introduction and Purpose: Pelvic injuries are among the most serious consequences of blunt trauma, particularly in high-energy mechanisms such as motor vehicle accidents. Although less common in the pediatric population compared to adults, pelvic fractures and diastasis can be associated with significant morbidity. Early recognition and appropriate management are essential to prevent complications.

Materials and Methods: A 13-year-old male patient was brought to the emergency department following an in-vehicle traffic accident. On admission, the Glasgow Coma Scale (GCS) score

was 14. Vital signs revealed a blood pressure of 122/68 mmHg and a pulse rate of 98 beats/min.On physical examination, tenderness was present in the lower abdominal quadrants. Pain was elicited upon compression over the anterior superior iliac spine (ASIS).Computed tomography (CT) imaging was performed for diagnostic evaluation. Imaging revealed a fracture of the left pubic ramus along with pelvic diastasis.The patient was consulted with the orthopedic department and was admitted for further management and follow-up.

PHOTO 1

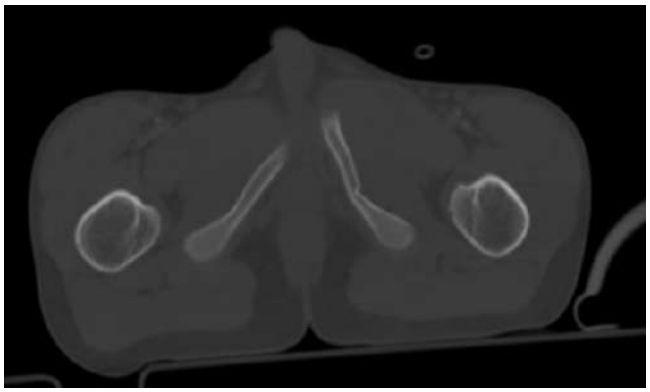

Materials and Methods: Pelvic trauma in pediatric patients is relatively rare but can result from high-energy mechanisms such as motor vehicle accidents. Due to the elasticity of the pediatric pelvis, fractures may be less common; however, when present, they may indicate significant force and potential associated injuries.Pelvic diastasis typically involves disruption of the pubic symphysis and may be associated with ligamentous injury. Clinical findings such as localized pain and tenderness, especially with pelvic compression, are important diagnostic clues.Computed tomography plays a crucial role in identifying pelvic fractures and associated injuries, providing detailed anatomical information necessary for management planning.Management depends on the severity of injury and hemodynamic stability. Stable patients are often managed conservatively, while unstable injuries may require surgical intervention.

Keywords: Pelvic diastasis, pelvic fracture, blunt trauma

Ref No: 1357

Deep vein thrombosis presenting with knee pain: The critical role of point-of-care ultrasound

Dr. Enes YILMAZ[1], Dr. Merve BULUT[1], Asst. Prof. Dr. Sultan Tuna AKGÖL GÜR[1]

[1]Ataturk University Emergency Department

Dr. Merve BULUT / Ataturk University Emergency Department

Introduction and Purpose: Deep vein thrombosis (DVT) typically presents with classical symptoms such as unilateral leg swelling, warmth, and calf tenderness. However, atypical clinical presentations can lead to diagnostic delays and life-threatening complications like pulmonary embolism. The objective of this report is to present a case of DVT in a patient presenting with isolated knee pain and the utility of point-of-care ultrasound (POCUS) in the emergency department (ED) for rapid diagnosis.

Materials and Methods: A 55-year-old female patient presented to the ED with a six-day history of left knee pain following a twisting injury (stepping awkwardly). The patient had no known systemic diseases or a history of prior surgeries. Initial vital signs were stable: blood pressure 133/85 mmHg, pulse 79 bpm, and oxygen saturation 93%. Physical examination revealed a natural neurovascular status and a normal range of joint motion. On inspection, a minimal circumference difference was noted in the left femoral region without associated heat increase.

Results and Conclusion: Due to the clinical suspicion arising from the limb circumference discrepancy, a bedside POCUS was performed. Evaluation of the left popliteal vein revealed hyperechoic thrombus images that only partially allowed for vein compression. Following the diagnosis of DVT, low molecular weight heparin (LMWH) was initiated. The patient was discharged with an LMWH prescription and referred to the outpatient clinic for follow-up. In conclusion, DVT should be considered in the differential diagnosis of lower extremity pain, even when symptoms are localized to the knee or follow minor trauma. Bedside ultrasound is a crucial tool for emergency physicians to ensure rapid diagnosis and treatment in such atypical cases.

left popliteal vein noncompressed



left popliteal vein compressed



Keywords: Deep vein thrombosis, Knee pain, Point-of-care ultrasound

Ref No: 1402

Thoracoabdominal Gunshot Injury

Ekrem Bulut[1], Merve Bulut[1], Ayça Çalbay[1]

[1]Ataturk University Faculty of Medicine

Ekrem Bulut / Ataturk University Faculty of Medicine

Introduction and Purpose: In firearm injuries, the kinetic energy of the projectile and its trajectory may cause unpredictable and destructive damage to adjacent cavities, independent of entry and exit wounds. Thoracoabdominal injuries carry a high mortality risk due to potential involvement of both thoracic and intraabdominal organs. We present the multidisciplinary emergency department management of a patient who appeared hemodynamically stable after a self-inflicted gunshot wound but was found to have major intrathoracic and intraabdominal injuries.

Materials and Methods: A 23-year-old woman was brought to the emergency department by emergency medical services after a self-inflicted gunshot wound to the left chest. On primary survey, the airway was patent and the Glasgow Coma Scale (GCS) score was 15. Vital signs were notable only for sinus tachycardia (118 bpm) (BP 110/70 mmHg, SpO_2 96%). Secondary examination revealed an entry wound at the left 4th–5th intercostal space and an exit wound at the lateral aspect of the left 9th rib(figure-1). Bedside e-FAST showed no pericardial fluid but detected intraabdominal free fluid. Whole-body trauma CT demonstrated bilateral pneumothorax, a fracture of the left 9th rib, and intraperitoneal free air consistent with hollow viscus perforation(figure-2,3,4,5). With a simultaneous multidisciplinary approach, bilateral tube thoracostomy was performed in the emergency department by thoracic surgery. As the patient remained hemodynamically stable, she was admitted to the intensive care unit for urgent operative management by general surgery for repair of intraabdominal perforation and close monitoring.

figure-1

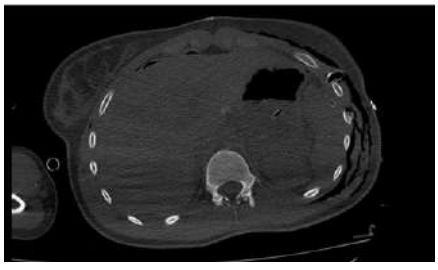

figure-2

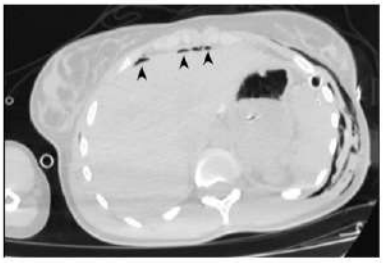

figure-3



figure-4

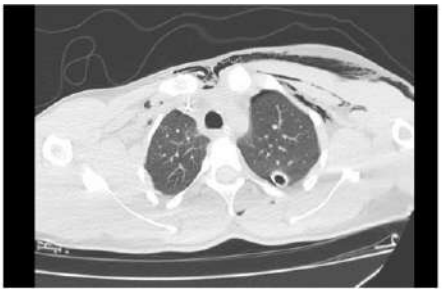

figure-5



Materials and Methods: In thoracoabdominal gunshot injuries, misleading "honeymoon" periods with normal vital signs may occur. Anatomical displacement of the diaphragm during respiration may allow thoracic entry wounds to involve intraabdominal organs. In this case, bilateral pneumothorax despite a left-sided thoracic trajectory highlights the blast effect of the projectile. Adherence to advanced trauma life support principles, rapid use of POCUS and CT, and early integration of surgical specialties are key life-saving components in the management of thoracoabdominal trauma.

Keywords: gunshot, pneumothorax, viscus perforation

Ref No: 1406

MAXİLLOFACİAL TRAUMA

Merve Bulut[1], Ekrem Bulut[1], Mevlana Gül[1]

[1]Atatürk University Faculty of Medicine

Merve Bulut / Atatürk University Faculty of Medicine

Introduction and Purpose: A horse kick is one of the high-energy blunt traumas and is frequently seen in individuals working in rural areas. In addition to causing maxillofacial injuries, it can be associated with other morbidities such as intracranial hemorrhages, cervical spine injuries, and thoracoabdominal organ damage.

Materials and Methods: A 63-year-old male patient presented to the emergency department following a horse kick. The patient was conscious but described significant facial deformity and widespread facial pain. On physical examination, there were periorbital ecchymosis and edema, nasal deformity with epistaxis, tenderness in the maxilla and zygomatic regions, malocclusion and dental trauma, as well as lacerations and soft tissue injuries. Imaging studies revealed bilateral maxillary fractures, a left zygomatic arch fracture, a nasal bone fracture, and mild subcutaneous emphysema (Figures 1, 2).The patient was managed conservatively in the emergency department due to hemodynamic stability. Analgesics and intravenous hydration were initiated for pain management. An anterior nasal packing was applied to control the epistaxis, and consultations with the plastic surgery and otolaryngology departments were obtained regarding the maxillofacial fractures. The patient was admitted to the maxillofacial surgery clinic for surgical repair of the fractures.

Materials and Methods: Trauma resulting from a horse kick is a high-energy injury that can lead to serious maxillofacial fractures. The maxilla and zygomatic bones are among the most commonly affected structures.A multidisciplinary approach is essential in such traumas. Airway security should be prioritized in these patients. In patients with facial fractures, a cranial nerve examination should be performed and additional head trauma should be carefully evaluated. The type of fractures should be determined through imaging, and surgical intervention should be planned if necessary.

Keywords: Maxillofacial Trauma, Horse Kick, Fracture

Ref No: 1425

A rare cause of acute abdomen: Uterocolonic fistula

Sultan Cennet Çakar[1], Gülbanu Emrem[1], Ayşe Ertekin[1]

[1]Afyonkarahisar Health Sciences University, Department of Emergency Medicine, Afyonkarahisar, Türkiye

Gülbanu Emrem / Afyonkarahisar Health Sciences University, Department of Emergency Medicine, Afyonkarahisar, Türkiye

Introduction and Purpose: Uterocolonic fistula is an extremely rare condition usually associated with diverticular disease, malignancy, or inflammatory processes. Due to nonspecific clinical findings, diagnosis may be delayed. This study aims to present a rare case of uterocolonic fistula causing acute abdomen and to emphasize the importance of early imaging and a multidisciplinary approach.

Materials and Methods: A 75-year-old female patient presented to the emergency department with abdominal pain and vomiting for two days. Her medical history included diabetes mellitus, atrial fibrillation, and a known uterine mass. Tachycardia was noted in vital signs. Physical examination revealed diffuse abdominal tenderness and a palpable mass-like rigidity in the lower abdomen. Laboratory tests showed significant hyperglycemia, elevated C-reactive protein, acute kidney injury, and hyponatremia. Abdominal computed tomography (CT) demonstrated air within the uterine cavity and perforation of colonic loops into the uterus (Figure 1). Intravenous fluid therapy and broad-spectrum antibiotics (ceftriaxone and metronidazole) were initiated, and consultations with general surgery and gynecology were performed.

Abdominal CT images revealing air within the uterine cavity and perforation of colonic loops into the uterus

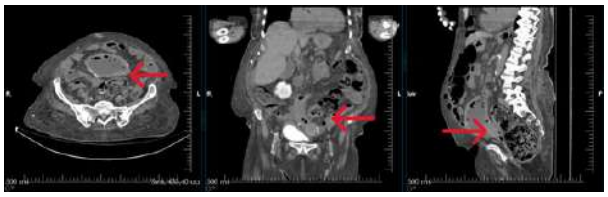

figure: Abdominal CT images revealing air within the uterine cavity and perforation of colonic loops into the uterus (arrows)

Materials and Methods: Following multidisciplinary evaluation, the patient underwent emergency surgery. Uterocolonic fistula is a rare but important cause of acute abdomen, especially in elderly patients with underlying uterine pathology. CT plays a critical role in diagnosis. Early diagnosis and prompt surgical intervention are essential to reduce morbidity and mortality.

Keywords: Uterocolonic fistula, acute abdomen, emergency department

---

Ref No: 1437

AIR IS ONLY BEAUTIFUL INSIDE THE ALVEOLI

Yusuf Burak Eker[1], Fatma Tortum[1], Nisa Mındız[1]

[1]Atatürk Üniversitesi Tıp Fakültesi Acil Tıp Anabilim Dalı

Yusuf Burak Eker / Atatürk Üniversitesi Tıp Fakültesi Acil Tıp Anabilim Dalı

Introduction and Purpose: Pneumomediastinum is defined as the presence of free air within the mediastinum. The underlying mechanism typically involves alveolar rupture, where the released air tracks along the hilum of the affected lung into the mediastinum and subsequently spreads to the subcutaneous tissues of the chest or neck (the Macklin effect). Additionally, rupture or perforation of the major airways or the esophagus can lead to the same clinical presentation. Pneumomediastinum is classified based on its etiology. Secondary or acquired pneumomediastinum usually develops following thoracic or abdominal surgery, foreign body aspiration, cardiac catheterization, endotracheal intubation, or mechanical ventilation. Another

common cause is blunt or penetrating neck and chest trauma that damages tracheobronchial structures.

Materials and Methods: A 51-year-old male presented to our emergency department with complaints of intensifying pain in the neck and chest, swelling, and dyspnea following an awkward or sudden movement. The patient reported a history of a fall two weeks prior, during which he sustained rib fractures that did not require hospitalization or surgical intervention at the time. However, his persistent pain had significantly worsened over the last few hours, accompanied by newly developed swelling in the chest and neck areas. His medical history was otherwise unremarkable. Upon admission, his oxygen saturation was 92% on room air. Systemic physical examination revealed subcutaneous crepitus upon palpation of the neck region, with no other significant pathologies. Based on a preliminary diagnosis of pneumomediastinum, a thoracic computed tomography (CT) scan was performed. The diagnosis was confirmed, and the patient was admitted to the thoracic surgery clinic for further management.

figure

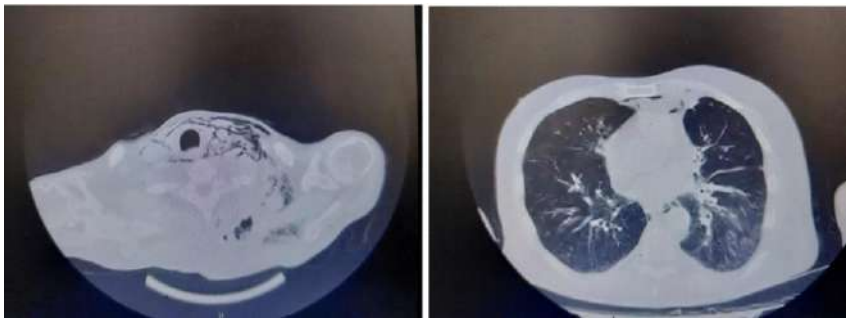

Materials and Methods: Pneumomediastinum can result from internal or external trauma, or it may occur spontaneously. As demonstrated in our case, alveolar injury can occur secondary to an existing rib fracture. Therefore, patients with rib fractures remain at risk for developing pneumomediastinum, even during the late post-traumatic period.

Keywords: Pneumomediastinum, Subcutaneous emphysema, Rib fracture

Ref No: 1475

Peritonsillar Abscess

Kadir Akburun[1], Murat Seyit[1], Alten Oskay[1], Atakan Yılmaz[1], Mert Özen[1], İbrahim Türkçüer[1]

[1]Pamukkale University Faculty of Medicine

Murat Seyit / Pamukkale University Faculty of Medicine

Introduction and Purpose: Sore throat is commonly attributed to viral pharyngitis. However, unilateral severe pain, dysphagia, and changes in speech should raise concern for a potential complication. Prompt recognition of peritonsillar abscess is essential to prevent airway compromise and deep neck space infections.

Materials and Methods: A 27-year-old man presented with progressively worsening sore throat over five days. Initially mild, the pain had significantly intensified during the previous two days. He reported difficulty swallowing and stated, “I cannot fully open my mouth.” Fever was present. Vital Signs: Blood pressure was 118/74 mmHg, heart rate 104 beats/min, body temperature 38.6°C, and oxygen saturation 99% on room air. Physical Examination:The left tonsil was markedly edematous and displaced medially. The uvula was deviated to the right. Trismus was evident. Laboratory Findings: Leukocyte count was 15,800/mm³, and C-reactive protein was elevated. Imaging: Although the diagnosis was clinically apparent, contrast-enhanced neck computed tomography demonstrated a 2.5 cm abscess collection in the left peritonsillar space.

Materials and Methods: Needle aspiration and drainage were performed in the emergency department, followed by initiation of intravenous antibiotic therapy. Symptoms improved rapidly. In patients with unilateral severe throat pain, trismus, and uvular deviation, peritonsillar abscess must be considered rather than simple pharyngitis. Early drainage prevents serious complications.

Keywords: Peritonsillar abscess, Deep neck infection, Trismus

Ref No: 1500

Sudden-onset imbalance and dizziness: Pituitary macroadenomas

Duygu Aras Seyit[1], Murat Seyit[2]

[1]ERPA Saglik Hospital, Denizli
[2]Pamukkale University Faculty of Medicine

Murat Seyit / Pamukkale University Faculty of Medicine

Introduction and Purpose: Pituitary macroadenomas are tumours that develop in the pituitary gland, are larger than 10 mm in diameter, and are generally benign. Macroadenomas cause visual disturbances, headaches and hypopituitarism by compressing surrounding structures. ACTH deficiency manifests itself with symptoms such as fatigue, joint pain, weight loss, dizziness, and nausea and vomiting. We present the case of a patient who presented with sudden onset of dizziness and imbalance; a macroadenoma was identified in the pituitary gland on the initial brain MRI, and a 17 mm macroadenoma was subsequently detected on a contrast-enhanced pituitary MRI, leading to referral for surgery.

Materials and Methods: A 53-year-old male patient presented with sudden-onset imbalance and dizziness. The patient, who had no known pre-existing medical conditions, exhibited ataxia on tandem gait during the neurological examination. Blood tests were normal, and a brain MRI performed to investigate possible cranial pathologies revealed a pituitary macroadenoma. Following the identification of a 17 mm macroadenoma with haemorrhage on a contrast-enhanced pituitary MRI performed for definitive diagnosis, the patient was referred for surgical treatment. The patient underwent surgery and was discharged without sequelae. Hormone therapy was initiated by the Endocrinology department.

MRI

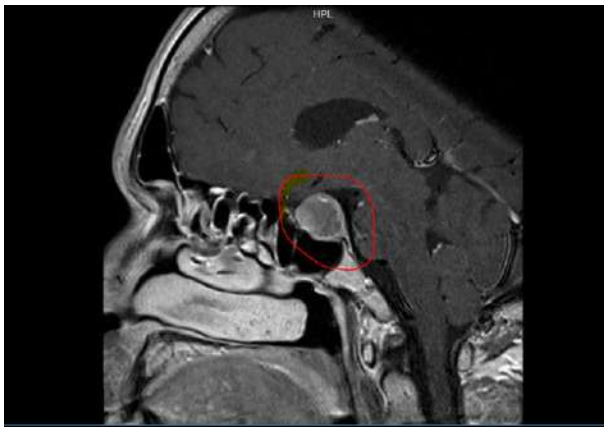

MRI

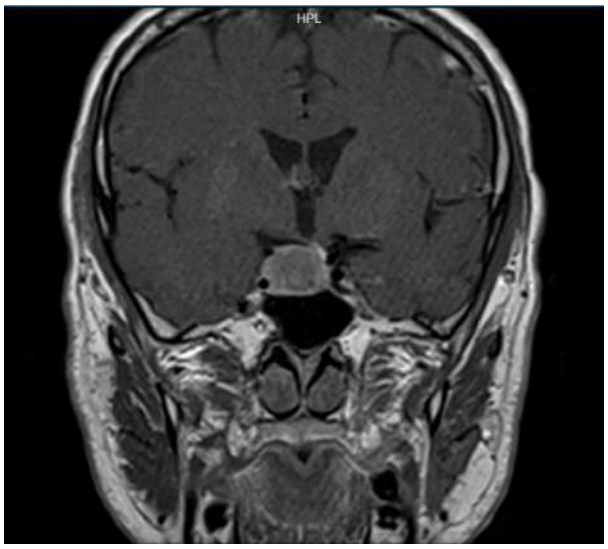

Materials and Methods: Pituitary macroadenomas are lesions originating from the sellar region, measuring more than 10 mm in size and exhibiting extrasellar extension. The most common symptoms are headache, visual disturbances and hypopituitarism due to mass effect. However, 15–20% of these cases are detected incidentally, with no clinical symptoms present. Although headaches are present in the majority of cases, they may also lead to hormonal imbalances and symptoms such as nausea and vomiting. Occasionally, haemorrhage within the lesion may occur, leading to more acute symptoms. In patients presenting with acute-onset headaches, visual disturbances, or dizziness, pituitary pathologies must always be considered.

Keywords: Pituitary macroadenomas, headache, dizziness

Ref No: 1522

A Rare Cause of Jaundice: Malignancy in Mirizzi Syndrome

Şamil Altay Besler[1]

[1]SBÜ Şanlıurfa Mehmet Akif İnan Eğitim ve Araştırma Hastanesi, Acil Tıp Kliniği

Şamil Altay Besler / SBÜ Şanlıurfa Mehmet Akif İnan Eğitim ve Araştırma Hastanesi, Acil Tıp Kliniği

Introduction and Purpose: Mirizzi syndrome is a rare condition caused by obstruction of the main bile duct or hepatic duct due to external pressure from multiple or a single large gallstone in the gallbladder. It presents with clinical similarities to cholecystitis. Due to the presence of jaundice, it can be confused with complicated clinical conditions such as choledocholithiasis or cholangitis. In this case report, we wanted to emphasize that malignancy can also play a role as an obstructive cause in the pathogenesis of Mirizzi syndrome.

Materials and Methods: A 60-year-old male patient presented to our emergency department with complaints of jaundice and abdominal pain that had been present for 2 weeks. His general condition was moderate, and physical examination revealed tenderness in the upper right quadrant of the abdomen and widespread scleral jaundice. Vital signs were normal. Blood tests showed ALT 236 U/L (upper limit 50), AST 89.8 U/L (upper limit 50), total bilirubin 6.88 mg/dl (upper limit 1.2), direct bilirubin 6.6 mg/dl (upper limit 0.3), and GGT 423 IU/L (upper limit 60); other parameters were within normal limits. Contrast-enhanced abdominal computed tomography (CT) revealed a gallstone up to 1 cm in the lumen of the gallbladder and increased gallbladder wall thickness. Dilation of the intrahepatic biliary tracts beyond the common biliary tract junction was considered suggestive of Mirizzi syndrome. Ultrasonography (US) revealed a suspicious mass within the lumen at the level of the main hepatic duct, which was found to be significant for Klatskin tumor. The patient was admitted to the gastroenterology department and underwent endoscopic retrograde cholangiopancreatography (ERCP) one day later. A stent was placed in the common bile duct, and the existing endoscopic appearance was evaluated as consistent with bismuth type 1 cholangiocellular carcinoma. A general surgery consultation was held, and surgery for resection was planned. After 10 days of follow-up in the ward following surgery, the patient was discharged in good health.

Results and Conclusion: In cases of persistent abdominal pain and non-specific symptoms such as jaundice, underlying biliary tract pathologies should be investigated. Although often caused by benign processes, malignancy should also be considered in the etiology of Mirizzi syndrome.

Keywords: Mirizzi syndrome, jaundice, cholangiocellular carcinoma

Ref No: 1541

Ischemic Stroke In A Young Patient Presenting With Seizure

Dilar Dikici[1], Murat Seyit[1], Duygu Aras Seyit[1], Atakan Yılmaz[1], Mert Özen[1], Alten Oskay[1]

[1]Pamukkale University Faculty of Medicine

Murat Seyit / Pamukkale University Faculty of Medicine

Introduction and Purpose: Ischemic stroke results from thrombotic or embolic occlusion of cerebral arteries, leading to acute cerebral ischemia and infarction. Neuronal membrane instability, glutamate-mediated excitotoxicity, and ionic imbalance during ischemia may trigger seizures. Post-stroke seizures are classified as early (within 7 days) or late (after 7 days). Cortical involvement and large infarct size increase seizure risk. Early recognition and management are essential to prevent secondary brain injury and improve outcomes.

Materials and Methods: A 36-year-old male with no known chronic medical history was brought to the emergency department after a generalized tonic–clonic seizure lasting approximately three minutes. Relatives reported severe headache, decreased activity, and reduced responsiveness for three days prior to admission. On arrival, the patient was in a postictal state. He was monitored, intravenous access was established, and laboratory tests were obtained. During brain computed tomography (CT), the patient experienced another seizure and was intubated for airway protection.Brain CT revealed loss of gray–white matter differentiation, sulcal effacement, and hypodensity in the right frontotemporal region within the middle cerebral artery (MCA) territory. A hyperdense MCA sign at the M1–M2 level was consistent with acute ischemic stroke. Neurology and interventional radiology consultations were obtained for reperfusion therapy evaluation. Diffusion MRI and CT angiography were performed. The patient was admitted to the intensive care unit for close monitoring and further management.

Materials and Methods: Ischemic stroke may occur in young patients without known risk factors and may present with seizures. Early neuroimaging and multidisciplinary management are critical for timely diagnosis and improved outcomes.

Keywords: İschemic stroke, young patient, seizure

Ref No: 1593

Diagnostic Challenges in Bariatric Emergencies: A Case of Profound Hyponatremia

Julide Gurbuz[1], Onur Bozdag[1], Emre Sonmez[1], Bahadir Taslidere[1], Basar Cander[1]

[1]Bezmialem Foundation University Hospital, Department of Emergency Medicine, İstanbul, Turkey

Emre Sonmez / Bezmialem Foundation University Hospital, Department of Emergency Medicine, İstanbul, Turkey

Introduction and Purpose: Hyponatremia, defined as a serum sodium concentration below 136 mmol/L, is a common and potentially fatal electrolyte imbalance that can lead to cerebral edema, seizures, and cardiac arrest. In emergency medicine, the management of this condition becomes exceptionally complex when paired with morbid obesity due to altered respiratory mechanics and systemic comorbidities. This case report aims to evaluate the diagnostic, logistical, and technical challenges encountered during the management of a morbidly obese patient presenting with profound hyponatremia (103 mmol/L) emphasizing the critical need for specialized bariatric emergency infrastructure.

Materials and Methods: A 68-year-old bedridden, morbidly obese female presented with aphasia and loss of consciousness. The patient arrived at the emergency department in cardiac arrest, and return of spontaneous circulation (ROSC) was achieved after 20 minutes of cardiopulmonary resuscitation. Initial laboratory findings revealed profound hyponatremia (Na: 103 mmol/L), severe metabolic acidosis (pH: 7.17), and signs of infection (WBC: 20.53 x $10^3/\mu L$). Management included mechanical ventilation, inotropic support, and slow sodium replacement using 3% hypertonic saline. Diagnostic efforts were severely hindered by the patient's habitus; the facility lacked obesity-compatible equipment, necessitating an external transfer for computed tomography (CT). Imaging was significantly obscured by tissue-density artifacts, though it suggested a 30% left hemithorax pneumothorax and potential gastrointestinal perforation. A tube thoracostomy was attempted but abandoned due to pleural adhesions and anatomical complexity.

Materials and Methods: Conclusion and Discussion: Profound hyponatremia is a life-threatening emergency, yet its management is severely compromised when coupled with morbid obesity. This case demonstrates that even in tertiary centers, pharmacological expertise remains insufficient without a bariatric infrastructure.The primary challenge identified was the inadequacy of standard bariatric medical equipment. Tissue-density artifacts and poor X-ray penetration in standard CT scanners precluded definitive diagnoses of potential gastrointestinal perforation and pneumonia. Furthermore, the lack of specialized bariatric beds and wide-bore

imaging systems necessitated a high-risk inter-facility transfer, causing critical diagnostic delays.To address the growing obesity pandemic, emergency departments and intensive care units must prioritize technical infrastructure—including high-capacity stretchers, mechanical CPR devices, and open-gantry CT systems. Without these logistical advancements, physical limitations will continue to shadow medical successes, leading to fatal outcomes.

Keywords: Hyponatremia, Morbid Obesity, Bariatric Emergency Management

---

Ref No: 1608

Procalcitonin-Guided Antibiotic Therapy in Lower Respiratory Tract Infections

burcu yormaz[1]

[1]Selcuk University Medicine Faculty Department of Chest Disease,Konya,Turkıye

burcu yormaz / Selcuk University Medicine Faculty Department of Chest Disease,Konya,Turkıye

Introduction and Purpose: Antibiotic overuse in lower respiratory tract infections (LRTIs) contributes to antimicrobial resistance, a growing global concern. Procalcitonin (PCT) has been proposed as a biomarker to guide antibiotic therapy. This study aims to evaluate the effectiveness of PCT-guided treatment strategies.

Materials and Methods: A review of randomized controlled trials and clinical studies evaluating PCT-guided antibiotic therapy in LRTIs was conducted. Outcomes including antibiotic duration, clinical recovery, hospitalization rates, and safety were analyzed

Results and Conclusion: PCT-guided strategies significantly reduced antibiotic exposure without negatively affecting clinical outcomes. This approach was particularly useful in distinguishing bacterial from viral infections, leading to more rational antibiotic use. Additionally, reduced antibiotic duration contributed to lower healthcare costs and decreased resistance development.In conclusion, PCT-guided antibiotic therapy is a safe and effective method to optimize antibiotic use in LRTIs. Its integration into clinical practice may improve antimicrobial stewardship and patient outcomes.

Keywords: Procalcitonin; Antibiotics; Respiratory Infections

Ref No: 1674

Hypertensive Pulmonary Edema Mimicking Acute Inhalational Toxicity After Agricultural Pesticide Exposure; a case report

Meryem Keçelioğlu[1], Murat Seyit[1], Mert Özen[1], Alten Oskay[1], Atakan Yılmaz[1], İbrahim Türkçüer[1]
[1]Pamukkale University Faculty of Medicine
Murat Seyit / Pamukkale University Faculty of Medicine

Introduction and Purpose: Acute dyspnea following pesticide exposure is commonly attributed to inhalational toxicity, particularly organophosphate or phosphide poisoning. However, anchoring bias toward exposure history may obscure alternative, potentially life-threatening diagnoses. This case highlights the importance of comprehensive clinical assessment beyond exposure-related assumptions.

Materials and Methods: A 79-year-old male presented to the emergency department with progressive dyspnea after inhaling a water-soluble granular agricultural pesticide (“Biçer”) for approximately 20 minutes while gardening the previous day. He reported prior exposure to the same agent without symptoms, and no other exposed individuals developed complaints.On admission, the patient was tachypneic with diffuse wheezing. Vital signs revealed severe hypertension (blood pressure 209/99 mmHg), heart rate 86 beats/min, respiratory rate 28/min, oxygen saturation 86% on room air, and body temperature 36.2°C. There was no uvular or upper airway edema. Physical examination showed bilateral +1 pretibial edema.Initial management included inhaled bronchodilators and intravenous therapy with continuous monitoring. Electrocardiography was performed. Toxicological evaluation of the pesticide confirmed that it did not contain organophosphates or aluminum phosphide.Given the severity of dyspnea, hypoxemia, marked hypertension, peripheral edema, and physical findings, hypertensive pulmonary edema was suspected rather than primary inhalational toxicity. Appropriate treatment for hypertensive pulmonary edema was initiated.Following treatment, the patient demonstrated significant clinical improvement with marked relief of dyspnea. Urine output reached approximately 4000 mL. NT-proBNP level was elevated at 811 ng/L, supporting a cardiogenic component to the pulmonary edema.

Materials and Methods: This case illustrates how acute pesticide exposure can mask underlying cardiopulmonary pathology and lead to diagnostic anchoring. Comprehensive evaluation of vital signs, physical examination, laboratory findings, and clinical response to treatment is essential. Clinicians should avoid attributing acute respiratory symptoms solely to exposure history and remain vigilant for alternative diagnoses such as hypertensive pulmonary edema.

Keywords: Hypertensive pulmonary edema; Pesticide inhalation; Diagnostic anchoring bias

Ref No: 1683

Traumatic Presentation of Bipartite Patella Mimicking Patellar Fracture

ESMA BULUT[1]

[1]BAYBURT DEVLET HASTANESİ

ESMA BULUT / BAYBURT DEVLET HASTANESİ

Introduction and Purpose: Bipartite patella is a rare anatomical variant resulting from non-fusion of the patellar ossification centers and is usually asymptomatic. Trauma can render it symptomatic, mimicking a patellar fracture clinically.

Materials and Methods: A 26-year-old male presented to the emergency department with anterior knee pain following a collision during a recreational soccer match. Pain worsened with movement, and physical examination revealed tenderness over the patella without instability. Initial plain radiographs were inconclusive, and no prior imaging was available for comparison. A computed tomography (CT) scan revealed a bipartite patella consistent with a developmental variant, with no evidence of acute fracture. The patient was managed conservatively, provided with a medical knee brace, and discharged with outpatient follow-up.

bipartite patella direkt grafi



bipartite patella BT



Materials and Methods: Although typically asymptomatic, bipartite patella can cause pain after trauma and may be mistaken for a patellar fracture. Accurate diagnosis relies on careful radiological evaluation and awareness of typical location and border characteristics. Misdiagnosis can lead to unnecessary immobilization or interventions. This case highlights the importance of considering bipartite patella in the differential diagnosis of post-traumatic anterior knee pain and correlating clinical and imaging findings for appropriate management.

Keywords: Bipartite patella; Knee pain; Trauma; Patellar fracture; Emergency department

---

Ref No: 1728

Volvulus

Safa Gödeoğlu[1], Murat Seyit[1], Atakan Yılmaz[1], Mert Özen[1], İbrahim Türkçüer[1], Alten Oskay[1]

[1]Pamukkale University Faculty of Medicine

Murat Seyit / Pamukkale University Faculty of Medicine

Introduction and Purpose: Sigmoid volvulus is a common cause of large bowel obstruction in elderly patients and may rapidly progress to ischemia, perforation, and sepsis if not promptly

diagnosed and treated. Chronic constipation and advanced age are important predisposing factors. This case report aims to present an elderly patient with sigmoid volvulus accompanied by metabolic acidosis, hyperkalemia, and renal dysfunction, emphasizing the importance of early radiological diagnosis and timely surgical intervention.

Materials and Methods: A 78-year-old male with a medical history of hypertension, chronic kidney disease, coronary artery disease, cholecystectomy, and left orchiectomy presented to the emergency department with a three-month history of constipation and acute onset of abdominal distension, inability to pass gas or stool, and recurrent vomiting since the previous day. On admission, vital signs were blood pressure 100/60 mmHg, heart rate 77 beats/min, oxygen saturation 100%, and body temperature 36.8°C. Physical examination revealed diffuse abdominal tenderness, while other system examinations were unremarkable. An upright abdominal radiograph demonstrated a characteristic coffee-bean sign with dilated colonic loops. Laboratory analysis showed metabolic acidosis and hyperkalemia on blood gas analysis (pH 7.27, bicarbonate 15.6 mmol/L), elevated inflammatory markers (C-reactive protein 59 mg/L, procalcitonin 7.32 ng/mL), and impaired renal function (creatinine 1.86 mg/dL, blood urea nitrogen 62 mg/dL).

Volvulus



.

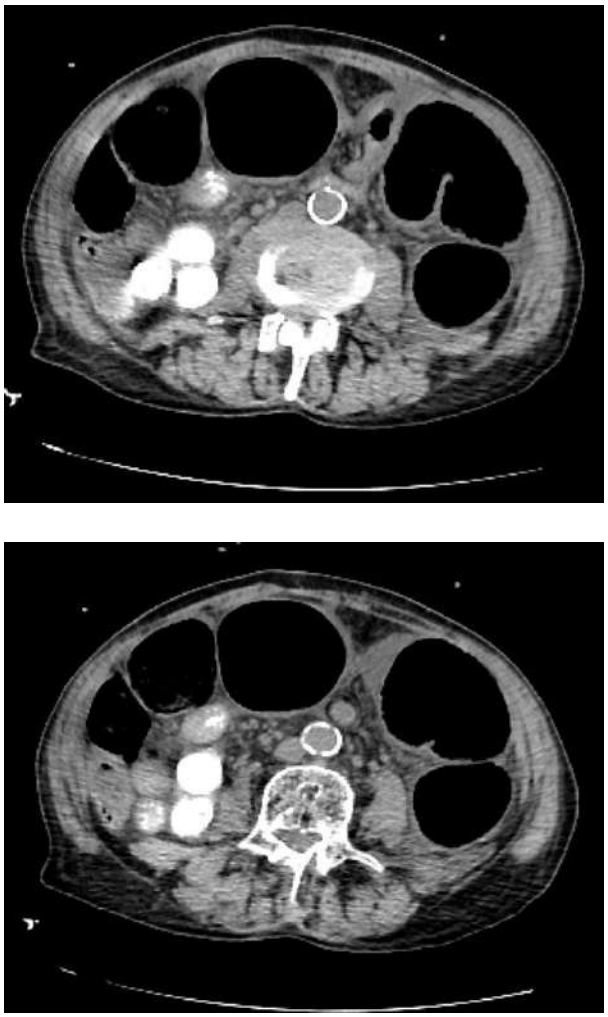

Materials and Methods: Electrocardiography revealed no findings suggestive of hyperkalemia; therefore, calcium therapy was not initiated. Oral intake was discontinued, and intravenous hydration and medical treatment for hyperkalemia were started due to dehydration and electrolyte imbalance. Non-contrast abdominal computed tomography revealed colonic dilatation up to 7 cm at the transverse colon level, a mesenteric whirl sign, diffuse interloop fluid densities, and a transition zone at the proximal sigmoid colon, with distal colonic collapse, consistent with sigmoid volvulus. Following consultation with general surgery, the patient was taken for emergency surgical intervention. This case highlights that sigmoid volvulus should be promptly considered in elderly patients presenting with bowel obstruction symptoms, and early imaging and surgical management are crucial to prevent life-threatening complications.

Keywords: Sigmoid volvulus, Intestinal obstruction, Coffee-bean sign

Ref No: 1730

INNOCENT OLIVE PITS

Erhan Şahin[1], Abdullah Süha Akça[1], İbrahim Özlü[1]

[1]Atatürk Üniversitesi Acil Tıp

Erhan Şahin / Atatürk Üniversitesi Acil Tıp

Introduction and Purpose: Intestinal obstruction can be functional or mechanical, and may be partial or complete. Mechanical large bowel obstruction can be caused by malignant or benign etiologies. Patients with large bowel obstruction may present acutely with sudden onset abdominal distension and abdominal pain due to abrupt luminal obstruction, or with subacute or chronic changes in bowel habits over time due to progressive luminal narrowing. A longer duration of symptoms and associated findings such as unintentional weight loss or rectal bleeding may suggest a malignant cause rather than a benign etiology.

Materials and Methods: 67-year-old patient with no known comorbidities was brought to our emergency department by emergency medical services with complaints of abdominal pain, abdominal distension, nausea, and vomiting that had been ongoing for one week. Vital signs were within normal limits. On systemic examination, bowel sounds were decreased on abdominal auscultation, and no tenderness was detected on palpation apart from generalized distension. On plain abdominal radiography, multiple air-fluid levels with broad bases were observed. The patient's history was further explored, revealing that he had been swallowing olive pits for the past month. Contrast-enhanced abdominal CT showed findings consistent with large bowel ileus, along with visible olive pits. After nasogastric tube placement, the patient was admitted to the general surgery service.

Materials and Methods: In patients presenting with ileus without any comorbidities, prior surgical history, or electrolyte imbalance that could cause paralytic ileus, factors such as hair ingestion, external mechanical compression by a mass, and malignancies such as colon or rectal cancer should be considered. Additionally, lifestyle changes and dietary habits should be questioned, and it should be kept in mind that ingestion of hard objects via the oral route may lead to similar clinical presentations.

photo 1

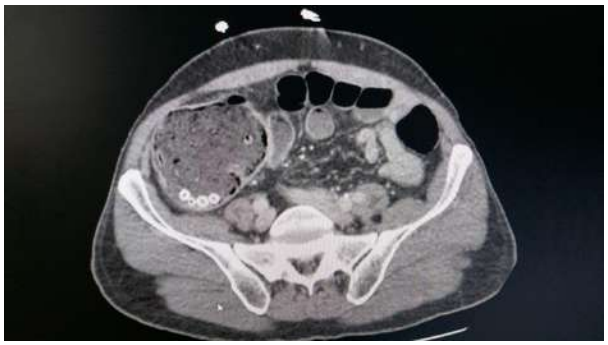

Keywords: olive, ileus, stomach ache

Ref No: 1765

Derby Day Chest Pain: Carbon Monoxide Poisoning

Sabri Furkan Bulca[1], Murat Seyit[1], Alten Oskay[1], Atakan Yılmaz[1], Mert Özen[1], İbrahim Türkçüer[1]

[1]Pamukkale University Faculty of Medicine

Murat Seyit / Pamukkale University Faculty of Medicine

Introduction and Purpose: Carbon monoxide (CO) is a colorless, odorless, and tasteless gas produced by incomplete combustion of carbon-containing materials. It binds to hemoglobin with approximately 220 times greater affinity than oxygen and causes tissue hypoxia, leading to clinical manifestations. Clinical findings are non-specific and may often resemble a “flu-like” syndrome; the neurological and cardiovascular systems are particularly vulnerable.

Materials and Methods: A 23-year-old man presented to the emergency department with sudden-onset burning chest pain and headache that began while watching a derby match with friends. He had no known medical conditions and was not taking regular medications; there was no family history of sudden cardiac death. He had a smoking history of 3 pack-years. Vital signs were: blood pressure 120/70 mmHg, heart rate 85/min, SpO_2 98%, temperature 36.5°C, respiratory rate 16/min, and perfusion index 2%. Physical examination revealed normal breath sounds and a normal neurological examination, with no additional pathological findings. Electrocardiography showed normal sinus rhythm. As the patient did not improve with symptomatic treatment, further evaluation was performed. Arterial blood gas analysis showed pH 7.38, pCO_2 38 mmHg, pO_2 96 mmHg, lactate 2.1 mmol/L, and a carboxyhemoglobin (COHb) level of 18%. Complete blood count and biochemistry were within normal limits, and troponin

was normal. Chest radiography and brain CT showed no acute pathology. Based on the elevated COHb level and clinical presentation, a diagnosis of carbon monoxide poisoning was made.

Hookah



Materials and Methods: Carbon monoxide poisoning may present with non-specific symptoms such as chest pain and headache. COHb level and clinical suspicion are key to diagnosis. In this case, clinical improvement was observed after 100% oxygen therapy via a non-rebreather mask; the patient was also evaluated for hyperbaric oxygen therapy to reduce the half-life of COHb.

Keywords: Carbon monoxide poisoning, hyperbaric oxygen, chest pain

---

Ref No: 1787

Gastric Perforation

Batuhan Özbek[1], Ayça Çalbay[1], Enes Akınci[1]

[1]Atatürk University Research Hospital

Batuhan Özbek / Atatürk University Research Hospital

Introduction and Purpose: A gastric perforation is a severe medical emergency where a hole forms in the stomach wall, leading to leakage of contents into the abdominal cavity, severe pain, peritonitis, and sepsis. Primarily caused by peptic ulcer disease, it presents with sudden, intense abdominal pain, rigidity, and nausea. Immediate surgery is usually required to repair the breach.

Materials and Methods: A 37-year-old male patient with no known chronic disease presented to our department with a complaint of epigastric pain lasting approximately 10 hours. His vital signs were within normal limits at admission. On physical examination, tenderness was noted in the epigastric region. Although no remarkable findings were observed in his plain radiography and laboratory tests, the patient did not improve with symptomatic treatment. On re-evaluation, the patient exhibited diffuse abdominal guarding with a board-like rigidity. Advanced imaging was performed, and the CT report stated: "Free intraperitoneal air adjacent to the gastric antrum was observed." The patient was consulted to the general surgery department and subsequently admitted for further management.

Results and Conclusion: Even in patients whose initial physical examination and investigations are unremarkable, those who do not respond to treatment should undergo repeated clinical evaluation, and advanced imaging should be performed promptly.

Keywords: stomacache

Ref No: 1808

Subdural Hematoma After Minor Trauma in an Elderly Patient on Anticoagulation

Sabri Furkan Bulca[1], Murat Seyit[1], Alten Oskay[1], Atakan Yılmaz[1], Mert Özen[1], İbrahim Türkçüer[1]

[1]Pamukkale University Faculty of Medicine

Murat Seyit / Pamukkale University Faculty of Medicine

Introduction and Purpose: In elderly patients receiving anticoagulant therapy, the risk of intracranial hemorrhage increases even after minor trauma, and clinical findings may be subtle. Therefore, a low threshold for neuroimaging and close neurological monitoring are essential.

Materials and Methods: A 76-year-old woman presented to the emergency department with increasing somnolence and headache following a low-energy fall at home. Her medical history was notable for atrial fibrillation, and she was taking regular anticoagulant therapy. On admission, vital signs were: blood pressure 145/85 mmHg, heart rate 88/min, respiratory rate 18/min, temperature 36.4°C, and SpO_2 95%. Neurological examination revealed a Glasgow Coma Scale (GCS) score of 13 and mild right-sided weakness. Emergency brain computed tomography (CT) demonstrated an acute hemorrhagic lesion consistent with a subdural hematoma. Neurosurgery consultation was obtained, and serial neurological examinations and

repeat imaging were planned to monitor for hemorrhage progression. Reversal or corrective measures for anticoagulation were considered according to institutional protocol, and hemodynamic stability was maintained.

Materials and Methods: This case highlights that a history of “minor trauma” may be misleading in elderly patients on anticoagulation. Prompt CT imaging in the presence of altered mental status or focal neurological deficits, along with interdisciplinary coordination, is crucial to reduce mortality and long-term sequelae.

Keywords: Anticoagulation, elderly, minor trauma.

Ref No: 1829

Emergency Department Experience with POCUS and Multimodal Active Internal Rewarming (Pleural Lavage) in the Management of Hypothermic Cardiac Arrest: "Nobody is Dead Until Warm and Dead"

MUHAMMED EMİN AKGÜN[1], ZEYNEP ÇAKIR[1]

[1]ATATURK UNIVERSTY

MUHAMMED EMİN AKGÜN / ATATURK UNIVERSTY

Introduction and Purpose: In cardiac arrests secondary to severe hypothermia (core temperature < 28°C), cerebral metabolism slows down significantly, making intact neurological survival possible even after prolonged cardiopulmonary resuscitation (CPR) efforts lasting for hours. Although extracorporeal life support (ECMO/ECLS) is currently considered the gold standard in managing these cases, aggressive "active internal and external rewarming" strategies are life-saving in emergency departments (EDs) where this facility is unavailable. This report presents the case of a hiker who got lost and was successfully resuscitated from a profound hypothermic cardiac arrest in the ED using uninterrupted mechanical CPR and pleural lavage.

Materials and Methods: A 30-year-old male mountaineer was found unconscious and apneic by search and rescue teams approximately 4 hours after getting lost in the snow. The patient, who was found to be in asystole on initial monitoring, was brought to the ED with ongoing CPR initiated at the scene. In the ED, his core temperature, measured via an esophageal probe, was 22°C. Point-of-care ultrasound (POCUS) revealed no cardiac activity. An automated mechanical CPR device (LUCAS) was applied for uninterrupted compressions. As our center lacks ECMO capabilities, a multimodal rewarming protocol was immediately initiated. Active external

rewarming was provided using a forced-air warming blanket (Bair Hugger). For active internal rewarming, bilateral tube thoracostomies were performed, and continuous pleural lavage was initiated using isotonic fluids heated to 40-42°C. Simultaneously, 42°C heated intravenous crystalloid infusions and heated-humidified oxygen support were administered. At the 160th minute of resuscitation, when the core temperature reached 30°C, the monitor displayed coarse ventricular fibrillation (VF). A first defibrillation shock was delivered, successfully restoring a sinus rhythm. The patient's hemodynamics stabilized with inotropic support; he was extubated on the 7th day and discharged with an intact neurological status (Cerebral Performance Category 1).

Materials and Methods: Although ECMO remains the gold standard for managing hypothermic cardiac arrest in the ED, hope should not be abandoned in centers where this equipment is unavailable. In regions experiencing harsh winter conditions, such as Erzurum, the preparedness of emergency departments to implement early and aggressive pleural lavage, mechanical CPR, and POCUS integration literally dictates the difference between life and death for these patients.

Keywords: HYPOTHERMI, CPR, ventricular fibrillation

Ref No: 1856

Temporal Arteritis

Fazilet Gücüko[1], Murat Seyit[1], Alten Oskay[1], Atakan Yılmaz[1], Mert Özen[1], İbrahim Türkçüer[1]

[1]Pamukkale University Faculty of Medicine

Murat Seyit / Pamukkale University Faculty of Medicine

Introduction and Purpose: Temporal arteritis, also known as giant cell arteritis, is a chronic vasculitis of unknown etiology that affects medium- and large-sized arteries. Temporal arteritis is the most common systemic vasculitis in adults, particularly in women. Its incidence increases with age. Patients may present with headache, tenderness over the temporal artery and scalp, jaw and tongue claudication, and transient or permanent vision loss.

Materials and Methods: Our case is a 90-year-old female patient with a known history of congestive heart failure and atrial fibrillation who presented with sudden vision loss in the right eye that began after a headache three days prior. The patient had complete vision loss in the left eye following trauma 10 years ago. On admission, her vital signs were within normal limits. On physical examination, Glasgow Coma Scale (GCS) was 15, there were no lateralizing neurological findings, and muscle strength was 5/5 in both upper and lower extremities.

Tenderness was present along the course of the temporal artery. Brain CT and diffusion MRI revealed no acute pathology. Laboratory tests showed elevated CRP and erythrocyte sedimentation rate. Ophthalmologic evaluation did not reveal any acute pathology. Based on the current findings, temporal arteritis was primarily suspected, and the patient was consulted to the relevant department.

Materials and Methods: Giant cell arteritis is a systemic vasculitis involving large- and medium-sized elastic arteries and, although relatively rare, it may lead to serious major complications. The most feared complication of the disease is vision loss, which develops secondary to ischemic retinopathy. Involvement of the aorta and its main branches may cause extremity claudication and aortic aneurysm. Myocardial infarction may occur due to involvement of the coronary arteries. In elderly patients presenting with rheumatologic complaints, especially with newly onset headache localized to the temporal region, giant cell arteritis should be considered. Due to its potentially severe complications, although rare, the diagnosis of temporal arteritis should not be missed.

Keywords: Temporal arteritis, Vision Loss, Elderly

Ref No: 1868

Traumatic Pneumothorax and Hemothorax Following Blunt Chest Trauma: A Case Report

Alperen Kodal[1], Murat Seyit[1], Alten Oskay[1], Atakan Yılmaz[1], Mert Özen[1], İbrahim Türkçüer[1]

[1]Pamukkale University Faculty of Medicine

Murat Seyit / Pamukkale University Faculty of Medicine

Introduction and Purpose: Thoracic trauma is a common cause of morbidity and mortality in emergency departments. The most frequently encountered injuries in chest trauma include pneumothorax, rib fractures, pulmonary contusion, and hemothorax. Pneumothorax occurs when air enters the pleural space due to lung injury and is considered a thoracic surgical emergency. The pleural space is a potential space between the parietal pleura, lining the mediastinum, diaphragm, and inner surface of the chest wall, and the visceral pleura, which covers the lungs including the fissures. Early diagnosis and appropriate management are crucial, especially in cases accompanied by hemothorax.

Materials and Methods: A 47-year-old male patient was admitted to the emergency department following an assault. The patient had sustained blows to the head, chest, and arm with the butt of a firearm. On physical examination, a deep laceration approximately 5 cm in length was observed in the occipital region. The Glasgow Coma Scale score was 15, and the neurological examination was normal. On auscultation, decreased breath sounds were noted in the left lung. Abdominal examination was unremarkable, with no guarding or rebound tenderness. Thoracic computed tomography and chest radiography revealed left-sided pneumothorax and hemothorax. Additionally, a displaced fracture of the left 8th rib was identified. The occipital laceration was sutured by the plastic surgery department. Due to the presence of pneumothorax and hemothorax, the patient was consulted by the thoracic surgery department and admitted for further monitoring and treatment.

Materials and Methods: Pneumothorax is a frequently encountered condition in emergency departments following thoracic trauma. Patients with concomitant pneumothorax and hemothorax require close clinical monitoring and timely intervention to prevent potential complications. Early diagnosis and multidisciplinary management play a critical role in patient outcomes.

Keywords: Pneumothorax, hemothorax, contusion

Ref No: 1920

Toxicological and psychiatric approach after oral ingestion of topical creams

Hasan Yıldız[1], Ayla Mollaoğlu[1], Zeynel Emre Bal[1], Ayşe Işık[1], Mehmet Gül[1]

[1]Emergency Medicine Department, Konya City Hospital, Türkiye

Hasan Yıldız / Emergency Medicine Department, Konya City Hospital, Türkiye

Introduction and Purpose: Suicide attempts in individuals with psychiatric disorders may occur through various methods. In this case, a patient with a known diagnosis of psychosis ingested multiple topical creams orally with suicidal intent. The toxicological and psychiatric manifestations that developed following oral ingestion of products containing salicylic acid and corticosteroids required a multidisciplinary approach.

Materials and Methods: A 28-year-old male patient with a known diagnosis of psychosis was admitted to the Toxicology Intensive Care Unit of Konya City Hospital. The patient had orally ingested the following topical products with suicidal intent: Üresal Forte Ointment, Klo-Sal

Lotion, Adventan Cream, Duoderm Skin Solution, Momesalic Ointment, Betasalic Lotion, Hametan Ointment, Fucidin Cream, Vital signs were stable, and the Glasgow Coma Scale score was 15. However, treatment noncompliance was observed, including refusal of intravenous access and refusal of oral intake.During follow-up, partial laboratory abnormalities were detected. On September 7, 2025, glucose was measured at 137 mg/dL, indicating mild hyperglycemia. Lactate dehydrogenase (LDH) was 268 U/L, considered a marker of cellular injury. Phosphorus level was 1.8 mg/dL, consistent with hypophosphatemia. On September 9, 2025, INR was 1.33, indicating a potential coagulation abnormality. Prothrombin time (PT) was 14.9 seconds, suggesting prolonged clotting time. Lactate level was 1.6 mmol/L, at the upper limit of normal.The patient was closely monitored for these abnormalities. Following intramuscular Norodol plus Akineton administration, intensive intravenous hydration was provided. However, poor treatment compliance limited optimal management.

Materials and Methods: This case highlights the systemic toxicity potential of dermatological products and the presence of unusual suicide methods in psychiatric patients. The toxicological manifestations following oral ingestion of salicylic acid-containing products were managed through early recognition and a multidisciplinary approach.Assessment of suicide risk and appropriate psychiatric treatment planning in individuals with psychiatric disorders are of vital importance. Reporting such cases contributes to awareness in both toxicology and psychiatry.

Keywords: suicide attempt, topical cream, toxicology

Ref No: 1947

Subacute Subdural Hematoma Showing Septation: A Rare Clinical Presentation

ÖMER FARUK ÖZ[1], EMRE KALKAN[1], BAŞAR CANDER[1], ŞEYMA NUR ÇALIŞIR[2]

[1]BEZMIALEM VAKIF UNIVERSITY
[2]BASAKSEHIR CAM VE SAKURA SEHIR HASTANESI

ÖMER FARUK ÖZ / BEZMIALEM VAKIF UNIVERSITY

Introduction and Purpose: Acute subdural hematoma is a recognized medical condition characterized by the accumulation of blood beneath the dura mater following a severe head injury. Subacute subdural hematomas represent a poorly defined nosological category, sometimes clinically conflated with chronic subdural hematomas. The necessity of surgical intervention in the elderly is increasingly scrutinized due to its related morbidity and mortality

rates. Burr-hole craniostomy is the predominant method for surgical evacuation, yielding generally positive outcomes.

Materials and Methods: A 74-year-old male patient presented to the emergency department with complaints of increasing dizziness, loss of balance, and headaches over several days. He fell down the stairs and hit his head while on Umrah pilgrimage 15 days ago. The patient has chronic diseases including Parkinson's disease, epilepsy, and hypertension. Clinical examination revealed the patient's general condition was good, and they were oriented and cooperative. The Glasgow Coma Scale score was 15. When the patient arrives at the cricital care unit vital signs were; fever:36,20C, pulse:65/min, oxygen saturation(SpO2):96%, respiratory rate:20/min, arterial blood pressure:165/68 mmHg.

Materials and Methods: The patient underwent brain CT and diffusion MRI scans during follow-up. The CT scan revealed a subdural hematoma in the left frontoparietal region, showing septation up to 2.5 cm at its widest point and indicating subacute development. CT imaging revealed a flattened left lateral ventricle and a marked shift effect in the midline structures. Following the CT scan, urgent consultations were held with Neurosurgery and Intensive Care. The neurosurgery department did not consider an emergency neurosurgical intervention based on the patient's current findings and imaging. Monitoring in the intensive care unit was recommended. The patient was subsequently admitted to the intensive care unit. The patient underwent successful burr-hole subdural hematoma drainage by neurosurgery on the second day of hospitalization in the intensive care unit. Septate subdural hematoma is a rare condition. Septating subdural hematoma is a rare condition that requires careful emergency department management, prompt imaging and consultations, and prompt treatment and, if necessary, surgery planning.

septated subdural hematoma

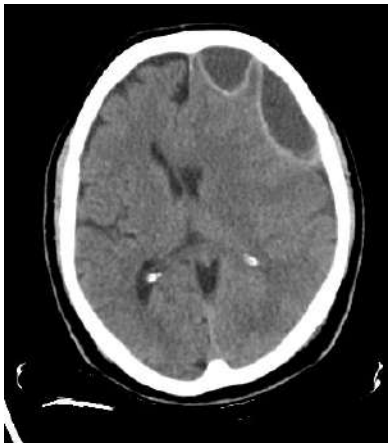

septated subdural hematoma



Keywords: burr-hole drainage, septated subdural hematoma, emergency Medicine

---

Ref No: 1950

Guıllaın-Barre Syndrome

Büşra Nur Büşra Nur Gülbahar Minisker[1], Murat Seyit[1], Duygu Aras Seyit[2], Atakan Yılmaz[1], Mert Özen[1], Alten Oskay[1]

[1]Pamukkale University Faculty of Medicine
[2]ERPA Saglik Hospital, Denizli

Murat Seyit / Pamukkale University Faculty of Medicine

Introduction and Purpose: Guillain–Barré syndrome (GBS) is an acute-onset, progressive neuropathy that often develops following a gastrointestinal or respiratory tract infection. Early recognition in the emergency department is critical to prevent potentially life-threatening complications, such as respiratory failure and autonomic dysfunction.

Materials and Methods: A 43-year-old man presented to the emergency department with weakness that developed after numbness in both feet, which had started two days earlier. This was followed by numbness in the hands. He reported marked difficulty with fine motor tasks, such as fastening a zipper. He denied dysphagia or shortness of breath and had no known comorbidities. His history was notable for diarrhea 4 days earlier and again 1 month prior.On neurological examination, he was awake, cooperative, and oriented. Bilateral foot drop was

observed in the lower extremities. Distal muscle strength in the upper extremities was mildly reduced (approximately 4/5). No weakness was noted in other muscle groups. Deep tendon reflexes were hypoactive in the lower extremities. Electromyography (EMG) demonstrated findings consistent with polyneuropathy, with predominant motor axonal involvement accompanied by demyelinating features. Based on the clinical presentation, examination, and electrophysiological findings, the patient was admitted to the neurology ward from the emergency department with a presumptive diagnosis of Guillain–Barré syndrome.

Materials and Methods: In this case, acute-onset distal-predominant weakness progressing over days, a tendency toward areflexia/hyporeflexia, and a history of diarrhea are supportive of Guillain–Barré syndrome. In the emergency department, the most critical steps are early assessment of the rate of progression, involvement of bulbar and respiratory muscles, and the risk of autonomic instability.

Keywords: Guillain–Barré syndrome, Acute polyneuropathy, Foot drop.

Ref No: 1989

Adrenal Crisis Presenting With Altered Mental Status And Refractory Hypotension

Tuba Nur Vural[1], Murat Seyit[1], Atakan Yılmaz[1], Mert Özen[1], Alten Oskay[1], İbrahim Türkçüer[1]

[1]Pamukkale University Faculty of Medicine

Murat Seyit / Pamukkale University Faculty of Medicine

Introduction and Purpose: Adrenal insufficiency is a life-threatening endocrine emergency that may present with nonspecific findings such as altered mental status, hypotension, hyponatremia, hyperkalemia, and hypoglycemia. Delayed recognition may lead to refractory shock and increased mortality. This case highlights the importance of medication history and clinical suspicion in the emergency department.

Materials and Methods: A 61-year-old woman presented to the emergency department with progressive somnolence and right upper extremity weakness over two days. Her medical history included cardiac arrhythmia and possible cerebrovascular disease. She was taking metoprolol (Saneloc) and acetylsalicylic acid (Ecopirin). On admission, vital signs were blood pressure 85/50 mmHg, heart rate 105/min, respiratory rate 18/min, temperature 36.2 °C, and oxygen saturation 97%. Glasgow Coma Scale was 14 (E3V5M6) and capillary glucose was 64 mg/dL. The patient was somnolent but arousable, with slowed speech and 4/5 motor strength in the right

upper extremity.Arterial blood gas revealed pH 7.31, pCO_2 44 mmHg, HCO_3^- 20 mmol/L, lactate 2.4 mmol/L, sodium 127 mmol/L, potassium 5.4 mmol/L, and glucose 59 mg/dL. Serum biochemistry showed sodium 130 mmol/L, potassium 5.5 mmol/L, creatinine 0.9 mg/dL, glucose 62 mg/dL, and CRP 153 mg/L. Cranial CT and diffusion MRI showed no acute intracranial pathology.Despite a 500 mL isotonic saline bolus, hypotension persisted and norepinephrine infusion was started. Blood pressure further decreased to 55/38 mmHg. Recurrent hypoglycemia persisted despite dextrose administration. Thoracic and abdominal CT excluded hemorrhage or trauma. Further medication review revealed recent discontinuation of methylprednisolone (Prednol 16 mg), which the patient had used for two months and stopped ten days earlier. Considering refractory hypotension, hyponatremia, hyperkalemia, and hypoglycemia after steroid withdrawal, adrenal crisis was suspected. Intravenous hydrocortisone 100 mg was administered, leading to rapid improvement in blood pressure and heart rate.

Materials and Methods: Adrenal crisis should be considered in patients with unexplained hypotension, electrolyte abnormalities, and altered mental status, particularly in the setting of recent corticosteroid withdrawal. Early steroid administration is crucial to prevent refractory shock and mortality.

Keywords: Adrenal Crisis, Steroid Withdrawal, Hypotension

Ref No: 2008

Massive Pulmonary Embolism in a Patient with Bipolar Disorder

Taner Küçücük[1], Murat Seyit[1], Atakan Yılmaz[1], Mert Özen[1], Alten Oskay[1], İbrahim Türkçüer[1]

[1]Pamukkale University Faculty of Medicine

Murat Seyit / Pamukkale University Faculty of Medicine

Introduction and Purpose: Pulmonary embolism (PE) is a life-threatening condition, with massive and saddle emboli associated with particularly high mortality. Early recognition and prompt intensive care management are crucial for preserving right ventricular function and preventing complications. We present a case of massive PE in a patient with no comorbidities other than bipolar disorder.

Materials and Methods: A 44-year-old male presented with a three-day history of chest pain, dyspnea, and dizziness. Physical examination revealed tachycardia and tachypnea, with a Glasgow Coma Scale of 15; the patient was conscious and cooperative. Electrocardiography

showed an S1Q3T3 pattern. Thoracic CT angiography revealed extensive thrombi in both main pulmonary arteries, lobar, and segmental branches, consistent with a saddle embolus; no parenchymal infiltration or consolidation was noted. The patient was admitted to the pulmonary intensive care unit. Oxygen supplementation was provided for hypoxemia, anticoagulation therapy was initiated, and thrombolytic therapy was considered. This case highlights that massive and saddle PE can pose serious mortality risk even in patients who are hemodynamically relatively stable. Early diagnosis, close intensive care monitoring, and timely initiation of anticoagulation and thrombolytic therapy are essential to reduce morbidity and mortality. In patients with psychiatric comorbidities, drug interactions and adherence should also be carefully evaluated. A multidisciplinary approach is critical to optimize outcomes, ensuring right heart function is preserved and complications are minimized.

ECG

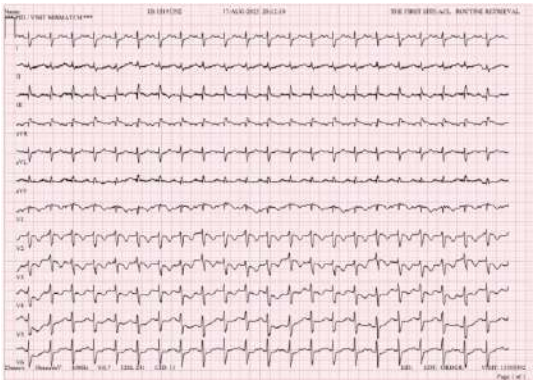

CT



CT



Materials and Methods: Massive PE requires rapid recognition and tailored management. This case emphasizes the importance of vigilance in patients with psychiatric disorders and the value of a coordinated, multidisciplinary strategy for timely intervention and improved prognosis.

Keywords: Chest pain, dyspnea, massive pulmonary embolism

Ref No: 2032

Pulmonary Manifestations of Obesity: Impact on Respiratory Mechanics and Clinical Outcomes

burcu yormaz[1]

[1]Selcuk University Medicine Faculty Department of Chest Disease,Konya,Turkıye

burcu yormaz / Selcuk University Medicine Faculty Department of Chest Disease,Konya,Turkıye

Introduction and Purpose: Obesity is a global health problem with significant respiratory implications. It affects lung mechanics, gas exchange, and predisposes patients to various pulmonary diseases. This study aims to evaluate the impact of obesity on respiratory physiology and clinical outcomes

Materials and Methods: A review of clinical and physiological studies assessing lung volumes, airway resistance, and respiratory muscle function in obese individuals was performed. The relationship between obesity and comorbid conditions such as obstructive sleep apnea (OSA) and obesity hypoventilation syndrome (OHS) was also examined.

Results and Conclusion: Obesity was associated with reduced functional residual capacity, decreased lung compliance, and increased airway resistance. These changes lead to impaired ventilation and increased risk of hypoxemia. Additionally, obese patients demonstrated higher rates of OSA, OHS, and perioperative respiratory complications.In conclusion, obesity significantly alters respiratory mechanics and contributes to adverse clinical outcomes. Early recognition and targeted interventions are essential to improve respiratory health in this population.

Keywords: Obesity; Respiratory Mechanics; Lung Function

Ref No: 2082

Pubic Diastasis

Merve Bulut[1], Ekrem Bulut[1], Mevlana Gül[1]

[1]Atatürk University Faculty of Medicine

Merve Bulut / Atatürk University Faculty of Medicine

Introduction and Purpose: Spinopelvic injuries are generally associated with high-energy trauma in young adults and primarily develop due to excessive axial loading transmitted from the spine to the sacrum. In addition to fractures and ligament injuries related to the trauma, these injuries are often accompanied by severe organ damage that can be life-threatening due to the high-energy nature of the trauma.

Materials and Methods: A 14-year-old female patient presented with a complaint of falling while skiing. During the fall, she hit her pubic region against a pole and experienced severe pain in the area. The patient was examined, and necessary tests were ordered. Peripheral pulses were intact, and lower extremity movements were normal. A direct radiograph revealed pubic diastasis (Figure 1). The patient was consulted with the orthopedic clinic. During the follow-up examination, a deformity was noticed in the left forearm, and a direct radiograph confirmed a distal radius fracture.

Materials and Methods: Since spinopelvic injuries are often the result of high-energy trauma, a thorough systemic examination must be performed. Associated injuries should not be overlooked. The stabilization of the patient should be ensured, and consultation with the relevant clinical department should be arranged.

Keywords: pubic diastasis, spinopelvic injuries, trauma

Ref No: 2124

A SILENT BUT DEADLY INFECTION

Nisa Mındız[1], İBRAHİM ÖZLÜ[1], BERK ORAL[1]

[1]ATATÜRK UNIVERSITY EMERGENCY DEPARTMENT

Nisa Mındız / ATATÜRK UNIVERSITY EMERGENCY DEPARTMENT

Introduction and Purpose: Necrotizing fasciitis is a rapidly progressive, life-threatening soft tissue infection involving the skin, subcutaneous tissue, and fascial planes. Early clinical findings may be nonspecific, making diagnosis challenging; however, delayed diagnosis and treatment significantly increase mortality. Therefore, early recognition and prompt management in the emergency department are crucial.

Materials and Methods: A 55-year-old female patient presented to the emergency department with complaints of a wound on the left hip and left leg. The patient's general condition was assessed as moderate-to-good, and vital signs were stable.On physical examination, lesions measuring approximately 5–6 cm in diameter in the left gluteal region and 2–3 cm in diameter in the left thigh were observed. The lesions were tender and firm on palpation; additionally, fluctuation was present in the left thigh region. The lesions exhibited mild warmth, a shiny and tense appearance, and a sharp foul odor. Peripheral pulses (tibialis posterior and dorsalis pedis) were palpable.Laboratory investigations revealed elevated inflammatory markers. Abdominal computed tomography (CT) performed for further evaluation demonstrated findings consistent with necrotizing fasciitis. Based on clinical and radiological findings, the patient was admitted to the orthopedic clinic for further management and surgical planning.

PHOTO 1

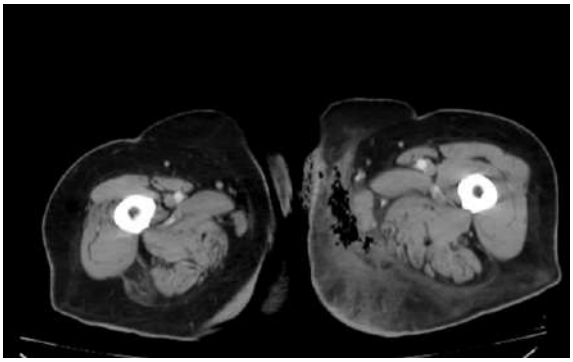

PHOTO 2



Materials and Methods: Necrotizing fasciitis is a rapidly progressive infection associated with high morbidity and mortality if not recognized early. The most common causative organisms include Streptococcus pyogenes, Staphylococcus aureus, and polymicrobial agents. Clinically, it may initially mimic cellulitis but can progress to severe pain, skin discoloration, bullae formation, necrosis, and foul-smelling discharge.Although clinical suspicion is paramount for diagnosis, imaging modalities such as computed tomography and magnetic resonance imaging can support the diagnosis. The presence of gas along fascial planes and extensive soft tissue involvement are important radiological findings.Early initiation of broad-spectrum antibiotics and urgent surgical debridement are life-saving. Delayed surgical intervention significantly increases mortality rates. Therefore, patients suspected of having necrotizing fasciitis in the emergency department should be evaluated promptly and referred to the appropriate specialty without delay.

Keywords: Necrotizing fasciitis, soft tissue infection, surgical debridement

Ref No: 2130

19 Years Old Mass Suicide Attempt

Ali Ümit Arıgüloğlu[1], Murat Seyit[1], Atakan Yılmaz[1], Mert Özen[1], Alten Oskay[1], İbrahim Türkçüer[1]

[1]Pamukkale University Faculty of Medicine

Murat Seyit / Pamukkale University Faculty of Medicine

Introduction and Purpose: Zinc phosphide causes a phosphine flash that is released upon reaction with stomach acid, and this can be potentially life-threatening not only for the patient but also for the healthcare personnel involved in the treatment process. This issue should not be overlooked.

Materials and Methods: A 19-year-old male with no known chronic medical history was brought to the emergency department by ambulance after a suicide attempt involving multiple self-inflicted lacerations. The injuries were located in the neck, thorax, abdomen, and upper extremities.On arrival, the patient was unconscious and hemodynamically unstable. Immediate resuscitative measures were initiated, and O Rh-negative blood transfusion was administered emergently. Bedside ultrasonography revealed findings consistent with bilateral pneumothorax. A penetrating abdominal injury was suspected. In addition, a tendon laceration was identified on the ulnar aspect of the left hand.Following initial stabilization and improvement of vital signs, the patient was transferred for further imaging studies. Approximately two hours later, after regaining consciousness and becoming fully oriented, a detailed history was obtained. The patient reported that he had initiated the suicide attempt approximately five hours prior by ingesting rat poison. Believing it to be ineffective, he subsequently began inflicting stab wounds on himself. The commercial name of the ingested rodenticide could not be identified.The National Poison Information Center was consulted. It was emphasized that if the ingested rodenticide contained zinc phosphide, it could react with gastric acid to release toxic phosphine gas, posing a potentially life-threatening risk not only to the patient but also to healthcare personnel involved in his management. Further investigation revealed that the ingested product did not contain zinc phosphide.

Materials and Methods: This case highlights the challenges of obtaining a reliable and detailed medical history in suicidal patients presenting with altered mental status and underscores the importance of a multidisciplinary approach in emergency settings. After completion of emergency interventions, the patient was admitted to the intensive care unit for close monitoring.

Keywords: Suicide attempt, Zinc phosphide, Suicid

Ref No: 2148

Acalculous cholecystitis presenting with epigastric pain in a young healthy patient: a diagnostic challenge in the emergency department

Hilal Türk, Mine Kayacı Yıldız, Hatice Yollar, Emine Doğan, Mehmet Gül

[1]Emergency Medicine Department, Konya City Hospital, Türkiye

Hatice Yollar / Emergency Medicine Department, Konya City Hospital, Türkiye

Introduction and Purpose: Acalculous cholecystitis (AC) is an inflammatory disease of the gallbladder that occurs in the absence of gallstones and accounts for approximately 5-10% of all cases of acute cholecystitis. It is most commonly associated with severe clinical conditions such as trauma, major surgery, sepsis, or a prolonged intensive care unit (ICU) stay. In this report, we aimed to present a rare case of AC diagnosed by imaging methods in a young, otherwise healthy patient who presented to the emergency department (ED) with atypical epigastric pain.

Materials and Methods: A 28-year-old female patient with no known comorbidities presented to the ED with epigastric pain radiating to the back for three days. She reported mild loss of appetite but denied fever, vomiting, and diarrhea. Physical examination revealed localized tenderness predominantly in the epigastric region, extending to the right upper and right lower quadrants, with no guarding or rebound tenderness. Laboratory evaluation showed a C-reactive protein (CRP) level of 4 milligrams per liter (mg/L). The initial white blood cell (WBC) count was 10,000/mm³, which mildly increased to 13,000/mm³ in a repeat hemogram two hours later. Liver function tests and pancreatic enzymes were normal. Because her pain persisted despite symptomatic treatment, a contrast-enhanced abdominal computed tomography (CT) scan was performed.

Materials and Methods: Results and Conclusion:CT imaging demonstrated marked gallbladder wall thickening and edema with pericholecystic fluid, alongside free fluid between the intestinal loops in the lower abdominal quadrants. The patient was promptly admitted to the general surgery service with a preliminary diagnosis of AC. Although AC is typically observed in critically ill patients, it may rarely occur in otherwise healthy individuals. When clinical and laboratory findings are not prominent, the diagnosis may easily be delayed. Therefore, AC should be considered in the differential diagnosis of patients presenting to the ED with atypical epigastric or right upper quadrant pain, and appropriate imaging must be utilized early.

Keywords: Acalculous cholecystitis, epigastric pain, emergency department

Ref No: 2150

Delayed splenic rupture presenting with hemodynamic instability after minor trauma

Erdem Zeki Karabulut[1], Mevlana Gül[1], Enes Yılmaz[1]
[1]Ataturk University

Erdem Zeki Karabulut / Ataturk University

Introduction and Purpose: Delayed splenic rupture is a rare but potentially fatal complication of blunt abdominal trauma. It may occur days or even weeks after the initial injury, often in patients who were initially asymptomatic or minimally symptomatic.

Materials and Methods: A 36-year-old male presented to the emergency department with sudden onset of severe abdominal pain, dizziness, and a brief syncopal episode. He reported a history of minor blunt abdominal trauma during a fall 10 days prior but did not seek medical evaluation at that time. On admission, he was hypotensive and tachycardic. Physical examination revealed abdominal distension and diffuse tenderness. Focused Assessment with Sonography in Trauma (FAST) demonstrated free intraperitoneal fluid. Laboratory analysis revealed a significant drop in hemoglobin compared to previous records.

Materials and Methods: Emergency laparotomy confirmed splenic rupture with active intra-abdominal bleeding, and splenectomy was performed. The patient recovered uneventfully and was discharged with appropriate vaccinations. This case highlights the importance of considering delayed splenic rupture in patients presenting with acute abdomen and hemodynamic instability, even when the trauma history is remote or initially considered insignificant. Thorough history-taking is essential in emergency practice.

Keywords: Splenic rupture, trauma

Ref No: 2163

Spontaneous Celiac Artery Dissection Presenting with Splenic Infarction: A Case Report

AHMET DURSUN DEMİR[1], HIZIR UFUK AKDEMİR[1]

[1]Department of Emergency Medicine, Ondokuz Mayıs University Faculty of Medicine, Samsun, Türkiye

AHMET DURSUN DEMİR / Department of Emergency Medicine, Ondokuz Mayıs University Faculty of Medicine, Samsun, Türkiye

Introduction and Purpose: Spontaneous celiac artery dissection is a rare vascular condition affecting visceral arteries and typically presents with nonspecific abdominal pain. Early diagnosis can be challenging, yet delayed recognition may result in serious complications such as visceral ischemia or organ infarction. This case report aims to present a patient with acute abdominal pain diagnosed with splenic infarction secondary to spontaneous celiac artery dissection and to emphasize the importance of considering this rare entity in the differential diagnosis.

Materials and Methods: A 47-year-old female presented to the emergency department with sudden-onset epigastric and left upper quadrant abdominal pain radiating to the back and lumbar region. She had no known chronic illness or medication history. On admission, vital signs were stable with a body temperature of 36.6°C, blood pressure of 155/85 mmHg, heart rate of 80 bpm, respiratory rate of 22 breaths/min, and oxygen saturation of 96% on room air. Physical examination revealed tenderness in the epigastric and left upper quadrant regions without guarding or rebound.Laboratory investigations demonstrated mild leukocytosis, while other parameters, including renal function and coagulation tests, were within normal limits. Arterial blood gas analysis was unremarkable. Bedside ultrasonography revealed decreased parenchymal perfusion in the spleen without free intra-abdominal fluid.Contrast-enhanced abdominal computed tomography demonstrated a dissection flap originating from the celiac artery and extending distally, accompanied by mural thrombus formation in the splenic artery. Additionally, wedge-shaped hypodense areas within the spleen were identified, consistent with splenic infarction.The patient was evaluated by gastroenterology, general surgery, cardiovascular surgery, and interventional radiology teams. As there was no indication for urgent surgical or endovascular intervention, conservative management was initiated with low-molecular-weight heparin and acetylsalicylic acid. The patient’s symptoms improved during follow-up, and she was discharged with outpatient follow-up recommendations.

Materials and Methods: Spontaneous celiac artery dissection is a rare but important cause of acute abdominal pain. Splenic infarction may be the initial clinical manifestation. Clinicians should consider visceral arterial pathologies in the differential diagnosis, and contrast-enhanced computed tomography plays a critical role in early diagnosis. Conservative management can be a safe and effective treatment option in clinically stable patients.

Keywords: Celiac artery dissection, Splenic infarction, Acute abdominal pain

Ref No: 2166

Acute Abdomen

Yunus Ek[1], Ayça ÇALBAY[1]
[1]atatürk üniversitesi
Yunus Ek / atatürk üniversitesi

Introduction and Purpose: ACUTE ABDOMEN CAUSES INCLUDE ACUTE APPENDICITIS, ACUTE PANCREATITIS, ACUTE PANCREATITIS, ACUTE CHOLECYSTITIS, ILEUS, PERIENTERITIS, INTRA-ABDOMINAL PERFORATION, ETC., WHICH ARE COMMON CAUSES IN THE EMERGENCY DEPARTMENT.

Materials and Methods: A 39-YEAR-OLD FEMALE PATIENT WAS ADMITTED TO US WITH THE COMPLAINT OF ABDOMINAL PAIN FOR 1 WEEK. THE PATIENT HAD A KNOWN DIAGNOSIS OF CECAL CA CA. THE PATIENT HAD A DEFICIENCY IN THE RIGHT LOWER QUADRANT OF THE ABDOMEN IN THE EXAMINATION OF THE PATIENT WITH STABLE INCOMING VITALS. THE PATIENT WHO HAD INTRA-CELL PERFORATION ON IMAGING WAS CONSULTED TO THE GENERAL SURGERY CLINIC. HER TREATMENT WAS ORGANIZED BY THE RELEVANT CLINIC.

CT

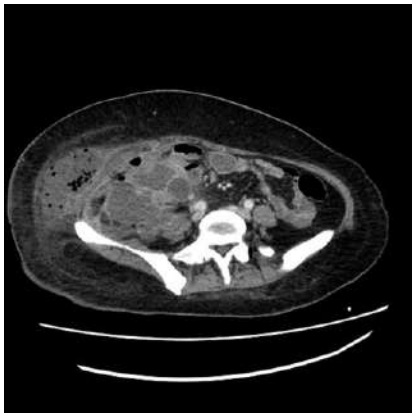

Materials and Methods: INTRA-ABDOMINAL PERFORATION SHOULD BE KEPT IN MIND IN PATIENTS WHO PRESENT TO THE EMERGENCY DEPARTMENT WITH ABDOMINAL PAIN, HAVE AN ACUTE ABDOMEN ON EXAMINATION, AND HAVE AN INTRA-ABDOMINAL MASS.

Keywords: ACUTE ABDOMEN, SURGERY

Ref No: 2173

Hypertensive Intracranial Hemorrhage

Taner Küçücük[1], Murat Seyit[1], Duygu Aras Seyit[2], Atakan Yılmaz[1], Mert Özen[1], Alten Oskay[1]

[1]Pamukkale University Faculty of Medicine
[2]ERPA Saglik Hospital, Denizli

Murat Seyit / Pamukkale University Faculty of Medicine

Introduction and Purpose: - Hypertensive intracranial hemorrhage is one of the most common causes of spontaneous brain hemorrhage. Chronic uncontrolled hypertension leads to lipohyalinosis and the formation of Charcot–Bouchard microaneurysms in small penetrating arteries, increasing the risk of rupture.Intraventricular hemorrhage (IVH) may occur secondary to intraparenchymal bleeding extending into the ventricular system and is associated with poor prognosis. Massive ventricular involvement may result in acute hydrocephalus, elevated intracranial pressure, and brainstem compression.

Materials and Methods: A 72-year-old female patient with a history of hypertension and heart failure presented to the emergency department with sudden-onset aphasia, decreased consciousness, nausea and vomiting, and right facial asymmetry. On admission: GCS: 7 (E1M4V2), BP: 174/68 mmHg, Heart rate: 99 bpm and SpO_2: 93%Due to low GCS, the patient was intubated and admitted to the intensive care unit. -Brain CT: Hyperdense intraventricular hemorrhage completely filling the right lateral and fourth ventricles, extending throughout the ventricular system; no significant midline shift.-CT angiography: The arteries of the Circle of Willis were patent; the right anterior cerebral artery (ACA) was smaller than the contralateral side, and the distal segment of the right posterior cerebral artery (PCA) showed no contrast filling. The basilar and vertebral arteries, as well as bilateral CCA, ECA, and ICA, were patent. No aneurysm or dissection was detected.Treatment and Outcome: After blood pressure control, the patient was referred to neurosurgery. Hypertension is the most important risk factor for spontaneous intracranial hemorrhage. The presence of massive IVH indicates a poor prognosis. Early surgical evaluation and intensive care support are critical in reducing mortality and morbidity.

CT



CT



Materials and Methods: This case highlights the clinical and radiological features, risk factors, and emergency management strategies for hypertensive IVH. Massive ventricular involvement should be considered a severe complication requiring aggressive critical care and surgical intervention.

Keywords: hypertension, intraparenchymal hemorrhage, intraventricular hemorrhage

Ref No: 2190

Acute interstitial pneumonia following inhalation of polydimethylsiloxane-containing silicone-based spray: an occupational exposure case mimicking pulmonary embolism

Fadime ÖZYİĞİT GÖK[1], Mine Kayacı Yıldız[1], Emre Gök[1], Demet Acar[1], Mehmet Gül[1]

[1]Emergency Medicine Department, Konya City Hospital, Türkiye

Fadime Özyiğit Gök / Emergency Medicine Department, Konya City Hospital, Türkiye

Introduction and Purpose: Acute lung injury following inhalation of vinyl silicone-based aerosol sprays may present with sudden dyspnea, hypoxemia, and bilateral ground-glass opacities. This clinical presentation may mimic pulmonary embolism (PE), particularly in patients presenting with acute dyspnea and pleuritic chest pain. In this study, we present a case of acute interstitial pneumonia following occupational exposure to polydimethylsiloxane.

Materials and Methods: A 35-year-old male presented with sudden onset dyspnea during the application of a silicone spray on his first day of work in a shoe factory. Initial ambulance evaluation revealed an oxygen saturation of 90%. Due to pleuritic chest pain, PE was suspected, and D-dimer levels were found to be elevated. Pulmonary computed tomography (CT) angiography showed no evidence of embolism; however, bilateral diffuse ground-glass opacities were reported.

Materials and Methods: Results and Conclusion: The patient showed clinical improvement with systemic steroid and inhaler therapy. Acute interstitial pneumonia following occupational exposure to polydimethylsiloxane-based aerosols may clinically and biochemically mimic PE in patients presenting with sudden dyspnea and pleuritic chest pain. Diagnostic evaluation based solely on D-dimer levels may be misleading; clinical history, exposure assessment, and radiological findings should be evaluated together. This case highlights the importance of considering occupational aerosol inhalation in the differential diagnosis of acute respiratory syndromes and underscores the critical role of a multidisciplinary approach for diagnostic accuracy. Early diagnosis, cessation of exposure, and appropriate supportive treatment are the cornerstones of a favorable clinical outcome.

Keywords: Acute interstitial pneumonia, chemical pneumonitis, polydimethylsiloxane

Ref No: 2227

Mechanical thrombectomy following a lack of response to thrombolytic therapy

Duygu Aras Seyit[1], Murat Seyit[2]

[1]ERPA Saglik Hospital, Denizli
[2]Pamukkale University Faculty of Medicine

Murat Seyit / Pamukkale University Faculty of Medicine

Introduction and Purpose: A stroke is a clinical condition caused by vascular factors, characterised by focal or global impairment of cerebral function. It ranks third among causes of death worldwide, with ischaemic strokes accounting for the majority of cases. In ischaemic strokes, early intervention both reduces the rate of disability and is life-saving. Here, we report a case of a patient presenting with acute ischaemic stroke who did not respond to intravenous thrombolytic therapy and subsequently underwent mechanical thrombectomy.

Materials and Methods: A 56-year-old male patient with a history of diabetes mellitus. Twenty hours prior, he developed sudden weakness on the left side, inability to speak, and altered consciousness. Following a brain MRI performed at an external centre, which revealed a right middle cerebral artery (MCA) infarction (acute ischaemic stroke), the patient was administered intravenous thrombolytic therapy. As no significant improvement in symptoms was observed, a mechanical thrombectomy was performed by the neurosurgery team at the 20-hour mark. Following the procedure, the patient, having overcome the immediate life-threatening phase, was discharged with residual right hemiparesis.

MRI

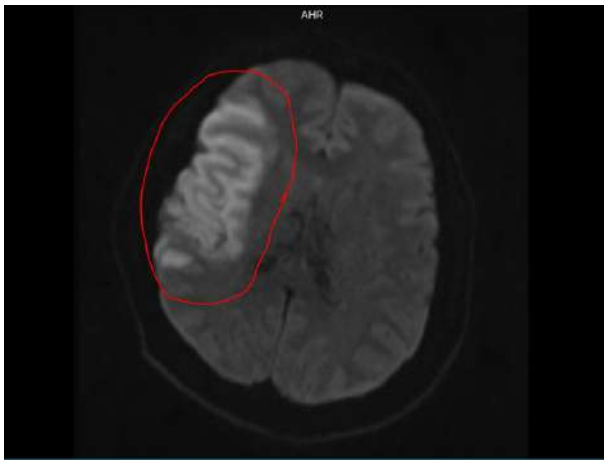

Materials and Methods: In suitable cases presenting within the first 4.5 hours of an acute ischaemic stroke, intravenous thrombolytic therapy is administered. However, in cases of large vessel occlusion, intravenous tPA therapy is unfortunately insufficient to reopen the occlusion and is effective in only 4–30% of cases. Consequently, due to the narrow treatment window, its ineffectiveness in reducing mortality, and its limited efficacy on large thrombi—particularly those longer than 8 mm—affecting proximal arteries, there has been a need for a more effective treatment. Consequently, following clinical trials, mechanical thrombectomy has become the gold standard, applicable within the first 6 hours and, in selected cases, up to 24 hours. Mechanical thrombectomy involves the removal of the thrombus via the femoral artery using a catheter and specialised devices (such as aspiration or stents). In our case, there was a large vessel occlusion; following mechanical thrombectomy performed at the 20-hour mark, the patient was discharged with residual mild hemiparesis on the right side.

Keywords: Mechanical thrombectomy

Ref No: 2333

Delayed Subdural Hematoma After Minor Head Trauma in an Elderly Patient

Ekrem Bulut[1], Merve Bulut[1], Ayça Çalbay[1]

[1]Atatürk University Faculty of Medicine

Ekrem Bulut / Atatürk University Faculty of Medicine

Introduction and Purpose: Minor blunt head trauma in the geriatric population may lead to life-threatening intracranial hemorrhage (ICH) due to physiological brain atrophy and widespread anticoagulant use. In particular, among patients using novel oral anticoagulants (NOACs), initially normal imaging and delayed bleeding days later create diagnostic challenges in the emergency department. We present a case discharged after minor trauma who returned days later with acute confusional state and was diagnosed with subdural hematoma (SDH).

Materials and Methods: A 78-year-old man using rivaroxaban for atrial fibrillation was brought to the emergency department after tripping over a carpet at home. Initial evaluation revealed a GCS of 15, and non-contrast brain CT was normal; the patient was discharged. Five days later, he returned with complaints of incoherent speech and somnolence. Vital signs were stable, and GCS was 13 (E3V4M6). There was no focal neurological deficit. Repeat brain CT demonstrated a 12-mm right frontoparietal subacute–acute SDH with a 4-mm midline shift. Prothrombin

complex concentrate (PCC) was administered for reversal of anticoagulant effect, and the patient was transferred to neurosurgery for urgent operative management.

Materials and Methods: Tintinalli and Rosen's guidelines emphasize that a normal initial CT does not exclude delayed ICH in geriatric trauma patients using NOACs. Brain atrophy predisposes to stretching of bridging veins, facilitating venous rupture even after minor trauma. UpToDate recommends thorough caregiver education regarding delayed neurological deterioration and a low threshold for repeat CT imaging in this population. This case highlights the insidious course of minor trauma in elderly patients on NOACs and the life-saving role of rapid PCC administration in the emergency department.

Keywords: blunt head trauma, subdural hematoma, NOACs

Ref No: 2336

Massive Pulmonary Embolism Presenting with Hemoptysis and Hemodynamic Instability: A Case Report

Alperen Kodal[1], Murat Seyit[1], Mert Özen[1], Alten Oskay[1], Atakan Yılmaz[1], İbrahim Türkçüer[1]

[1]Pamukkale University Faculty of Medicine

Murat Seyit / Pamukkale University Faculty of Medicine

Introduction and Purpose: Pulmonary embolism (PE) is a life-threatening condition that may present with nonspecific symptoms such as dyspnea and hemoptysis. Massive PE is characterized by hemodynamic instability and requires urgent diagnosis and reperfusion therapy to reduce mortality.

Materials and Methods: A 70-year-old female presented to the emergency department with hemoptysis and acute onset dyspnea that began approximately six hours prior to admission. Her past medical history was significant for hypertension and diabetes mellitus. She was brought to the emergency department by ambulance due to worsening symptoms. On arrival, vital signs revealed oxygen saturation of 90% on room air, blood pressure of 80/50 mmHg, and heart rate of 130 beats per minute. Physical examination demonstrated minimal basal crackles on lung auscultation. Abdominal examination was unremarkable, without guarding or rebound tenderness. Electrocardiography showed sinus tachycardia. Given the patient's hemodynamic instability and clinical suspicion of pulmonary embolism, emergent computed tomography pulmonary angiography (CTPA) was performed. Imaging revealed findings consistent with

embolism in the left main pulmonary artery. The patient was consulted to the Department of Pulmonology. In accordance with specialist recommendations, systemic thrombolytic therapy with alteplase was administered. After careful monitoring and bleeding risk assessment, the patient was admitted to the pulmonology ward for further follow-up and management.

Materials and Methods: This case highlights the importance of early recognition of massive pulmonary embolism in patients presenting with hemoptysis, dyspnea, and hemodynamic instability. Prompt imaging confirmation and immediate initiation of thrombolytic therapy are critical to improving clinical outcomes.

Keywords: Pulmonary embolism, hemoptysis, dyspnea

Ref No: 2360

Mesenteric Ischemia: When Pain Exceeds Physical Findings

Kadir Eryürük[1], Murat Seyit[1], Atakan Yılmaz[1], Mert Özen[1], Alten Oskay[1], İbrahim Türkçüer[1]

[1]Pamukkale University Faculty of Medicine

Murat Seyit / Pamukkale University Faculty of Medicine

Introduction and Purpose: Abdominal pain represents one of the most challenging diagnostic entities in emergency medicine. Although mesenteric ischemia is relatively uncommon, it carries high mortality. A classic clinical clue is severe abdominal pain disproportionate to physical examination findings. Early imaging is critical for timely diagnosis and improved outcomes.

Materials and Methods: A 71-year-old male presented with diffuse abdominal pain and nausea of six hours' duration. He described it as "the worst abdominal pain of my life." He denied diarrhea or fever. His medical history was significant for atrial fibrillation (with irregular anticoagulant use during the preceding week), hypertension, and peripheral arterial disease. On initial evaluation, the abdomen was surprisingly soft, without guarding or rebound tenderness, despite reported pain intensity of 10/10. Restlessness persisted even after analgesic administration.Vital Signs: Blood pressure 108/64 mmHg, heart rate 118 beats/min (atrial fibrillation with rapid ventricular response), SpO_2 98%, temperature 36.4°C.Laboratory Findings: Leukocyte count was 15.9 K/µL and C-reactive protein 12 mg/L. Serum lactate was markedly elevated at 4.6 mmol/L. Arterial blood gas analysis revealed metabolic acidosis (pH 7.31, HCO_3^- 18 mmol/L). D-dimer was 3.1 mg/L. Creatinine was 1.4 mg/dL. Amylase was mildly elevated at 160 U/L, potentially confounding the differential diagnosis with pancreatitis. Troponin was

negative.Imaging: Plain abdominal radiography showed no significant air-fluid levels. Given the combination of atrial fibrillation, pain out of proportion to examination findings, and elevated lactate, computed tomography mesenteric angiography was performed. Imaging demonstrated embolic occlusion of the proximal superior mesenteric artery (SMA) with early ischemic changes in small bowel loops. No evidence of perforation or free intraperitoneal air was observed.Management: Aggressive fluid resuscitation, broad-spectrum antibiotics, and systemic anticoagulation with heparin were initiated. Emergent consultations with general surgery and interventional radiology were obtained. The patient was rapidly prepared for surgical intervention with concurrent intensive care planning. Early revascularization was achieved before progression to transmural bowel necrosis.

Materials and Methods: In elderly patients—particularly those with atrial fibrillation—severe abdominal pain disproportionate to physical findings should prompt urgent evaluation for mesenteric ischemia. Serum lactate and CT angiography are crucial for early diagnosis. When pain exceeds examination findings, vascular etiologies must be considered.

Keywords: Abdominal pain, Mesenteric Ischemia, Lactate

Ref No: 2390

Predictive Factors of Abnormal Brain CT scan In Patients with Opioid Poisoning: A Single-Center Study

Alireza Abbasi[1], Mohammad Farhadi[1], Robab Sadegh[1], Kiarash Kavari[1]

[1]Shiraz University Of Medical Sciences

Mohammad Farhadi / Shiraz University Of Medical Sciences

Introduction and Purpose: Abstract Background: Opioid poisoning is a major cause of morbidity and mortality, particularly in Iran, yet no clear guideline exists for when to perform non-contrast BCTS in these patients. This study aims to identify clinical and laboratory factors that predict abnormal BCTS findings in patients with opioid poisoning, to inform more effective use of emergency neuroimaging.We conducted the study among opioid-poisoned patients presenting to the emergency department of Shiraz Namazi Hospital.

Materials and Methods: Method: This retrospective cross-sectional study was performed on 208 patients with opioid poisoning who were referred to the emergency department of Namazi Hospital between March 2019 and March 2021. To collect data, it was referred to the archives of

Namazi Hospital and then the necessary information for this study was collected from existing files.

Materials and Methods: Results: Of 208 patients with opioid poisoning who underwent brain CT scan, 57 (27.4%) had abnormal BCTS findings which applied to this selected subgroup of patients. On multivariable logistic regression, two independent predictive factors for abnormal BCTS were identified: advanced age (OR 1.041 per year; 95% CI 1.01–1.07; p=0.008) and lower serum bicarbonate (OR 0.908 per mEq/L; 95% CI 0.83–0.99; p=0.025).Conclusion: Advanced age and lower serum bicarbonate levels are independent predictors of abnormal BCTS findings in patients with acute opioid poisoning. Clinicians should consider urgent BCTS in older or metabolic acidotic patients, as these groups are at higher risk and may benefit most from emergent neuroimaging. The most common abnormal findings were microvascular ischemic damage changes, followed by ischemic infarctions.

Keywords: Poisoning, Opioid

Ref No: 2391

FROM INNOCENT HEADACHE TO A FATAL DIAGNOSIS: SINUS VEIN THROMBOSIS

Erdal Tekin[1], Hakan Alp[1], Mehmet Yaşar[1]

[1]Erzurum Atatürk Üniversitesi Araştırma Hastanesi

Hakan Alp / Erzurum Atatürk Üniversitesi Araştırma Hastanesi

Introduction and Purpose: Sinus Vein Thrombosis is a rare but potentially life-threatening condition that develops as a result of clot formation in the venous sinuses of the brain. This clot can obstruct cerebral venous drainage, leading to increased intracranial pressure and causing brain infarction or hemorrhage.

Materials and Methods: A 32-year-old female patient, 30 weeks pregnant, presented with complaints of increasing headache, nausea, and vomiting for the past 3 days. The patient has no additional complaints. It was learned that the patient recently had an upper respiratory tract infection. She states that the headache is unresponsive to analgesics. Upon arrival, the patient was conscious with unremarkable vital signs. The oropharynx and breath sounds were natural. In her neurological examination, muscle strength was 4/5 in the right lower and upper extremities; there were no other specific findings. No abnormalities were observed in the patient's laboratory

tests. After the patient's symptoms persisted following analgesic and hydration therapy, an MRI and MR Venography were planned. In the Brain MRI, the left transverse sinus was observed as hyperintense in the T2 axial sequence, consistent with left transverse sinus thrombosis. In the MR Venography, signal loss consistent with occlusion in the transverse sinus was observed in the axial section. The patient was admitted to the Neurology clinic with a pre-diagnosis of Sinus Vein Thrombosis.

Materials and Methods: When pregnant patients especially present with resistant headaches, it is important to perform a careful neurological examination and to keep a life-threatening diagnosis like SVT in mind.

Keywords: Pregnant, headache, sinus vein thrombosis

Ref No: 2398

Reduction of Temporomandibular Joint (TMJ) Dislocation Utilizing Point-of-Care Ultrasound (POCUS)-Guided Masseteric Nerve Block in the Emergency Department

MUHAMMED EMİN AKGÜN[1], ZEYNEP ÇAKIR[1]

[1]ATATURK UNIVERSTY

MUHAMMED EMİN AKGÜN / ATATURK UNIVERSTY

Introduction and Purpose: Temporomandibular joint (TMJ) dislocation is an acute condition presenting with severe pain and anxiety in the emergency department (ED). Traditional reduction techniques frequently require deep procedural sedation, which increases both the length of hospital stay and the risk of complications. In recent years, point-of-care ultrasound (POCUS)-guided masseteric nerve blocks have emerged as a safe alternative that eliminates the need for systemic sedation.

Materials and Methods: A 40-year-old female patient presented to the ED complaining of an inability to close her mouth and severe facial pain following a yawn. Physical examination revealed a bilateral anterior TMJ dislocation. Due to the patient's obesity (BMI 35) and history of sleep apnea, procedural sedation was deemed high-risk. Consequently, the masseter muscle was visualized inferior to the zygomatic arch using a high-frequency linear probe, and a bilateral POCUS-guided masseteric nerve block was administered (3 mL of 2% lidocaine per side). Ten minutes post-procedure, the masseter spasm had completely resolved, and the patient successfully self-reduced her jaw using the traditional syringe technique, completely pain-free

and without any sedation.The primary factor complicating the reduction of a TMJ dislocation is the reactive spasm of the masseter and pterygoid muscles. A POCUS-guided masseteric block overcomes this spasm, allowing the joint to easily glide back into its anatomical position. This technique entirely eliminates the risk of respiratory depression associated with sedative agents such as midazolam or propofol, saves valuable physician time, and expedites the patient's safe discharge from the ED.

Materials and Methods: The expanding proficiency of emergency physicians in utilizing POCUS-guided regional anesthesia represents a patient-centric approach that significantly mitigates the need for systemic sedation in painful orthopedic and facial procedures, such as TMJ reductions.

Keywords: Temporomandibular Joint, Masseteric Nerve Block, lidocaine

---

Ref No: 2407

IATROGENIC UNILATERAL MYDRIASIS FOLLOWING NEBULIZED SALBUTAMOL TREATMENT: A CASE REPORT

ALARA NERGİZ SOSLU[1], ZEYNEP ÇAKIR[1]

[1]ATATURK UNIVERSITY FACULTY OF MEDICINE, DEPARTMENT OF EMERGENCY MEDICINE

ALARA NERGİZ SOSLU / ATATURK UNIVERSITY FACULTY OF MEDICINE, DEPARTMENT OF EMERGENCY MEDICINE

Introduction and Purpose: Nebulized bronchodilator therapy is a cornerstone in the management of obstructive lung diseases presenting with shortness of breath in emergency departments. Although the use of beta-2 agonists like salbutamol is generally considered safe, contact of the drug with the eye due to mask leakage or careless application can lead to various ocular side effects. This situation, especially in patients with a history of cerebrovascular disease, can be confused with an acute neurological event, leading to unnecessary advanced imaging and anxiety.

Materials and Methods: A 40-year-old female patient with a known history of hypertension (HT) and hemorrhagic cerebrovascular accident (CVA) presented to our emergency department with complaints of shortness of breath and headache. Her blood pressure at admission was 184/96 mmHg. No neurological findings were detected on physical examination, but rhonchi

were heard in the lung bases on auscultation.Symptomatic treatment including salbutamol nebulization and antihypertensive therapy was initiated. After treatment, the patient's blood pressure normalized, and respiratory complaints improved; she was discharged with a prescription. Ten minutes after discharge, the patient returned with complaints of blurred vision in the right eye and enlargement of the pupil. On examination, the right eye appeared mydriatic. Due to her history of CVA, an emergency cranial CT was performed, which showed no acute cerebrovascular event. Following neurology and ophthalmology consultations, the pathology in the right eye was attributed to iatrogenic mydriasis caused by the exposure to nebulized salbutamol. The patient was discharged again with a recommendation for outpatient follow-up.

UNILATERAL MYDRIASIS



Materials and Methods: In cases of unilateral mydriasis developing after nebulized treatment in the emergency department, a thorough medical history is vital to avoid unnecessary radiological investigations. Incomplete fitting of the mask during treatment can cause the drug to leak into the eye, leading to pupil dilation through anticholinergic or sympathomimetic effects. Keeping this iatrogenic effect in mind during differential diagnosis ensures patient safety and aids in the efficient use of emergency department resources.

Keywords: salbultemol, anticholinergic side effect, iatrogenic unilateral mydriasis

---

Ref No: 2413

Multiple Thrombi Of Unknown Origin

Murat Kurtulmuş[1], Erdal Tekin[1]

[1]Atatürk Üniversitesi

Murat Kurtulmuş / Atatürk Üniversitesi

Introduction and Purpose: Many thromboses usually occur due to autoimmune syndromes, AFAS syndrome, active cancer, and genetic predisposition.we will examine a patient with multiple thromboses but no clinical symptoms .

Materials and Methods: Case:67 years old, femaleChronic disease: diabetes mellitus and hypertensionMedical complaint : pain in the left arm and chest pain.Vital signs : Right arm: 130/70, Left arm: 70/40, Pulse 105. Sat: 91ECG : sinus tachycardia.Physical examination: weak pulse in the left arm, normal lung sounds. Abdomen is relaxed.The patient was initially diagnosed with dissection, and a CT scan was performed. The CT scan did not show any dissection. However, the patient had near-total occlusion of the left subclavian artery , bilaterally. Pulmonary embolism is present. Partial thrombus is present in the SMA . Thrombus is present in the left iliac artery. Subsequent diffusion MRI revealed numerous findings consistent with acute ischemic stroke.Bilateral lower extremity Doppler ultrasound showed no evidence in favor of DVT .Transthoracic echocardiography of the implanted tissue did not reveal any intracardiac thrombus.

bt1



bt2

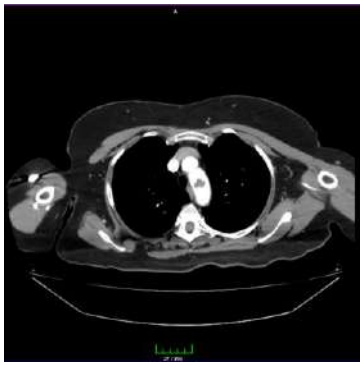

bt3



bt4

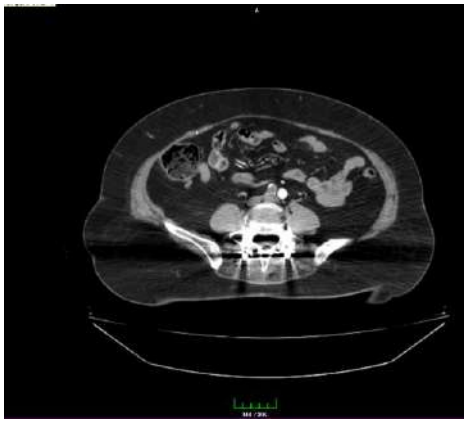

mr1

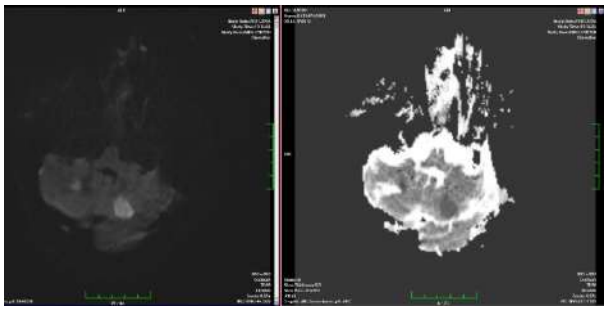

Materials and Methods: Conclusion:Even without an underlying disease causing multiple acute thromboses , we may find thrombosis in patients based on subtle clues or during imaging studies while investigating another preliminary diagnosis.

Keywords: tromboses, multiple, no symptoms

Ref No: 2435

From abdominal pain to tumors

Murat Kurtulmuş[1], Erdal Tekin[1]
[1]Atatürk Üniversitesi
Murat Kurtulmuş / Atatürk Üniversitesi

Introduction and Purpose: Intra-abdominal masses may not cause any symptoms. Or they may present with persistent abdominal pain, constipation, or blood in the stool.In this case, we will examine a patient who presented with persistent abdominal pain.

Materials and Methods: Case:38 years old, femaleThere are no chronic illnesses.Vital signs: blood pressure: 125/70, heart rate: 95, pulse: 85ECG: NSRPhysical examination: Widespread tenderness in the abdomen. No guarding, no rebound tenderness.Laboratory: no specific features.A contrast-enhanced CT scan revealed widespread increase in the diameter and content of the ileal loops, and a 31x16 mm mass lesion anterior to the ileum and cecum.

bt1

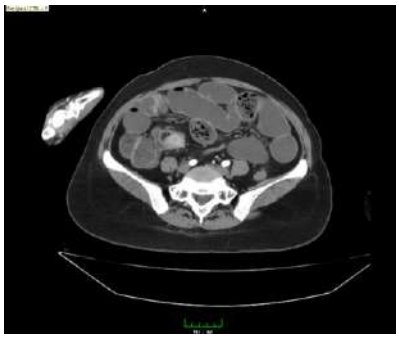

bt2

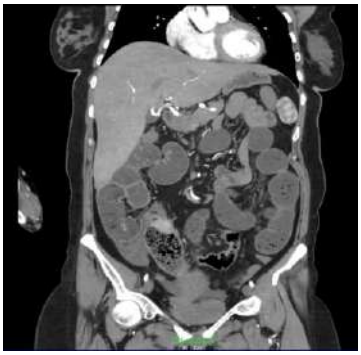

Materials and Methods: The patient was referred to general surgery and admitted to the hospital.

Keywords: pain, tümör, ileus

Ref No: 2440

Acute ischemic stroke in a patient with arrhythmogenic right ventricular dysplasia: a case report

Muhammed Fatih Düzyol[1], Abdülaziz Doğan[1], Hakan Akçırahan[1], Emin Fatih Vişneci[1], Mehmet Gül[1]

[1]Emergency Medicine Department, Konya City Hospital, Türkiye
[2]Emergency Medicine Department, Konya City Hospital, Türkiye

Hakan Akçırahan / Emergency Medicine Department, Konya City Hospital, Türkiye

Introduction and Purpose: Acute ischemic stroke is a neurological emergency that requires early diagnosis and prompt treatment. Imaging modalities play a critical role in diagnosis. However, in some patients—particularly those with implantable devices—magnetic resonance imaging (MRI) may not be feasible, complicating the diagnostic process. Arrhythmogenic right ventricular dysplasia (ARVD) is a rare cardiomyopathy that may predispose patients to arrhythmias and thromboembolic complications .

Materials and Methods: A 23-year-old female presented to the emergency department with impaired consciousness and speech difficulty. Her medical history revealed a diagnosis of arrhythmogenic right ventricular dysplasia, and she had an implantable cardioverter defibrillator (ICD) in situ.At presentation: Vital signs were stable, Neurological deficits were prominent on physical examination, The patient exhibited speech impairment and altered mental status. Initial brain computed tomography (CT) was interpreted as normal. Magnetic resonance imaging (MRI) could not be performed due to the presence of the ICD. A neurology consultation was obtained, and the patient was placed under close clinical observation. During follow-up: No clinical improvement was observed, Lumbar puncture (LP) findings were normal, Toxicological analyses were negative. Approximately 6 hours after symptom onset, repeat brain CT demonstrated: A hypodense area consistent with ischemia in the right middle cerebral artery (MCA) territory. Based on these findings, the patient was diagnosed with acute ischemic stroke and admitted to the intensive care unit.

Materials and Methods: Early diagnosis of acute ischemic stroke is critical for treatment and prognosis (1). However, CT imaging performed in the early phase may often be normal.

Therefore, in the presence of strong clinical suspicion, close monitoring and repeat imaging are essential.In this case, despite an initially normal CT scan, the persistence of neurological deficits prompted repeat imaging, leading to the diagnosis.This case highlights the importance of close clinical follow-up and repeat imaging in patients with persistent neurological deficits despite initially normal imaging findings.

Keywords: Acute ischemic stroke, arrhythmogenic right ventricular dysplasia, implantable cardioverter defibrillator

---

Ref No: 2538

Abdominal Aortic Aneurysm Rupture

Ahmet Mıtış[1], Umut Ocak[1], Mehmet Oğuzhan Ay[1], Yeşim İşler[1], Halil Kaya[1], Melih Yüksel[1]

[1]University of Health Sciences, Bursa Yuksek Ihtisas Training and Research Hospital, Department of Emergency Medicine, Bursa, Türkiye

Ahmet Mıtış / University of Health Sciences, Bursa Yuksek Ihtisas Training and Research Hospital, Department of Emergency Medicine, Bursa, Türkiye

Introduction and Purpose: Ruptured abdominal aortic aneurysm is a critical condition that predominantly affects elderly male patients and requires rapid diagnosis and immediate intervention. Hypotension, sudden onset abdominal or flank pain, and associated comorbidities are the main factors that increase mortality.

Materials and Methods: A 63-year-old male patient presented to the emergency department with sudden onset right flank pain. On admission, his blood pressure was 70/40 mmHg and heart rate was 120 beats per minute. The patient had a known history of hypertension. Physical examination revealed abdominal tenderness and significant pain in the right lumbar region. Due to hemodynamic instability, a rapid assessment and resuscitation protocol was initiated. Bedside emergency ultrasonography revealed a markedly dilated abdominal aorta. Following partial hemodynamic stabilization, contrast-enhanced abdominal computed tomography demonstrated a retroperitoneal hematoma consistent with a ruptured abdominal aortic aneurysm (Image 1-2). Laboratory tests showed decreased hemoglobin levels and elevated serum lactate. An urgent cardiovascular surgery consultation was requested for the patient. He was taken to emergency surgery.

Image 1

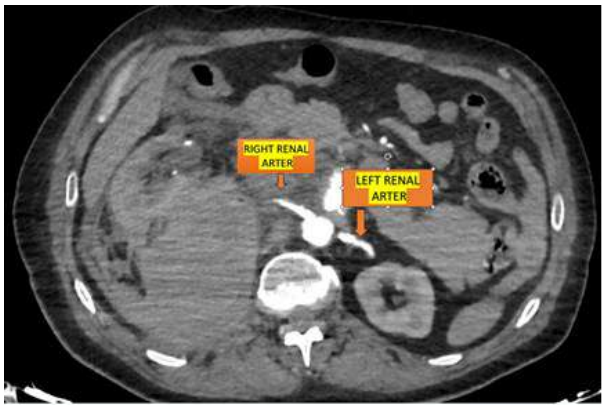

Computed Tomography (CT) images of the patient's abdomen.

Image 2

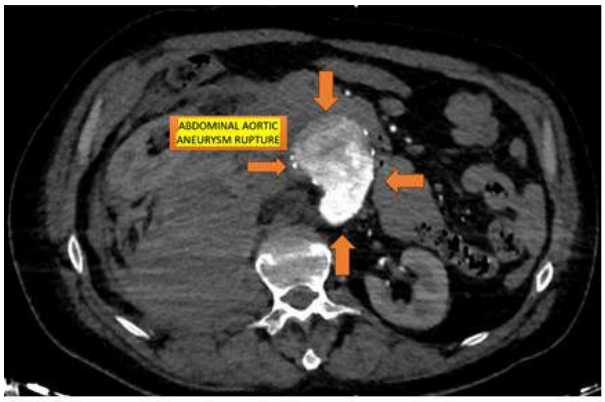

Findings of Rupture on Computed Tomography of the Abdominal Image

Materials and Methods: Ruptured abdominal aortic aneurysm may present with non-specific clinical findings. Hypotension, sudden onset abdominal or flank pain, and the presence of risk factors provide important diagnostic clues. Bedside ultrasonography plays a crucial role in rapid diagnosis and reducing mortality in emergency settings. In hemodynamically unstable patients, simultaneous coordination between imaging and surgical teams is essential. Ruptured abdominal aortic aneurysm is a life-threatening emergency that requires early diagnosis and prompt intervention. Effective use of bedside imaging and timely surgical management are the key determinants of patient survival.

Keywords: Emergency department, Abdominal aortic aneurysm, hypotension

Ref No: 2600

Gas-Containing Shoulder Abscess in a Patient with Multiple Comorbidities

Nevzat HERGÜL[1], Sevdegül KARADAŞ[1], Barış ÇİÇEK[1]
[1]Yuzuncu Yil University, Medical School Hospital, Van, Türkiye

Barış ÇİÇEK / Yuzuncu Yil University, Medical School Hospital, Van, Türkiye

Introduction and Purpose: Shoulder soft tissue infections are uncommon but may cause significant morbidity, particularly in patients with multiple systemic comorbidities. Early recognition and appropriate imaging are essential for detecting deep-seated infection and guiding timely management. We present a patient with multiple comorbidities in whom computed tomography revealed a gas-containing shoulder abscess extending from the glenohumeral region to the humeral metaphyseal-diaphyseal level.

Materials and Methods: A patient with diabetes mellitus, congestive heart failure, chronic kidney disease, ischemic cerebrovascular disease with left hemiplegia, chronic obstructive pulmonary disease, mitral valve replacement, and hypertension presented to the emergency department with weakness, fever, and right shoulder pain for one week. The patient reported right shoulder trauma approximately two years earlier, with marked worsening of pain during the preceding week. On examination, body temperature was 38°C, blood pressure was 160/90 mmHg, heart rate was 115 beats/min, and oxygen saturation was 85%. The right shoulder was swollen compared with the contralateral side, with tenderness, crepitation during movement, and restricted range of motion. Laboratory findings are presented in Table 1. Computed tomography demonstrated a fluid collection containing gas and dense internal components between the muscle planes, extending from the anteromedial aspect of the right glenohumeral joint to the humeral metaphyseal-diaphyseal level, consistent with a soft tissue abscess. The axial CT image is shown in Figure 1, and the sagittal CT image demonstrating inferior extension of the collection is shown in Figure 2.

Figure 1

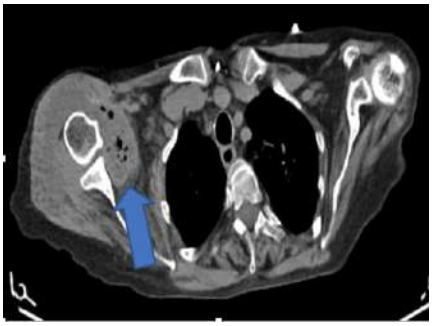

Axial CT image demonstrating a dense fluid collection containing air densities between the muscle planes, originating from the anteromedial aspect of the right glenohumeral joint.

Figure 2

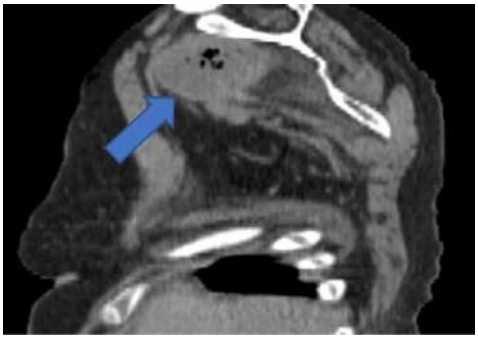

Sagittal CT image showing the extension of the same collection toward the humeral metaphyseal–diaphyseal level

Table 1

Parameter	Result	Reference Range
Blood glucose	127 mg/dL	70-110mg/dL
White blood cell count	7 x 10^3/µL	4.0-10.0 x 10^3/µL
Hemoglobin	11 g/dL	12.0-17.0 g/dL
C-reactive protein	91.2 mg/L	<5 mg/L
INR(International Normalized Ratio)	4.42	0.8-1.2

The patient's laboratory findings are presented

Results and Conclusion: Gas-containing soft tissue infections around the shoulder are rare but may progress rapidly, especially in patients with diabetes and other chronic diseases. Clinical findings may be nonspecific, making imaging crucial for early diagnosis. CT is particularly valuable for identifying soft tissue gas, delineating the extent of infection, and supporting prompt treatment planning. This case emphasizes that gas-containing shoulder abscess should be

considered in patients presenting with fever, shoulder pain, and multiple comorbidities. Early cross-sectional imaging may facilitate timely diagnosis and appropriate management.

Keywords: Shoulder abscess, soft tissue infection, computed tomography

---

Ref No: 2624

Warfarin Overdose

Fazilet Gücüko[1], Murat Seyit[1], Mert Özen[1], Alten Oskay[1], Atakan Yılmaz[1], İbrahim Türkçüer[1]
[1]Pamukkale University Faculty of Medicine
Murat Seyit / Pamukkale University Faculty of Medicine

Introduction and Purpose: Warfarin is used in the treatment and prophylaxis of many diseases. At low levels, the risk of thrombosis increases, whereas at high levels, the risk of bleeding increases. In this case, we present a patient with intra-abdominal bleeding due to warfarin overdose.

Materials and Methods: Our case is a 63-year-old male patient diagnosed with diabetes mellitus, hypertension, and chronic renal failure. He presented to an external medical center with complaints of abdominal pain and dizziness for one week. He was referred to our center with a diagnosis of progression of chronic renal failure. The patient stated that he did not know the names of the medications he was using. According to information obtained from the system, the patient has a history of heart valve replacement and is on warfarin therapy. The patient's neurological examination was evaluated as normal. On abdominal examination, there was diffuse tenderness. In the patient's blood tests, the device was unable to measure APTT, PT, and INR values (most likely due to excessively high levels). Abdominal CT imaging was consistent with hemoperitoneum. There was no recent history of trauma. The patient was evaluated as having hemoperitoneum secondary to warfarin overdose. He was hospitalized by the General Surgery Department for follow-up and treatment.

Materials and Methods: In patients using warfarin, a target INR range should be determined. Compliance with regular INR monitoring should be ensured once the target range is achieved. In cases of overdose, bleeding is an important cause of morbidity. First, warfarin therapy should be discontinued and appropriate treatment should be administered. Patients and their relatives should also be adequately informed about possible complications that may develop during warfarin use and the importance of INR monitoring.

Keywords: Warfarin, Bleeding, Overdose

Ref No: 2625

Anaphylaxis

Mert Can Yılmaz[1], Murat Seyit[1], Atakan Yılmaz[1], Mert Özen[1], Alten Oskay[1], İbrahim Türkçüer[1]

[1]Pamukkale University Faculty of Medicine

Murat Seyit / Pamukkale University Faculty of Medicine

Introduction and Purpose: Pruritus and erythema are often considered manifestations of a mild allergic reaction. However, the development of respiratory compromise and hypotension indicates progression to anaphylaxis, a life-threatening systemic hypersensitivity reaction. Early administration of intramuscular epinephrine is the cornerstone of treatment and is lifesaving.

Materials and Methods: A 26-year-old woman presented with generalized pruritus and lip swelling approximately 20 minutes after consuming seafood. Shortly thereafter, she developed dyspnea and dizziness. Vital Signs: Blood pressure was 88/54 mmHg, heart rate 124 beats/min, oxygen saturation 92% on room air, and body temperature 36.8°C. Physical Examination:Diffuse urticarial plaques were observed. There was angioedema involving the lips and tongue. Auscultation revealed bilateral wheezing. Laboratory and Imaging:No specific acute laboratory or imaging studies were required, as the diagnosis was clinical. Intramuscular epinephrine was administered immediately. Supplemental oxygen and intravenous fluid resuscitation were initiated. Antihistamines and corticosteroids were given as adjunctive therapy. The patient's hemodynamic and respiratory status improved under close observation.

Materials and Methods: In the presence of hypotension and respiratory findings, anaphylaxis must be assumed and treated promptly with epinephrine rather than antihistamines alone. Minutes can be lifesaving.

Keywords: Anaphylaxis, hypersensitivity, angioedema

Ref No: 2629

Antifreeze (Ethylene Glycol) Intoxication: An Initially Asymptomatic Case with Severe Metabolic Acidosis

Salih Necati İlhan[1], Murat Seyit[1], Atakan Yılmaz[1], Mert Özen[1], Alten Oskay[1], İbrahim Türkçüer[1]

[1]Pamukkale University Faculty of Medicine

Murat Seyit / Pamukkale University Faculty of Medicine

Introduction and Purpose: Ethylene glycol–containing antifreeze products are toxic substances that, after hepatic metabolism, produce glycolic acid and oxalic acid, leading to severe metabolic acidosis and multi-organ injury. Early clinical manifestations may be mild or nonspecific, which can delay diagnosis. We present a case of ethylene glycol intoxication that appeared clinically stable at presentation but was found to have severe high–anion gap metabolic acidosis.

Materials and Methods: A 44-year-old female presented to the emergency department two hours after ingesting approximately half a tea glass of antifreeze. She had no history of chronic alcohol use and reported no active symptoms at admission. Vital signs were as follows: blood pressure 118/72 mmHg, heart rate 96 beats/min, respiratory rate 22 breaths/min, temperature 36.7°C, and oxygen saturation 98% on room air. She was alert (GCS 15), oriented, and cooperative. Physical examination revealed no significant abnormalities.Arterial blood gas analysis demonstrated pH 7.10, bicarbonate 8 mmol/L, and $PaCO_2$ 24 mmHg, consistent with respiratory compensation. The anion gap was markedly elevated, indicating high–anion gap metabolic acidosis consistent with toxic alcohol ingestion

Materials and Methods: Supportive treatment and intravenous hydration were initiated. After consultation with the Poison Control Center, antidote therapy was started with 10% ethanol at 0.6 g/kg intravenously. Due to severe metabolic acidosis and the risk of toxic metabolite accumulation, the patient was admitted to the intensive care unit for hemodialysis.Early clinical stability may be misleading in ethylene glycol intoxication. Prompt recognition of metabolic acidosis and timely initiation of antidote therapy are critical to reducing morbidity and mortality.

Keywords: Ethylene glycol, metabolic acidosis, high anion gap

Ref No: 2646

Normotensive sepsis in a diabetic patient presenting with nonspecific symptoms

Erdem Zeki Karabulut[1], Mevlana Gül[1], Halim Taş[1]

[1]Ataturk University

Erdem Zeki Karabulut / Ataturk University

Introduction and Purpose: Sepsis is a major cause of morbidity and mortality worldwide. Although it is classically associated with fever, hypotension, and tachycardia, atypical presentations are common, particularly in patients with diabetes mellitus, leading to delayed diagnosis and treatment.

Materials and Methods: A 67-year-old male with a history of type 2 diabetes mellitus presented with generalized weakness, decreased oral intake, and mild confusion for two days. He denied fever, dysuria, or respiratory symptoms. On admission, vital signs were within normal limits. Physical examination was unremarkable except for mild dehydration. Laboratory findings revealed leukocytosis, elevated C-reactive protein (CRP), procalcitonin elevation, and serum lactate of 3.9 mmol/L. Renal function tests showed mild acute kidney injury. Urinalysis demonstrated significant pyuria and bacteriuria. Blood and urine cultures were obtained. Despite the absence of hypotension or fever, the elevated lactate level raised concern for occult tissue hypoperfusion.

Materials and Methods: The patient was diagnosed with sepsis secondary to urinary tract infection and promptly treated with intravenous fluids and broad-spectrum antibiotics. Blood cultures later confirmed Escherichia coli. Clinical status improved rapidly with early intervention. This case emphasizes that sepsis may present without classical findings, especially in diabetic patients. Elevated lactate levels may serve as an early indicator of sepsis even in normotensive patients, and clinicians should maintain a high index of suspicion.

Keywords: Sepsis, diabetes mellitus, lactate

Ref No: 2647

ST-Segment Elevation Mimicking Acute Myocardial Infarction in a Young Adult with Gastrointestinal Symptoms: Myocardial Bridging as a Diagnostic Pitfall

Ömer Babaoğlu[1], Murat Seyit[1], Atakan Yılmaz[1], Mert Özen[1], Alten Oskay[1], İbrahim Türkçüer[1]

[1]Pamukkale University Faculty of Medicine

Murat Seyit / Pamukkale University Faculty of Medicine

Introduction and Purpose: ST-segment elevation on electrocardiography is most commonly associated with acute myocardial infarction; however, not all ST elevations represent acute coronary occlusion. In young patients without cardiovascular risk factors, atypical presentations and coexisting non-cardiac symptoms may obscure the underlying diagnosis and lead to unnecessary invasive interventions.Myocardial bridging is a congenital coronary anomaly characterized by systolic compression of an epicardial coronary artery, most frequently the left anterior descending artery. Although often asymptomatic, it may occasionally present with ischemic electrocardiographic changes and elevated cardiac biomarkers.This case aims to highlight myocardial bridging as a diagnostic pitfall mimicking ST-segment elevation myocardial infarction in a young patient presenting with prominent gastrointestinal symptoms.

Materials and Methods: An 18-year-old male presented to the emergency department with fever, abdominal pain, diarrhea, and vomiting. He had no known medical conditions, cardiovascular risk factors, or family history of coronary artery disease. Initial vital signs were stable.During evaluation, the patient also reported chest discomfort. Electrocardiography demonstrated ST-segment elevation suggestive of acute myocardial infarction. Initial cardiac troponin level was elevated at 29 ng/L and increased to 40 ng/L on serial measurement. Given the electrocardiographic findings and biomarker elevation, acute coronary syndrome was suspected, and cardiology consultation was obtained.Urgent coronary angiography was performed. The right coronary artery and circumflex artery were normal. Angiography revealed a myocardial bridge involving the distal segment of the left anterior descending artery without evidence of fixed coronary stenosis or thrombotic occlusion. No percutaneous coronary intervention was required. The patient was managed conservatively with medical therapy and close observation.

ECG

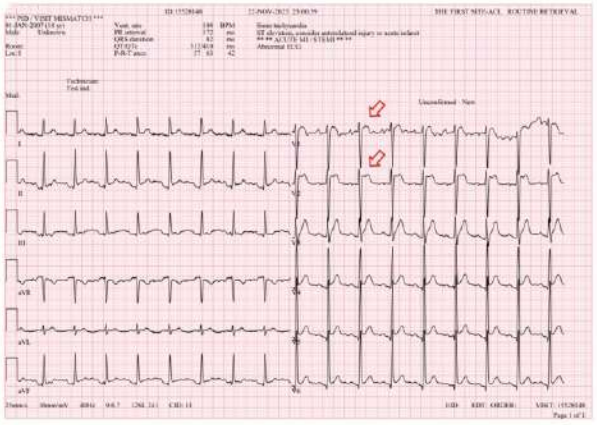

Figure 1. Initial electrocardiogram demonstrating ST-segment elevation suggestive of acute myocardial infarction in a young patient.

Materials and Methods: The patient's symptoms resolved with supportive and medical management, and no further ischemic events occurred during follow-up. This case demonstrates that myocardial bridging may present with ST-segment elevation and troponin elevation, closely mimicking acute myocardial infarction, particularly in young patients with atypical and misleading gastrointestinal symptoms.In young adults presenting with ST-segment elevation and low cardiovascular risk, dynamic coronary anomalies such as myocardial bridging should be considered in the differential diagnosis. Careful electrocardiographic interpretation, serial cardiac biomarkers, and early cardiology collaboration are essential to ensure accurate diagnosis and to avoid unnecessary invasive procedures in the emergency department.

Keywords: ST-segment elevation, Myocardial bridging, Acute coronary syndrome

---

Ref No: 2668

Allopurinol-Induced Dress Syndrome In A Patient With Gout

Tuba Nur Vural[1], Murat Seyit[1], Mert Özen[1], Alten Oskay[1], Atakan Yılmaz[1], İbrahim Türkçüer[1]

[1]Pamukkale University Faculty of Medicine

Murat Seyit / Pamukkale University Faculty of Medicine

Introduction and Purpose: Drug Reaction with Eosinophilia and Systemic Symptoms (DRESS) syndrome is a severe, potentially life-threatening hypersensitivity reaction. Allopurinol is one of the most commonly implicated medications. Early recognition and withdrawal of the offending agent are essential.

Materials and Methods: A 76-year-old female patient with a known history of gout was prescribed allopurinol. Following initiation of therapy, she developed widespread erythematous and pruritic skin eruptions involving the entire body. Physical Examination and Vital Signs: On admission, the patient's airway was patent and vital signs were stable. Dermatological examination revealed diffuse erythematous, pruritic maculopapular rash. Diagnosis: Based on the clinical presentation and recent exposure to allopurinol, the condition was evaluated as Drug Reaction with Eosinophilia and Systemic Symptoms (DRESS) syndrome. Management: Allopurinol was discontinued immediately. The patient was admitted to the dermatology service for close monitoring and initiation of appropriate supportive and systemic therapy.

Materials and Methods: DRESS syndrome should be suspected in patients presenting with widespread rash after recent initiation of high-risk medications such as allopurinol. Prompt discontinuation of the causative agent and specialist management are crucial to prevent severe complications.

Keywords: DRESS Syndrome, Allopurinol, Drug Hypersensitivity Reaction

---

Ref No: 2686

A Critical Entity Mimicking Acute Coronary Syndrome in the Emergency Department: Spontaneous Coronary Artery Dissection (SCAD)

ŞAFAK ÇOMURLU[1]

[1]ATATURK UNIVERSTY

ŞAFAK ÇOMURLU / ATATURK UNIVERSTY

Introduction and Purpose: Introduction: Spontaneous coronary artery dissection (SCAD) is a rare but potentially fatal cause of acute myocardial infarction (AMI), frequently observed in young women lacking atherosclerotic risk factors. Its presentation as classic atherosclerotic AMI in the emergency department creates a diagnostic challenge. This report aims to discuss the management of SCAD in a young female patient presenting with ST-segment elevation myocardial infarction (STEMI).

Materials and Methods: Case Presentation: A 32-year-old female patient, three weeks postpartum with no known comorbidities, presented to the emergency department with sudden-onset, compressive chest pain radiating to the left arm. Her electrocardiogram (ECG) revealed a 3 mm ST-segment elevation in the anterolateral leads (V1-V6, I, aVL). The patient was

transferred to the catheterization laboratory for primary percutaneous coronary intervention (PCI). Coronary angiography demonstrated a type 2 SCAD in the left anterior descending (LAD) artery. Due to the risk of dissection propagation, stenting was deferred; a decision was made for medical management, and the patient was admitted to the coronary intensive care unit.Discussion: The pathophysiology of SCAD involves a tear in the coronary artery intima or spontaneous hemorrhage from the vasa vasorum. According to Tintinalli and the American Heart Association (AHA) guidelines, the postpartum period, fibromuscular dysplasia, and connective tissue disorders are the most significant risk factors. Unlike in classic STEMI patients, routine PCI (stenting) in SCAD cases may exacerbate luminal occlusion by extending the dissection flap. Therefore, in the absence of hemodynamic instability or left main coronary artery involvement, conservative medical management (e.g., beta-blockers, antiplatelet therapy) should be the preferred approach.

Materials and Methods: Conclusion: Emergency physicians should maintain a high index of suspicion for SCAD in STEMI presentations among young female patients, particularly those in the peripartum period and lacking atherosclerotic risk factors. Early and accurate diagnosis protects the patient from unnecessary and potentially harmful invasive procedures.

Keywords: STEMI, Coronary Artery Dissection, Postpartum Myocardial Infarction

---

Ref No: 2703

A Rare Cause of Syncope in the Emergency Department: COVID-19-Associated Systemic Capillary Leak Syndrome

Murat Koyun[1], Arzu Babacan[2]

[1]Murat Koyun
[2]Arzu Babacan

Murat Koyun / Murat Koyun

Introduction and Purpose: Introduction :Systemic capillary leak syndrome (SCLS) is characterized by significant plasma shift from the intravascular to the extravascular space with increased capillary permeability. Hypotension, hemoconcentration, and hypoalbuminemia are the classic triads. Here, we aim to discuss the diagnosis, treatment and prognosis of our patient with syncope complaints, diagnosed with SCLS and had positive reverse transcriptase polymerase chain reaction (RT-PCR) results.

Materials and Methods: Case :A female patient, who had given birth vaginally forty-five days earlier without additional medical conditions or medication use, admitted to the emergency department weakness, syncope, sweating, and fatigue complaints. Upon arrival, the patient was conscious, hypotensive (77/55 mmHg), tachycardic (118 beats/min) with respiratory rate of 28 (minute) and 88 O2 saturation. In physical examination, filiform pulses, pallor, bilateral pretibial edema and bilateral rales in lung bases were found. Laboratory investigations revealed significant hemoconcentration (Hb:20.7 g/dL, Hct: 62.8%), hypoalbuminemia (21.2 g/L) and hypoproteinemia (total protein:24.26). Fluid accumulation is present in thoracic and abdominal computer tomography (CT) (Figure 1, 2). No bleeding, infection or trauma focus that could explain the shock-state was found. The patient was diagnosed with SCLS. Fluid therapy, vasopressor support, and supportive treatments (prednisolone, theophylline, diuretics, salbutamol) were started. The patient whose clinical condition rapidly worsened was intubated and admitted to the intensive care unit but passed away six hours later. The subsequent RT-PCR test came back positive.

Figure 2



Figure 1



Materials and Methods: Discussion:SCLS, a rare disease, usually begins suddenly with nonspecific symptoms like weakness, dizziness, nausea, mild fever, and fatigue. As fluid-loss increases, it progresses to shock state of muscle pains and low blood pressure. Although rare, viral infections, overreaction of immune system, and certain medications can trigger the process. The diagnosis is usually made with clinical observation and laboratory data including blood, urine tests, and imaging methods. Recently, some case reports have been published regarding SARS-CoV-2 infection and SCLS developing after vaccination. Although its exact pathophysiology has not been explained, the presumed mechanism is dysregulation in the inflammatory response leading to cytokine storm. Suspicion of emergency physicians towards this rare but fatal condition, which can be triggered by COVID-19 is vital for early diagnosis and management.

Keywords: Systemic Capillary Leak Syndrome, Covid-19, Emergency Department

---

Ref No: 2768

Ventricular Fibrillation Developing Due to Anterior STEMI in the Emergency Department

Taner Küçücük[1], Murat Seyit[1], Mert Özen[1], Alten Oskay[1], Atakan Yılmaz[1], İbrahim Türkçüer[1]

[1]Pamukkale University Faculty of Medicine

Murat Seyit / Pamukkale University Faculty of Medicine

Introduction and Purpose: Acute ST-segment elevation myocardial infarction (STEMI) can lead to sudden cardiac death due to malignant ventricular arrhythmias in the early phase. Anterior STEMI, in particular, involves a large myocardial area and increases the risk of ventricular fibrillation (VF). Primary VF can often be reversed with early defibrillation and has a better prognosis compared to late-phase arrhythmias. In this case, the emergency management of a patient with anterior STEMI who was hemodynamically stable on arrival but developed sudden VF during monitored observation is presented.

Materials and Methods: : A 39-year-old male patient with a 20 pack-year smoking history presented with fatigue, restlessness, and inability to stay still. On initial evaluation, vital signs were stable: Glasgow Coma Scale 15, blood pressure 121/68 mmHg, heart rate 91 bpm, SpO_2 98%, and temperature 36.4 °C. ECG showed ST elevation in anterior leads. While preparing the patient for PCI, sudden loss of consciousness and VF occurred during monitored observation. Immediate defibrillation was applied, achieving return of spontaneous circulation (ROSC), followed by endotracheal intubation. After hemodynamic stabilization, the patient was

transferred to the coronary angiography unit for primary PCI. Anterior STEMI affects a large myocardial area, resulting in a high risk of early malignant arrhythmias. Development of VF in a monitored setting and rapid defibrillation reduce mortality. This case highlights the importance of early diagnosis, continuous monitoring, and prompt intervention in emergency departments. Even if primary VF occurs, early management and rapid transfer for PCI can significantly improve patient prognosis.

ECG

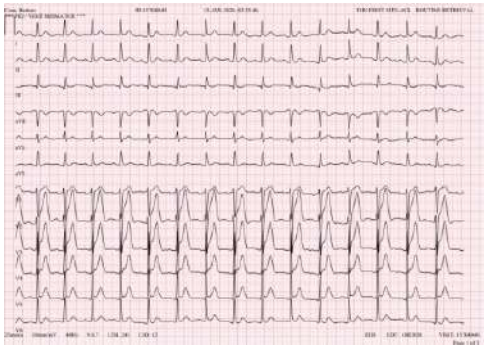

Materials and Methods: Even STEMI patients who appear initially stable may develop sudden ventricular arrhythmias. Continuous monitoring, early defibrillation, and timely primary PCI in the emergency department are key measures to reduce mortality.

Keywords: Fatigue, STEMI, Ventricular fibrillation

Ref No: 2773

Pleural Empyema

Fazilet Gücüko[1], Murat Seyit[1], Atakan Yılmaz[1], Mert Özen[1], Alten Oskay[1], İbrahim Türkçüer[1]

[1]Pamukkale University Faculty of Medicine

Murat Seyit / Pamukkale University Faculty of Medicine

Introduction and Purpose: Parapneumonic effusions are frequently caused by bacterial and viral pneumonias. When these effusions become complicated, pus accumulates in the pleural cavity, resulting in empyema. The most common microorganisms causing empyema in adults

and children are Streptococcus pneumoniae, Staphylococcus aureus, and Streptococcus pyogenes.

Materials and Methods: A 35-year-old male patient with no known medical history and no regular medication use, working in cotton harvesting, presented to the emergency department with complaints of shortness of breath, cough, and yellow-green sputum for 4–5 days. On admission, his vital signs were: BP: 120/20 mmHg, Temperature: 36.4°C, RR: 28/min, SpO_2: 88%. On auscultation, breath sounds were absent in the right lung and normal in the left lung. Oxygen therapy was initiated, and imaging studies were performed.Thoracic CT revealed an effusion between the right pleural layers showing loculation, reaching up to 9 cm at its thickest point, pleural thickening, and air-fluid levels, which were primarily evaluated in favor of empyema.The patient was evaluated by the thoracic surgery department, and the fluid observed on ultrasound was aspirated. After chest tube placement, fluid analysis was reported as neutrophil-dominant exudate. The patient was hospitalized under the care of thoracic surgery with preliminary diagnoses of right pyothorax?, abscess?, and pneumothorax?, and a right VATS exploratory procedure was planned.

Materials and Methods: Empyema is a common complication of bacterial pneumonia and is one of the oldest diseases known in medical history. Even today, in cases of delayed intervention, it remains an important medical problem with high mortality rates.

Keywords: Empyema, Pleura, Shortness of Breath

Ref No: 2776

Subarachnoid Hemorrhage with Intraventricular Extension in a Patient with Multiple Cardiovascular Comorbidities

Samed Tolun[1], Sabri Sekme[1]

[1]Niğde Ömer Halisdemir Training Research Hospital

Sabri Sekme / Niğde Ömer Halisdemir Training Research Hospital

Introduction and Purpose: Subarachnoid hemorrhage(SAH) represents one of the most critical neurological emergencies, often presenting with a sudden, severe "thunderclap" headache. When accompanied by intraventricular extension, the prognosis worsens significantly, necessitating rapid neurovascular intervention.

Materials and Methods: A 41-year-old female with a known history of hypertension(HT), type 2 diabetes mellitus(DM), and coronary artery disease(CAD)—including a history of two prior coronary angiography procedures and appendectomy—presented to the emergency department on April 6, 2026.The patient reported a sudden-onset, severe headache that had begun that morning and persisted without relief, accompanied by nausea. She was currently on insulin, antihypertensive, antidiabetic, and cardiac medications, though she was unable to specify their names. No known drug allergies were reported, and family history was unremarkable.On admission, vital signs revealed a temperature of 36.5°C, blood pressure of 180/90 mmHg, heart rate of 78 bpm, and oxygen saturation of 94%. Neurological examination demonstrated a Glasgow Coma Scale(GCS) score of 15, with the patient fully alert, oriented, and cooperative. Cranial nerve examination was intact, respiratory auscultation revealed equal bilateral air entry, and abdominal examination showed no guarding or rebound tenderness.Non-contrast cranial computed tomography (CT) revealed widespread spontaneous hyperdensities within the basal cisterns and bilateral sylvian fissures, consistent with diffuse subarachnoid hemorrhage. Additionally, hemorrhagic hyperdensities were identified within the fourth ventricular lumen, raising concern for intraventricular hemorrhage(IVH). Bilateral basal ganglia, thalami, bilateral centrum semiovale, and cerebellar sulci showed no additional acute pathology. No major osseous abnormality was detected.The patient received intravenous paracetamol, tramadol, ondansetron, and nimodipine (100 cc in normal saline) for symptomatic management and vasospasm prophylaxis. Given the imaging findings indicating diffuse SAH with suspected IVH, urgent digital subtraction angiography(DSA) was indicated to identify a potential underlying aneurysm or vascular malformation. The patient was monitored in the critical care unit and subsequently transferred to Adana City Hospital for definitive neurovascular evaluation and management.

1

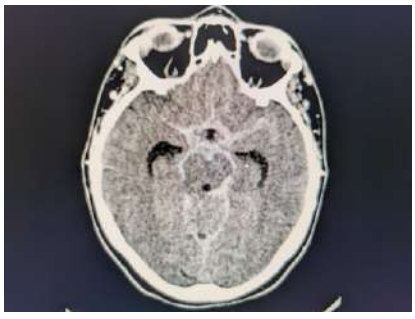

2

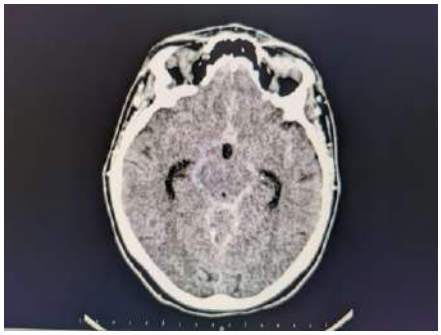

3

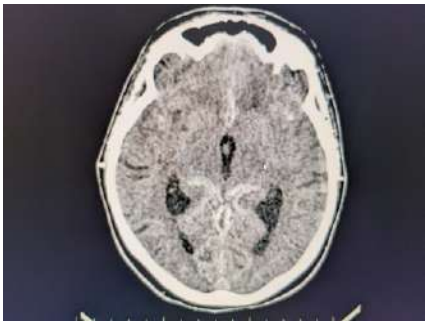

4

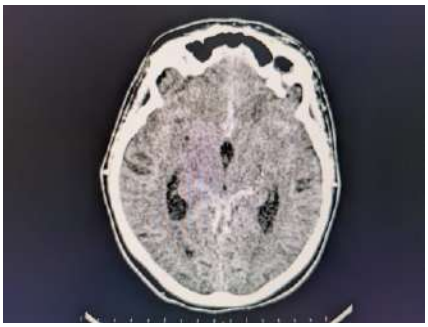

Results and Conclusion: This case highlights the importance of immediate neuroimaging in patients presenting with thunderclap headache, particularly those with poorly controlled hypertension. The co-occurrence of IVH with diffuse SAH significantly increases procedural urgency and underscores the need for prompt transfer to a tertiary center capable of endovascular intervention.

Keywords: Subarachnoid hemorrhage, Hypertension

Ref No: 2780

Is it possible to swallow a toothbrush completely?

Bülent Kavuşturan[1], Halil Kaya[1], Yeşim Işler[1], Mehmet Oğuzhan Ay[1], Melih Yüksel[1], Umut Ocak[1]

[1]University of Health Sciences, Bursa Yüksek İhtisas Training and Research Hospital, Department of Emergency Medicine, Bursa/Türkiye

Bülent Kavuşturan / University of Health Sciences, Bursa Yüksek İhtisas Training and Research Hospital, Department of Emergency Medicine, Bursa/Türkiye

Introduction and Purpose: İn a Medline screening, nearly 40 cases of swallowing a toothbrush were found. Nearly all of the cases were women with bulimia/anorexia nervosa.Tooth brushes were found in the oesophagus or stomach. Spontaneous passage from the gastrointestinal tract wasn't observed.

Materials and Methods: A 30-year-old woman was admitted to the emergency room with a complaint of accidentally swallowing a toothbrush while trying to clean the backside of her tongue. After taking a detailed anamnesis, she was a physically and mentally healthy person, and there were no chronic diseases or history of alcohol and drug or substance abuse.All vital findings were within normal limits. Examination of the oropharynx was normal. She had no dyspnoea, dysphagia, pain, or hypersalivation. Physical Examination of the abdomen was within the normal limits. X-rays of the thorax and abdomen didn’t clearly visualize the toothbrush. Ultrasound of the abdomen wasn’t successful enough to define the suspected toothbrush.But abdominal Computerised tomography clearly showed that there was a full toothbrush in the stomachA control endoscopy was performed to see if there is any complication. There weren’t any problems.

Figure 1



Figure 2



Results and Conclusion: If the swallowed objects are smaller than 5 centimeters in diameter and have smooth edges, they can pass through the gastrointestinal tract. A toothbrush or a broken bristle part of the toothbrush has never been observed exiting from the rectumForeign objects longer than 10 centimeters cannot pass through the gastrointestinal tract. They must be removed surgically or endoscopicallyIf Emergency Physicians observe a foreign object in the esophagus or stomach, we have to consider bulimia or anorexia nervosa, and these patients generally use a toothbrush to trigger vomiting and accidentally swallow it.

Keywords: Swallowing a toothbrush, Gastrointestinal foreign objects, Endoscopic removal of gastrointestinal foreign objects

---

Ref No: 2819

A Case of Plastron Appendicitis Presenting with Nonspecific Complaints

ALPARSLAN ALTUN[1], HALİM TAŞ[1], ALİ GÜR[1]

[1]Atatürk University Hospital Department of Emergency Medicine

ALPARSLAN ALTUN / Atatürk University Hospital Department of Emergency Medicine

Introduction and Purpose: Acute appendicitis is one of the most common surgical emergencies. However, in some cases, diagnosis may be delayed, leading to the development of plastron appendicitis. Plastron appendicitis is defined as a localized inflammatory mass formed

by the surrounding tissues following perforation of the appendix. Clinical findings may be atypical, and diagnosis is often established imaging modalities.

Materials and Methods: A 65-year-old male patient presented with complaints of fatigue persisting for approximately one month. The patient reported intermittent abdominal pain but did not describe typical signs of an acute abdomen.On physical examination, the abdomen was soft with no rebound tenderness or guarding. The patient was subfebrile, and his general condition was good.Laboratory investigations revealed leukocytosis and elevated C-reactive protein levels. Abdominal ultrasonography and contrast-enhanced computed tomography demonstrated inflammatory changes around the appendix in the right lower quadrant, along with a mass consistent with plastron formation.Based on clinical and radiological findings, the patient was diagnosed with plastron appendicitis. The patient was managed conservatively with antibiotic therapy and close follow-up instead of surgical intervention.

coronal



axial

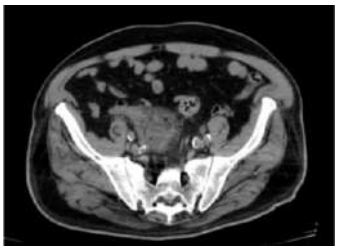

Materials and Methods: Plastron appendicitis is a delayed complication of acute appendicitis and may present with atypical symptoms. It should be considered in the differential diagnosis, especially in patients with long-standing nonspecific complaints. Imaging modalities play a crucial role in diagnosis. Conservative management can yield successful outcomes in appropriately selected patients.

Keywords: Plastron Appendicitis, Nonspecific Complaints, complication

Ref No: 2828

CONCURRENT CEREBROVASCULAR AND PERIPHERAL THROMBOEMBOLISM

Yusuf Burak Eker[1], Erdal Tekin[1], Aykut Adıgüzel[1]

[1]Atatürk Üniversitesi Tıp Fakültesi Acil Tıp Anabilim Dalı

Yusuf Burak Eker / Atatürk Üniversitesi Tıp Fakültesi Acil Tıp Anabilim Dalı

Introduction and Purpose: Thromboembolism can present with a wide variety of clinical manifestations upon hospital admission. These may range from short-lived episodes, such as transient ischemic attacks (TIA), to persistent emboli that require intervention to resolve. The clinical presentation varies depending on the anatomical site of the thromboembolism. Findings may include neurological deficits such as speech disturbances or lateralizing signs; cardiac and pulmonary symptoms like chest pain and dyspnea; or acute extremity pain.

Materials and Methods: An 80-year-old female patient presented to our emergency department with a 30-minute history of numbness and loss of strength in her left arm and leg. Physical examination revealed 2/5 motor strength in both the left upper and lower extremities, along with hypoesthesia in the left lower extremity. Imaging studies identified a lacunar infarct in the right parietal region (Figure 1). Simultaneously, during the physical examination, peripheral pulses in the right lower extremity were found to be impalpable. Subsequent diagnostic imaging demonstrated a complete absence of contrast flow in the right popliteal artery (Figure 2).

Figure 1

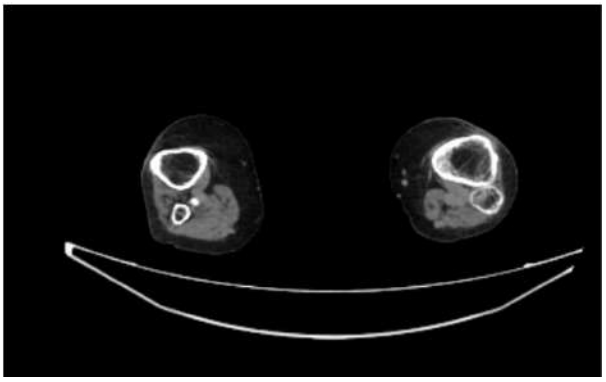

Figure 2

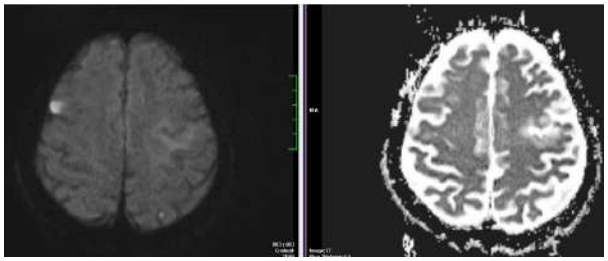

Materials and Methods: Depending on the primary source of the emboli, thromboembolism can occur in multiple vascular territories simultaneously. In patients where a single thromboembolic event is identified, a meticulous systemic examination must be performed to screen for concurrent emboli in other regions.

Keywords: Thromboembolism, Acute Ischemic Stroke, Acute Limb Ischemia

---

Ref No: 2859

Scleral Perforation

Safa Gödeoğlu[1], Murat Seyit[1], Mert Özen[1], İbrahim Türkçüer[1], Alten Oskay[1], Atakan yılmaz[1]

[1]Pamukkale University Faculty of Medicine

Murat Seyit / Pamukkale University Faculty of Medicine

Introduction and Purpose: Open globe injuries are ophthalmic emergencies that may result in permanent visual loss if not promptly recognized and managed. Blunt facial trauma can cause globe rupture, especially in pediatric and adolescent patients. Early diagnosis, appropriate initial management in the emergency department, and urgent ophthalmologic intervention are critical for visual prognosis. This case report aims to present an adolescent patient with an open globe injury following occupational blunt facial trauma and to emphasize the importance of early multidisciplinary management.

Materials and Methods: A 14-year-old male with no known chronic medical conditions presented to the emergency department after sustaining blunt facial trauma when a vehicle cooling fan dislodged and struck his face while he was working as a trainee in an auto repair shop. The patient reported three episodes of vomiting prior to admission and complained of vision loss in the left eye. On arrival, vital signs were stable (blood pressure 110/70 mmHg, heart rate 95 beats/min, oxygen saturation 98%, body temperature 36.9°C). Physical examination

revealed hyphema and vitreous fluid leakage in the left eye, suggestive of globe injury. Additionally, a 3-cm superficial laceration was present on the nasal dorsum, along with newly developed abrasions inferior to the left orbit. Other system examinations were unremarkable.

Scleral Perforation



Materials and Methods: A non-contrast cranial computed tomography scan showed no acute intracranial pathology; however, orbital computed tomography revealed findings suspicious for left globe perforation. Gentle, non-pressurized eye irrigation was performed, and bilateral eye shielding was applied. Oral intake was withheld. Intravenous cefazolin was initiated at a weight-appropriate dose for infection prophylaxis. Tetanus vaccination was not administered, as the patient had completed three doses and received the last booster one year prior. The nasal laceration was managed with primary suturing. Following ophthalmology consultation, an open globe injury was confirmed, and the patient was admitted to the ophthalmology service for urgent surgical intervention. This case highlights the necessity of avoiding ocular pressure, initiating early antibiotic prophylaxis, and ensuring rapid ophthalmologic consultation in suspected open globe injuries to optimize visual outcomes.

Keywords: Open globe injury, Blunt facial trauma, Hyphema

Ref No: 2870

A Rare Presentation Of Acute Pyelonephritis Mimicking Appendicitis İn The Emergency Department

Betül Aytürk[1], Murat Seyit[1], Alten Oskay[1], Atakan Yılmaz[1], Mert Özen[1], İbrahim Türkçüer[1]

[1]Pamukkale University Faculty of Medicine

Murat Seyit / Pamukkale University Faculty of Medicine

Introduction and Purpose: Acute pyelonephritis (APN) is a potentially severe bacterial infection of the renal pelvis and kidney. While classical symptoms include flank pain and fever, atypical presentations can lead to diagnostic challenges. The objective of this case report is to present an unusual case of APN presenting with acute right lower quadrant pain in the emergency department (ED).

Materials and Methods: We report the clinical course of a 32-year-old female patient who presented to our ED with a two-day history of right lower quadrant pain, low-grade fever, and nausea. The patient's clinical examination findings, laboratory test results, and radiological imaging records were retrospectively reviewed. On initial physical examination, the patient exhibited significant right lower quadrant tenderness without classical costovertebral angle tenderness. Laboratory investigations revealed leukocytosis (15,000 cells/mcL) and elevated C-reactive protein (CRP) levels. Given the suspicion of acute appendicitis, an abdominal computed tomography (CT) scan was performed. The CT scan ruled out appendicitis but demonstrated right-sided perinephric fat stranding and an enlarged right kidney, confirming the diagnosis of APN. Urinalysis later confirmed pyuria and bacteriuria. The patient was admitted and successfully treated with intravenous antibiotics, showing full clinical improvement by day four.

Materials and Methods: In conclusion, APN can present atypically and mimic other acute abdominal emergencies. Emergency physicians should maintain a high index of suspicion and utilize appropriate imaging like CT to prevent misdiagnosis and delay in appropriate care.

Keywords: Acute pyelonephritis, Emergency department, Abdominal pain

Ref No: 2882

Boerhaave Syndrome

Firuze Yusuf[1], Umut Ocak[1], Melih Yüksel[1], Yeşim İşler[1], Mehmet Oğuzhan Ay[1], Dursun Mafis[1], Halil Kaya[1]
[1]University of Health Sciences, Bursa Yuksek Ihtisas Training and Research Hospital, Department of Emergency Medicine, Bursa/Türkiye
Firuze Yusuf / University of Health Sciences, Bursa Yuksek Ihtisas Training and Research Hospital, Department of Emergency Medicine, Bursa/Türkiye

Introduction and Purpose: Boerhaave syndrome is a full-thickness perforation of the esophagus following a sudden increase in intraesophageal pressure. The mechanism in most cases is sudden, forceful retching; it has also been reported that coughing, straining, seizures, and childbirth can cause perforation. The perforation is usually on the left side of the distal esophagus.

Materials and Methods: A 72-year-old male patient with a known history of asthma presented to the emergency department (ED) with complaints of pain on the left side of the chest and difficulty breathing, which developed after several days of nausea and vomiting following the initiation of medication for an upper respiratory tract infection. Vital signs at presentation: blood pressure 130/70 mmHg; heart rate 96/min; oxygen saturation 99%; temperature 36.3°C; respiratory rate 22/min. On physical examination, the oropharynx was normal, and bilateral rhonchi were present on lung auscultation. ECG showed sinus rhythm, the abdomen was soft with no guarding or rebound tenderness. No abnormal findings were detected in laboratory tests. No abnormalities were observed on the patient's PA chest imaging (İmage1). A computed tomography scan of the thorax was requested. Tomographic sections showed air foci, contamination, and loculations adjacent to the esophagus (İmage 2). The patient was admitted after consultation with the general surgery clinic.

Image



Patient PA Chest X-ray

Image 2

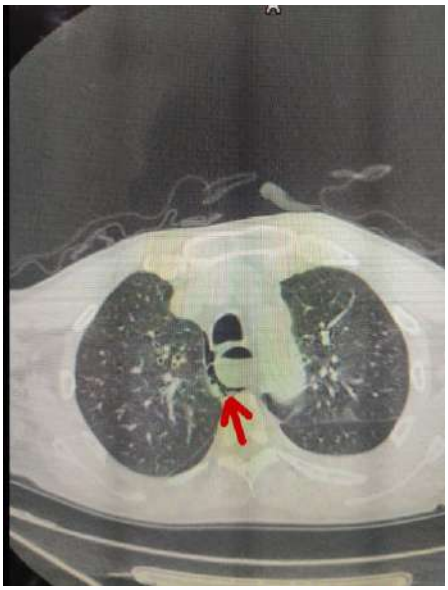

Tomographic section air foci, contamination, and loculations adjacent to the esophagus

Materials and Methods: Esophageal perforations are rare but, due to the increase in invasive procedures in recent years, their incidence has risen. They are associated with high mortality and are a pathological condition that usually comes to mind last when listing differential diagnoses for life-threatening chest pain. Because of the esophagus's close relationship with vital organs, esophageal perforation can quickly lead to mediastinal and pleural inflammation and infection, followed by the development of sepsis, resulting in high morbidity and mortality. Although quite rare, its mortality rate ranges between 10–20%. Delay in diagnosis is directly associated with mortality. Therefore, it should be rapidly diagnosed and a treatment plan should be established in the ED.

Keywords: Boerhaave Syndrome, Emergency Department, Esophagus

Ref No: 2888

Avoiding unnecessary surgery: the diagnostic value of ultrasound in epiploic appendagitis

Nurettin Özkan[1], Demet Acar[1], Mustafa Nurullah Çekiç[1], Ayla Mollaoğlu[1], Mehmet Gül[1]
[1]Emergency Medicine Department, Konya City Hospital, Türkiye
Demet Acar / Emergency Medicine Department, Konya City Hospital, Türkiye

Introduction and Purpose: Epiploic appendages are adipose-rich, vascular structures originating from the serosal surface of the colon, predominantly concentrated around the sigmoid colon and cecum. Patients typically present with sudden-onset, localized abdominal pain. In this case report, a patient presenting with acute abdominal pain who was diagnosed with epiploic appendagitis following radiological evaluation is discussed in light of the current literature, accompanied by clinical and radiological findings.

Materials and Methods: A 27-year-old male patient with no known comorbidities presented to the emergency department due to the persistence of sudden-onset abdominal pain that had started two days prior. The patient had no history of nausea, vomiting, fever, diarrhea, or constipation. On physical examination, his general condition was good; he was conscious, cooperative, and his vital signs were stable. His body temperature was within normal limits. Abdominal examination revealed marked tenderness in the left lower quadrant; no rebound or guarding was observed. Bowel sounds were evaluated as normoactive. Laboratory investigations showed a leukocyte count within normal limits and a slight elevation in C-reactive protein levels. Other biochemical parameters were evaluated as normal. Abdominal ultrasonography (USG) revealed increased echogenicity in the intra-abdominal adipose tissue adjacent to the anteromedial aspect of the descending colon in the left lower quadrant. These findings were evaluated as consistent with epiploic appendagitis. The patient was admitted to the General Surgery department for observation and treatment. Following three days of conservative treatment, his symptoms regressed, and the patient was discharged with a scheduled outpatient follow-up.

Materials and Methods: Epiploic appendagitis is a rare cause of acute abdominal pain. As it most frequently occurs around the sigmoid colon and cecum, it can clinically mimic diverticulitis and acute appendicitis, respectively. Although computed tomography (CT) remains the gold standard for diagnosis, it can also be diagnosed using abdominal ultrasonography (USG). Epiploic appendagitis is generally a benign, self-limiting condition, and its management is primarily conservative. Symptomatic relief is achieved with nonsteroidal anti-inflammatory drugs, and complete clinical resolution is typically observed within 1 to 2 weeks in the majority of cases. Prompt and accurate diagnosis is of critical importance to prevent unnecessary surgical interventions

Keywords: Epiploic appendagitis, acute abdominal pain, emergency department

Ref No: 2892

Aortic Dissection

Halim Taş[1], Ali Gür[1]

[1]Erzurum Atatürk Üniversitesi Araştırma Hastanesi

Halim Taş / Erzurum Atatürk Üniversitesi Araştırma Hastanesi

Introduction and Purpose: Aortic dissection is a life-threatening emergency characterized by a tear in the intimal layer of the aorta, allowing blood to enter the medial layer and create a false lumen, thereby separating the layers of the vessel wall.

Materials and Methods: A 62-year-old male patient with a known history of Hypertension presented to the emergency department. The patient reported non-adherence to his antihypertensive medications for the past two months.The patient presented with abdominal pain that began on the morning of admission. Blood pressure: 200/120 mmHg Oxygen saturation: 95% Heart rate: 80 beats per minute.Physical Examination:Abdomen: soft, non-tender, without rebound tenderness or guarding. Peripheral pulses: right radial pulse weaker compared to the left. Neurological examination: unremarkable.Laboratory Findings:White blood cell count: 18,000 /mm³. Other laboratory parameters: within normal limits.Diagnostic Workup: Electrocardiogram: normal sinus rhythm. Plain radiography: no significant findings. Contrast-enhanced abdominal computed tomography revealed findings consistent with aortic dissectio.The patient was urgently consulted to the cardiovascular surgery department and subsequently admitted to the cardiovascular surgery intensive care unit.

CT



Materials and Methods: In patients with hypertension presenting with abdominal pain, especially when the abdominal examination is benign and symptoms are refractory to treatment, Aortic dissection should always be considered in the differential diagnosis. Physical examination findings may be misleading, and a high index of suspicion is essential for timely diagnosis.

Keywords: Aortic Dissection, Stomachache, Side pain

Ref No: 2905

Should cases of high hyperbilirubinemia be named 'Simpson Syndrome'?

Hatice Simge Acun[1], Murat Seyit[1], Atakan Yılmaz[1], Mert Özen[1], Alten Oskay[1], İbrahim Türkçüer[1]

[1]Pamukkale University Faculty of Medicine

Murat Seyit / Pamukkale University Faculty of Medicine

Introduction and Purpose: Cholangiocarcinoma is a malignant tumor originating from the biliary epithelium and is frequently associated with obstructive jaundice and progressive hepatic dysfunction. In advanced stages, biliary obstruction may lead to cholangitis, renal impairment, metabolic derangements, and multi-organ dysfunction. This case report aims to present a 77-year-old male with a known diagnosis of cholangiocarcinoma who presented with acute cholestatic jaundice, renal failure, and metabolic acidosis, highlighting the importance of multidisciplinary management and timely biliary decompression.

Materials and Methods: A 77-year-old male with a known diagnosis of cholangiocarcinoma presented to the emergency department with abdominal distension, nausea, vomiting, and progressive jaundice of the skin and sclera. On initial evaluation, he appeared icteric and clinically dehydrated. Laboratory investigations revealed elevated inflammatory markers and severe biochemical abnormalities: creatinine 5.46 mg/dL, urea 182 mg/dL, blood urea nitrogen 85 mg/dL, total bilirubin 36.75 mg/dL, direct bilirubin 30.89 mg/dL, LDH 2265 U/L, uric acid 9.3 mg/dL, AST 75 U/L, ALT 45 U/L, GGT 65 U/L, ALP 233 U/L, CRP 44 mg/L, amylase 128 U/L, lipase 189 U/L, and estimated glomerular filtration rate (GFR) 9 mL/min. Complete blood count showed leukocytosis (WBC 14.15 $\times 10^3/\mu L$) and anemia (hemoglobin 10.3 g/dL). Arterial blood gas analysis demonstrated metabolic acidosis with pH 7.20. Coagulation tests revealed prolonged aPTT (42 seconds), PT (17.8 seconds), and INR 1.54. Urinalysis showed dark orange urine with elevated bilirubin (6.3 mg/dL).

Skin color



Skin color



Materials and Methods: In the emergency department, intravenous hydration was initiated, and a urinary catheter was placed for strict intake-output monitoring. The patient was consulted with oncology, gastroenterology, and nephrology departments. Due to severe renal failure and metabolic acidosis, a dialysis catheter was inserted and hemodialysis was initiated. The patient was subsequently admitted to the oncology ward. Preparations were made for percutaneous transhepatic biliary drainage to relieve obstructive jaundice. Considering the characteristic clinical phenotype observed in this patient, we referred to this presentation as “Simpson syndrome” in our clinical practice. This case demonstrates that patients with advanced cholangiocarcinoma may rapidly develop acute renal failure, metabolic acidosis, and coagulopathy secondary to biliary obstruction and systemic inflammation. Early multidisciplinary intervention and timely biliary decompression are essential to improve clinical outcomes and prevent further organ dysfunction.

Keywords: Cholangiocarcinoma, Obstructive jaundice, Acute renal failure

Ref No: 2914

The Silent ECG Trap

Kadir Eryürük[1], Murat Seyit[1], Alten Oskay[1], Atakan Yılmaz[1], Mert Özen[1], İbrahim Türkçüer[1]

[1]Pamukkale University Faculty of Medicine

Murat Seyit / Pamukkale University Faculty of Medicine

Introduction and Purpose: Palpitations and anxiety-related complaints are common presentations in the emergency department and are frequently attributed to psychogenic causes. However, metabolic disturbances—particularly electrolyte abnormalities—may be overlooked under this assumption. Hyperkalemia can progress to life-threatening arrhythmias even in the absence of dramatic electrocardiographic (ECG) findings.

Materials and Methods: A 37-year-old male presented with sudden-onset palpitations, chest tightness, and a subjective sense of impending doom. He reported recent fatigue following an episode of gastroenteritis. His medical history was notable for stage 3 chronic kidney disease and hypertension treated with an angiotensin-converting enzyme (ACE) inhibitor. Physical examination revealed no overt chest pain and normal pulmonary auscultation; however, muscle weakness and paresthesia were observed. While a preliminary diagnosis of panic attack was being considered, continuous cardiac monitoring detected a brief episode of wide-complex tachycardia.Vital Signs: Blood pressure was 146/88 mmHg, heart rate 128 beats/min with intermittently irregular beats, SpO_2 99%, and body temperature 36.5°C.Laboratory Findings:Serum potassium was markedly elevated at 6.8 mmol/L. Sodium was 134 mmol/L. Creatinine was 2.1 mg/dL (increased compared to baseline), and blood urea nitrogen was 74 mg/dL. Venous blood gas analysis revealed metabolic acidosis (pH 7.28, HCO_3^- 16 mmol/L). Troponin levels were negative, and C-reactive protein was low.Electrocardiography: The ECG demonstrated sinus tachycardia without significant ST-segment elevation. T waves were mildly peaked, and PR interval prolongation was suspected. During the monitored episode, QRS widening was documented. The apparently “benign” ECG did not exclude severe hyperkalemia.Management: Immediate membrane stabilization was achieved with intravenous calcium gluconate, followed by insulin with dextrose infusion and nebulized salbutamol to promote intracellular potassium shift. Sodium bicarbonate was administered due to concomitant metabolic acidosis. Given decreased urine output and the risk of refractory hyperkalemia, nephrology consultation was obtained, and hemodialysis preparation was initiated. Following treatment, serum potassium decreased to 5.5 mmol/L, QRS duration normalized, andsymptoms markedly improved.

Materials and Methods: In patients presenting with palpitations and anxiety-like symptoms, the presence of chronic kidney disease, ACE inhibitor/ARB use, metabolic acidosis, or neuromuscular symptoms should prompt immediate evaluation of serum potassium before attributing symptoms to panic disorder. A seemingly normal ECG does not exclude hyperkalemia. The condition may begin silently butcan rapidly progress to fatal arrhythmias.

Keywords: Metabolic acidosis, Hyperkalemia, Arrhythmias

Ref No: 2929

Pulmonary embolism presenting with dizziness and headache: a case report

Gülbanu Emrem[1], Sultan Cennet Çakar[1], Mehmet Soyugüzel[1]

[1]Afyonkarahisar Health Sciences University, Department of Emergency Medicine, Turkey

Gülbanu Emrem / Afyonkarahisar Health Sciences University, Department of Emergency Medicine, Turkey

Introduction and Purpose: Pulmonary embolism (PE) is a common and potentially life-threatening disease within the spectrum of venous thromboembolism. Early diagnosis and prompt treatment are critical in reducing mortality and morbidity. Classical risk factors include major trauma, lower extremity surgery, history of venous thromboembolism, recent hospitalization, oral contraceptive use, postpartum period, malignancy, and thrombophilia. This case aims to emphasize the importance of PE diagnosis in a patient presenting with nonspecific complaints such as dizziness and headache.

Materials and Methods: A 78-year-old male patient presented to the emergency department with sudden onset headache and dizziness. Vital signs on admission were blood pressure 120/80 mmHg, heart rate 82/min, respiratory rate 20/min, temperature 36.4°C, and oxygen saturation 90% on room air. The patient had a history of hypertension and diabetes mellitus.On physical examination, the patient was conscious, oriented, and cooperative. Breath sounds were decreased bilaterally, and bilateral +1 pretibial edema was present. Electrocardiography revealed sinus tachycardia, right bundle branch block, and S1Q3T3 pattern (Figure 1).Laboratory findings were unremarkable. After excluding central causes, due to persistent symptoms, ECG findings, and unexplained hypoxemia, CT pulmonary angiography was performed. Imaging revealed filling defects in the right and left main pulmonary arteries and their lobar branches, consistent with acute pulmonary embolism (Figure 2).The patient was monitored and weight-adjusted anticoagulant therapy was initiated. After consultation with pulmonology, the patient was

hospitalized. The patient was followed with anticoagulant treatment and oxygen support and was discharged in stable condition after four days.

S1Q3T3 pattern on ECG

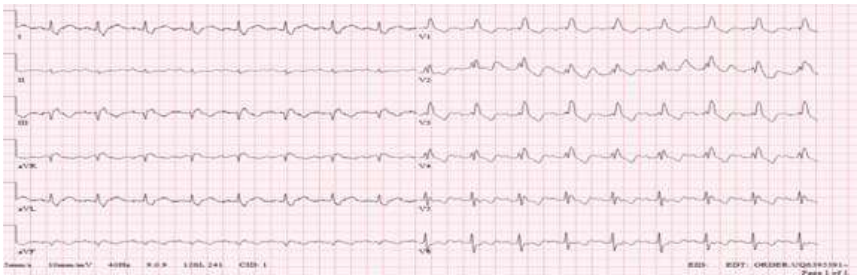

figure: S1Q3T3 pattern on ECG

Embolus in right and left main pulmonary arteries

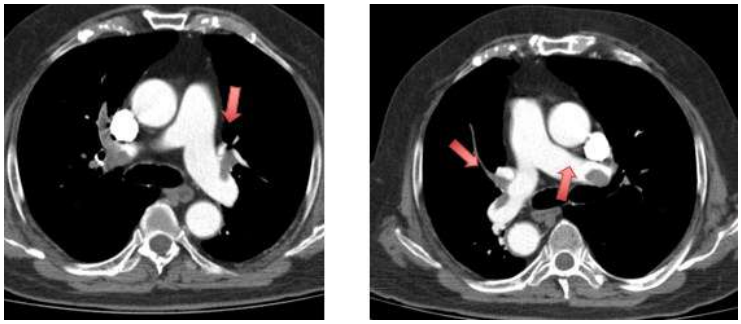

figure 2: Embolus in right and left main pulmonary arteries

Materials and Methods: Pulmonary embolism should be considered in patients presenting with nonspecific symptoms such as sudden onset headache and dizziness. Early diagnosis and prompt initiation of appropriate treatment are crucial for improving patient prognosis.

Keywords: Pulmonary embolism, dizziness, emergency medicine

Ref No: 2970

A two-month latency: chronic subdural hematoma with significant midline shift in an elderly patient

Rıdvan Tuncer[1], Fatih Cemal Tekin[1], Zeynel Emre Bal[1], Demet Acar[1], Mehmet Gül[1]

[1]Emergency Medicine Department, Konya City Hospital, Türkiye

Rıdvan Tuncer / Emergency Medicine Department, Konya City Hospital, Türkiye

Introduction and Purpose: Chronic subdural hematoma (CSDH) is one of the most common neurosurgical conditions, typically observed in elderly patients. Due to the continuous aging of the population, its incidence is expected to progressively increase. Clinically, it can be asymptomatic or present with symptoms ranging from a simple headache to more severe manifestations such as memory impairment, focal neurological deficits, and seizures. The definitive diagnosis of CSDH is established by cranial computed tomography and cranial magnetic resonance imaging.

Materials and Methods: A 66-year-old patient with no known comorbidities and no history of medication use presented to our clinic with a 2-day history of speech impairment, right lower extremity weakness, and numbness. The patient's brain computed tomography revealed a left-sided chronic subdural hematoma measuring up to approximately 4 cm, accompanied by a 14 mm midline shift to the right. Following a neurosurgery consultation, the patient was taken for emergency surgery.

Materials and Methods: Chronic subdural hematoma is a significant and potentially insidious neurological emergency that necessitates a meticulous evaluation of past trauma history, particularly in elderly patients. It must be considered in the differential diagnosis of patients presenting with a focal neurological deficit. Early diagnosis via computed tomography and prompt surgical intervention in appropriate candidates play a critical role in reducing morbidity and mortality.

Keywords: Hematoma, Subdural hematoma, Trauma

Ref No: 2971

Total Occlusion of the Celiac Trunk Presenting with Atypical Abdominal Pain: Diagnostic Challenges and Emergency Management

AHMET DURSUN DEMİR[1], HIZIR UFUK AKDEMİR[1]

[1]Department of Emergency Medicine, Ondokuz Mayıs University Faculty of Medicine, Samsun, Türkiye

AHMET DURSUN DEMİR / Department of Emergency Medicine, Ondokuz Mayıs University Faculty of Medicine, Samsun, Türkiye

Introduction and Purpose: Abdominal pain is one of the most common presentations in the emergency department and encompasses a broad spectrum of etiologies. Acute mesenteric ischemia represents a rare but life-threatening cause, often associated with high morbidity and mortality when diagnosis is delayed. Isolated total occlusion of the celiac trunk is an exceptionally rare vascular condition that may present with nonspecific clinical findings, posing significant diagnostic challenges.

Materials and Methods: A 55-year-old female with no known chronic medical history presented to the emergency department with a three-day history of colicky, non-radiating abdominal pain localized to the midline. She reported normal bowel movements and no associated gastrointestinal symptoms such as nausea or vomiting. On admission, she was hemodynamically stable with normal vital signs, including a blood pressure of 120/80 mmHg, heart rate of 73 bpm, respiratory rate of 18 breaths/min, and body temperature of 36.3°C. Physical examination revealed only mild epigastric tenderness without guarding or rebound tenderness.Laboratory investigations were largely unremarkable except for mild leukocytosis and an elevated serum lactate level (3.31 mmol/L), raising suspicion for underlying ischemia. Bedside clinical findings were otherwise nonspecific, making early diagnosis challenging.Contrast-enhanced abdominal computed tomography revealed a short-segment, ring-shaped occlusion of the proximal celiac trunk approximately 8 mm distal to its origin, with mild post-stenotic dilatation. The splenic artery and other mesenteric vessels remained patent. Based on these findings, a diagnosis of isolated celiac trunk occlusion was established.The patient was evaluated by cardiovascular surgery, general surgery, and interventional radiology teams. As there were no signs of peritonitis, bowel ischemia, or hemodynamic instability, immediate surgical or endovascular intervention was not indicated. Medical management was initiated, and thrombolytic therapy with tissue plasminogen activator (tPA) was planned. The patient was admitted for close monitoring and further management.

Materials and Methods: Isolated celiac trunk occlusion is a rare but clinically significant cause of abdominal pain that may present with subtle and nonspecific findings. Elevated lactate levels in the absence of clear clinical signs should prompt consideration of mesenteric ischemia. Early diagnosis with contrast-enhanced computed tomography and a multidisciplinary approach are essential to guide appropriate management and prevent serious complications.

Keywords: Celiac trunk occlusion, Mesenteric ischemia, Abdominal pain

---

Ref No: 3015

From Hospital to Home: Reducing Emergency Department Overcrowding Through Care Pathway Reconfiguration

Dimitrios Bampalis[3], Olympia Kouliou[4], Anna Patrikakou[1], Maria Agrogianni[2], Varsha Reddy J.[5], Dimitrios Tsiftsis[2]

[1]2nd Regional Health Authority of Piraeus and the Aegean Islands
[2]Emergency Department of General Hospital of Nikaia-Piraeus
[3]Emergency Department of General Hospital of Larissa
[4]Department of Anesthesia, General Hospital of Larissa
[5]Royal Lancaster Infirmary, University Hospitals of Morecambe Bay

Varsha Reddy J. / Royal Lancaster Infirmary, University Hospitals of Morecambe Bay

Introduction and Purpose: Background: Emergency Departments (EDs) in Greece are frequently overcrowded and function as default points of care for patients with advanced, life-limiting illness. This is largely driven by fragmented palliative care services, limited access to structured home-based support, and lack of formal care pathways for end-of-life management. As a result, many patients who could be effectively managed at home continue to present to EDs for symptom control. Integrating palliative care within emergency medicine and strengthening links to home-based services represents a potential system-level solution to reduce avoidable ED utilization.

Materials and Methods: Methods: The Hellenic Emergency Palliative Care Project (HelP CaPe) is a multicomponent model of care implemented in two high-volume Greek EDs. The intervention includes (1) structured training of emergency clinicians in primary palliative care using a culturally adapted curriculum; (2) establishment of ED-based palliative care hubs delivering symptom management, minor procedures, goals-of-care discussions, and family support; and (3) development of formal referral pathways to community and home-based

palliative care services. The model emphasizes care pathway reconfiguration, enabling appropriate triage of palliative patients away from acute ED care toward coordinated, home-centered management when clinically feasible.

Materials and Methods: Results: The model is expected to improve timely symptom control, enhance communication around goals of care, and increase alignment of care with patient preferences. At the system level, it aims to reduce avoidable ED visits and hospital admissions by redirecting patients toward home-based care pathways. Strengthened continuity between EDs and community services is anticipated to support families in managing patients at home, thereby decreasing reliance on emergency services. Additionally, the intervention is expected to improve clinician experience through enhanced skills and reduced burnout associated with high ED workload.Conclusions: Reconfiguring care pathways to integrate palliative care across ED and home settings offers a pragmatic and scalable response to ED overcrowding in Greece. By shifting appropriate patients from hospital-based acute care to supported home management, this model directly addresses a major driver of unnecessary ED utilization. If successful, it could serve as a national framework for reducing ED burden while improving quality of care for patients with serious illness.

Keywords: Hellenic Emergency Palliative Care Project (HelP CaPe), Overcrowding, Care Pathway Reconfiguration

---

Ref No: 3022

Occult Wellens Syndrome In A Cancer Patient Presenting With Hypotension

Ömer Babaoğlu[1], Murat Seyit[1], Alten Oskay[1], Atakan Yılmaz[1], Mert Özen[1], İbrahim Türkçüer[1]

[1]Pamukkale University Faculty of Medicine

Murat Seyit / Pamukkale University Faculty of Medicine

Introduction and Purpose: Wellens syndrome is a high-risk form of acute coronary syndrome characterized by biphasic or deeply inverted T-waves in the precordial leads and is associated with critical stenosis of the proximal left anterior descending artery. These electrocardiographic changes often appear during pain-free periods, making early recognition challenging.In patients with active malignancy, acute coronary syndrome may present atypically, frequently without chest pain. Instead, nonspecific symptoms such as hypotension, dizziness, or syncope may predominate, further complicating diagnosis. This case highlights the importance of routine

electrocardiographic evaluation and heightened clinical suspicion for Wellens syndrome in cancer patients presenting with unexplained hypotension.

Materials and Methods: A 59-year-old woman with metastatic breast cancer receiving chemotherapy (last cycle 20 days prior) presented to the emergency department with recurrent episodes of dizziness, visual darkening, and near-syncope. She denied chest pain and dyspnoea and had no known history of coronary artery disease.On examination, blood pressure was 89/65 mmHg, later decreasing to 80/50 mmHg, with a heart rate of 95 beats/min and temperature of 36.6 °C. Cardiopulmonary examination was unremarkable. Due to persistent hypotension, an electrocardiogram was obtained, revealing deep, symmetric T-wave inversions in leads V2–V5, consistent with a type B Wellens pattern. Initial troponin-T level was elevated at 150 ng/L. Transthoracic echocardiography demonstrated a reduced ejection fraction (35–45%) with apical hypokinesis.Cardiology consultation was obtained, and urgent coronary angiography was recommended. The patient was transferred to a percutaneous coronary intervention–capable center for definitive management.

Electrocardiography

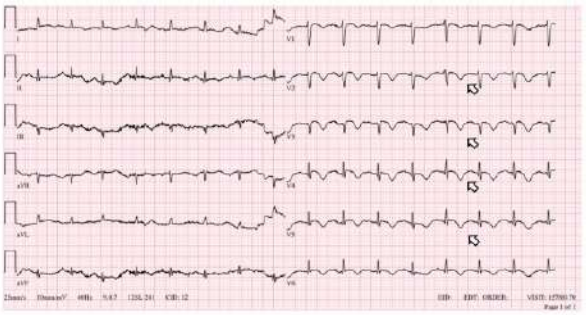

"ECG demonstrating deep, symmetric T-wave inversions in precordial leads (V2–V5), consistent with type B Wellens pattern."

Materials and Methods: This case demonstrates that acute coronary syndrome may present without chest pain, particularly in patients with active malignancy. The Wellens electrocardiographic pattern represents a pre-infarction state, and delayed recognition may result in extensive anterior myocardial infarction.Routine electrocardiographic assessment in patients presenting with unexplained hypotension or syncope, even in the absence of chest pain, is essential. Emergency physicians should maintain a high index of suspicion for Wellens syndrome and promptly involve cardiology services to facilitate early revascularization and improve outcomes.

Keywords: Wellens syndrome, Acute coronary syndrome, Electrocardiography

Ref No: 3033

KounisSyndrome in theEmergencyService

Yunus Hatipoğlu[1], Ferdi Ulusoy[1], Muhammed Ethem Hasanoğlu[1]

[1]1Niğde Ömer Halisdemir Training Andresearchhospital, Department Of Emergencymedicine

Yunus Hatipoğlu / 1Niğde Ömer Halisdemir Training Andresearchhospital, Department Of Emergency Medicine

Introduction and Purpose: When allergic or hypersensitivity and anaphylactic or anaphylactoid insults lead to cardiovascular symptoms and signs, including acute coronary events, the result might be the recently defined nosologic entity known as Kounis syndrome. Vasospastic allergic angina, allergic myocardial infarction, and stent thrombosis with an occluding thrombus infiltrated by eosinophils and/or mast cells are the three reported variants of this syndrome.

Materials and Methods: A 76-year-old female patient developed widespread redness, itching, and shortness of breath after using the painkiller Dolorex to relieve knee pain. She left her house to seek help but subsequently fainted. Her neighbors called an ambulance, and she was brought to our hospital.The patient's blood was drawn, and an ECG was performed. Due to high troponin levels, the patient was referred to the cardiology department with a diagnosis of post-allergy NSTEMI. She was admitted to the hospital with a preliminary diagnosis of Kounis syndrome.

Results and Conclusion: Kounis syndrome is likely an underdiagnosed condition. Awareness of this syndrome will enable optimal management of patients presenting with both acute allergic and/or myocardial events. Additional research, including randomized trials, is needed to better characterize the epidemiology, clinical features, and diagnosis of Kounis syndrome, as well as to define appropriate preventive and interventional strategies.

Keywords: Allergic acute coronary syndrome, Kounis syndrome, allergic myocardial infarction

Ref No: 3096

Posterior Circulation Infarction With Atypical Presentation Complicated By Early Hemorrhagic Transformation

Sarah SABBAGH SHARIF[1], Bahadır TAŞLIDERE[1], Başar CANDER[1]
[1]Bezmialem University Hospital

Sarah SABBAGH SHARIF / Bezmialem University Hospital

Introduction and Purpose: Posterior circulation strokes may present with non-specific symptoms such as isolated visual disturbance or headache, which can lead to delayed recognition in the emergency setting. Hemorrhagic transformation is a known complication of ischemic stroke and may occur early, affecting clinical course and management.

Materials and Methods: A 68-year-old male presented to the emergency department with sudden onset of visual impairment and severe left-sided headache upon awakening. He denied nausea, vomiting, or focal motor weakness. His medical history included hypertension, diabetes mellitus, and coronary artery disease with prior stent placement, and he was on dual antiplatelet therapy. On examination, the patient was alert and oriented (GCS: 15). Neurological evaluation revealed right homonymous hemianopia without motor or sensory deficits. Initial brain computed tomography showed no evidence of hemorrhage. Diffusion-weighted magnetic resonance imaging demonstrated an acute infarction in the left posterior cerebral artery (PCA) territory, extending from the occipitotemporal region to the thalamus. CT angiography revealed approximately 70% stenosis of the left vertebral artery and a thrombus in the left PCA (P2 segment). As the exact time of symptom onset was unknown (wake-up stroke), the patient was not eligible for thrombolytic therapy. Endovascular thrombectomy was not performed due to the distal location of the thrombus (P2 segment) and lack of a clear indication for intervention. During observation in the emergency department, the patient developed worsening headache and changes in mental status. Repeat imaging demonstrated progression of the infarct with hemorrhagic transformation, without midline shift. Neurosurgical evaluation did not indicate the need for surgical intervention, and the patient was admitted to the neurology ward for continued management.

Materials and Methods: This case highlights that posterior circulation stroke may present with isolated visual symptoms in the absence of focal motor deficits, increasing the risk of delayed diagnosis. It also underscores the importance of close monitoring, as hemorrhagic transformation may occur early in the clinical course. Early recognition and timely imaging are essential to optimize outcomes in such patients.

Keywords: Posterior circulation stroke, Hemorrhagic transformation, Visual disturbance

Ref No: 3174

A CASE OF HYDATID CYST

Murat Kurtulmus[1]
[1]Atatürk Üniversitesi
Murat Kurtulmus / Atatürk Üniversitesi

Introduction and Purpose: A CASE OF HYDATID CYSTHydatid cyst is a common parasitic infection in countries where agriculture and livestock farming are practiced. It most frequently occurs in the liver, and secondly in the lungs.we will examine a 26-year-old patient who presented with shortness of breath and cough .

Materials and Methods: CASE:26 years old, male.Occupation: agricultureThere are no chronic illnesses.Vital signs : blood pressure: 130/70 , heart rate : 95, pulse: 105, temperature: 37.5Physical examination: Auscultation of the lungs reveals no significant difference in ventilation. Abdomen is relaxed. No guarding, no rebound tenderness .A cavitary lesion was seen on the patient's chest X-ray , prompting a non-contrast thoracic CT scan . The CT scan revealed two lesions resembling hydatid cysts. One of the lesions was found to be perforated.

bt 1 bt 2

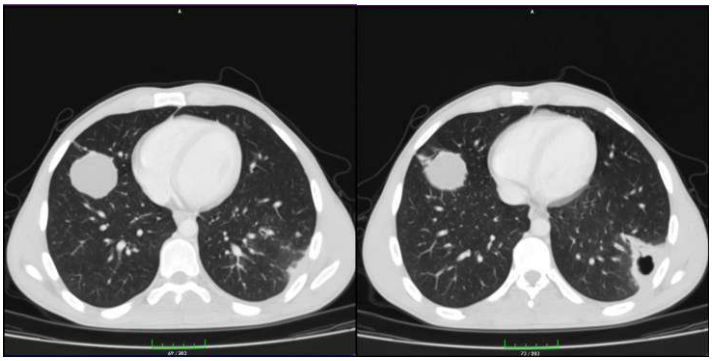

Materials and Methods: CASE:26 years old, male.Occupation: agricultureThere are no chronic illnesses.Vital signs : blood pressure: 130/70 , heart rate : 95, pulse: 105, temperature: 37.5Physical examination: Auscultation of the lungs reveals no significant difference in ventilation. Abdomen is relaxed. No guarding, no rebound tenderness .A cavitary lesion was seen on the patient's chest X-ray , prompting a non-contrast thoracic CT scan . The CT scan revealed two lesions resembling hydatid cysts. One of the lesions was found to be perforated.

Keywords: HYDATID CYST

Ref No: 3179

SEIZURE:ECLAMPSIA OR CENTRAL CAUSE ?

Muhammed Emir Kaplan[1], Ertan Sönmez[1], Murtaza Kaya[1], Harun Yıldırım[1], Ali Halıcı[1], Abdil Coşkun[1]

[1]Department of Emergency Medicine Kutahya Health Sciences University,Kutahya,Turkey

Muhammed Emir Kaplan / Department of Emergency Medicine Kutahya Health Sciences University,Kutahya,Turkey

Introduction and Purpose: Seizure is the manifestation of altered cerebral function caused by excessive and abnormal electrical discharges of brain cells. Recent studies have reported that approximately 55% of patients are male and 45% are female. Women with epilepsy account for 0.3–0.6% of all pregnancies. In this study, we aimed to share the information obtained from our patient who experienced a seizure in the postpartum period.

Materials and Methods: 35-years-old female patient(G1P1A0Y1)on postoperative day 3 following a cesarean section was referred to our hospital after experiencing a "generalized tonic-clonic" type seizure at an external center. During observation, the patient had two additional seizures and was subsequently taken under treatment and monitoring.Medical History: Convulsions (last seizure occurred 6 years ago). Vital Signs: Body temperature 36.8°C,heart rate 110 beats/min, blood pressure 80/40 mmHg. Physical Examination: GCS:12,no active bleeding. Breath sounds decreased. Laboratory Findings: CRP: 156 mg/L, pH: 6.99, Lactate: 11.8 mmol/L; no other acute pathology was detected in the blood.With a preliminary diagnosis of preeclampsia,6 g IV magnesium sulfate was administered as a 30-minute infusion, along with 1500 mg IV Keppra. Based on the recommendation of the Obstetrics and Gynecology department,13 ampoules of magnesium(50 cc/h) and Oksapar 0.4(once daily) were administered. With a preliminary diagnosis of normotensive eclampsia, admission to the intensive care unit was deemed appropriate.The patient was evaluated by neurology in the intensive care unit, where a finding consistent with "left transverse sinus hypoplasia" was diagnosed, and the patient was admitted to the neurology ward. The patient, who did not experience any further seizures during follow-up, was discharged.

Transverse Sinus Hypoplasia



Materials and Methods: It should be remembered that eclampsia can occur up to 7 days postpartum and, in rare cases, even within 2–6 weeks. In postpartum and pregnant patients presenting with convulsive seizures, it should be considered that, in addition to eclampsia, central neurological events may also develop, and central imaging is therefore necessary. References:1.Cirillo PM, Cohn BA: Pregnancy complications and cardiovascular disease death: fiftyyear follow-up of the Child Health and Development Studies Pregnancy Cohort. Circulation 132:1234,2015.[PMID: 26391409]2.Hibbard J, Committee on Practice Bulletins:Chronic hypertension in pregnancy. ObstetGynecol 119:396,2012.[PMID: 11508256]

Transverse Sinus Hypoplasia

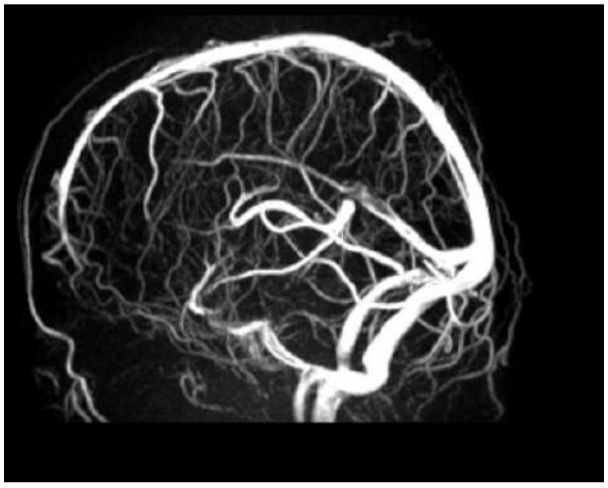

Keywords: Eclampsia, Seizure, Transverse Sinus Hypoplasia

Ref No: 3185

WHO SAID THERE'S NOTHING

Yunus Emre Ek[1], Ayça ÇALBAY[1]

[1]ATATÜRK ÜNİVERSİTESİ

Yunus Emre Ek / ATATÜRK ÜNİVERSİTESİ

Introduction and Purpose: Posterior malleolar fractures are observed in a considerable proportion of patients presenting to the hospital following rotational ankle injuries. The majority of these fractures are associated with trimalleolar fractures. The posterior malleolus is a critical structure for both rotational stability of the ankle and stability of the syndesmotic complex. Therefore, appropriate management of trimalleolar fractures is essential, as inadequate treatment may lead to a poor prognosis.Due to the wide variability in the morphology of posterior malleolar fractures, accurate diagnosis can be challenging. One of the few aspects on which there is consensus in current practice is the crucial role of computed tomography (CT) and three-dimensional CT (3D-CT) in both diagnosis and treatment planning.

Materials and Methods: A 26-year-old male patient presented with a complaint of left ankle injury sustained while descending stairs two days prior. The mechanism of injury involved an inversion of the ankle. Initially, the patient experienced only pain during the first few hours; however, due to progressively increasing swelling, he presented to an external healthcare facility, where immobilization with a splint was applied. Despite this, he continued to have severe pain and therefore presented to our department.On physical examination, there was diffuse edema of the left ankle, marked tenderness, and limited dorsiflexion. Neurovascular examination and other system examinations were unremarkable. Plain radiographs did not reveal any pathology. Subsequently, a non-contrast ankle computed tomography (CT) scan was performed, which demonstrated a non-displaced fracture of the posterior malleolus of the tibia extending into the articular surface.The patient was consulted to the orthopedic clinic, and appropriate management was arranged by the relevant department.

DG



DG



BT



Materials and Methods: In cases of ankle sprains, if physical examination reveals severe tenderness, limitation of movement, swelling, and edema, and if the patient has difficulty bearing weight, advanced imaging such as computed tomography (CT) is important for early diagnosis and appropriate management, even if no pathological findings are observed on plain radiographs.

Keywords: fracture

Ref No: 3270

Hypoglycemia

Halim Taş[1], Ali Gür[1]
[1]Erzurum Atatürk Üniversitesi Araştırma Hastanesi
Halim Taş / Erzurum Atatürk Üniversitesi Araştırma Hastanesi

Introduction and Purpose: In the emergency department, patients presenting with agitation and behavioral changes are often attributed to psychiatric causes; however, underlying metabolic disorders can be overlooked. Hypoglycemia is a critical condition that, if promptly diagnosed and treated, is fully reversible, but delayed recognition may result in severe neurological damage.

Materials and Methods: A 34-year-old male patient was brought to the emergency department by his relatives due to the sudden onset of agitation, restlessness, and nonsensical speech. The patient had no known psychiatric history, chronic illnesses, or regular medication use. Upon presentation, his vital signs were as follows: blood pressure 130/80 mmHg, heart rate 110 bpm, respiratory rate 20/min, and oxygen saturation 98%. On physical examination, the patient was agitated, uncooperative, and disoriented. Neurological examination revealed no focal deficits.During the initial bedside evaluation in the emergency department, capillary blood glucose measurement revealed a level of 42 mg/dL. The patient was promptly administered an intravenous bolus of 80 mL of 30% dextrose. Following intervention, the patient's agitation rapidly subsided, his consciousness improved, and his orientation fully normalized. Subsequent laboratory investigations revealed no additional abnormalities. Further history-taking revealed that the symptoms had developed after a prolonged period of fasting. The patient was discharged with recommendations after the follow-up period was completed.

Materials and Methods: Regardless of etiology, blood glucose measurement should always be included in the initial assessment of patients presenting with agitation in the emergency department. When recognized early, hypoglycemia is a fully treatable condition, whereas delayed diagnosis can lead to serious consequences.

Keywords: Hypoglycemia, Agitation, behavioral changes

Ref No: 3292

Life-Threatening Orolingual Angioedema Following Intravenous Thrombolytic (tPA) Therapy in Acute Ischemic Stroke

ŞAFAK ÇOMURLU[1]
[1]ATATURK UNIVERSITY
ŞAFAK ÇOMURLU / ATATURK UNIVERSITY

Introduction and Purpose: Introduction: The use of recombinant tissue plasminogen activator (rt-PA, alteplase) remains the gold standard in the treatment of acute ischemic stroke. However, life-threatening orolingual angioedema may develop in 1-5% of cases, particularly in patients concurrently using angiotensin-converting enzyme (ACE) inhibitors. This case report discusses a patient who developed asymmetric tongue edema during a tPA infusion, necessitating emergent airway management.

Materials and Methods: Case Presentation: A 70-year-old female patient with a history of hypertension treated with lisinopril presented to the emergency department (ED) with right-sided hemiparesis and aphasia two hours after symptom onset. Following a non-contrast cranial CT that ruled out intracranial hemorrhage, intravenous rt-PA was initiated at a standard dose of 0.9 mg/kg. At the 40th minute of the infusion, the patient developed rapidly progressive massive swelling on the right side of her tongue, accompanied by dysphagia and stridor. The tPA infusion was immediately discontinued. Intravenous methylprednisolone, diphenhydramine, and famotidine were administered. Due to worsening respiratory distress, preparations for an awake fiberoptic intubation were made; however, given the imminent risk of complete glottic closure, a successful single-attempt endotracheal intubation was performed utilizing a video laryngoscope.Discussion: tPA-associated angioedema is typically bradykinin-mediated and, unlike histamine-mediated anaphylaxis, demonstrates a poor clinical response to epinephrine and corticosteroids. Standard emergency medicine references, such as UpToDate and Tintinalli's, recommend the immediate cessation of the tPA infusion and, if necessary, the administration of bradykinin receptor antagonists (e.g., icatibant) or fresh frozen plasma (FFP). Because airway edema can progress at an unpredictable and rapid pace, a "wait-and-see" approach can prove fatal; therefore, early airway intervention, such as awake intubation or prompt preparation for a surgical airway (cricothyrotomy), is imperative in the ED setting.

Materials and Methods: Conclusion: Patients receiving tPA in the stroke unit or emergency department must be rigorously monitored during the initial two hours of treatment—not only for hemorrhagic complications but also for the insidious onset of angioedema. A prior history of ACE inhibitor therapy serves as the most significant red flag for this life-threatening complication.

Keywords: tPA-Associated Angioedema, Acute Ischemic Stroke, Emergency Airway Management

Ref No: 3410

The Effect of the Type and Timing of Medical Treatment on Mortality and Length of Hospital Stay in Traumatic and Non-Traumatic Intracranial Haemorrhages

Onur Bozdağ[1], Elif Betül Balcı[1], Emre Kalkan[1], Bahadır Taşlıdere[1], Başar Cander[1]

[1]Bezmialem Vakıf University

Onur Bozdağ / Bezmialem Vakıf University

Introduction and Purpose: In this study, the effects of the medical treatment initiated in patients diagnosed with intracranial haemorrhage on mortality and hospitalisation will be compared. There are very few studies in the literature investigating the relationship between the timing of initiation of medical treatments (nicardipine, mannitol, dexamethasone, levetiracetam) and mortality and length of hospital stay.Descriptive statistics for the data included the mean, standard deviation, median, minimum and maximum values, and frequency. The distribution of the variables was assessed using the Kolmogorov–Smirnov and Shapiro–Wilk tests. The Mann–Whitney U test was used to analyse non-normally distributed quantitative independent data. For the analysis of categorical data, the chi-square test was used; where the conditions for the chi-square test were not met, the Fischer's exact test was employed. The analyses were conducted using SPSS 28.0.

Materials and Methods: The need for treatment with nicardipine, dexamethasone and mannitol, as well as the mortality rate, were found to be significantly higher in the group with a hospital stay of 4 days or more compared to the group with a hospital stay of 3 days or fewer. There was no significant difference in the need for levetiracetam treatment between the groups with a clinical hospital stay of 3 days or fewer and those with a clinical hospital stay of 4 days or more. (Table 1). In patients with traumatic injuries, whilst there was no significant difference in the use of nicardipine, levetiracetam and dexamethasone between the group of survivors and the group that died, the rate of mannitol use was found to be significantly higher in the group that died. No significant difference in mortality rates was found between the non-traumatic and traumatic groups (Table 2).

Haemorrhage

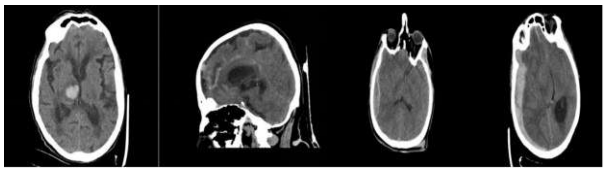

From left to right: Intraparenchymal haemorrhage, Subarachnoid haemorrhage, Epidural haemorrhage, Subdural haemorrhage

The effect of demographic data

		Duration of hospital stay ≤ 3 Days (n:55)			Duration of hospital stay ≥ 4 Days (n:49)			p	
		Ave.±ss/n-%		Median	Ave.±ss/n-%		Median		
Age		60.8 ± 18.1		64.0	61.7 ± 19.4		65.0	0.799	ns
Gender	Female	12	21.8%		20	40.8%		*0.036*	X^2
	Male	43	78.2%		29	59.2%			
CT Scan Time (Minute)		33.2 ± 41.9		16.0	56.9 ± 90.7		25.0	0.081	ns
Diagnosis									
Subarachnoid Haemorrhage		28	50.9%		27	55.1%		0.669	X^2
Intraparenchymal Haemorrh.		6	10.9%		12	24.5%		0.068	X^2
Subdural Haemorrhage		17	30.9%		8	16.3%		0.082	X^2
Epidural Haemorrhage		4	7.3%		2	4.1%		0.486	X^2
Glasgow Coma Scale (GCS)		13.9 ± 3.0		15.0	9.0 ± 4.8		9.0	*0.000*	ns
Treatment									
Use of Nicardipine		13	23.6%		24	49.0%		*0.007*	X^2
Start Time (Minute)		105.5 ± 113.2		48.0	114.0 ± 146.7		47.5	0.924	ns
Use of Levetiracetam		16	29.1%		23	46.9%		0.061	X^2
Start Time (Minute)		157.8 ± 138.4		114.0	122.0 ± 101.2		105.0	0.661	ns
Use of Dexamethasone		3	5.5%		15	30.6%		*0.001*	X^2
Start Time (Minute)		53.7 ± 40.1		31.0	136.6 ± 81.7		107.5	0.101	ns
Use of Mannitol		2	3.6%		8	16.3%		*0.028*	X^2
Start Time (Minute)		96.0 ± 5.7		96.0	136.9 ± 58.5		116.0	0.295	ns
Mortality	Ex	5	9.1%		20	40.8%		*0.000*	X^2
	Alive	50	90.9%		29	59.2%			
Surviving Group		Ort.±ss		Median	Ort.±ss		Median		
Start Time (Minute)									
Nicardipine		118.3 ± 105.9		44.0	185.9 ± 162.0		58.0	0.446	ns
Levetiracetam		143.5 ± 173.2		124.0	118.5 ± 138.7		105.0	0.591	ns
Dexamethasone			31.0	31.0	93.8 ± 142.5		122.5	0.205	ns

The effect of demographic data, the time of CT scan, the type of intracranial haemorrhage, the type of medical treatment administered, and the time of initiation of treatment on the length of hospital stay. (As a subgroup analysis: examining the effect of the time of initiation of medical treatment on the length of hospital stay in the group of survivors only)

Materials and Methods: When the subgroups were examined, the early initiation of medical treatment had no effect on the length of stay in intensive care or on mortality in either the surviving group or the deceased group. Similarly, in both the traumatic and non-traumatic subgroups, the early initiation of treatment had no positive effect on the outcome.

Keywords: Intracranial Haemorrhages, Mortality, Non-Traumatic

Ref No: 3476

From Periorbital Cellulitis to Cervicofacial Necrotizing Cellulitis: A Rapidly Progressive Case Over Four Days

Nevzat HERGÜL[1], Mustafa DEMİR[2], Mehmet Reşit öncü[1]
[1]Van Yüzüncü Yıl University, Faculty of Medicine
[2]Health Sciences University Van Training and Research Hospital
Nevzat HERGÜL / Van Yüzüncü Yıl University, Faculty of Medicine

Introduction and Purpose: Cervicofacial necrotizing infections are rare but potentially life-threatening soft-tissue infections characterized by rapid tissue destruction. Because they may initially present with cellulitis-like findings, early diagnosis can be challenging. The clinical course may be particularly aggressive in patients with underlying comorbidities such as diabetes mellitus. This case aims to highlight the importance of close clinical follow-up in patients initially treated for periorbital/orbital cellulitis who subsequently demonstrate rapid progression.

Materials and Methods: A middle-aged man with a history of diabetes mellitus and hypertension presented with progressively worsening swelling, erythema, and skin discoloration around the right eye. According to the medical history, he had initially been evaluated at an outside center, where orbital cellulitis was suspected and medical treatment was prescribed. However, because his symptoms failed to improve and the lesion progressed rapidly, he presented to our clinic on the fourth day of symptom onset. Physical examination revealed marked edema, erythema, skin discoloration, and necrotic changes extending from the right periorbital region to the infraorbital area and cheek. Imaging studies showed no orbital or paranasal sinus involvement. Microbiological culture from the lesion yielded Staphylococcus aureus. Laboratory findings at admission are presented in Table 1. Serial clinical photographs obtained at 1-day intervals demonstrated the striking progression of the lesion from early periorbital edema and erythema to extensive cutaneous necrosis (Figures 1–4). Based on the clinical, laboratory, microbiological, and imaging findings, the patient was diagnosed with cervicofacial necrotizing cellulitis, and appropriate antimicrobial therapy and surgical management were initiated.

Figure 1



The initial clinical photograph demonstrates marked edema and erythema in the right periorbital region, consistent with the early stage of cellulitis.

Figure 2



The photograph obtained one day later shows a marked increase in right periorbital soft-tissue swelling and progression of the periorbital edema, suggesting rapid advancement of the infection.

Figure 3



The subsequent clinical image reveals skin discoloration, superficial tissue damage, and early necrotic transformation in the right periorbital region.

Figure 4



The final clinical photograph demonstrates extensive black necrotic areas extending from the right periorbital and infraorbital regions toward the cheek, consistent with advanced-stage cervicofacial necrotizing soft-tissue infection.

Table 1

Parameter	Result	Reference Range
Hemoglobin	15.1 g/dL	13–17 g/dL
Hematocrit	45.4 %	40–50 %
White Blood Cell	19.14×10³/µL	4–10 ×10³/µL
Platelet	261 ×10³/µL	150–400 ×10³/µL
Creatinine	1.42 mg/dL	0.6–1.2 mg/dL
C-reactive protein	64.94 mg/L	0–5 mg/L

Laboratory Findings at Admission

Materials and Methods: This case demonstrates that infections initially considered periorbital/orbital cellulitis may rarely progress to cervicofacial necrotizing cellulitis, particularly in patients with diabetes mellitus. The presence of necrosis, rapid spread, and clinical deterioration despite initial treatment should raise suspicion for a necrotizing soft-tissue infection. Close monitoring, early recognition, and timely aggressive treatment are essential to reduce tissue loss and prevent systemic complications.

Keywords: periorbital cellulitis, cervicofacial necrotizing cellulitis, diabetes mellitus

Ref No: 3488

Management of High-Risk Pulmonary Embolism Developing on a Background of Malignancy and Coexisting Acute Kidney Injury: A Case Report

Hakan Ergin[1], Ertan Sönmez[1], Murtaza Kaya[1], Ali Halıcı[1], Harun Yıldırım[1], Abdil Çoşkun[1]

[1]Department of Emergency Medicine, Kütahya Health Sciences University, Kütahya, Türkiye

Hakan Ergin / Department of Emergency Medicine, Kütahya Health Sciences University, Kütahya, Türkiye

Introduction and Purpose: Introduction•Chronic inflammation in malignancy and procoagulant factors released from tumor cells significantly increase the risk of venous thromboembolism (VTE) compared to the healthy population.•In massive Pulmonary Embolism (PE) cases complicated by acute kidney injury (AKI), balancing the risk of contrast-induced nephrotoxicity against life-saving thrombolytic therapy remains one of the most challenging dilemmas in emergency medicine.•We aimed to examine the management of massive PE in the context of terminal gastric cancer and severe AKI, guided by PESI scoring and current literature.

Materials and Methods: Case Presentation•A 67-year-old male with gastric cancer presented with a 2-3 day history of dyspnea, clinical deterioration, and restricted oral intake.•Bedside echocardiography showed signs of right ventricular strain; Doppler USG confirmed DVT in the left femoral and popliteal veins.•Massive PE was confirmed via CT Pulmonary Angiography (CTPA) to establish a definitive diagnosis.

Figure 1. Circumferential difference between lower extremities. Pitting edema



Figure 2. Thrombus in the right main pulmonary artery and segmental arteries.

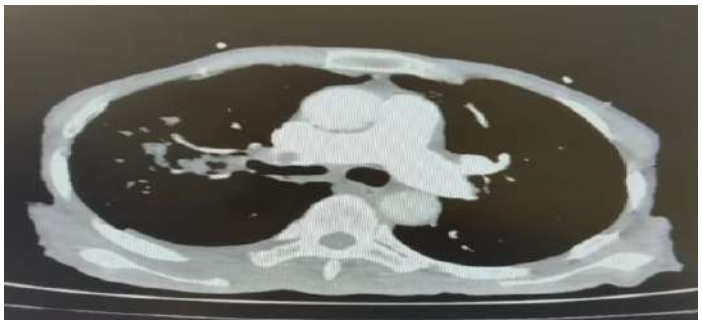

PESI score calculatıon

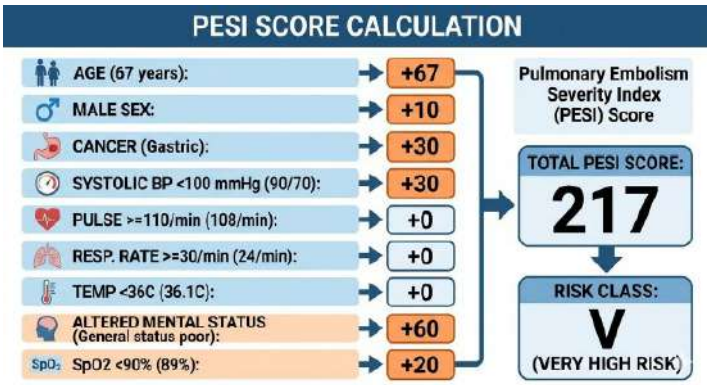

Materials and Methods: Management & Outcome•Despite renal failure, a 100 mg Actilyse (tPA) infusion (which requires no dose adjustment in AKI) was initiated alongside hydration and antihyperkalemic therapy.•The patient underwent emergency hemodialysis; however, during follow-up, his GCS dropped to 3 and he was intubated.•The patient went into cardiac arrest at the 4th hour of admission and was lost despite all resuscitative efforts.

Keywords: Massive Pulmonary Embolism, Acute Kidney Injury, Thrombolytic Therapy

Ref No: 3491

A rare cause of upper gastrointestinal bleeding in a cirrhotic patient: iatrogenic varix perforation

Fatih Karaçam[1], Abdullah Cüneyt Hocagil[1], Ömer Faruk Kurt[1], Hilal Hocagil[1], Ali Rıza Bayar[1], Samed Bulut[1]
[1]Zonguldak Bülent Ecevit University
Abdullah Cüneyt Hocagil / Zonguldak Bülent Ecevit University

Introduction and Purpose: Esophageal variceal bleeding is a critical complication of liver cirrhosis, associated with significant morbidity and mortality rates of 10-20%. Nasogastric (NG) tube placement is a routine clinical procedure for gastric decompression and assessing bleeding severity. However, in cirrhotic patients with coagulopathy and increased mucosal fragility, this invasive intervention may lead to severe iatrogenic complications. We present a rare case of esophageal varix perforation occurring during routine NG tube placement.

Materials and Methods: Case Report: An 81-year-old female with a history of cirrhosis, diabetes, hypertension, and heart failure presented to an external center with confusion and somnolence. Initial evaluation revealed melena, a critical INR of 12, and hemoglobin at 7.2 g/dL. Cranial imaging was normal, and the altered mental status was attributed to hepatic encephalopathy. Following resuscitation with 1 unit of RBCs, 2 units of FFP, and 5 mg of Vitamin K, an NG tube was inserted for decompression. Subsequently, the patient developed profuse hematemesis, requiring intubation for airway protection.Upon transfer to our center, the patient's INR was 1.76 and hemoglobin was 7.6 g/dL. Immediate treatment with proton pump inhibitors, terlipressin, and prophylactic ceftriaxone was initiated. Emergency endoscopy revealed that the NG tube had penetrated directly into the variceal columns, causing extensive submucosal hematomas. Proximal esophageal erosions and diffuse submucosal hemorrhage were observed, alongside Grade I-II distal varices. While no active arterial bleeding was detected, dense clots were noted upon NG tube removal. The patient was admitted to the intensive care unit for further management.

Materials and Methods: Discussion and Conclusion: This case dramatically highlights the risks of NG tube placement in cirrhotic patients with severe coagulopathy. Although guidelines do not consider esophageal varices an absolute contraindication, the procedure increases the risk of mucosal trauma and variceal rupture by 10-15%. While esophageal lacerations are documented, the direct penetration of an NG tube into a variceal column is extraordinary. The patient's initial profound coagulopathy likely rendered the mucosa highly vulnerable. In conclusion, NG tube insertion in cirrhotic patients is a "blind" procedure that demands extreme caution. In high-risk cases with sudden clinical worsening post-insertion, iatrogenic injury must be suspected, and endoscopic assistance should be considered.

Keywords: Esophageal variceal bleeding, Nasogastric tube, iatrogenic complications

---

Ref No: 3537

Acute Intestinal Obstruction In A Patient With Pancreatic Cancer

Oğuz Yılmaz[1], Murat Seyit[1], Atakan Yılmaz[1], Mert Özen[1], Alten Oskay[1], İbrahim Türkçüer[1]

[1]Pamukkale University Faculty of Medicine

Murat Seyit / Pamukkale University Faculty of Medicine

Introduction and Purpose: Acute intestinal obstruction is a common surgical emergency and may occur secondary to malignancy or prior abdominal surgery. Early recognition and prompt surgical intervention are crucial to prevent morbidity and mortality.

Materials and Methods: A 71-year-old female patient presented to the emergency department with nausea and vomiting lasting for two days. Her medical history included pancreatic cancer, hypertension, and prior pancreaticoduodenectomy (Whipple procedure). Physical Examination and Vital Signs: On examination, the abdomen was markedly distended. The patient reported that her last bowel movement had occurred the previous day. Vital signs were stable on admission. Laboratory and Imaging Findings: Abdominal radiography demonstrated multiple broad-based air–fluid levels. Abdominal computed tomography revealed dilated bowel loops consistent with ileus and acute intestinal obstruction. Diagnosis and Management: Based on clinical and radiological findings, the patient was diagnosed with acute intestinal obstruction. The patient was evaluated by the general surgery team and taken to the operating room for surgical intervention.

Materials and Methods: Patients with abdominal malignancy and a history of major abdominal surgery are at increased risk for intestinal obstruction. Timely imaging and early surgical consultation are essential for optimal outcomes.

Keywords: Intestinal Obstruction, Ileus, Pancreatic Cancer

Ref No: 3594

A CASE REPORT: ATYPICAL PRESENTATION OF SINUS VENOUS THROMBOSIS

AKIN AKINCI[1]

[1]NİĞDE EĞİTİM ARAŞTIRMA HASTANESİ

AKIN AKINCI / NİĞDE EĞİTİM ARAŞTIRMA HASTANESİ

Introduction and Purpose: Cerebral venous sinus thrombosis (CVT) is a rare but serious cerebrovascular disease characterized by thrombus formation in the cerebral venous structures, associated with significant morbidity and mortality. Diagnosis can be delayed due to the heterogeneity of findings and the often non-specific nature of symptoms. While CVT most commonly presents with headache, it can also manifest with nausea, vomiting, seizures, focal neurological deficits, altered consciousness, and various other neurological and systemic findings. Risk factors include estrogen-related conditions, acquired and hereditary thrombophilia, and various triggering factors. Contrast-enhanced cranial magnetic resonance imaging (MRI) and MR venography are considered reliable diagnostic methods.

Materials and Methods: A 21-year-old female patient presented to the emergency department with complaints of diarrhea, nausea, weakness, and decreased oral intake that had been ongoing for 4 days. On admission, her vital signs were stable, and systemic examination revealed no significant pathology. Neurological examination showed mild drowsiness, cooperative, and oriented consciousness; however, disorientation developed during clinical observation. The patient had no history of chronic illness or regular medication use. Laboratory tests revealed no major pathology. However, due to her general malaise, weakness, and drowsiness, central nervous system imaging was planned. Following a non-contrast computed tomography scan of the brain, diffusion MRI, cranial MRI, and MR venography were performed, revealing findings consistent with sinus vein thrombosis. Based on these imaging findings, the patient was evaluated by the neurology and neurosurgery departments; surgical intervention was not considered, and admission to the neurology intensive care unit was deemed appropriate. During intensive care monitoring, selective cerebral angiography of four systems revealed no venous flow between the right transverse sinus, inferior sagittal sinus, and sinus rectus. After 4 days in intensive care and 4 days in the ward, the patient was discharged with a plan for anticoagulant therapy.

SVT BT



SVT DIF MR

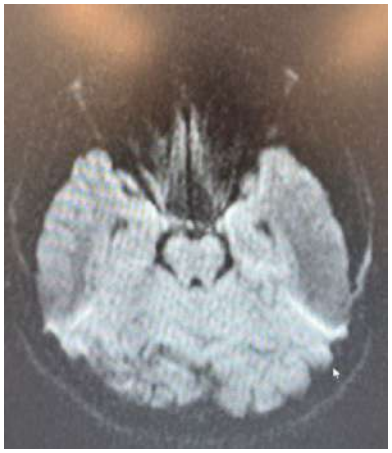

SVT DIF MR

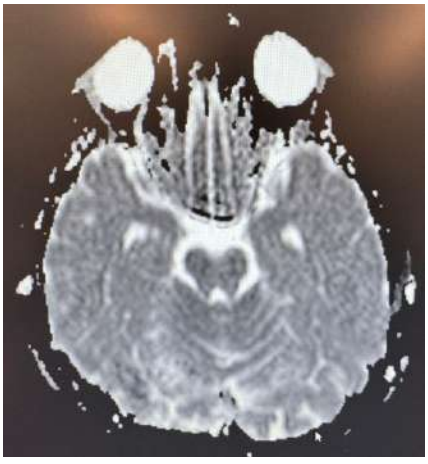

SVT VENOGRAFI



SVT VENOGRAFI

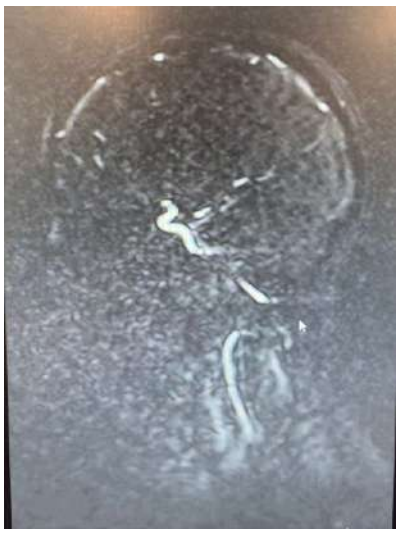

Results and Conclusion: SVT is a clinical condition that can present with non-specific symptoms and can lead to serious consequences if not diagnosed early. Detailed neurological evaluation and appropriate central imaging techniques are critical for diagnosis, especially in patients presenting with general malaise, drowsiness, and altered consciousness.

Keywords: sinus vein thrombosis

Ref No: 3610

Masked Addisonian Crisis in a Young Male Presenting with Recurrent Vomiting and Electrolyte Disturbances

MURTEZA ZAFER[1]

[1]atatürk üniversitesi eğitim ve araştırma hastanesi

MURTEZA ZAFER / atatürk üniversitesi eğitim ve araştırma hastanesi

Introduction and Purpose: IntroductionAddisonian crisis is a rare but life-threatening endocrine emergency. Its presentation is often subtle and can mimic common gastrointestinal conditions. In the emergency department, diagnosis is usually made based on clinical suspicion and rapid laboratory results, without waiting for morning cortisol levels. We present a case of a young male patient initially thought to have simple vomiting, later recognized as adrenal crisis.

Materials and Methods: Case PresentationA 25-year-old male presented to the emergency department with two days of recurrent vomiting and generalized weakness. He also reported progressive fatigue and poor appetite over the past week.Physical examination:•Blood pressure: 88/55 mmHg•Heart rate: 120 bpm•Patient appeared lethargic but orientedLaboratory findings:•Sodium: 128 mmol/L•Potassium: 5.8 mmol/L•Glucose: 52 mg/dL•Creatinine: 1.4 mg/dLInitially, his symptoms were attributed to viral gastroenteritis. However, persistent hypotension, hyponatremia, hyperkalemia, and hypoglycemia raised suspicion for adrenal insufficiency.The patient was promptly treated with intravenous fluids and hydrocortisone. Internal medicine consultation was obtained, and his condition improved rapidly. The diagnosis was supported by the clinical presentation and rapid response to treatment.In the emergency department, Addisonian crisis can easily be masked by gastrointestinal symptoms. Key clinical clues include:•Hypotension disproportionate to dehydration•Hyponatremia and hyperkalemia•HypoglycemiaEarly recognition and immediate steroid replacement are life-saving. Diagnosis can often be confirmed retrospectively based on response to therapy; waiting for morning cortisol is not required in the acute setting.

Materials and Methods: ConclusionAddisonian crisis should be considered in young patients presenting with recurrent vomiting, weakness, and unexplained electrolyte abnormalities. Rapid recognition, early treatment, and internal medicine consultation can significantly reduce mortality.

Keywords: Addisonian Crisis

Ref No: 3634

High-Flow Nasal Oxygen Therapy in Acute Hypoxemic Respiratory Failure: Clinical Outcomes and Indications

burcu yormaz[1]

[1]Selcuk University Medicine Faculty Department of Chest Disease,Konya,Turkıye

burcu yormaz / Selcuk University Medicine Faculty Department of Chest Disease,Konya,Turkıye

Introduction and Purpose: Acute hypoxemic respiratory failure (AHRF) is a common and life-threatening condition in emergency and intensive care settings. High-flow nasal oxygen (HFNO) therapy has gained increasing attention as a non-invasive respiratory support modality. This study aims to evaluate the effectiveness and clinical indications of HFNO in patients with AHRF.

Materials and Methods: A literature-based clinical analysis was conducted focusing on randomized trials and observational studies evaluating HFNO use in AHRF. Outcomes such as intubation rates, ICU length of stay, patient comfort, and mortality were reviewed. Comparisons were made with conventional oxygen therapy and non-invasive ventilation (NIV).

Results and Conclusion: HFNO was associated with improved oxygenation, reduced respiratory effort, and better patient tolerance compared to conventional oxygen therapy. Several studies demonstrated a reduction in intubation rates, particularly in patients with pneumonia and early ARDS. Additionally, HFNO provided better humidification and secretion clearance.In conclusion, HFNO is an effective and well-tolerated respiratory support modality that should be considered early in selected patients with AHRF. Appropriate patient selection remains critical for maximizing its clinical benefit.

Keywords: High-Flow Oxygen; Respiratory Failure; Hypoxemia

Ref No: 3749

AN ANALYSIS OF OXYGEN THERAPY IN PATIENTS WITH EXACERBATED COPD PRESENTING TO THE EMERGENCY DEPARTMENT

Feyzanur AKBULUT[1], Sultan Tuna AKGÖL GÜR[2], Fatih FIRAT[2]

[1]Ataturk Unıversıty Faculty of Pharmacy
[2]Ataturk Unıversity Department of Emergency Medıcıne

Feyzanur AKBULUT / Ataturk Unıversity Faculty of Pharmacy

Introduction and Purpose: Chronic obstructive pulmonary disease (COPD) is a chronic disease characterized by irreversible and progressive airflow limitation resulting from an inflammatory response to exposure to harmful particles and gases, primarily cigarette smoke. Its main symptoms are shortness of breath, coughing, and sputum production, with sputum-producing cough seen in approximately one-third of patients. A post-bronchodilator FEV_1/FVC ratio below 70% is considered indicative of COPD.COPD is a frequent cause of emergency department visits due to acute exacerbations and constitutes a significant public health problem with reduced quality of life, accelerated loss of lung function, increased mortality, and high healthcare costs. Exacerbations are mostly triggered by viral upper respiratory tract and tracheobronchial infections. An exacerbation is an acute clinical condition requiring a change in treatment, characterized by shortness of breath, cough, and an increase in sputum volume or purulence beyond daily variability. This condition may be accompanied by wheezing, fatigue, fever, and changes in sleep and mental status.

Materials and Methods: The initial approach for patients presenting to the emergency department with COPD exacerbation involves assessing the severity of symptoms and previous clinical status. Respiratory rate, oxygen saturation, heart rhythm, and hydration status should be quickly reviewed, and oxygen therapy should be initiated when necessary. Arterial blood gas, laboratory tests, chest X-ray, and sputum examination are indicative of the cause and severity of the exacerbation.Oxygen therapy is fundamental to management, and the target saturation should be 88–92%. This range corrects hypoxemia while reducing the risk of hypercapnia associated with excessive oxygen. High-dose oxygen should be administered with caution as it can lead to CO_2 retention. Non-invasive mechanical ventilation is the first choice in hypercapnic respiratory failure, with invasive ventilation considered if unsuccessful. pCO_2 and pH should be closely monitored during oxygen administration.

Results and Conclusion: Effective management of COPD exacerbations is achieved through a comprehensive approach that includes controlled oxygen therapy, appropriate pharmacological management, and NIMV when necessary. Maintaining saturation between 88% and 92% reduces

mortality and hypercapnia risk. In addition to acute treatment, smoking cessation, vaccination, patient education, and pulmonary rehabilitation play an important role in preventing exacerbations in the long term.

Keywords: COPD, Exacerbation, Oxygen therapy

Ref No: 3760

4th Hour tPA

Duygu Aras Seyit[1], Murat Seyit[2]
[1]ERPA Saglik Hospital, Denizli
[2]Pamukkale University Faculty of Medicine

Murat Seyit / Pamukkale University Faculty of Medicine

Introduction and Purpose: A stroke is a clinical condition caused by vascular factors, characterised by focal or global impairment of cerebral function. Ischemic strokes account for the majority of cases, and in suitable patients, early intervention both reduces the rate of disability and saves lives. Here, we report a case of a young patient presenting with acute ischaemic stroke who made a full recovery following intravenous thrombolytic therapy.

Materials and Methods: A 43-year-old male patient, with no history of chronic illness, presented with sudden-onset numbness, weakness and speech impairment on the right side. No abnormalities were detected in the patient's blood tests; however, an acute infarction was identified on the brain MRI scan. As the onset of symptoms had occurred within the first 4 hours, intravenous thrombolytic therapy was administered with the consent of the patient's relatives. Following treatment, the patient recovered without any sequelae.

MRI

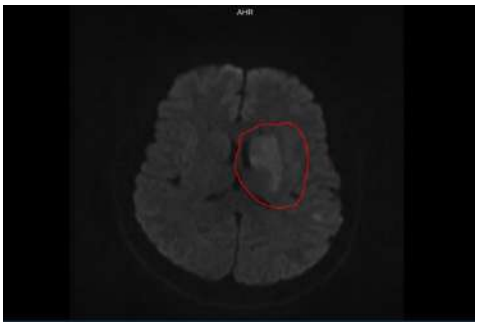

Materials and Methods: Stroke ranks third among the leading causes of death worldwide. Whilst strokes can be either haemorrhagic or ischaemic, the majority of cases are ischaemic strokes. In patients presenting with ischaemic stroke, early intervention reduces the rate of disability and enables patients to recover without sequelae. A study published by the US National Institutes of Health in 1995 demonstrated significant improvement in acute ischaemic stroke cases following systemic thrombolytic therapy using intravenous tissue plasminogen activator (tPA). Whilst the efficacy of the treatment was initially limited to the first 3 hours, it was subsequently extended to 4.5 hours, and in certain specific cases (where the presence of ischaemic penumbra tissue was established) to 9 hours and up to the first 24 hours. Consequently, as in our case, intravenous tPA administered in suitable cases is life-saving.

Keywords: Stroke, tPA

Ref No: 3855

Traumatic Pneumomediastinum

Ekrem Bulut[1], Merve Bulut[1], Ayça Çalbay[1]

[1]Atatürk University Faculty of Medicine

Ekrem Bulut / Atatürk University Faculty of Medicine

Introduction and Purpose: Neck trauma requires a high index of suspicion and a multidisciplinary approach in the emergency department due to the close anatomical relationship of vital vascular, neurologic, and aerodigestive structures. Laryngotracheal injuries caused by blunt or penetrating mechanisms may initially present with stable vital signs but can lead to fatal complications such as airway obstruction or mediastinitis. We present the emergency department management of a 15-year-old boy with pneumomediastinum and extensive subcutaneous emphysema following an atypical trauma mechanism.

Materials and Methods: A 15-year-old boy was brought to the emergency department after sustaining a blow to the neck from a cattle horn. On arrival, he was alert with a Glasgow Coma Scale score of 15; vital signs were within normal limits (BP 115/70 mmHg, HR 88 bpm, RR 18/min, SpO_2 97%). Physical examination revealed diffuse cervical tenderness and palpable crepitus. Computed tomography (CT) of the neck and thorax demonstrated widespread emphysema within the cervical fascial planes, raising suspicion for tracheal injury, and marked pneumomediastinum (figure-1,2). Broad-spectrum antibiotics and tetanus prophylaxis were administered for possible aerodigestive injury. After otolaryngology and thoracic surgery consultations, the patient was admitted to the thoracic surgery service for further evaluation of tracheobronchial integrity and close monitoring.

figure-1



figure-2



Materials and Methods: According to Tintinalli and Rosen's Emergency Medicine, subcutaneous emphysema and pneumomediastinum after neck trauma should be considered highly suggestive of laryngotracheal rupture or esophageal perforation. In pediatric patients, the elasticity of tissue planes allows rapid air dissection from the cervical region into the mediastinum. UpToDate emphasizes that stable vital signs do not exclude significant tracheal injury and that palpable crepitus is a red flag requiring early CT imaging. In high-energy cervical trauma, clinicians should not be reassured by clinical stability; aggressive diagnostic evaluation and multidisciplinary follow-up are warranted when crepitus is present.

Keywords: Subcutaneous Emphysema, Pneumomediastinum, atypical trauma mechanism

Ref No: 3860

Sewing Pin Ingestion Causing An Epiglottic Foreign Body: A Domestic Accident Case

Ömer Babaoğlu[1], Murat Seyit[1], Mert Özen[1], Alten Oskay[1], Atakan Yılmaz[1], İbrahim Türkçüer[1]
[1]Pamukkale University Faculty of Medicine

Murat Seyit / Pamukkale University Faculty of Medicine

Introduction and Purpose: Accidental ingestion of sharp objects is a potentially life-threatening emergency, particularly when the foreign body becomes lodged in the upper airway. Sharp foreign bodies impacted in the oropharynx or epiglottic region pose a significant risk of airway compromise and require prompt recognition and intervention in the emergency department.This case aims to emphasize the importance of early diagnosis, appropriate imaging, and timely specialist involvement in the management of epiglottic foreign bodies, as well as the role of preventive education.

Materials and Methods: A 20-year-old woman presented to the emergency department with acute throat pain, dysphagia, and inability to swallow after accidentally ingesting a sewing pin while sewing at home. On admission, vital signs were stable (blood pressure 124/61 mmHg, pulse 88/min, temperature 36.3 °C).Oropharyngeal examination did not reveal a visible foreign body. Postero-anterior and lateral cervical radiographs demonstrated a 3–4 cm radiopaque linear object located at the level of the epiglottis. An emergency otorhinolaryngology consultation was obtained. The foreign body was successfully removed under direct laryngoscopy with topical anesthesia in the operating room. The patient was subsequently observed in the emergency department for potential airway-related complications.The sewing pin was removed without complications, and the patient experienced rapid resolution of symptoms. No airway compromise or secondary injury was observed during follow-up, and the patient was discharged with appropriate symptomatic treatment and safety instructions.

Lateral X-Ray



Lateral cervical radiograph demonstrating a linear radiopaque foreign body at the level of the epiglottis.

Materials and Methods: This case highlights that sharp epiglottic foreign bodies represent true airway emergencies requiring immediate imaging and multidisciplinary management. Emergency physicians play a key role in early diagnosis, coordination of care, and patient education. Increasing public awareness regarding the avoidance of holding sharp objects in the mouth during domestic activities may help prevent similar incidents.

Keywords: Epiglottic foreign body, Sewing pin ingestion, Airway Emergency

---

Ref No: 3864

Severe Metabolic Acidosis And Bilateral Lentiform Nucleus İnvolvement İn Suspected Methanol İntoxication: A Case Report

Emirhan Ünlü, Kayaalp Sonkaya, Ayla Mollaoğllu, Ayşe Işık, Mehmet Gül

[1]Emergency Medicine Department, Konya City Hospital, Türkiye

Emirhan Ünlü / Emergency Medicine Department, Konya City Hospital, Türkiye

Introduction and Purpose: Methanol intoxication is a life-threatening condition characterized by high anion gap metabolic acidosis, visual toxicity, and central nervous system (CNS) injury due to formate accumulation. Neuroimaging classically demonstrates bilateral basal ganglia, particularly putaminal or lentiform nucleus involvement. In this report, we aim to present a severe case of suspected methanol intoxication presenting with profound metabolic acidosis and typical magnetic resonance imaging (MRI) findings.

Materials and Methods: A 40-year-old male with a history of alcohol and substance use was transferred to the emergency department (ED) intubated for suspected intoxication. On admission, he had profound high anion gap metabolic acidosis (pH 6.94, HCO3 6.2 mmol/L) with negative serum ethanol. Diffusion MRI revealed symmetric diffusion restriction in the bilateral lentiform nuclei. Based on clinical, laboratory, and radiological findings, severe methanol intoxication was strongly suspected. The patient received comprehensive antidotal therapy, including enteral ethanol, folate and vitamin supplementation, and intravenous bicarbonate therapy.

Materials and Methods: Results and Conclusion:Following the initial interventions, the patient underwent urgent hemodialysis to remove toxic metabolites. He responded well to the treatment, was successfully extubated on day 3, and transferred to the ward after 9 days of intensive care unit (ICU) follow-up. Because direct serum methanol measurements are frequently unavailable

or delayed, clinicians must rely on surrogate markers such as high anion gap metabolic acidosis and compatible neuroimaging. This case highlights the diagnostic value of combining severe acidosis with characteristic basal ganglia involvement on MRI, underscoring the importance of early hemodialysis in suspected cases.

Keywords: Methanol intoxication, metabolic acidosis, basal ganglia

---

Ref No: 3890

Mallory-Weiss syndrome

Batuhan Özbek[1], Ayça Çalbay[1], Halim Taş[1]
[1]Atatürk University Research Hospital
Batuhan Özbek / Atatürk University Research Hospital

Introduction and Purpose: Mallory-Weiss syndrome is a condition characterized by longitudinal mucosal lacerations at the gastroesophageal junction, typically caused by forceful vomiting or retching. It can lead to upper gastrointestinal bleeding, presenting with hematemesis and, less commonly, melena. Although often self-limited, severe cases may require endoscopic intervention.

Materials and Methods: A 45-year-old male patient with no known chronic illnesses presented to the emergency department with complaints of repeated vomiting followed by the sudden onset of hematemesis over the past 6 hours. The patient reported a history of heavy alcohol intake the night before admission. On initial evaluation, his vital signs revealed mild tachycardia, while blood pressure was within normal limits. Physical examination showed mild epigastric tenderness without guarding or rebound. Laboratory investigations demonstrated a slight decrease in hemoglobin levels compared to baseline. The patient continued to have episodes of hematemesis during observation. An urgent upper gastrointestinal endoscopy was performed, revealing a linear mucosal tear at the gastroesophageal junction consistent with Mallory-Weiss syndrome, with signs of active bleeding. Endoscopic hemostasis was successfully achieved using epinephrine injection and hemoclipping. The patient was admitted for monitoring, intravenous fluid replacement, and proton pump inhibitor therapy. Over the following 48 hours, his symptoms resolved, and no further bleeding episodes were observed.

Materials and Methods: Mallory-Weiss syndrome should be considered in patients presenting with hematemesis following repeated vomiting, especially in the context of alcohol use. Early endoscopic evaluation is essential for both diagnosis and treatment, and most patients respond well to minimally invasive interventions when managed promptly.

Keywords: vomitting, melena

Ref No: 3895

Unstable Pelvic Fracture with Morel-Lavallée Lesion Following a High-Energy Crush Injury

Egenur Yılmaz[1], Murat Seyit[1], Mert Özen[1], Alten Oskay[1], Atakan Yılmaz[1], İbrahim Türkçüer[1]

[1]Pamukkale University Faculty of Medicine

Murat Seyit / Pamukkale University Faculty of Medicine

Introduction and Purpose: Unstable pelvic fractures are life-threatening injuries typically caused by high-energy trauma and are associated with significant hemorrhage and soft tissue damage. Disruption of the pelvic ring may lead to hemodynamic instability and increased mortality. The Morel-Lavallée lesion is a closed degloving injury resulting from separation of the skin and subcutaneous tissue from the underlying fascia after trauma. We aimed to present the early management of an unstable pelvic fracture accompanied by a Morel-Lavallée lesion following a crush injury.

Materials and Methods: A 37-year-old male was brought to the emergency department after his pelvis was compressed by a forklift. Vital signs were stable. He complained of pelvic and bilateral leg pain and numbness in the right leg. Neurological and respiratory examinations were normal. Pelvic examination revealed tenderness and positive open-book instability. Subcutaneous edema and hematoma were present over the right femur and tibia. A closed degloving injury consistent with a Morel-Lavallée lesion was observed on the right thigh. The patient was monitored, two large-bore intravenous lines were established, and a Foley catheter was inserted. Blood samples were obtained and cross-matched packed red blood cells were prepared due to the risk of massive hemorrhage. Blood transfusion and intravenous fluid resuscitation were initiated in the emergency department. A jugular central venous catheter was placed for hemodynamic monitoring and continued resuscitation. A pelvic binder was applied for temporary stabilization.CT angiography demonstrated left sacroiliac joint widening (1.5 cm), pubic symphysis diastasis (2 cm), and a comminuted displaced fracture of the left proximal femoral shaft. Major lower extremity arteries were patent.The patient subsequently underwent emergency orthopedic surgery.

Morel-Lavallée lesion



Materials and Methods: Early stabilization, aggressive resuscitation, and prompt recognition of associated soft tissue injuries are critical in high-energy pelvic trauma. Early diagnosis of Morel-Lavallée lesions helps prevent complications such as infection and soft tissue necrosis.

Keywords: Unstable pelvic fracture, Morel-Lavallée lesion, Crush injury

---

Ref No: 3920

Traumatic Intraventricular Hemorrhage: A Case Report of Severe Traumatic Brain Injury

Salih Necati İlhan[1], Murat Seyit[1], Mert Özen[1], Alten Oskay[1], Atakan Yılmaz[1], İbrahim Türkçüer[1]

[1]Pamukkale University Faculty of Medicine

Murat Seyit / Pamukkale University Faculty of Medicine

Introduction and Purpose: Traumatic brain injury (TBI) is a leading cause of mortality and long-term neurological sequelae among patients presenting to emergency departments. Intracranial hemorrhages with intraventricular extension are particularly associated with elevated intracranial pressure, hydrocephalus, and poor prognosis. This case report aims to emphasize the

importance of early resuscitation, prompt airway management, and timely surgical intervention in traumatic intraventricular hemorrhage following severe head trauma.

Materials and Methods: A 34-year-old male was admitted to the emergency department after a fall from height. On arrival, his general condition was poor; blood pressure was 85/50 mmHg, heart rate 124 beats/min, respiratory rate 8 breaths/min, and oxygen saturation (SpO_2) 82%. The Glasgow Coma Scale (GCS) score was 6 (E1M4V1). Pupils were isochoric with diminished light reflexes. A 3×4 cm scalp hematoma was noted on physical examination. Due to low GCS and inadequate respiratory effort, the patient was rapidly intubated and placed on mechanical ventilation. Hemodynamic stabilization was achieved with intravenous fluid resuscitation and vasopressor support. Laboratory investigations revealed hemoglobin 11.2 g/dL, leukocyte count 14,800/mm^3, INR 1.1, and metabolic acidosis on arterial blood gas analysis. Brain computed tomography demonstrated intracranial hemorrhage extending into the ventricular system along with diffuse cerebral contusions.

Materials and Methods: The patient was immediately evaluated by the neurosurgery team and taken for emergency surgery. Traumatic intraventricular hemorrhage is a life-threatening condition that may lead to rapid neurological deterioration. Early airway control, aggressive resuscitation, and timely neuroimaging play a critical role in reducing mortality. A coordinated multidisciplinary approach remains essential in improving outcomes in severe TBI.

Keywords: Traumatic brain injury, intraventricular hemorrhage

---

Ref No: 3955

An unusual presentation of colonoscopy-related perforation: retroperitoneal air with pneumomediastinum and facial subcutaneous emphysema

Nevzat HERGÜL[1], MEHMET REŞİT ÖNCÜ[1], MUSTAFA BOLAT[1]

[1]Van Yüzüncü Yıl University Faculty of Medicine

Nevzat HERGÜL / Van Yüzüncü Yıl University Faculty of Medicine

Introduction and Purpose: Colonoscopy is widely used for colorectal cancer screening and diagnostic evaluation. Although considered a relatively safe procedure, bowel perforation remains a rare but serious complication. We present the case of a 68-year-old woman who developed extensive retroperitoneal air associated with subcutaneous emphysema and pneumomediastinum following an elective colonoscopy.

Materials and Methods: A 68-year-old woman underwent elective colonoscopy in the morning as part of a routine colorectal cancer screening program. Several hours after the procedure, she presented to the emergency department with complaints of shortness of breath accompanied by swelling of the face and eyelids.On arrival, the patient's vital signs were stable. Physical examination revealed marked facial and periorbital swelling. Palpation of the cervical region demonstrated subcutaneous crepitus extending toward the upper thoracic area.Initial laboratory evaluation showed leukocytosis and mildly elevated inflammatory markers. Electrolyte abnormalities including hyponatremia and hypokalemia were also noted. Detailed laboratory findings are presented in Table 1.Computed tomography of the chest and abdomen demonstrated extensive air distribution in multiple anatomical compartments. Widespread subcutaneous emphysema was observed involving the facial, cervical, and thoracic soft tissues (Figure 1). Air was also detected within the mediastinum, consistent with pneumomediastinum (Figure 2). Additionally, large amounts of air were identified in the retroperitoneal space, raising suspicion for colonoscopy-related colonic perforation (Figure 3).Based on these radiological findings and the clinical suspicion of bowel injury, the patient underwent emergency surgical intervention. Following the operation, she was admitted to the general surgery intensive care unit for postoperative monitoring.

Figure 1.



Computed tomography demonstrating extensive subcutaneous emphysema involving the facial and cervical soft tissues.

Figure 2.



Thoracic computed tomography showing pneumomediastinum.

Figure 3.



Abdominal computed tomography demonstrating extensive retroperitoneal air compatible with colon perforation.

Table 1.

Parameter	Result	Reference Range
WBC	19.3 ×10³/µL	3.9–10.9
Hemoglobin	13.3 g/dL	13–16.9
Platelets	232 ×10³/µL	150–450
CRP	9.6 mg/L	0–5
Sodium	124 mmol/L	136–145
Potassium	3.1 mmol/L	3.1 mmol/L
Creatinine	0.71 mg/dL	0.57–1.11

Laboratory findings on admission

Materials and Methods: Perforation is an uncommon but potentially life-threatening complication of colonoscopy, with reported incidence rates ranging between 0.03% and 0.8%. Retroperitoneal perforations may allow air to track along fascial planes and spread into distant anatomical regions, including the mediastinum and subcutaneous tissues.As a result, patients may present with atypical manifestations such as facial swelling, cervical crepitus, or dyspnea rather than typical abdominal symptoms. Computed tomography plays a crucial role in detecting the presence and distribution of extraluminal air and guiding further management. Early diagnosis is essential to ensure timely surgical treatment and to reduce morbidity.

Keywords: Colonoscopy perforation, Retroperitoneal air, Pneumomediastinum

Ref No: 3958

Ruptured hydatid cyst presenting with atypical clinical findings

Gülbanu Emrem[1], Sultan Cennet Çakar[1], Ayşe Ertekin[1]

[1]Afyonkarahisar Health Sciences University, Department of Emergency Medicine, Afyonkarahisar, Türkiye

Gülbanu Emrem / Afyonkarahisar Health Sciences University, Department of Emergency Medicine, Afyonkarahisar, Türkiye

Introduction and Purpose: Hydatid cyst is a parasitic disease caused by Echinococcus granulosus, most commonly involving the liver and lungs. Rupture of the cyst is a life-threatening condition that may lead to anaphylaxis, peritonitis, and severe systemic complications. This study aims to present a case of ruptured hydatid cyst with atypical clinical findings and to emphasize the importance of early diagnosis.

Materials and Methods: A 75-year-old female patient presented to the emergency department with progressive deterioration in general condition over several days. Vital signs on admission were blood pressure 100/60 mmHg, heart rate 110/min, respiratory rate 22/min, and body temperature 36.4°C.Her medical history included permanent pacemaker due to atrioventricular block, severe valvular heart disease, hypothyroidism, arrhythmia, and chronic kidney disease. The patient was confused with a Glasgow Coma Scale score of 14.Physical examination revealed diffuse abdominal tenderness, guarding and rebound in the right upper and lower quadrants, decreased bilateral breath sounds, and anuria. Laboratory findings showed a significant increase in renal function tests. Imaging revealed multiple cystic lesions in the liver, free fluid in the pelvis, cystic lesions in the lungs, and pleural effusion (Figure 1) (Figure 2).

Axial CT image reveals liver cyst

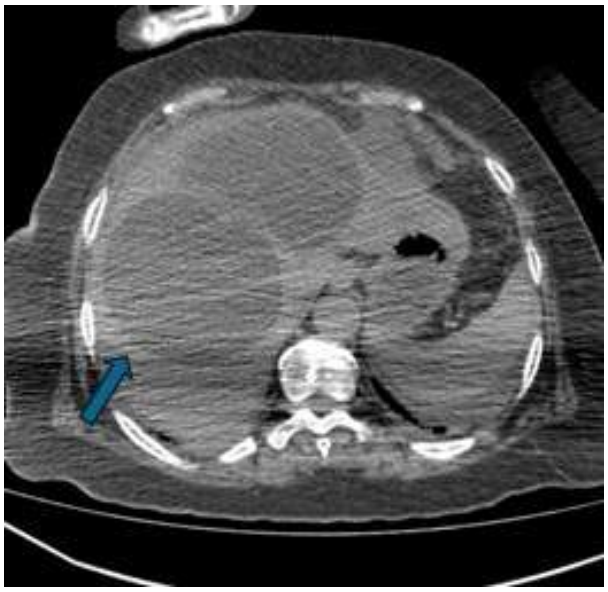

figure 1: Axial CT image reveals liver cyst (arrow)

Coronal CT image reveals cystic lung lesion

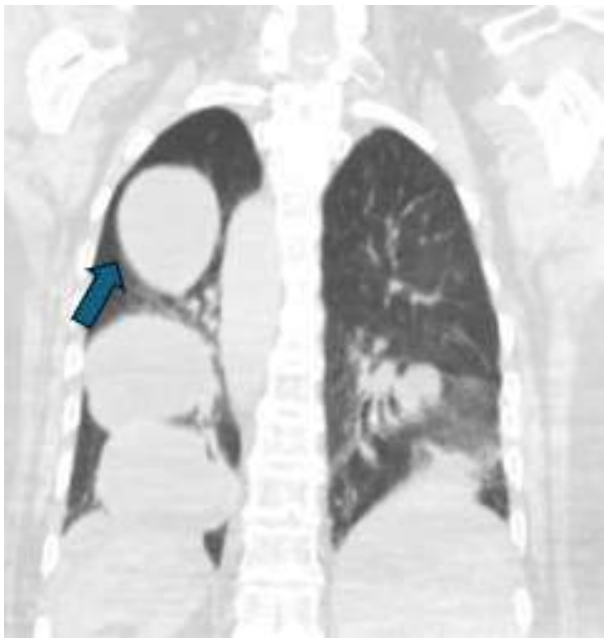

figure 2: Coronal CT image reveals cystic lung lesion (arrow)

Materials and Methods: The patient was evaluated in a multidisciplinary manner and admitted to the intensive care unit following emergency hemodialysis. During surgical intervention, cyst contents were aspirated and the germinative membrane was removed. However, metabolic instability developed during intensive care follow-up, and the patient died on the third day due to cardiac arrest.Ruptured hydatid cyst should be considered in elderly patients presenting with nonspecific symptoms, especially in endemic regions. Early diagnosis and multidisciplinary management are essential; however, advanced age and comorbidities significantly increase mortality.

Keywords: Hydatid cyst, acute abdomen, Echinococcus granulosus

---

Ref No: 3963

Diagnosis Behind Non-Specific Symptoms In The Emergency Department: Digoxin Toxicity

Sabri Furkan Bulca[1], Murat Seyit[1], Atakan Yılmaz[1], Mert Özen[1], Alten Oskay[1], İbrahim Türkçüer[1]

[1]Pamukkale University Faculty of Medicine

Murat Seyit / Pamukkale University Faculty of Medicine

Introduction and Purpose: Digoxin has a narrow therapeutic index and therefore carries a significant risk of toxicity, particularly in elderly patients with comorbidities. In polypharmacy patients presenting to the emergency department with non-specific symptoms such as chest pain or epigastric pain, it should be kept in mind that these complaints may be related to adverse drug effects or toxicity. The aim of this case report is to emphasize that digoxin toxicity should be considered in the differential diagnosis of non-specific presentations in elderly patients with comorbidities.

Materials and Methods: A 70-year-old woman presented to the emergency department with chest pain and epigastric pain that started on the same day. On admission, her vital signs were: blood pressure 137/63 mmHg, temperature 36.8°C, SpO_2 93%, and heart rate 84 bpm. Her medical history was significant for hypertension and atrial fibrillation (AF). Her regular medications included Isoptin (verapamil), Warfmadin, digoxin, and Sulinex; she also had a history of heart valve replacement. On physical examination, she was alert and oriented; neurological examination was normal; breath sounds were bilaterally normal; the abdomen was soft without guarding or rebound; costovertebral angle tenderness was negative; and rectal

examination was normal. Electrocardiography revealed AF with a slow ventricular response. Laboratory tests obtained due to suspicion of digoxin toxicity showed: creatinine 1.05 mg/dL, CRP 10.06 mg/L, pH 7.39, INR 3.9, hemoglobin 13.7 g/dL, troponin T 33.1 ng/L at 0 hour and 36.9 ng/L at 1 hour, and a digoxin level of 4.48 µg/L (upper limit 1.2 µg/L). The patient was diagnosed with digoxin toxicity and was admitted to the cardiology department.

Materials and Methods: This case demonstrates that, in elderly patients with comorbidities presenting to the emergency department with non-specific symptoms, early consideration of drug toxicities—especially digoxin—together with ECG findings and medication history can reduce diagnostic delay. In the presence of polypharmacy, symptoms may be “atypical”; therefore, when clinical suspicion exists, digoxin levels and accompanying risk markers (e.g., renal function, electrolytes, and interacting medications) should be evaluated promptly.

Keywords: Digoxin toxicity, arrhythmia, atrial fibrillation.

Ref No: 3977

Mechanical Adverse Event During Endotracheal Intubation: Stylet Fracture

Fırat Okta[1], Murat Seyit[1], Atakan Yılmaz[1], Mert Özen[1], Alten Oskay[1], İbrahim Türkçüer[1]

[1]Pamukkale University Faculty of Medicine

Murat Seyit / Pamukkale University Faculty of Medicine

Introduction and Purpose: Securing airway patency has a critical role in the management of critically ill patients. In emergency departments, airway security is achieved through endotracheal intubation. Adverse events occurring during ETI are generally addressed as adverse events. However, device-related mechanical complications may also occur. Examples include pharyngeal bleeding, bronchial rupture, hemopneumothorax, and intratracheal or pulmonary migration of fractured fragments of the stylet used during ETI.

Materials and Methods: This poster presentation aimed to draw attention to device-related mechanical events that may occur during ETI.In a patient undergoing ETI, a 7.5 mm endotracheal tube and a stylet (TUORen, China) were used. Resistance was encountered while removing the stylet from the ETT. It was noted that the removed stylet was shorter than expected. At that time, both lungs were ventilated and oxygen saturation was 100%.It was suspected that the stylet had fractured and remained insidethe tube. Without changing the patient’s position, replacement of the ETT was decided. Upon removal of the existing ETT, the

distal fragment of the stylet was observed within the tube.ETI was re-established with a new ETT, and the patient was admitted to the intensive care unit.The stylet is a widely used instrument that facilitates successful intubation. In a cohort study including 197 centers across 29 countries, the use of a stylet as an intubation adjunct was reported at 77.4%. During repeated use, the stylet may fracture within the ETT. Indeed, cases involving intratracheal or pulmonary migration of detached metal or plastic coating materials of the stylet have been reported in the literature. In the reported cases, it is considered that repeated shaping before each use created a structural weak pointon thestylet, and that the angle formed during shaping generated resistance during withdrawal, leading to fracture at the weakened site. We believethat the fracture in ourcase occurred through a similar mechanism. Inpreviously reported cases, stylet fracture was identified on imaging performed after the development of respiratory pathology. In our case, it was recognized due to the shortened proximal stylet fragment.

Stylet



Materials and Methods: To prevent such events, routine inspection of the stylet before and after intubation should be standard practice for emergency physicians.

Keywords: Endotracheal intubation, Endotracheal tube, Stylet

Ref No: 4006

Delayed Neuropsychiatric Syndrome (DNS) in Carbon Monoxide (CO) Poisoning Presenting with Atypical Neurological Symptoms

MUHAMMED EMİN AKGÜN[1], ZEYNEP ÇAKIR[1]

[1]ATATURK UNIVERSTY

MUHAMMED EMİN AKGÜN / ATATURK UNIVERSTY

Introduction and Purpose: Carbon monoxide (CO) poisoning is a frequently encountered and potentially fatal condition in emergency departments during the winter months. Following recovery from acute intoxication, a subset of patients may develop Delayed Neuropsychiatric Syndrome (DNS) days or weeks later, characterized by cognitive impairment, parkinsonism, and aphasia. This report examines a case of CO poisoning in which the patient was initially discharged but presented with a clinical picture of DNS three weeks later.

Materials and Methods: A 45-year-old male patient was treated in the emergency department for CO poisoning caused by a gas leak from a stove, along with his family. After his carboxyhemoglobin (COHb) levels were reduced using normobaric oxygen therapy, he was discharged without any neurological deficits. Twenty days post-incident, the patient was brought back to the emergency department presenting with gait disturbances, masked facies, urinary incontinence, and memory loss. A cranial MRI revealed hyperintense lesions in the bilateral globus pallidus and white matter. The patient was diagnosed with Delayed Neuropsychiatric Syndrome secondary to CO intoxication, and Hyperbaric Oxygen (HBO) therapy was planned.The pathophysiology of DNS is driven less by hypoxia and more by lipid peroxidation and inflammatory cascades targeting brain myelin sheaths (specifically, lymphocyte-mediated destruction of myelin basic protein). According to Tintinalli's Emergency Medicine, patients with a history of syncope, seizures, or cardiac ischemia during the acute phase are at a very high risk for DNS and should be referred for early HBO therapy. Unfortunately, the initial COHb level is an inadequate predictor of DNS development.

Materials and Methods: When arranging an emergency department discharge plan for CO poisoning cases, the patient and their relatives must be explicitly warned about the cognitive and neurological changes (DNS) that may emerge several weeks later, and indications for HBO therapy should be aggressively evaluated in high-risk patients.

Keywords: Hyperbaric Oxygen, Carbon monoxide, Delayed Neuropsychiatric Syndrome

Ref No: 4052

Idiopathic Intracranial Hypertension Presenting with Progressive Visual Disturbance in a Young Woman in the Emergency Department: A Case Report

AHMET DURSUN DEMİR[1], HIZIR UFUK AKDEMİR[1]
[1]Department of Emergency Medicine, Ondokuz Mayıs University Faculty of Medicine, Samsun, Türkiye
AHMET DURSUN DEMİR / Department of Emergency Medicine, Ondokuz Mayıs University Faculty of Medicine, Samsun, Türkiye

Introduction and Purpose: Idiopathic intracranial hypertension (IIH) is a syndrome characterized by elevated intracranial pressure in the absence of an identifiable structural lesion or cerebral venous sinus thrombosis. It predominantly affects young women and may present with headache, papilledema, and visual disturbances

Materials and Methods: A 22-year-old female presented to the emergency department with a one-month history of persistent bilateral frontal headache and progressively worsening visual blurring over the preceding two weeks. She had no history of chronic illness, medication use, or trauma. Her body mass index was 22.3 kg/m². The patient had been referred from an ophthalmology clinic where papilledema had been detected during prior evaluation.On admission, vital signs were within normal limits. Neurological examination revealed an alert and oriented patient with no focal deficits. Pupillary responses were normal. Fundoscopic examination demonstrated bilateral grade 4 papilledema, while visual acuity was preserved at 8/10 bilaterally. Visual field testing revealed enlargement of the blind spot and peripheral constriction in the superior quadrants.Magnetic resonance imaging demonstrated increased tortuosity of the optic nerves and a partially empty sella. Magnetic resonance venography excluded cerebral venous sinus thrombosis, although hypoplasia of the right transverse and sigmoid sinuses was noted. Lumbar puncture revealed an elevated opening pressure of 40 cmH_2O, with normal cerebrospinal fluid composition.Based on clinical, radiological, and cerebrospinal fluid findings, a diagnosis of idiopathic intracranial hypertension was established. The patient was admitted for medical management and treated with acetazolamide, along with supportive therapy. During follow-up, her symptoms improved significantly, with gradual resolution of papilledema. At the nine-month follow-up, complete clinical and ophthalmological recovery was achieved.

Materials and Methods: Idiopathic intracranial hypertension should be considered in young patients presenting with headache and visual disturbances, particularly in the presence of papilledema. Careful fundoscopic examination, appropriate neuroimaging, and timely lumbar puncture are essential for diagnosis. Early initiation of medical therapy is crucial to prevent permanent visual impairment.

Keywords: Idiopathic intracranial hypertension, Papilledema, Visual disturbance

Ref No: 4091

Iatrogenic Rectovesical Fistula: A Rare Complication After Transurethral Prostate Resection

Ozan Doğan Sırtkaya[1], Sema Nur Saka[2], İsmail Ataş[1], Mehmet Altuntaş[1]

[1]Recep Tayyip Erdoğan University Training and Research Hospital, Department of Emergency Medicine, Rize, Türkiye
[2]Recep Tayyip Erdoğan University Faculty of Medicine, Rize, Türkiye

Ozan Doğan Sırtkaya / Recep Tayyip Erdoğan University Training and Research Hospital, Department of Emergency Medicine, Rize, Türkiye

Introduction and Purpose: Rectovesical fistulas are rare but serious clinical conditions characterized by an abnormal connection between the bladder and rectum. The most common causes are malignancies, inflammatory diseases and surgical interventions. Iatrogenic fistulas after transurethral resection of the prostate (TURP) are extremely rare. The aim of this case report is to emphasize the importance of recognition of rectovesical fistula after TURP in the emergency department and multidisciplinary treatment approach.

Materials and Methods: A 69-year-old male patient was admitted to the emergency department with the complaint of fecal discharge from the bladder catheter. It was learned that the patient had undergone TURP operation five days ago. His medical history included dementia, hypertension, diabetes mellitus, benign prostatic hyperplasia and coronary artery disease. Physical examination revealed abdominal tenderness and vital signs were stable. Laboratory tests revealed elevated C-reactive protein (66 mg/L). Computed tomography revealed total fistulization between the bladder and rectum. Based on the present findings, the patient was diagnosed as iatrogenic rectovesical fistula.

Figure 1

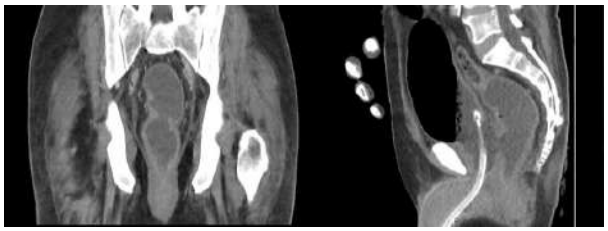

Coronal and sagittal CT images of the abdomen showing a fistula tract between the bladder and rectum

Figure 2

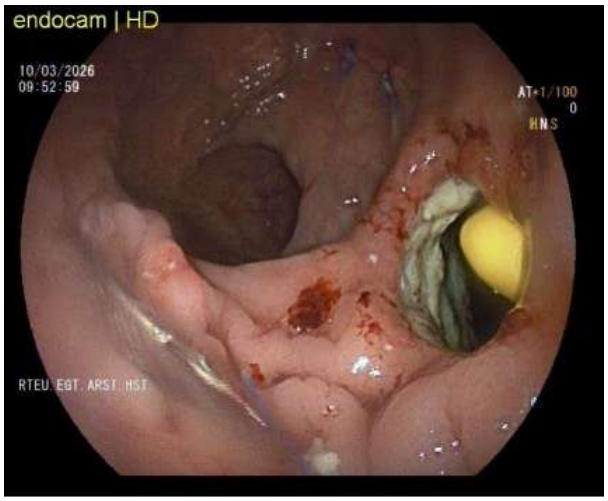

Rectosigmoidoscopy image showing a bladder catheter balloon through the fistula tract between the rectum and bladder

Results and Conclusion: Rectovesical fistulas are rare but carry a risk of serious infection and sepsis if not diagnosed early. Specific findings such as stool from the bladder catheter are diagnostic. In such cases, planning surgical treatment with rapid imaging and multidisciplinary approach is important in terms of prognosis. Awareness of emergency physicians about this rare but important complication plays a critical role in early diagnosis and initiation of appropriate treatment.

Keywords: rectovesical fistula, TURP, iatrogenic complication

Ref No: 4165

Rhabdomyolysis

Kadir Eryürük[1], Murat Seyit[1], Atakan Yılmaz[1], Mert Özen[1], Alten Oskay[1], İbrahim Türkçüer[1]

[1]Pamukkale University Faculty of Medicine

Murat Seyit / Pamukkale University Faculty of Medicine

Introduction and Purpose: Diffuse muscle pain and fatigue are frequently attributed to benign myalgia or post-viral syndromes. However, when accompanied by dark-colored urine, rhabdomyolysis must be considered. Early recognition is critical, as delayed diagnosis may result in acute kidney injury and life-threatening electrolyte disturbances.

Materials and Methods: A 24-year-old man presented with bilateral leg pain and generalized weakness following intense physical exercise. He reported that his urine had appeared “tea-colored” for the past two days. There was no history of trauma. He stated that this was the first time he had engaged in such strenuous training.Vital Signs: Blood pressure was 122/76 mmHg, heart rate 96 beats/min, body temperature 37.3°C, and oxygen saturation 99% on room air.Physical Examination: Marked tenderness was noted in the thigh muscles without significant edema. No neurological deficits were identified.Laboratory Findings: Creatine kinase (CK) was markedly elevated at 18,500 U/L. Aspartate and alanine aminotransferase levels were mildly elevated. Serum creatinine was 1.8 mg/dL, increased from previous baseline values. Potassium level was 5.6 mmol/L. Urinalysis was positive for blood on dipstick testing; however, microscopic examination revealed no erythrocytes, consistent with myoglobinuria.Imaging:No specific imaging studies were required.

Materials and Methods: Aggressive intravenous fluid resuscitation was initiated to prevent pigment-induced acute kidney injury. Electrolytes and renal function were closely monitored. Hemodialysis was not required. In patients presenting with muscle pain and dark urine, serum CK measurement is essential. Early fluid therapy significantly reduces the risk of renal complications. Seemingly benign muscle pain may conceal a serious and potentially reversible condition.

Keywords: Rhabdomyolysis, Muscle pain, Fluid therapy

Ref No: 4166

Testicular Torsion: The Abdominal Emergency in Disguise

Kadir Eryürük[1], Murat Seyit[1], Alten Oskay[1], Atakan Yılmaz[1], Mert Özen[1], İbrahim Türkçüer[1]
[1]Pamukkale University Faculty of Medicine
Murat Seyit / Pamukkale University Faculty of Medicine

Introduction and Purpose: Right lower quadrant abdominal pain is classically associated with acute appendicitis. However, in adolescent and young adult males, genitourinary causes must always be considered. Testicular torsion is a true surgical emergency that may result in testicular loss within hours if diagnosis is delayed. Notably, pain may be perceived predominantly in the abdomen rather than the scrotum, leading to diagnostic pitfalls.

Materials and Methods: A 19-year-old male presented with progressively worsening right lowerquadrant pain of 3 hours' duration, accompanied by nausea and a single episode of vomiting. He was afebrile. The pain intensified with ambulation and was described as "stabbing." Initial evaluation favored acute appendicitis, and surgical consultation was planned. Upon further history-taking, the patient reported a brief pulling sensation in the right groin at pain onset, followed by scrotal discomfort that he had hesitated to mention due to embarrassment.Vital Signs: Blood pressure was 128/74 mmHg, heart rate 104 beats/min, SpO_2 99%, and body temperature 36.8°C. Physical Examination:Abdominal examination revealed right lower quadrant tenderness with minimal rebound. Scrotal examination demonstrated the right testis in a slightly elevated position with marked tenderness. The cremasteric reflex was diminished on the right side.Laboratory Findings: Leukocyte count was 13.4 K/µL, and C-reactive protein was mildly elevated at 6 mg/L. Urinalysis was negative for leukocytes and nitrites, with no significant hematuria.Imaging: Abdominal ultrasonography did not clearly visualize the appendix and demonstrated minimal free fluid. Given clinical suspicion, scrotal Doppler ultrasonography was performed, revealing significantly decreased arterial blood flow to the right testis, consistent with testicular torsion. Following this finding, the appendicitis workup was discontinued.Management: Urology was urgently consulted. After administration of analgesia, the patient was taken promptly tothe operating room. Surgical exploration confirmed 360–540° torsion. Following detorsion, testicular color and perfusion improved. Bilateral orchiopexy was performed. Postoperatively, the patient's pain rapidly resolved, and discharge planning was initiated.

Materials and Methods: In adolescent and young adult males presenting with right lower quadrant pain, a scrotal examination is mandatory. Symptoms may be concealed due to embarrassment. Mild laboratory abnormalities may mimic appendicitis; however, failure to exclude testicular torsion with Doppler ultrasonography canresult in irreversible testicular loss. A single careful examination may save an organ.

Keywords: Testicular Torsion, Doppler ultrasonography, Scrotal examination

Ref No: 4258

The Life-Saving Role of High-Dose Insulin Euglycemia (HIE) Therapy in the Emergency Department for Refractory Calcium Channel Blocker and Beta-Blocker Co-Intoxication

ŞAFAK ÇOMURLU[1]

[1]ATATURK UNIVERSTY

ŞAFAK ÇOMURLU / ATATURK UNIVERSTY

Introduction and Purpose: Introduction: Simultaneous overdose of calcium channel blockers(CCBs) and beta-blockers(BBs) represents one of the most lethal toxicological emergencies encountered in the emergency department(ED). In cases of cardiogenic shock refractory to conventional treatments—such as intravenous fluids, atropine, glucagon, and calcium—High-Dose Insulin Euglycemia(HIE) therapy has become a cornerstone of current management guidelines. This report aims to present a case of massive antihypertensive ingestion resulting in refractory shock, which was successfully managed with the timely initiation of HIE therapy.

Materials and Methods: Case Presentation:A 45-year-old female patient was admitted to the ED two hours after a suicidal ingestion of high-dose verapamil, metoprolol. Upon presentation, the patient was confused, with a blood pressure of 60/40 mmHg and a heart rate of 35 beats per minute. The electrocardiogram(ECG) revealed a third-degree atrioventricular(AV) block. Immediate interventions included intravenous fluid resuscitation, calcium gluconate, glucagon, and vasopressor(norepinephrine) infusion. An external pacemaker was applied due to the high-degree heart block.Despite these measures, the patient remained hemodynamically unstable. Consequently, HIE therapy was initiated (a bolus of 1 U/kg regular insulin followed by a 1 U/kg/hr infusion) with a concurrent dextrose infusion to maintain euglycemia. Improvement in hemodynamic parameters was observed within the first hour of treatment. By the fourth hour, the patient reverted to sinus rhythm, and vasopressor requirements were gradually tapered. The patient was subsequently transferred to a tertiary intensive care unit for continued monitoring.DiscussionIn the setting of CCB and BB intoxication, the myocardium shifts its metabolic preference from free fatty acids to carbohydrates. HIE therapy facilitates this shift by enhancing myocardial glucose uptake, thereby providing a potent inotropic effect and improving cytoplasmic calcium cycling. Leading clinical resources, such as Rosen's Emergency Medicine and UpToDate, recommend the early initiation of HIE in vasopressor-resistant cases. In this

instance, the early transition to an HIE strategy likely averted the need for more invasive measures such as ECMO.

Materials and Methods: Conclusion: HIE therapy is a powerful tool that should be readily available in the armamentarium of emergency physicians for refractory CCB and BB intoxications. However, close monitoring of blood glucose and electrolyte levels is vital to mitigate the risks of iatrogenic hypoglycemia and hypokalemia during treatment.

Keywords: High-Dose Insulin Euglycemia(HIE) therapy, beta-blockers, calcium channel blockers

---

Ref No: 4262

Advanced Chronic Kidney Disease in a Young Patient Presenting with Non-specific Symptoms

MURTEZA ZAFER[1]

[1]ATATÜRK ÜNİVERSİTESİ EĞİTİM VE ARAŞTIRMA HASTANESİ

MURTEZA ZAFER / ATATÜRK ÜNİVERSİTESİ EĞİTİM VE ARAŞTIRMA HASTANESİ

Introduction and Purpose: IntroductionKidney disease usually presents with specific symptoms, but some young patients may come to the emergency department with non-specific complaints. In these cases, routine laboratory tests are crucial for the early detection of serious underlying renal disorders.

Materials and Methods: Case PresentationA 19-year-old male presented to the emergency department with fatigue, weakness, and mild nausea. He had no fever, headache, or urinary complaints. The patient had no prior chronic illnesses.Physical examination:•Vital signs were within normal limits•No edema or signs of dehydration•No arrhythmia or cardiovascular instabilityLaboratory findings:•Creatinine: 9 mg/dL•BUN: 110 mg/dL•Electrolytes: mild hyperkalemia (5.6 mmol/L)•Urinalysis: protein +, no red blood cellsInitially, his symptoms were considered non-specific and thought to be due to a viral infection or simple fatigue. However, laboratory results indicated advanced chronic kidney disease. Postrenal causes, acute trauma, arrhythmia-related complications, and any chronic underlying disease were ruled out. The patient was admitted for further evaluation and planned follow-up with internal medicine.DiscussionThis case demonstrates that even in young patients, non-specific symptoms

can mask severe kidney disease. It also emphasizes the importance of routine blood tests for all patients, as these tests can reveal life-threatening metabolic or renal disorders early.

Materials and Methods: Conclusion•Advanced chronic kidney disease should be considered in young patients presenting with non-specific complaints, even in the absence of any chronic illness.•Routine laboratory tests are critical for early diagnosis and planning follow-up.

Keywords: Chronic Kidney Disease

Ref No: 4287

The challenge of lack of communication among migrants

Ali Ümit Arığüloğlu[1], Murat Seyit[1], Duygu Aras Seyit[2], Alten Oskay[1], Atakan Yılmaz[1], Mert Özen[1]

[1]Pamukkale University Faculty of Medicine
[2]ERPA Saglik Hospital, Denizli

Murat Seyit / Pamukkale University Faculty of Medicine

Introduction and Purpose: Altered mental status requires rapid evaluation and a systematic diagnostic approach, particularly when patient history is unavailable. We present a case of a young refugee patient admitted with impaired consciousness in whom lack of medical records complicated the diagnostic process.

Materials and Methods: A 23-year-old male was brought to the emergency department by emergency medical services due to decreased consciousness. According to prehospital information, his friends had been unable to reach him for approximately six hours. Upon entering his residence, they found him unconscious on the floor.On arrival, his Glasgow Coma Scale (GCS) score was 7, and he was intubated for airway protection. Bedside EFAST examination revealed no pathological findings. As the patient was a refugee with no accessible medical records, an extensive diagnostic workup was initiated. Electrocardiography showed no abnormalities.During follow-up in the emergency department, a friend stated that the patient had no known chronic illnesses. However, the patient subsequently developed a generalized tonic-clonic seizure. Antiepileptic treatment was initiated, and further imaging studies were performed.Later, another acquaintance reported that the patient had a known diagnosis of epilepsy but had been unable to access his medication due to lack of health insurance and limited healthcare access. Laboratory results showed no evidence of infection, and toxicology screening was negative. Based on the clinical presentation and recurrent seizure activity, the patient was

diagnosed with status epilepticus.Neurology consultation was obtained, and the patient was admitted to the neurology intensive care unit for further management.

Materials and Methods: This case highlights the diagnostic challenges encountered when medical history and healthcare access are limited. In refugee populations residing in Turkey, barriers to continuous care may result in preventable life-threatening emergencies. Strengthening healthcare integration and ensuring continuity of treatment remain essential to improving outcomes in vulnerable populations.

Keywords: Refugee, Status epilepticus, Seizure

Ref No: 4299

Is Every Fever an Infection? A Case of Parkinsonism-Hyperpyrexia Syndrome

Kevser Yıldırım[1], Murat Seyit[1], Duygu Aras Seyit[2], Atakan Yılmaz[1], Mert Özen[1], Alten Oskay[1]

[1]Pamukkale University Faculty of Medicine
[2]ERPA Saglik Hospital, Denizli

Murat Seyit / Pamukkale University Faculty of Medicine

Introduction and Purpose: A 74-year-old male with a history of Parkinson's disease, Alzheimer's, and dementia presented to the emergency department with a two-day history of fever, chills, clouded consciousness, and decreased oral intake. His family reported a significant slowdown in his movements and generalized body rigidity over the past 48 hours, leading to a bedridden state. His routine medications included Rasagiline (Azilect) and Donepezil.

Materials and Methods: On admission, the patient was tachycardic (130 bpm) and tachypneic (26/min) with a temperature of 38.6°C. Physical examination revealed a GCS of 13, limited eye contact, and prominent bilateral generalized 'lead-pipe' rigidity with marked hypokinesia. Laboratory results showed leukocytosis (WBC: 13.37), elevated CRP (23.32 mg/dL), and a glucose level of 268 mg/dL. Critically, despite the administration of antipyretics (paracetamol), his fever remained persistent, dropping only slightly to 37.6°C. Comprehensive imaging, including CT scans of the brain, thorax, and abdomen, revealed no acute septic focus or infectious pathology. An infectious disease consultation confirmed the absence of an acute infection. Subsequent testing showed an elevated Creatine Kinase (CK) of 253 U/L, further indicating muscle involvement.

Materials and Methods: The clinical picture pointed toward Parkinsonism-Hyperpyrexia Syndrome (PHS), triggered by the abrupt withdrawal of dopaminergic therapy (Rasagiline) due to the patient's decreased oral intake. PHS is a rare, life-threatening condition mirroring Neuroleptic Malignant Syndrome (NMS) but caused by dopaminergic withdrawal rather than antagonist use. This diagnosis is easily overlooked in the emergency department, where fever is often reflexively treated as sepsis. This case underscores the necessity of scrutinizing medication adherence in neurodegenerative patients presenting with unexplained hyperpyrexia and rigidity, as prompt reintroduction of dopaminergic therapy is vital for survival.

Keywords: Parkinsonism-Hyperpyrexia Syndrome, Hyperpyrexia, Dopaminergic Withdrawal.

Ref No: 4310

From shock to infarction: the cardiac face of anaphylaxis

İsmail Ceylan, Nurser Mutlu, Gamze Yıldız, Vahdet Işıkoğlu, Mehmet Gül

[1]Emergency Medicine Department, Konya City Hospital, Türkiye

Gamze Yıldız / Emergency Medicine Department, Konya City Hospital, Türkiye

Introduction and Purpose: Anaphylaxis is a life-threatening systemic hypersensitivity reaction that requires rapid diagnosis and treatment. Rarely, acute coronary syndrome (ACS) may develop during or after an anaphylactic reaction. In this case report, we present a 60-year-old male patient who was treated for anaphylaxis following a cystoscopy, and who subsequently developed ST-elevation myocardial infarction (STEMI) and cardiac arrest despite early clinical improvement.

Materials and Methods: A 60-year-old male patient was brought to the emergency department (ED) with a code blue after developing cold sweating, generalized itching, and a rash following a cystoscopy procedure in the urology clinic. Physical examination revealed uvular edema, rhonchi consistent with bronchospasm, and widespread erythema on the anterior chest. The patient was diagnosed with anaphylaxis and treated with intramuscular adrenaline and other supportive therapies.

Materials and Methods: Results and Conclusion:During ED follow-up, the patient developed ACS, went into cardiac arrest, and despite prolonged advanced cardiovascular life support (ACLS), no response was achieved, and the patient was declared deceased. Although typical findings of anaphylaxis were initially predominant, STEMI and malignant arrhythmias

developed rapidly. The clinical course strongly suggests the coexistence of anaphylaxis and ACS, a condition known as Kounis syndrome. This case is important as it demonstrates that the coexistence of anaphylaxis and ACS, although rare, can be rapidly fatal. Any chest pain or hemodynamic instability developing after anaphylaxis must be aggressively evaluated for ACS. Clinicians must maintain a high index of suspicion for Kounis syndrome and ensure serial electrocardiogram (ECG) and cardiac biomarker monitoring in severe allergic reactions.

Keywords: Anaphylaxis, Kounis syndrome, STEMI

Ref No: 4387

Appendicitis in a patient with prior appendectomy

Alparslan Altun[1], Ali Gür[1]

[1]Atatürk University Hospital Department Of Emergency Medicine

Alparslan Altun / Atatürk University Hospital Department Of Emergency Medicine

Introduction and Purpose: Stump appendicitis, which develops due to inflammation of residual appendiceal tissue left after surgical intervention, is a rare clinical condition. It is defined as the re-inflammation of the remaining appendiceal tissue following appendectomy performed for acute appendicitis. Clinically, it typically presents with acute abdominal pain.

Materials and Methods: A 40-year-old male patient presented with abdominal pain. He reported right lower quadrant pain for the past two days. His medical history was significant for a prior appendectomy, with no other known comorbidities.On admission, his vital signs were as follows: blood pressure 130/82 mmHg, oxygen saturation 95%, heart rate 90 beats per minute, and body temperature 36.9°C. Physical examination revealed tenderness and rebound in the right lower quadrant. Laboratory findings demonstrated leukocytosis, neutrophil predominance, and elevated C-reactive protein (CRP) levels. Imaging findings showed inflammatory changes, including fat stranding in the pericecal region and right paracolic area. Based on these findings, the differential diagnosis in this patient with a history of appendectomy included cecal diverticulitis and stump appendicitis. The patient was consulted to the general surgery department and was hospitalized with a diagnosis of stump appendicitis.

Materials and Methods: Physical examination remains one of the most important steps in the evaluation of acute abdomen. Although acute abdominal pathologies generally present with findings consistent with the examined region, in rare cases—as in this patient—the pathology

may originate outside the expected focus.Even in patients with a history of appendectomy, the presence of right lower quadrant acute abdomen findings and elevated inflammatory markers warrants further evaluation until acute abdomen is definitively excluded. As demonstrated in this case, stump appendicitis, although rare, should be considered.

Keywords: appendectomy, stump appendicitis

Ref No: 4406

Iatrogenic Tracheal Injury Following Endotracheal Tube Withdrawal in ICU: A Case Report

Esra Şenol Kaçar[1]

[1]Dicle University Hospital

Esra Şenol Kaçar / Dicle University Hospital

Introduction and Purpose: Tracheal injuries are rare but serious complications in intensive care units (ICU), often associated with prior intubation, difficult airway management, and procedural errors. Prompt recognition and multidisciplinary management are essential to reduce morbidity. We present a case of iatrogenic tracheal perforation in a post-ICU extubation patient with multiple risk factors.

Materials and Methods: Case Presentation: A 55-year-old female patient with a history of hypertension, previously intubated in the ICU, developed a tracheal injury during extubation in the intensive care unit. The endotracheal tube cuff was not fully deflated when the tube was removed, resulting in subcutaneous emphysema and respiratory distress. The patient required urgent tracheal repair and multidisciplinary management in the ICU.

Materials and Methods: The patient was managed in the ICU with sedation and analgesia using low-dose propofol, fentanyl, and midazolam. Neuromuscular blockade was performed with rocuronium (Esmeron), and an Ultiva infusion was administered during management. During extubation, the endotracheal tube cuff was not fully deflated, causing tracheal perforation. Post-extubation, subcutaneous emphysema and respiratory distress developed. Analgesia was maintained with tramadol and paracetamol. Neuromuscular blockade was reversed with sugammadex (Bridion), and the patient was successfully awakened without further complications.

Keywords: Tracheal perforation, ICU, Extubation complication

Ref No: 4407

A CASE OF AUTOİMMUNE HEMOLYTİC ANEMİA PRESENTİNG TO THE EMERGENCY DEPARTMENT WİTH FATİGUE AND OLİGURİA

Saygın Çanga[1], İzel Hüzmeli Öncü[1], Yusuf Ziya Taştekin[1], Firas Arda Dönmez[1], Mustafa Polat[1], Ali Karakuş[1]

[1]Hatay Mustafa Kemal University, Faculty of Medicine, Department of Emergency Medicine, Hatay, Türkiye

Yusuf Ziya Taştekin / Hatay Mustafa Kemal University, Faculty of Medicine, Department of Emergency Medicine, Hatay, Türkiye

Introduction and Purpose: Autoimmune hemolytic anemia (AIHA) is a rare but potentially life-threatening hemolytic anemia caused by autoantibody- and/or complement-mediated destruction of erythrocytes. In the emergency department, it may present with a wide clinical spectrum, including fatigue,jaundice, dark urine, and a rapid decline in hemoglobin levels.This case report emphasizes that AIHA should be considered in the differential diagnosis of patients presenting to the emergency department with non-specific complaints such as fatigue and decreased urine output.

Materials and Methods: A 42-year-old woman presented to the emergency department with decreased urine output and fatigue. She had no known chronic diseases and was not taking any regular medications.Physical examination revealed conjunctival/scleral pallor; no petechiae or purpura were observed. Abdominal examination was unremarkable, with no guarding or rebound tenderness.No additional pathological findings were noted on the examinations of other systems. Her past medical and family history were non-contributory. She reported no recent infection or illness within the preceding two weeks.On presentation, she was in good general condition and hemodynamically stable. Vital signs were as follows: temperature 36°C, heart rate 106 beats/min, respiratory rate 20 breaths/min, and oxygen saturation 98%.Electrocardiography showed normal sinus rhythm.Despite placement of a urinary catheter, no urine output was observed (anuria). Laboratory test results are presented in Table 1. Non-contrast computed tomography of the chest and abdomen revealed no acute pathology.The patient was consulted to hematology with a preliminary diagnosis of autoimmune hemolytic anemia (possible cold agglutinin disease). Peripheral blood smear demonstrated red blood cell clumping (agglutination). She was admitted to the intensive care unit for close monitoring and treatment. Hemodialysis was initiated, and plasmapheresis and blood product transfusion were planned. After 7 days in the ICU, she was transferred to the ward and was discharged after an additional 4 days of inpatient follow-up with a recommendation for outpatient clinic follow-up.

Materials and Methods: In conclusion, autoimmune hemolytic anemia is a rare, life-threatening condition that may present to the emergency department with nonspecific symptoms yet can rapidly progress to severe hemolysis and organ dysfunction. . Therefore, AIHA should always be considered in the differential diagnosis of patients presenting with fatigue, jaundice/dark urine, and a rapid decline in hemoglobin levels.

Keywords: Autoimmune hemolytic anemia, acute kidney injury, cold agglutinin disease.

Ref No: 4435

Demyelinating diseases

Duygu Aras Seyit[1], Murat Seyit[2]

[1]ERPA Saglik Hospital, Denizli
[2]Pamukkale University Faculty of Medicine

Murat Seyit / Pamukkale University Faculty of Medicine

Introduction and Purpose: Demyelinating diseases can lead to patients presenting to the Emergency department with acute-onset symptoms. These symptoms frequently include dizziness, unilateral numbness, weakness, vision loss and difficulty walking. Although contrast-enhanced brain MRI is used for diagnosis and differential diagnosis, it is sometimes insufficient on its own. This case report describes a patient in whom a tumour-like mass was suspected on contrast-enhanced brain MRI.

Materials and Methods: A 33-year-old male patient presented with complaints of numbness on the left side and newly-onset dizziness, which had been present for 1–2 days. Contrast-enhanced brain MRI revealed a lesion in the right parietal region showing contrast uptake; whilst a demyelinating lesion was initially suspected, a clear distinction from a mass could not be made. The patient was admitted for further investigation and treatment.

MRI



Materials and Methods: Although acute-onset neurological symptoms primarily suggest a cerebrovascular event, demyelinating diseases may also present with acute neurological findings. Diffusion MRI performed in the emergency department is insufficient for diagnosis; a contrast-enhanced brain MRI must also be performed. Furthermore, as in our case, some lesions may mimic a mass lesion, so further investigations may also be required.

Keywords: Demyelinating diseases, acute neurological findings, Diffusion MRI

Ref No: 4526

Pulmonary embolism presenting as isolated anxiety attack

Mehmet Yaşar[1], Fatma Tortum[1]

[1]Atatürk University

Mehmet Yaşar / Atatürk University

Introduction and Purpose: Pulmonary embolism (PE) can present with nonspecific symptoms and may be misdiagnosed as psychiatric conditions. This case illustrates an unusual presentation of PE.

Materials and Methods: A 47-year-old female presented with sudden-onset anxiety, palpitations, and a sense of impending doom. Vital signs showed mild tachycardia but were otherwise normal. The patient had no known psychiatric history. Physical examination was unremarkable. Due to unexplained symptoms, further evaluation was performed.

Materials and Methods: D-dimer was elevated, and computed tomography pulmonary angiography (CTPA) revealed segmental pulmonary embolism. Anticoagulation therapy was initiated. PE should be considered in patients presenting with unexplained anxiety symptoms, particularly when accompanied by subtle physiological abnormalities.

Keywords: Pulmonary embolism, anxiety, atypical presentation

Ref No: 4579

Clarithromycin-Induced Acute Neurotoxicity: A Case of "Antibiomania"

Rümeysa DÜŞÜNCELİ[1], Nevzat HERGÜL[1]
[1]Van Yüzüncü Yıl University, Faculty of Medicine

Nevzat HERGÜL / Van Yüzüncü Yıl University, Faculty of Medicine

Introduction and Purpose: Clarithromycin-induced neurotoxicity is a rare but likely underrecognized adverse effect, particularly in older adults. It typically develops within days of treatment initiation and presents with delirium, psychosis, or manic symptoms, a condition often referred to as "antibiomania." Early recognition is essential, as symptoms are reversible following drug discontinuation. We report a case of acute neuropsychiatric deterioration temporally associated with clarithromycin use.

Materials and Methods: A 65-year-old woman with hypertension presented with a 2–3 day history of behavioral and cognitive disturbances, including disorientation, repetitive speech, visual misperceptions, talking to her deceased sibling, and transient loss of consciousness.Five days before admission, she had been prescribed clarithromycin (500 mg twice daily) for upper respiratory symptoms. She had no psychiatric history.On examination, she was conscious but disoriented to person, place, and time. Vital signs were stable, and neurological examination showed no focal deficits.Laboratory evaluation, including inflammatory markers, electrolytes, renal and liver function tests, revealed no abnormalities. Findings are summarized in Table 1. Cranial imaging was unremarkable. Cerebrospinal fluid (CSF) analysis showed normal biochemical and microbiological parameters (Table 2).Given the temporal relationship and exclusion of organic causes, clarithromycin-induced neurotoxicity was suspected. The patient was evaluated by psychiatry, admitted for monitoring, and clarithromycin was discontinued.During approximately one week of follow-up, her symptoms completely resolved without specific psychiatric treatment. She was discharged fully oriented.

Table 1

Parameter	Result	Reference Range
White blood cells ($\times 10^3/\mu L$)	8.63	3.91–10.9
Hemoglobin (g/dL)	12.2	13-17

Platelets (×10³/μL)	365	166-390
C-reactive protein (mg/dL)	2	0-5
Potassium (mmol/L)	4.1	3.5-5.1
Sodium (mmol/L)	138	135-145
Creatinine (mg/dL)	0.8	0.6-1.2
AST (U/L)	22	5-40
ALT (U/L)	18	5-41

Laboratory Findings

Table 2

Parameter	Result	Reference Range
Apperance	Clear	Clear
White blood cells (/mm³)	0	0-5
Protein (mg/dL)	16.8	15-40
Glucose (mg/dL)	69	40-70
CSF/Serum glucose ratio	0.65	>0.6
Gram stain	Negative	Negative

Cerebrospinal Fluid (CSF) Findings

Materials and Methods: This case demonstrates a reversible yet clinically significant adverse effect of clarithromycin. The temporal association, exclusion of alternative etiologies, and full recovery after discontinuation support a causal relationship.Clarithromycin has one of the highest reported risks of antibiotic-associated psychosis. Proposed mechanisms include GABA-A receptor antagonism and neurotoxic metabolite accumulation.Clinically, this condition may mimic primary psychiatric disorders or encephalopathy, leading to unnecessary investigations.

Therefore, medication history should be carefully reviewed in patients with acute neuropsychiatric symptoms.Early recognition and drug discontinuation usually result in rapid recovery.

Keywords: Antibiomania, Drug-induced psychosis, Clarithromycin

---

Ref No: 4633

CASE REPORT OF COMPARTMENT SYNDROME DEVELOPİNG İN THE LOWER EXTREMİTY OF A 35-YEAR-OLD MALE PATİENT

Kenan Özoğlu[1], Saygın Çanga[1], Yusuf Ziya Taştekin[1], Hakan Ercan[1], Ali Karakuş[1]

[1]Department of Emergency Medicine, Faculty of Medicine, Hatay Mustafa Kemal University, Hatay

Yusuf Ziya Taştekin / Department of Emergency Medicine, Faculty of Medicine, Hatay Mustafa Kemal University, Hatay

Introduction and Purpose: Any pathological process that causes the pressure within muscle tissue to exceed the tissue's perfusion pressure has the potential to lead to compartment syndrome of the extremities.Most cases of acute extremity compartment syndrome are associated with trauma and/or vascular disorders, but various other conditions can also lead to increased compartment pressure and result in extremity compartment syndrome.Any etiology that increases the fluid volume within a muscle compartment or restricts the compartment's outward expansion will increase the compartment's internal pressure due to the relatively inelastic fascia surrounding the muscles. Consequently, prolonged ischemia can lead to necrosis of the muscles within the compartment.

Materials and Methods: A 35-year-old male patient presented to the emergency department due to severe swelling of his right foot following an iron object falling on it two days prior.The entire right foot appears erythematous, and there is a 5x3 cm hyperemic wound with broken skin integrity on the lateral aspect of the right foot.There is limited mobility and tenderness.Crepitus is present in the right ankle. Laboratory findings:WBC: 10,760 × 10^3/μL,neutrophils:8,840 × 10^3/μL, ESR: 27 sec, CRP: 165 mg/L. Imaging studies revealed a displaced comminuted fracture line in the right calcaneus and subcutaneous air. Management:A patient suspected of having right lower leg compartment syndrome was referred to the Department of Orthopedics and Traumatology.The patient was evaluated by the Department of Orthopedics and admitted for treatment.Clinical Outcome:A fasciotomy was planned for the patient by the Orthopedics and

Traumatology Clinic for therapeutic purposes. During the procedure, an incision was made on the dorsal aspect of the patient's right foot between the 2nd and 4th interdigital spaces.A fasciotomy was performed. The area was thoroughly irrigated. A gauze dressing was applied. A short-leg cast was applied. The patient experienced no complications during postoperative dressing changes and was discharged following appropriate treatment.

Materials and Methods: This case highlights the importance of considering compartment syndrome in patients presenting to the emergency department with swelling in the extremities particularly following trauma especially when accompanied by loss of sensation, absence of a pulse, or paralysis.Compartment syndrome is an urgent clinical diagnosis; if diagnosis and treatment are delayed, it can lead to limb loss.

Keywords: Compartment syndrome, calcaneal fracture, fasciotomy

---

Ref No: 4664

Visual impairment and diffuse cerebral involvement secondary to carbon monoxide poisoning

Mehmet Kasa, Naim Hikmet Kalkan, Mustafa Çifttçi, Emin Fatih Vişneci,Mehmet Gül

[1]Emergency Medicine Department, Konya City Hospital, Türkiye

Mehmet Kasa / Emergency Medicine Department, Konya City Hospital, Türkiye

Introduction and Purpose: Carbon monoxide (CO) poisoning is a life-threatening condition that causes tissue hypoxia and cellular toxicity, leading to severe neurological sequelae. While the basal ganglia and deep white matter are classically affected, cortical involvement—particularly of the occipital lobe—resulting in cortical blindness is a rare manifestation and an indicator of severe hypoxic injury. In this report, we aim to present a rare case of cortical blindness and diffuse cerebral injury secondary to CO poisoning.

Materials and Methods: A 49-year-old male patient was admitted to the emergency department (ED) with a transient loss of consciousness and sudden vision loss following exposure to CO gas leaking from a heating stove. Upon admission, the patient was conscious and hemodynamically stable; although pupillary light reflexes were intact on physical examination, a marked visual deficit was detected. The patient's carboxyhemoglobin (COHb) level was measured at 26%. A cranial diffusion magnetic resonance imaging (MRI) scan was performed, which revealed widespread acute ischemic and hypoxic injury involving the bilateral occipital lobes, cerebellar hemispheres, and the corpus callosum.

Materials and Methods: Results and Conclusion:Diagnosed with CO-induced cortical blindness, the patient was promptly started on hyperbaric oxygen (HBO) therapy and admitted to the neurology intensive care unit (ICU) for close monitoring. CO poisoning is a complex syndrome that not only causes systemic hypoxia but can also lead to widespread cerebral injury and severe neurological deficits. Even in patients who are conscious and hemodynamically stable, specific complaints such as visual impairment may signal diffuse cortical involvement and occipital lobe infarction. In such atypical clinical presentations, early diagnosis, mapping of injury with cranial diffusion MRI, and prompt initiation of HBO therapy to restore tissue oxygenation are critical for preventing permanent neurocognitive sequelae

Keywords: Carbon monoxide poisoning, cortical blindness, hypoxic injury

---

Ref No: 4877

Normal Radiographs Do Not Exclude Significant Injury: The Value of MRI in Severe Post-traumatic Hip Pain

Sevdegül KARADAŞ[1], Nevzat HERGÜL[1]

[1]Yuzuncu Yil University, Medical School Hospital, Van, Türkiye

Sevdegül KARADAŞ / Yuzuncu Yil University, Medical School Hospital, Van, Türkiye

Introduction and Purpose: Acute hip pain after sports-related trauma in adolescents is commonly evaluated with plain radiographs to exclude fracture, dislocation, or avulsion injury. However, normal radiographic findings do not rule out clinically significant soft-tissue damage. In patients with severe pain disproportionate to initial imaging findings, further evaluation with magnetic resonance imaging (MRI) may be necessary. This case emphasizes the importance of considering MRI in adolescent athletes presenting with persistent severe hip pain despite unremarkable radiographs.

Materials and Methods: A 16-year-old male presented to the emergency department with severe left hip pain that had persisted for two days after a football injury. He had been playing as a goalkeeper and developed sudden pain while stretching to reach the ball during the match. Because his symptoms did not improve, he sought medical attention. On physical examination, there was marked tenderness over the left hip and gluteal region on palpation. Hip range of motion was preserved, although movement was painful. Plain radiographs of the pelvis and hip were normal, with no evidence of fracture, dislocation, or avulsion injury. Given the persistence and severity of pain despite normal radiographs, MRI of the left hip was performed. Axial fat-suppressed MRI demonstrated focal fiber disruption within the left gluteus maximus muscle, with surrounding edema and fluid-sensitive hyperintensity, consistent with acute rupture (Figure

1). Coronal fat-suppressed MRI better delineated the craniocaudal extent of the lesion and confirmed rupture of the left gluteus maximus with associated perifascial and intramuscular edema (Figure 2).

Figure 1



Axial fat-suppressed MRI shows focal fiber disruption in the left gluteus maximus muscle with surrounding edema and fluid-sensitive hyperintensity, compatible with acute rupture.

Figure 2

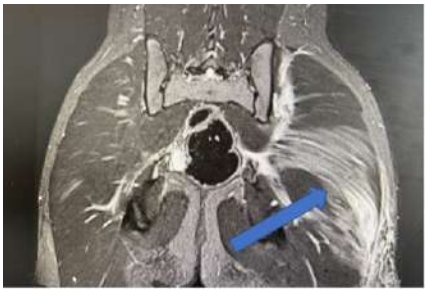

Coronal fat-suppressed MRI better delineates the craniocaudal extent of the lesion, confirming rupture of the left gluteus maximus with associated perifascial and intramuscular edema.

Results and Conclusion: This case demonstrates that normal radiographs do not exclude significant soft-tissue injury in adolescent athletes with acute hip trauma. When severe pain persists despite unremarkable plain films, MRI should be considered to avoid missed diagnosis. MRI is particularly valuable for detecting occult muscular injury and clarifying the etiology of symptoms when the initial evaluation is inconclusive. Early MRI assessment may therefore improve diagnostic accuracy in selected patients with disproportionate pain after sports-related hip trauma.

Keywords: hip pain, magnetic resonance imaging, gluteus maximus rüptüre

Ref No: 4881

Aspiration Pneumonia Leading To Respiratory Failure: A Case Report In A Frail Elderly Patient

Çağdaş Korucu[1], Murat Seyit[1], Mert Özen[1], Alten Oskay[1], Atakan Yılmaz[1], İbrahim Tükçüer[1]

[1]Pamukkale University Faculty of Medicine

Murat Seyit / Pamukkale University Faculty of Medicine

Introduction and Purpose: Aspiration pneumonia is a frequent and serious condition in elderly, bedridden patients, particularly those with impaired consciousness and multiple comorbidities. It may rapidly progress to respiratory failure, requiring intensive care support. This poster presents an elderly nursing home patient who developed aspiration pneumonia with subsequent respiratory deterioration.

Materials and Methods: An 89-year-old male nursing home resident was admitted to the emergency department due to acute onset dyspnea and oxygen desaturation following a meal. His medical history included coronary angiography with stent placement, hypertension, prior cholecystectomy, and a 40 pack-year smoking history. The patient was bedridden and dependent on full-time care. Physical Examination and Vital Signs: On admission, vital signs were as follows: blood pressure 115/83 mmHg, heart rate 62 bpm, respiratory rate 24/min, body temperature 36.2°C, and oxygen saturation 96% under 2 L/min supplemental oxygen. Auscultation revealed bilaterally coarse breath sounds. The Glasgow Coma Scale score was 10. Laboratory and Blood Gas Findings: Laboratory analysis showed leukocytosis (WBC: 18.76 $\times 10^9$/L) and elevated C-reactive protein (CRP: 131 mg/L). Arterial blood gas analysis revealed pH 7.32, $PaCO_2$ 44 mmHg, PaO_2 80 mmHg, and oxygen saturation 93%. Imaging Findings: Thoracic computed tomography demonstrated filling defects in the proximal segment of the right lower lobe bronchus and increased peribronchial markings in the lower lobe bronchi, findings suggestive of aspiration. Diagnosis and Treatment: The patient was diagnosed with aspiration pneumonia. Empirical intravenous antibiotic therapy with ceftriaxone 2×1 g and clindamycin 3×600 mg was initiated. Additional treatments included nebulized ipratropium–salbutamol and fluticasone, as well as intravenous N-acetylcysteine 3×600 mg. Clinical Course and Outcome: During follow-up, the patient developed worsening respiratory pattern and decreased level of consciousness. Due to respiratory failure and declining neurological status, endotracheal intubation was performed and the patient was transferred to the intensive care unit.

Materials and Methods: Aspiration pneumonia should be promptly considered in elderly, bedridden patients presenting with postprandial respiratory distress. Early recognition and aggressive management are essential to prevent rapid clinical deterioration.

Keywords: Aspiration Pneumonia, Respiratory Failure, Altered Mental Status

---

Ref No: 4902

Acute fournıer's gangrene ın a young male wıthout comorbıdıtıes: a case report

Nevzat HERGÜL[1], Mehmet Hüseyin Feyzullah EREN[1], Sevdegül KARADAŞ[1]

[1]Van Yüzüncü Yıl University, Faculty of Medicine

Nevzat HERGÜL / Van Yüzüncü Yıl University, Faculty of Medicine

Introduction and Purpose: Fournier's gangrene is a rapidly progressive, life-threatening necrotizing fasciitis of the perineal and genital regions. It typically affects elderly patients with risk factors such as diabetes mellitus, alcoholism, or immunosuppression. However, it may rarely occur in young and otherwise healthy individuals. Early diagnosis and emergent surgical debridement are critical in reducing mortality. This report presents a case of acute Fournier's gangrene in a 24-year-old male with no known comorbidities.

Materials and Methods: A 24-year-old male presented to the emergency department with rapidly progressive scrotal swelling and severe testicular pain. According to the patient, he had first noticed mild, painless scrotal swelling the day prior to admission. By the evening of presentation, the swelling had increased significantly and was accompanied by intense pain and cold sweats. There was no history of trauma, chronic illness, prior surgery, medication use, or suspicious sexual contact.On physical examination, the patient appeared clinically ill but was oriented and cooperative. Vital signs revealed hypotension (blood pressure: 90/60 mmHg), heart rate: 83 bpm, hypothermia (body temperature: 36.5°C), and oxygen saturation: 96%. Genital examination revealed marked edema, hyperemia, and necrotic areas in the scrotum (Figure 1). Laboratory findings are summarized in Table 1.Given the clinical presentation, Fournier's gangrene was strongly suspected, and urgent consultations were requested from the Urology and Infectious Diseases departments. The patient was immediately started on broad-spectrum intravenous antibiotics and aggressive fluid resuscitation. He was rapidly taken to the operating room, where extensive surgical debridement was performed (Figure 2).

Figure 1.



Patient presentation at admission (scrotal edema and necrotic areas).

Figure 2



Postoperative appearance after extensive surgical debridement.

Table 1

Parameter	Result	Normal Range
WBC (White Blood Cell) (mm3)	19	3,91-10,9
C reactive protein (mg/dl)	32	0-5
INR(International Normalized Ratio)	1.1	0.8-1.2
Platelet	183x10^3	100-400x10^3
Hgb (g/dl)	16.5	11-16

Laboratory parameters on admission.

Results and Conclusion: Fournier's gangrene is a polymicrobial necrotizing infection characterized by rapid dissemination along fascial planes and microvascular thrombosis, leading to tissue necrosis. Delay in diagnosis significantly increases mortality. Although the condition is predominantly reported in older patients with underlying risk factors, it is essential to remember that it can rarely occur in young, healthy individuals. The presence of hypotension and hypothermia, as observed in our case, may indicate systemic involvement and severe sepsis. The mainstay of treatment remains early diagnosis, aggressive fluid resuscitation, broad-spectrum antibiotics, and urgent surgical debridement.

Keywords: Fournier's gangrene, emergent surgical debridement, young patient

---

Ref No: 4947

Posterior Reversible Encephalopathy Syndrome (PRES) in the Postpartum Period: A Case Report

Ozan Deniz Keleş[1], Mehmet Ali Çağatay[1], Ahmet Melih Savaş[1], Selçuk Eren Çanakçı[1], Ayhan Aköz[1]

[1]Department of Emergency Medicine, Faculty of Medicine, Aydın Adnan Menderes University, Aydın, Turkey

Ozan Deniz Keleş / Department of Emergency Medicine, Faculty of Medicine, Aydın Adnan Menderes University, Aydın, Turkey

Introduction and Purpose: Posterior Reversible Encephalopathy Syndrome (PRES) is a clinico-radiological syndrome characterized by headaches, confusion, seizures, and visual disturbances. It is associated with hypertension, eclampsia, and cytotoxic or immunosuppressive treatments. Early diagnosis allows for complete reversibility.

Materials and Methods: A 24-year-old female patient presented with throbbing headaches, nausea, and vomiting starting five days after a cesarean section under spinal anesthesia. After being discharged from various centers with symptomatic treatment, she experienced generalized tonic-clonic seizures and was referred to our clinic due to recurrent episodes.Upon admission to the emergency department, she was confused with a Glasgow Coma Scale (GCS) score of 10 (E2V3M5). Vital signs were:•Blood Pressure: 135/77 mmHg •Heart Rate: 80 bpm •Temperature: 36.5°C •SpO_2: 99% No neck stiffness or focal neurological deficits were found. Laboratory tests showed mild hypokalemia (K: 3.2 mEq/L), while renal and liver functions were normal and infection markers were negative. Cranial CT showed no hemorrhage or edema. While diffusion

MRI showed no acute infarct, FLAIR sequences revealed increased signal intensity consistent with vasogenic edema in bilateral occipital, parietal, and cerebellar regions. MR venography ruled out sinus thrombosis.The patient, evaluated as being in status epilepticus after two seizures in the emergency room, was treated with intravenous diazepam followed by phenytoin (20 mg/kg). Blood pressure and electrolyte balance were stabilized. Following the diagnosis of PRES, the patient's clinical status improved, seizures ceased, and consciousness returned to normal.

Results and Conclusion: While the pathogenesis of PRES is not fully elucidated, cerebral autoregulation failure and endothelial dysfunction are the most likely mechanisms, leading to blood-brain barrier breakdown and vasogenic edema. MRI is the gold standard for diagnosis. Treatment focuses on controlled blood pressure reduction, seizure management, and addressing underlying causes. Early diagnosis and management typically lead to a good prognosis and full recovery.

Keywords: confusion, encephalopathy, seizures

Ref No: 4954

Severe hyponatremia as the first manifestation of occult lung malignancy

Erdem Zeki Karabulut[1], Mevlana Gül[1], Batuhan Özbek[1]

[1]Ataturk University

Erdem Zeki Karabulut / Ataturk University

Introduction and Purpose: Hyponatremia is one of the most common electrolyte abnormalities encountered in the emergency department. In some cases, it may be the first clinical manifestation of an underlying malignancy, particularly through the mechanism of syndrome of inappropriate antidiuretic hormone secretion (SIADH).

Materials and Methods: A 60-year-old female presented with nausea, vomiting, progressive fatigue, and mild confusion. There was no known history of chronic disease. On examination, she appeared euvolemic. Laboratory findings revealed severe hyponatremia (serum sodium: 114 mmol/L), low serum osmolality, and inappropriately elevated urine osmolality and sodium levels, consistent with SIADH. Thyroid and adrenal function tests were within normal limits. Given the suspicion of paraneoplastic SIADH, thoracic computed tomography was performed and revealed a suspicious lung mass.

Materials and Methods: The patient was managed with controlled sodium correction and fluid restriction. Further oncological evaluation and biopsy confirmed small cell lung carcinoma. This case illustrates that severe hyponatremia may be the initial presentation of an occult malignancy. Emergency physicians should consider SIADH in the differential diagnosis of euvolemic hyponatremia and investigate potential underlying causes promptly.

Keywords: Hyponatremia, SIADH, lung cancer

Ref No: 4957

Urban Animal Exposures and Rabies Post-Exposure Prophylaxis: Insights from a Metropolitan Emergency Department

Cansel Askin[1], Behcet Al[1]

[1]Istanbul medeniyet University

Cansel Askin / Istanbul medeniyet University

Introduction and Purpose: Background:Rabies remains a major zoonotic disease worldwide, particularly in regions with large populations of free-roaming animals. In urban settings, animal-related injuries constitute a substantial healthcare burden and frequently result in the administration of rabies post-exposure prophylaxis (PEP). This study aimed to evaluate the epidemiological characteristics of animal exposures and real-world PEP practices in a metropolitan emergency department.

Urban Animal Exposures and Rabies Post-Exposure Prophylaxis: Insights from a Metropolitan Emergency Department

	n (%)/ Mean ± SD	% / Median (min.-max.)
Age	28.79 ± 17.33	26 (0- 89)
Sex		
Female	1126(57.4)	57.4
Male	834(42.6)	42.6
Mode of presentation		

Primary presentation	1727(88.1)	88.1
Referred from another healthcare facility for vaccination	233(11.9)	11.9
Occupation		
Child	229(11.7)	11.7
Student	544(27.8)	27.8
Worker	103(5.3)	5.3
Officer	285(14.5)	14.5
Retired	93(4.7)	4.7
Housewife	90(4.6)	4.6
Other	616(31.4)	31.4

Table 1. Demographic Characteristics of the Study Population (n = 1960)

Characteristics of Animal Exposure and Injury (n = 1960)

	n (%)
Location of incident	
Home	372 (19)
Garden	293(15)
Street	877 (44.8)
Open area	7 (0.4)
Forest	6 (0.3)
Other	

	403 (20.6)
Animal involved	
Cat	1691(86.3)
Dog	254(13)
Rabbit	2(0.1)
Mouse	3(0.2)
Horse	3(0.2)
Monkey	4(0.2)
Bat	2(0.1)
Other	1(0.1)
Mechanism of exposure	
Bite	363 (18.5)
Scratch	1597 (81.5)
Pre-exposure prophylaxis	
No	1767 (90.2)
Yes	193 (9.8)
Animal ownership	
No (stray)	1766 (90.1)
Yes (owned)	194 (9.9)
Vaccination status of the animal	

Not vaccinated	340 (17.3)
Vaccinated	29 (1.5)
Unknown	1591 (81.2)
Outcome of the animal	
Alive	66 (3.4)
Euthanized	4 (0.2)
Died	4 (0.2)
Unknown	1886 (96.2)
Animal observation after exposure	
Not observed	1565 (79.8)
Observed	395 (20.2)
Time to presentation after exposure	
< 24 hours	1461 (74.5)
> 24 hours	499 (25.5)
Type of injury	
Superficial	1956 (99.8)
Deep	4 (0.2)

Characteristics of Animal Exposure and Injury (n = 1960)

Post-Presentation Clinical Management.

	n %

Wound care	
Not performed	43 (2.2)
Performed	1917 (97.8)
Vaccination status	
No	24 (1.2)
Yes	1936 (98.8)
Recommended vaccine doses	
0	22 (1.1)
2	151 (7.7)
4	1787 (91.2)
Vaccine doses received by the patient	
0	23 (1.2)
1	90 (4.6)
2	237 (12.1)
3	166 (8.5)
4	1444 (73.7)
Rabies immunoglobulin	
Not administered	1949 (99.4)
Administered	11 (0.6)
Tetanus prophylaxis	

No	561 (28.6)
Yes	1399 (71.4)
Surgical intervention	
No	1960 (100)
Outcome	
Discharged from the emergency department	1960 (100)

Post-Presentation Clinical Management.

Materials and Methods: Methods:This retrospective descriptive study included 1,960 patients presenting to a tertiary metropolitan emergency department between March 1 and September 1, 2025, due to suspected animal exposure. Demographic data, animal species involved, exposure mechanisms, animal ownership and vaccination status, time to presentation, and PEP practices were analyzed using descriptive statistics.

Materials and Methods: Results: Most exposures were cat-related (86.3%) and resulted from scratching (81.5%). Nearly all injuries were superficial (99.8%), while deep injuries were rare (0.2%). The majority of animals were classified as stray (90.1%), and vaccination status was unknown in 81.2% of cases. Rabies immunoglobulin was administered in only 0.6% of patients; however, rabies vaccination was initiated in 98.8%. Approximately 74.5% of patients presented within 24 hours. Post-exposure animal observation was documented in only 20.2% of cases.Conclusions:Urban animal exposures in this metropolitan setting were predominantly superficial and cat-related, yet nearly all patients received rabies vaccination. Limited animal observation and incomplete vaccination documentation appear to constrain risk stratification and may contribute to the use of precautionary PEP. Strengthening surveillance systems, improving documentation, and implementing evidence-based risk-stratification strategies are essential to optimizing rabies prophylaxis practices in urban environments.

Keywords: Rabies, animal exposure

Ref No: 4975

ELBOW DISLOCATION CAN ALSO OCCUR IN ADULTS

abdullah süha akça[1], alparslan altun[1], ibrahim özlü[1]

[1]atatürk üniversitesi acil tıp

abdullah süha akça / atatürk üniversitesi acil tıp

Introduction and Purpose: Elbow dislocations may be complete or partial and typically occur following trauma such as a fall or accident. In a complete dislocation, the joint surfaces are entirely separated, whereas in a partial dislocation, they are only partially displaced; this condition is also referred to as subluxation. Elbow dislocations are relatively uncommon. They most frequently occur when an individual falls onto an outstretched hand. Upon impact, the force is transmitted to the elbow, often accompanied by a rotational component, which may result in displacement of the joint. Complex dislocations may lead to significant bone and ligament injuries. In severe cases, the blood vessels and nerves traversing the elbow may be damaged, posing a risk of limb loss. Additionally, in patients with connective tissue disorders and increased joint mobility, such subluxations may occur even after minor trauma.

Materials and Methods: A 32-year-old male patient presented with left elbow pain after falling onto his left hand from the first floor. The patient had no known comorbidities, and vital signs were within normal limits. Physical examination revealed limited range of motion in the left elbow, deformity, and tenderness over the olecranon region. Neurovascular examination was unremarkable. Plain radiography demonstrated an elbow dislocation, and an orthopedic consultation was obtained. Closed reduction was performed under sedation. Post-reduction neurovascular examination remained normal. Computed tomography revealed a millimetric intra-articular bone fragment. The patient was discharged with symptomatic treatment and advised to follow up with orthopedics

Materials and Methods: Elbow dislocations in adults, whether resulting from direct or indirect trauma, require prompt diagnosis and appropriate management due to the complex ligamentous structures and close neurovascular relationships involved. Although relatively rare in the emergency setting, raising awareness of this condition and emphasizing the importance of follow-up advanced imaging is essential.

photo1



photo2



Keywords: trauma, drop, dislocation

Ref No: 4982

Aortic Dissection Presenting With Ischemic Leg Pain

Sabri Furkan Bulca[1], Murat Seyit[1], Atakan Yılmaz[1], Mert Özen[1], Alten Oskay[1], İbrahim Türkçüer[1]

[1]Pamukkale University Faculty of Medicine

Murat Seyit / Pamukkale University Faculty of Medicine

Introduction and Purpose: Acute aortic dissection is a highly lethal vascular emergency characterized by an intimal tear that allows blood to track into the media, creating true and false lumens. Early diagnosis and appropriate treatment significantly reduce mortality. Atypical presentations—such as loss of peripheral pulses or acute limb ischemia—may delay recognition. Therefore, aortic dissection must be excluded in patients presenting with acute extremity ischemia accompanied by chest pain.

Materials and Methods: A 63-year-old man presented with numbness and pain in the left leg after a 4–5-hour bus ride. He also reported left-sided chest pain for the previous 2 hours. He had no known medical conditions and was not taking regular medications. Vital signs were: blood pressure 165/81 mmHg, heart rate 55 bpm, and SpO_2 96%. Physical examination revealed an absent left femoral pulse and coldness in both lower extremities. Electrocardiography showed normal sinus rhythm. Bedside ultrasonography demonstrated no arterial or venous thrombus. Computed tomography angiography revealed findings consistent with aortic dissection.

CT Scan



Materials and Methods: The prevalence of aortic dissection is approximately 3 per 100,000, and mortality may reach 50% within the first 24 hours. Type A dissections require emergency surgical intervention, whereas initial medical management is recommended for Type B

dissections. In the emergency department, the hemodynamic targets are a systolic blood pressure of 100–120 mmHg and a heart rate < 60 bpm. Intravenous beta-blockers (e.g., esmolol, labetalol) are first-line therapy, with vasodilators added if needed. Urgent surgical consultation is mandatory in Type A dissection. Aortic dissection should be strongly considered in patients presenting with acute limb ischemia when chest pain is also present. Early imaging and rapid surgical evaluation reduce mortality.

Keywords: Aortic dissection, acute limb ischemia, atypical presentation.

Ref No: 5000

Intracranial Hemorrhage

Batuhan Özbek[1], Ayça Çalbay[1]

[1]Atatürk University Research Hospital

Batuhan Özbek / Atatürk University Research Hospital

Introduction and Purpose: An intracranial hemorrhage (ICH) is a life-threatening brain bleed within the skull caused by trauma, ruptured aneurysms, or high blood pressure. Symptoms include sudden severe headache, weakness, vomiting, confusion, and loss of consciousness. It requires immediate emergency medical attention, often requiring imaging (CT/MRI) and specialized neurological care.

Materials and Methods: A 45-year-old male patient with a known history of hypertension presented with a sudden onset of severe headache. On admission, his blood pressure was 205/117 mmHg. Neurological examination was unremarkable; however, the patient did not respond to analgesic treatment. Due to persistent severe symptoms, advanced brain imaging was performed. Imaging revealed an intracranial hemorrhage in the right parietal region. The patient was subsequently consulted with the Department of Neurosurgery. He was admitted to the Neurosurgery ward for planned surgical intervention.

Materials and Methods: In patients presenting with headache who do not respond to symptomatic treatment, advanced neuroimaging should be performed. It should be kept in mind that a significant proportion of intracranial hemorrhages may present solely with headache.

Keywords: headache, intracranial hemorrhage

Ref No: 5022

Type A aortic dissection presenting with atypical chest pain: a case report

Sultan Cennet Çakar[2], Gülbanu Emrem[2], Hülya Sevil[2]

[1]Afyonkarahisar Health Sciences University
[2]Afyonkarahisar Health Sciences University Hospital, Department of Emergency Medicine, Türkiye

Gülbanu Emrem / Afyonkarahisar Health Sciences University Hospital, Department of Emergency Medicine, Türkiye

Introduction and Purpose: Aortic dissection is one of the cardiovascular emergencies with high mortality despite its rarity. Due to the variability of clinical findings, diagnosis may be delayed, which increases mortality. This study aims to emphasize the diagnostic process and the importance of a multidisciplinary approach in a patient diagnosed with Type A aortic dissection presenting with atypical chest pain and mild dyspnea.

Materials and Methods: A 43-year-old male patient presented to the emergency department with mild dyspnea, atypical chest pain, and productive cough for approximately two days. The patient had no known chronic disease and was not on regular medication. Family history revealed coronary artery disease in his father.Vital signs on admission were blood pressure 140/80 mmHg, heart rate 75/min, respiratory rate 18/min, and oxygen saturation 97%. Physical examination was unremarkable. Laboratory findings showed no significant abnormalities except for mildly elevated D-dimer levels.

Materials and Methods: Electrocardiography revealed no signs of acute ischemia. Due to clinical suspicion, thoracic computed tomography angiography was performed and findings consistent with aortic dissection were observed, which were further supported by echocardiography (Figure 1) (Figure 2).The patient was closely monitored, and esmolol and nitroglycerin infusions were initiated for blood pressure control. After consultation with cardiology and cardiovascular surgery, the patient was diagnosed with Type A aortic dissection and underwent emergency surgery.Following an approximately eight-hour operation, the patient was monitored in the intensive care unit and ward and was discharged in good condition on the tenth day. Aortic dissection should be considered in patients presenting with atypical symptoms, and early imaging along with a multidisciplinary approach plays a crucial role in reducing mortality.

Dissection in the ascending aorta

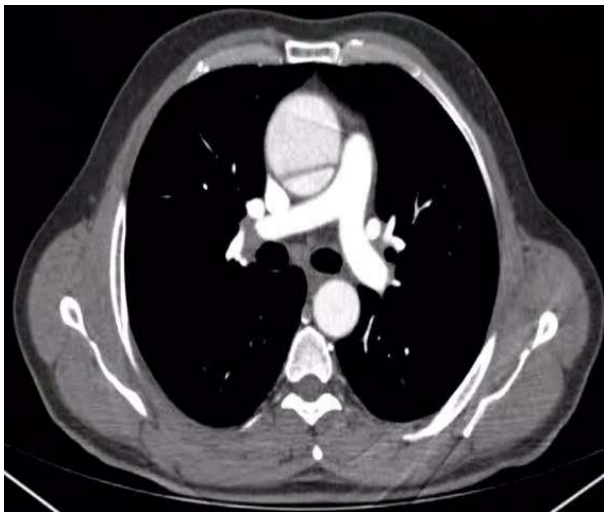

figure 1: Dissection in the ascending aorta

Dissection in the ascending aorta

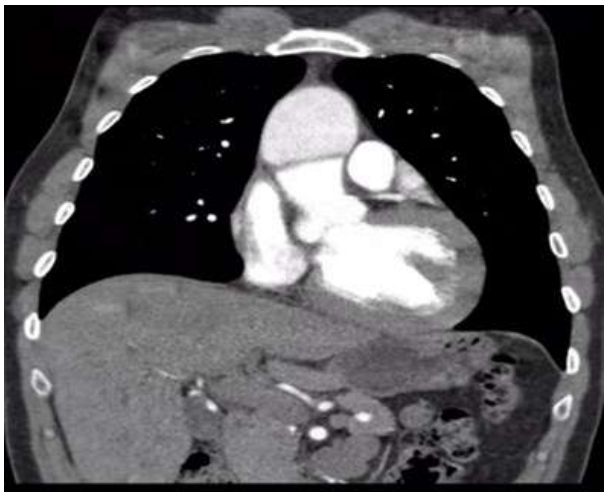

figure 2: Dissection in the ascending aorta

Keywords: Aortic dissection, chest pain, acute aortic syndrome

Ref No: 5115

Pulmonary Thromboembolism

Batuhan Özbek[1], Ayça Çalbay[1], Murteza Zafer[1]

[1]Atatürk University Research Hospital

Batuhan Özbek / Atatürk University Research Hospital

Introduction and Purpose: Acute pulmonary thromboembolism (PTE) is a clinical condition that occurs when a thrombus, most commonly originating from deep vein thrombosis (DVT), dislodges and travels through the venous system to the right heart and subsequently to the pulmonary arteries, where it causes sudden obstruction. This leads to impaired pulmonary perfusion and significant disruption in gas Exchange. This condition may result in increased pulmonary vascular resistance, right ventricular overload, hypoxemia, and, in severe cases, hemodynamic instability.

Materials and Methods: A 78-year-old immobilized female patient with a known diagnosis of ovarian cancer and a history of hysterectomy, not currently receiving active chemotherapy, presented to our department with a complaint of dyspnea. On admission, her arterial blood pressure was 82/51 mmHg and her heart rate was 120 beats per minute.On physical examination, lung sounds were normal and peripheral pulses were bilaterally equal and palpable. The left lower extremity showed increased circumference compared to the right, and Homan's sign was positive in the left leg. Laboratory tests were obtained, and Doppler ultrasonography was performed for suspected deep vein thrombosis (DVT). The ultrasound report stated: "At the level of the tibial veins, venous segments demonstrated non-compressible lumens. Hypoechoic thrombus material was present within the lumen. On color Doppler imaging, flow was markedly reduced in the affected segment." Further imaging was performed for suspected pulmonary embolism, revealing findings consistent with a segmental embolism at the level of the right main pulmonary artery. The pulmonary artery pressure (PAP) was calculated as 30 mmHg. The patient was consulted to the pulmonology department and subsequently admitted for further management.

Materials and Methods: In immobilized patients with comorbidities, deep vein thrombosis and possible pulmonary embolism should always be considered in the differential diagnosis. Clinical evaluation should be performed accordingly, and if suspicion exists, advanced imaging should be carried out promptly.

Keywords: shortness of breath

Ref No: 5149

BILATERAL SADDLE EMBOLISM DETECTED WITH LOW RISK SCORES AND ATYPICAL PRESENTATION: A CASE REPORT

ALARA NERGİZ SOSLU[1], ZEYNEP ÇAKIR[1]

[1]ATATURK UNIVERSITY FACULTY OF MEDICINE, DEPARTMENT OF EMERGENCY MEDICINE

ALARA NERGİZ SOSLU / ATATURK UNIVERSITY FACULTY OF MEDICINE, DEPARTMENT OF EMERGENCY MEDICINE

Introduction and Purpose: Pulmonary embolism (PE) is one of the most difficult clinical conditions to diagnose in emergency departments and has high mortality. Although clinical scoring systems such as Wells and PERC are frequently used in the diagnostic process, low scores do not always exclude the diagnosis of PE. Especially in young patients, atypical chest pain and mild troponin elevations may be misinterpreted as coronary syndromes.

Materials and Methods: A 34-year-old male patient presented to an external center with a stabbing sensation in the chest. Due to the troponin level being above the normal limit, he was referred to us with a preliminary diagnosis of "NSTEMI". Upon admission to our center, the patient had no active chest pain, shortness of breath, or palpitations. Vital signs were stable, and the physical examination was unremarkable.In laboratory tests, the troponin value was 26 ng/L; the 1st-hour control troponin value was 24 ng/L, showing no significant increase or decrease (delta). In the clinical evaluation, the PERC score was 0 and the Wells score was less than 2 (low risk). However, due to the presence of troponin positivity and atypical symptoms in a young patient, a contrast-enhanced computed tomography (CT) angiography was planned to exclude pulmonary pathologies. The imaging revealed a "saddle" thrombus image at the bifurcation of both main pulmonary arteries. The patient was admitted for further treatment and close monitoring.

Materials and Methods: This case emphasizes the importance of clinical suspicion and auxiliary laboratory findings (such as troponin elevation) even when clinical scoring systems indicate low risk. In young patients presenting with atypical chest pain, troponin elevation should not be attributed solely to coronary processes; massive pulmonary embolism must be ruled out in the differential diagnosis.

SADDLE PE

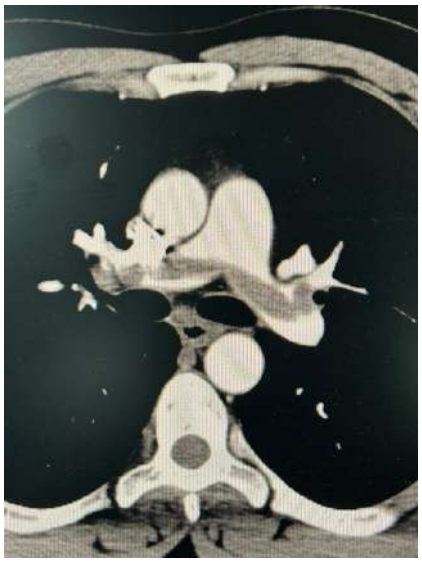

Keywords: PULMONARY EMBOLISM, SADDLE EMBOLISM, WELLS SCORE

Ref No: 5150

Secondary pneumothorax as a complication of cavitary pneumonia: a case report

Muhammet Ürgün[1], Osman Lütfi Demirci[1], Mehmet Akif Ersoy[1], Burak Polat[1], Mehmet Gül[1]

[1]Emergency Medicine Department, Konya City Hospital, Türkiye

Mehmet Akif Ersoy / Emergency Medicine Department, Konya City Hospital, Türkiye

Introduction and Purpose: Pneumonia is an infectious disease that can lead to severe complications, particularly in elderly individuals and those with comorbid conditions. Secondary pneumothorax is one of its rare but life-threatening complications. Infection-induced alveolar damage and necrosis may result in air leakage into the pleural space.

Materials and Methods: A 41-year-old male presented to the emergency department with complaints of fever, productive cough, and progressive dyspnea persisting for five days. Vital signs were as follows: Blood pressure: 100/65 mmHg, Heart rate: 112 bpm, Respiratory rate: 28 breaths/min, SpO: 88% (on room air), and Temperature: 38.2°C. Physical examination revealed decreased breath sounds in the right hemithorax and crepitant rales at the base. Chest X-ray showed opacity consistent with consolidation in the right lower lobe and a pneumothorax line in

the right hemithorax. Thoracic CT imaging revealed consolidation in the right lower lobe with focal areas of cavitation and approximately 20% pneumothorax. Management included nasal cannula oxygen therapy, broad-spectrum antibiotics, and tube thoracostomy. The patient was admitted to the ward for follow-up.

Materials and Methods: Pneumonia is rarely complicated by pneumothorax. This condition typically arises due to infection-related necrosis and cavitation. Chest X-ray and thoracic CT play a crucial role in diagnosis. The primary treatment goals are oxygen therapy, drainage (tube thoracostomy), and management of the underlying infection. Early diagnosis is life-saving; therefore, pneumothorax must be considered in pneumonia patients exhibiting clinical deterioration. This case emphasizes that although pneumonia-associated pneumothorax is rare, early diagnosis and appropriate intervention in the emergency department can significantly reduce mortality.

Keywords: Pneumonia, Pneumothorax, Emergency department

Ref No: 5171

Pneumomediastinum and Pneumopericardium After Blunt Trauma

Mevlüt Zengin[1], Umut Ocak[1], Melih Yüksel[1], Mehmet Oğuzhan Ay[1], Yeşim İşler[1], Şüheda Yıldırım[1], Halil Kaya[1]

[1]University of Health Sciences, Bursa Yuksek Ihtisas Training and Research Hospital, Department of Emergency Medicine, Bursa/Türkiye

Mevlüt Zengin / University of Health Sciences, Bursa Yuksek Ihtisas Training and Research Hospital, Department of Emergency Medicine, Bursa/Türkiye

Introduction and Purpose: Pneumopericardium is a rare clinical condition characterized by the presence of air within the pericardial cavity and most commonly occurs as a result of thoracic trauma. Less frequently, it may develop secondary to infections, mechanical ventilation, surgical interventions, or pathologies of adjacent organs. Although it is usually a self-limiting condition, it can rarely lead to life-threatening complications such as tension pneumopericardium and cardiac tamponade.Pneumomediastinum is defined as the presence of free air within the mediastinum and may occur either spontaneously or secondary to other causes. Spontaneous pneumomediastinum typically occurs in young adults as a result of a sudden increase in intrathoracic pressure, whereas secondary pneumomediastinum is most commonly associated with thoracic trauma, tracheobronchial injuries, esophageal perforation, and intrathoracic

infections. In this study, we present a case of combined pneumopericardium and pneumomediastinum that developed after blunt chest trauma.

Materials and Methods: A 17-year-old male patient presented to the emergency department with chest pain that started approximately two hours after being struck in the chest by a ball from close range. The patient reported that the chest pain increased when leaning forward. On evaluation, vital signs were stable and no pathological findings were detected on physical examination. Laboratory tests and electrocardiography were normal. No pathology was detected on chest radiography. Due to persistent chest pain, thoracic computed tomography (CT) was performed and revealed free air within the mediastinum. The air was observed to be distributed in the paratracheal and paraesophageal regions, along the bronchovascular structures, and in a limited area surrounding the pericardium (Image 1-2). These findings were considered compatible with pneumomediastinum and pneumopericardium. The patient was evaluated by pediatric surgery and admitted for observation. During follow-up, vital signs remained stable and no complications developed. The patient was discharged uneventfully after three days.

Image 1



Free air densities in the mediastinum

Image 2

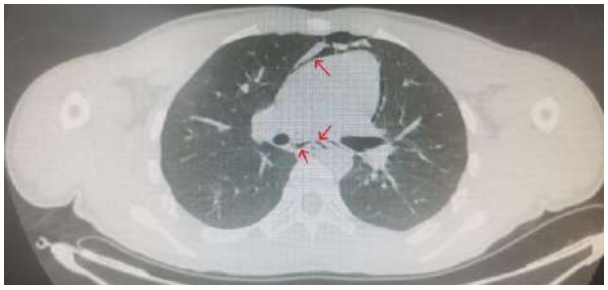

Air densities around the pericardium

Materials and Methods: It should be kept in mind that pneumomediastinum and pneumopericardium may develop even in patients with normal vital signs after blunt chest trauma. CT is the most sensitive diagnostic method, and early diagnosis with appropriate clinical follow-up leads to successful outcomes in most cases.

Keywords: Pneumomediastinum, Pneumocardium, Emergency Department

---

Ref No: 5284

Multi-algorithm consensus clustering identifies subphenotypes in sepsis-associated acute kidney injury

Shuang Chen[1], Xiancheng Xu[1], Guang Li[3], Qingzhan Zeng[1], Canlin Li[4], Xiaoyue Li[5], Shaohong Li[1], Heng Li[3]

[1]Department of Emergency medicine, Songshan Lake TungWah Hospital
[2]Guangdong Medical University
[3]Department of Cardiology, Dongguan Songshan Lake TungWah Hospital
[4]Department of Cardiology, Dongguan TungWah Hospital
[5]Department of Intensive care Unit, the Fifth Affiliated Hospital of Zunyi Medical University
[6]Key Laboratory of Coronary Intraluminal Imaging and Functional Analysis of Dongguan City

Shuang Chen / Department of Emergency medicine, Songshan Lake TungWah Hospital

Introduction and Purpose: Sepsis-associated acute kidney injury (SA-AKI) is a highly heterogeneous syndrome with variable clinical trajectories and outcomes. Conventional staging systems, such as KDIGO, fail to capture this heterogeneity, limiting risk stratification and personalized management.We aimed to identify reproducible SA-AKI subphenotypes using unsupervised machine learning on routinely collected clinical data and to characterize their clinical profiles and prognostic implications.

Materials and Methods: We conducted a retrospective cohort study of 9,029 adult patients with SA-AKI from the MIMIC-IV v3.1 database. Within the 24-hour period before and after the diagnosis of SA-AKI , 19 core clinical variables—including vital signs and laboratory values — were extracted. A multi-algorithm consensus clustering framework integrating K-means, hierarchical clustering, and K-medoids was applied to identify subphenotypes. Cluster stability was assessed using consensus strength, entropy, and silhouette analysis, with visualization via t-SNE. Key discriminative features were identified using XGBoost with SHapley Additive

exPlanations (SHAP). Primary outcome was in-hospital mortality; secondary outcome was 30-day survival.

Materials and Methods: Four robust SA-AKI subphenotypes were identified: Subphenotype I (Hypoinflammatory): preserved oxygenation (SpO2≈100%), low inflammation (WBC 8.9×109/L), hospital mortality 16.4%; Subphenotype II (Stable): highest urine output (470 mL/6h), lowest mortality (14.3%); Subphenotype III (Hyperdynamic): elevated heart/respiratory rates, impaired oxygenation (SpO2≈96%), mortality 21.6%; Subphenotype IV (Critical): severe renal dysfunction (creatinine 2.2 mg/dL, urine output 253.5 mL/6h), coagulopathy, metabolic acidosis, and highest mortality (34.2%).Kaplan-Meier analysis confirmed significant differences in 30-day survival across subphenotypes (log-rank $P < 0.0001$), with Subphenotype IV showing the poorest prognosis (median survival: ~18 days).Unsupervised consensus clustering reveals four clinically meaningful SA-AKI subphenotypes with markedly different outcomes. The "Critical" subphenotype is identifiable by routine parameters and warrants early aggressive intervention. This framework supports precision phenotyping for risk stratification and future targeted trials in SA-AKI.

Keywords: Sepsis-associated acute kidney injury; subphenotyping; consensus clustering; machine learning.

Ref No: 5285

Nonketotic Hyperosmolar State Presenting With Altered Mental Status: A Case Report

Oğuz Yılmaz[1], Murat Seyit[1], Alten Oskay[1], Atakan Yılmaz[1], Mert Özen[1], İbrahim Türkçüer[1]

[1]Pamukkale University Faculty of Medicine

Murat Seyit / Pamukkale University Faculty of Medicine

Introduction and Purpose: Nonketotic hyperosmolar state (NKHS) is a life-threatening metabolic complication of diabetes mellitus, characterized by severe hyperglycemia, hyperosmolality, and altered mental status without significant ketosis. It is most commonly observed in elderly patients and requires prompt recognition and intensive management.

Materials and Methods: An 88-year-old female patient was brought to the emergency department due to acute deterioration in general condition that began the previous night. Her medical history was significant for Alzheimer's dementia and diabetes mellitus. Physical Examination and Vital Signs: On admission, the patient's Glasgow Coma Scale score was 12.

Vital signs were within normal limits. Capillary blood glucose level was measured at 800 mg/dL. Laboratory and Imaging Findings: Urinalysis revealed negative ketone levels. Neuroimaging, including non-contrast brain computed tomography and diffusion-weighted magnetic resonance imaging, showed no acute pathology. Diagnosis and Treatment: Based on severe hyperglycemia, absence of ketosis, and altered mental status, the patient was diagnosed with nonketotic hyperosmolar state. Appropriate medical treatment was initiated, including intravenous fluids and insulin therapy. Clinical Course: The patient was admitted to the internal medicine intensive care unit for close monitoring and continued management.

Materials and Methods: Nonketotic hyperosmolar state should be considered in diabetic patients presenting with acute mental status changes. Early diagnosis and aggressive metabolic correction are essential to reduce morbidity and mortality.

Keywords: Hyperosmolar Hyperglycemic State, Altered Mental Status, Diabetes Mellitus

---

Ref No: 5303

Pulmonary embolism presenting with syncope in a young patient

İbrahim köroğlu Kılıç[1]

[1]Atatürk üniversitesi

İbrahim köroğlu Kılıç / Atatürk üniversitesi

Introduction and Purpose: Pulmonary embolism (PE) is a life-threatening condition that may present atypically, including syncope without obvious respiratory symptoms.

Materials and Methods: A 36-year-old female presented with sudden syncope. She had mild tachycardia but no chest pain. D-dimer levels were elevated. CT pulmonary angiography confirmed PE.

Materials and Methods: PE should be included in the differential diagnosis of syncope. Early diagnosis in the ED is crucial to reduce mortality.

Keywords: Pulmonary embolism, syncope, emergency

Ref No: 5314

Complicated St-Segment Elevation Myocardial Infarction Presenting With Malignant Arrhythmia

Dilara Dikici[1], Murat Seyit[1], Alten Oskay[1], Atakan Yılmaz[1], Mert Özen[1], İbrahim Türkçüer[1]

[1]Pamukkale University Faculty of Medicine

Murat Seyit / Pamukkale University Faculty of Medicine

Introduction and Purpose: Acute coronary syndrome (ACS) is a life-threatening condition caused by acute coronary artery obstruction leading to myocardial ischemia and infarction. ST-segment elevation myocardial infarction (STEMI) represents complete coronary occlusion and carries a high risk of malignant ventricular arrhythmias and cardiac arrest, particularly in the early phase.

Materials and Methods: A previously healthy male patient in his 40s presented to the emergency department with sudden onset weakness, agitation, and atypical joint pain that began approximately 30 minutes prior to admission. The patient had no known chronic medical conditions and was staying in the hospital as a caregiver for his spouse. Electrocardiography revealed widespread ST-segment elevation in the anterior leads, consistent with acute anterior STEMI. The patient was immediately transferred to a monitored setting and received guideline-directed loading doses of 300 mg acetylsalicylic acid and 600 mg clopidogrel. During cardiology evaluation, the patient developed ventricular tachycardia and underwent synchronized cardioversion. Shortly thereafter, cardiac arrest occurred with progression to asystole. Advanced cardiac life support was initiated, and return of spontaneous circulation (ROSC) was successfully achieved. The patient was subsequently transferred to the coronary intensive care unit for urgent coronary angiography and definitive management.

Materials and Methods: This case highlights that STEMI may present with atypical symptoms and rapidly deteriorate due to malignant ventricular arrhythmias and cardiac arrest. Early recognition, prompt initiation of antiplatelet therapy, continuous cardiac monitoring, and rapid reperfusion planning are essential to improve survival and clinical outcomes.

Keywords: Acute coronary syndrome, STEMI, ventricular tachycardia

Ref No: 5407

Atypical presentation of retro-renal appendicitis in an elderly patient

Aydın Coşkun[1], Mehmet Emin Pekşen[3], Ahmet Yıldırım[3]

[1]Sivas Numune Hastanesi Acil Tıp Kliniği
[2]Sivas Cumhuriyet Üniversitesi Tıp Fakültesi Genel Cerrahi Kliniği
[3]Sivas Numune Hastanesi Genel Cerrahi Kliniği

Aydın Coşkun / Sivas Numune Hastanesi Acil Tıp Kliniği

Introduction and Purpose: Acute appendicitis is a common surgical emergency; however, atypical anatomical locations may lead to delayed or misleading clinical presentations, particularly in elderly patients. This study aims to present a case of retro-renal appendicitis with atypical physical examination findings.

Materials and Methods: A 79-year-old female patient presented with abdominal pain lasting for two days. On admission, she was conscious, oriented, and cooperative. Vital signs were as follows: blood pressure 130/90 mmHg, heart rate 110 beats/min, body temperature 37.5°C, and respiratory rate 18 breaths/min. Abdominal examination revealed a normal contour, symmetry, and absence of surgical scars, with the presence of striae. There was no defans or rebound tenderness in all four quadrants. Right costovertebral angle tenderness was positive. Bowel sounds were normoactive (4 sounds/min), and no vascular bruit was detected. Laboratory findings showed leukocytosis (15,000/mm³), neutrophilia (12,000/mm³), and elevated C-reactive protein (CRP, 73 mg/L), while other parameters were within normal limits. Contrast-enhanced abdominal computed tomography (CT) demonstrated a retro-renally located appendix measuring 11 mm in diameter with periappendiceal heterogeneity, consistent with acute appendicitis.

Atypical Appendix Location

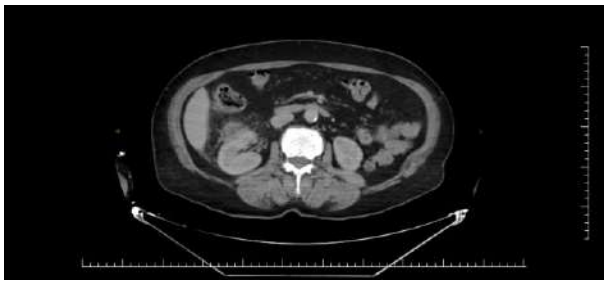

In this photograph, we attempted to show a retro-renal located appendix.

Materials and Methods: The patient underwent surgery, and perforation at the tip of the appendix was identified intraoperatively. This case highlights that atypical localization of the appendix may mask classical signs of acute appendicitis, especially in elderly patients. Careful clinical evaluation combined with imaging modalities such as CT is crucial for early diagnosis and prevention of complications.

Keywords: Acute appendicitis, Retro-renal appendix, Atypical presentation

---

Ref No: 5467

Severe hyponatremia due to syndrome of inappropriate antidiuretic hormone secretion in the emergency setting

İbrahim köroğlu Kılıç[1]

[1]Atatürk üniversitesi

İbrahim köroğlu Kılıç / Atatürk üniversitesi

Introduction and Purpose: Syndrome of inappropriate antidiuretic hormone secretion is a common cause of euvolemic hyponatremia and may present with neurological symptoms.

Materials and Methods: A 71-year-old male presented with confusion and weakness. Serum sodium level was 110 mEq/L. Serum osmolality was low, while urine osmolality was inappropriately high. Imaging suggested a possible pulmonary malignancy.

Materials and Methods: SIADH should be considered in severe hyponatremia cases. Prompt recognition and careful sodium correction are critical to prevent complications.

Keywords: Hyponatremia, SIADH, confusion

Ref No: 5470

SYNCOPE AND RUPTURED ECTOPIC PREGNANCY

Erdal Tekin[1], Hakan Alp[1], Muhammed Cengizhan Durmuş[1]

[1]Erzurum Atatürk Üniversitesi Araştırma Hastanesi

Hakan Alp / Erzurum Atatürk Üniversitesi Araştırma Hastanesi

Introduction and Purpose: Ectopic pregnancy is the implantation of a fertilized egg outside the uterine cavity (most commonly in the fallopian tubes). As the gestational material grows, it strains the tissue where it is implanted and eventually causes it to tear (rupture). This condition is a surgical emergency that can lead to massive intra-abdominal bleeding and hemorrhagic shock within minutes.

Materials and Methods: A 29-year-old female patient was brought in following syncope at her workplace after experiencing abdominal pain. Upon arrival, she was conscious but appeared pale and cold. She stated that she had been having abdominal pains for the last few days. She did not report diarrhea, constipation, nausea, or vomiting. She mentioned that her last menstrual period was 6 weeks ago; however, she was not entirely sure because she had intermittent irregular bleeding in the form of spotting. She uses an IUD (spiral) as a contraceptive method. In her admission vitals, blood pressure: 85/55, pulse: 120, respiratory rate: 22/min, temperature: 36.2. There were no significant findings in her neurological examination. Abdominal examination revealed severe tenderness in the lower quadrants and bilateral defense and rebound. Bilateral costovertebral angle tenderness was negative. Rectal examination showed stool smear. Peripheral pulses were open and equal. The ECG was in normal sinus rhythm. In her laboratory tests, Hb: 8.4 g/dl, hematocrit: 25%, and bHCG: 6500. Abdominal USG reported dense free fluid in the Douglas pouch. Due to the patient's hypotensive course and the detection of intra-abdominal free fluid, she was emergently consulted with the Obstetrics and Gynecology clinic with a pre-diagnosis of "Ruptured Ectopic Pregnancy." The patient was admitted to the Obstetrics and Gynecology Clinic and taken for emergency laparoscopy.

Materials and Methods: In every female patient of childbearing age presenting with abdominal pain and/or syncope (fainting), a pregnancy test and checking for intra-abdominal free fluid are of vital importance, even if they are using a contraceptive method.

Keywords: Abdominal Pain, Syncope, Ectopic Pregnancy.

Ref No: 5513

Carbon Monoxide Poisoning

Kadir Akburun[1], Murat Seyit[1], Atakan Yılmaz[1], Mert Özen[1], Alten Oskay[1], İbrahim Türkçüer[1]

[1]Pamukkale University Faculty of Medicine

Murat Seyit / Pamukkale University Faculty of Medicine

Introduction and Purpose: Patients presenting with dyspnea and headache accompanied by wheezing may be readily diagnosed with an asthma exacerbation. However, in carbon monoxide (CO) poisoning, pulse oximetry readings may appear normal despite significant hypoxic injury. Accurate diagnosis requires a high index of clinical suspicion and confirmation with co-oximetry.

Materials and Methods: A 33-year-old man presented in the early morning with headache, nausea, fatigue, and shortness of breath. He reported using a natural gas stove for heating at home and noted that his spouse was also experiencing mild headache. His medical history included childhood asthma. Initial auscultation revealed mild expiratory wheezing, and nebulized bronchodilator therapy was considered. However, the patient's statement that his symptoms partially improved after leaving the house raised concern for environmental exposure. Vital Signs:Blood pressure was 118/70 mmHg, heart rate 110 beats/min, respiratory rate 24 breaths/min, oxygen saturation 99% on room air, and temperature 36.4°C. Laboratory Findings:Standard arterial blood gas analysis demonstrated normal partial pressure of oxygen (pO_2). However, co-oximetry revealed an elevated carboxyhemoglobin (COHb) level of 22%. Serum lactate was 3.8 mmol/L. Troponin was negative, and complete blood count and C-reactive protein showed no significant abnormalities. Imaging and Electrocardiography:Chest radiography was unremarkable. Electrocardiography demonstrated sinus tachycardia without ischemic changes. Management: High-flow 100% oxygen was immediately administered via non-rebreather mask. Given the elevated COHb level and neurological symptoms, referral for hyperbaric oxygen therapy was arranged. Appropriate authorities were notified regarding the home gas system, and evaluation of household members was recommended.

Materials and Methods: In patients presenting with headache, nausea, and fatigue—particularly when multiple individuals in the same environment are affected—carbon monoxide poisoning must be considered. Normal pulse oximetry does not exclude significant exposure. Clinical history is paramount. Early administration of high-concentration oxygen reduces mortality and long-term neurological sequelae.

Keywords: Carbon monoxide poisoning, Carboxyhemoglobin, Co-oximetry

Ref No: 5561

The Negative Test

Kadir Eryürük[1], Murat Seyit[1], Mert Özen[1], Alten Oskay[1], Atakan Yılmaz[1], İbrahim Türkçüer[1]

[1]Pamukkale University Faculty of Medicine

Murat Seyit / Pamukkale University Faculty of Medicine

Introduction and Purpose: Lower abdominal pain accompanied by mild vaginal bleeding is a common presentation in women of reproductive age. Although urinary tract infection (UTI) may appear to be a convenient explanation, ectopic pregnancy remains a life-threatening condition that must be excluded. Importantly, urine pregnancy tests may yield false-negative results in early gestation.

Materials and Methods: A 32-year-old woman presented with a two-day history of right lower quadrant pain and spotting-type vaginal bleeding. Her last menstrual period was six weeks prior. At an outside facility, a urine pregnancy test had been reported as negative, and she was treated empirically for a presumed urinary tract infection. Due to worsening pain, she sought emergency care. She also reported dizziness and fatigue.Vital Signs: Blood pressure was 98/60 mmHg, heart rate 118 beats/min, oxygen saturation 99% on room air, and temperature 36.8°C.Physical Examination: Abdominal examination revealed marked tenderness in the right lower quadrant with minimal rebound. Pelvic examination demonstrated cervical motion tenderness and mild vaginal bleeding.Laboratory Findings: Hemoglobin was 10.8 g/dL, decreased compared to prior values. Leukocyte count was 11.6 K/µL. Serum β-human chorionic gonadotropin (β-hCG) measured 86 mIU/mL—low but positive. Urinalysis showed no significant leukocyturia or nitrites.Imaging: Transvaginal ultrasonography demonstrated no intrauterine gestational sac. A 2 cm heterogeneous mass was identified in the right adnexal region, along with free fluid in the pouch of Douglas.Management: Given borderline hemodynamic status, urgent obstetrics and gynecology consultation was obtained. Intravenous fluid resuscitation was initiated. Due to suspected rupture, the patient underwent emergent laparoscopic exploration, which confirmed a right tubal ectopic pregnancy. Salpingectomy was performed.

Materials and Methods: In women of reproductive age presenting with abdominal pain, pregnancy must be excluded before attributing symptoms to urinary tract infection. Even when urine testing is negative, early ectopic pregnancy may only be detected by serum β-hCG measurement and careful clinical assessment. Ectopic pregnancy should always remain in the differential diagnosis of lower abdominal pain.

Keywords: Abdominal examination, Urgent obstetrics and gynecology, Ectopic pregnancy

Ref No: 5623

Pelvic Fracture Associated With Genitourinary Injury

Mustafa Erkam Dut[1], Murat Seyit[1], Atakan Yılmaz[1], Mert Özen[1], Alten Oskay[1], İbrahim Türkçüer[1]

[1]Pamukkale University Faculty of Medicine

Murat Seyit / Pamukkale University Faculty of Medicine

Introduction and Purpose: Pelvic fractures secondary to high-energy trauma are frequently associated with concomitant genitourinary injuries. Prompt and systematic evaluation is essential to prevent delayed complications.

Materials and Methods: A 22-year-old male was brought to the emergency department following a motorcycle collision with a motor vehicle. He was wearing a helmet at the time of the accident. On admission, he was conscious, oriented, and hemodynamically stable with a Glasgow Coma Scale score of 15. Physical examination revealed significant tenderness on palpation of the pelvic region without gross deformity. There was no vertebral tenderness and lung auscultation was normal. Pelvic imaging demonstrated multiple fracture lines involving the pelvic ring. Computed tomography further revealed heterogeneous density changes extending to the left paravesical, inguinal, and scrotal regions, compatible with soft-tissue hematoma. Urinalysis showed 3+ erythrocytes, raising suspicion for lower urinary tract injury. Scrotal ultrasonography confirmed hematoma formation with preserved vascular perfusion of the testis and epididymis.

pelvic X-ray



pelvic X-ray

Materials and Methods: Multidisciplinary consultation with orthopedics and urology was performed. As there was no evidence of active bleeding or testicular ischemia, conservative management was preferred. This case emphasizes the importance of evaluating the urinary system in patients with pelvic trauma, even when hemodynamic parameters are stable.

Keywords: Pelvic fracture, Genitourinary trauma, Hematuria

Ref No: 5629

Hypoglycemia: A Single Drop of Blood Before Imaging

Kadir Eryürük[1], Murat Seyit[1], Duygu Aras Seyit[2], Mert Özen[1], Alten Oskay[1], Atakan Yılmaz[1]

[1]Pamukkale University Faculty of Medicine
[2]ERPA Saglik Hospital, Denizli

Murat Seyit / Pamukkale University Faculty of Medicine

Introduction and Purpose: Acute dizziness, ataxia, and speech disturbance frequently activate stroke protocols in the emergency department. However, metabolic causes—particularly hypoglycemia—can closely mimic focal neurological deficits and are rapidly reversible when promptly recognized.

Materials and Methods: A 62-year-old woman presented with severe dizziness, imbalance, and slurred speech lasting one hour. A relative reported gait instability and brief confusion. Her medical history included type 2 diabetes mellitus treated with insulin and metformin. She described poor oral intake for two days and stated that she had administered insulin the previous evening without adequate food intake. A stroke alert was initiated on arrival.Vital Signs: Blood pressure 152/86 mmHg, heart rate 96 beats/min, SpO_2 97%, temperature 36.6°C.Neurological Examination: Wide-based gait, marked ataxia, and mild dysarthria were noted. Pupils were isochoric and reactive. No focal motor weakness was present. NIHSS was low-to-moderate.Point-of-Care Testing and Laboratory Findings: Capillary blood glucose was 38 mg/dL and confirmed by serum measurement at 42 mg/dL. Electrolytes and renal function were within acceptable limits; lactate was 1.9 mmol/L. Troponin was negative.Imaging: Neuroimaging was deferred until correction of hypoglycemia. After clinical improvement, a non-contrast cranial CT showed no evidence of acute hemorrhage or established infarction.Management: Intravenous 20% dextrose bolus was followed by 10% dextrose infusion, maintaining glucose levels between 120–160 mg/dL. Neurological symptoms improved markedly within 15–20 minutes. Insulin

dosing was reviewed, and patient education regarding hypoglycemia prevention was provided. She was discharged after observation.

Materials and Methods: In suspected acute stroke, immediate capillary glucose measurement is essential. Hypoglycemia can present with focal neurological deficits yet is rapidly reversible. Early recognition prevents misdiagnosis, unnecessary imaging delays, and potential morbidity. A single drop of blood before imaging may be lifesaving.

Keywords: Hypoglycemia, Acute stroke, Acute dizziness

Ref No: 5653

Recurrent Hypoglycemia Presenting With Neurological Manifestations

Mustafa Erkam Dut[1], Murat Seyit[1], Duygu Aras Seyit[2], Atakan Yılmaz[1], Mert Özen[1], Alten Oskay[1]

[1]Pamukkale University Faculty of Medicine
[2]ERPA Saglik Hospital, Denizli

Mustafa Erkam Dut / Pamukkale University Faculty of Medicine

Introduction and Purpose: Hypoglycemia is a metabolic emergency that may present with a wide spectrum of neurological and autonomic symptoms. Early bedside recognition is essential to prevent irreversible neurological damage.

Materials and Methods: A 78-year-old female was brought to the emergency department with complaints of numbness in the hands and feet accompanied by perioral tingling. Symptoms had started approximately one day prior to admission. She denied syncope or trauma. On examination, she was conscious, cooperative, and fully oriented. Vital signs were within normal limits. Neurological examination revealed no focal deficits and muscle strength was preserved in all extremities. Electrocardiography demonstrated normal sinus rhythm. Capillary blood glucose measurement was 38 mg/dL. Intravenous dextrose was administered, resulting in transient symptomatic improvement. However, recurrent episodes of hypoglycemia occurred after cessation of infusion, necessitating continuous glucose replacement therapy and close monitoring.

The patient's biochemical laboratory results

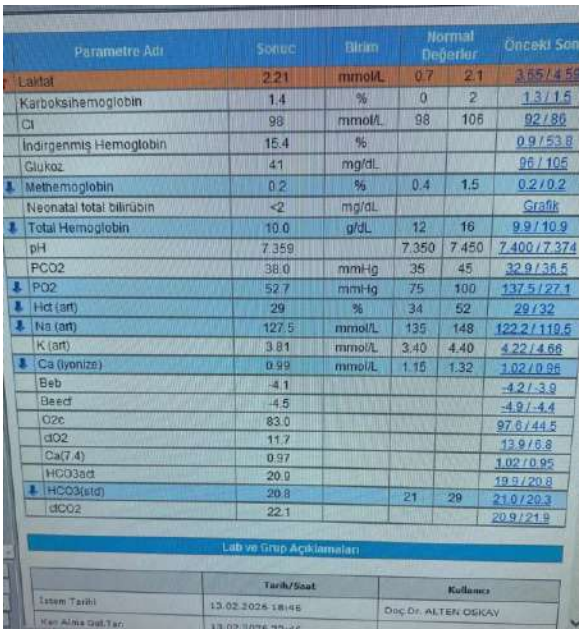

Parametre Adı	Sonuç	Birim	Normal Değerler		Önceki Sonuç
Laktat	2.21	mmol/L	0.7	2.1	3.65 / 4.55
Karboksihemoglobin	1.4	%	0	2	1.3 / 1.5
Cl	98	mmol/L	98	106	92 / 86
İndirgenmiş Hemoglobin	15.4	%			0.9 / 53.8
Glukoz	41	mg/dL			96 / 105
Methemoglobin	0.2	%	0.4	1.5	0.2 / 0.2
Neonatal total bilirübin	<2	mg/dL			Grafik
Total Hemoglobin	10.0	g/dL	12	16	9.9 / 10.9
pH	7.359		7.350	7.450	7.400 / 7.374
PCO2	38.0	mmHg	35	45	32.9 / 36.5
PO2	52.7	mmHg	75	100	137.5 / 27.1
Hct (art)	29	%	34	52	29 / 32
Na (art)	127.5	mmol/L	135	148	122.2 / 119.5
K (art)	3.81	mmol/L	3.40	4.40	4.22 / 4.66
Ca (iyonize)	0.99	mmol/L	1.15	1.32	1.02 / 0.86
Beb	-4.1				-4.2 / -3.9
Beecf	-4.5				-4.9 / -4.4
O2c	83.0				97.6 / 44.5
dO2	11.7				13.9 / 6.8
Ca(7.4)	0.97				1.02 / 0.95
HCO3act	20.9				19.9 / 20.8
HCO3(std)	20.8		21	29	21.0 / 20.3
dCO2	22.1				20.9 / 21.9

Lab ve Grup Açıklamaları

	Tarih/Saat	Kullanıcı
İstem Tarihi	13.02.2026 18:46	Doç.Dr. ALTEN OSKAY
Kan Alma Dat.Tar.		

The patient's biochemical laboratory results

Materials and Methods: The patient was admitted for further etiological investigation and metabolic stabilization. This case underlines the importance of routine glucose measurement in patients presenting with nonspecific neurological complaints, particularly in the elderly population.

Keywords: Hypoglycemia, Elderly patient, Emergency diagnosis

Ref No: 5660

Tricuspid Valve Infective Endocarditis in an Intravenous Drug User: A Case Report

Sabri Furkan Bulca[1], Murat Seyit[1], Alten Oskay[1], Atakan Yılmaz[1], Mert Özen[1], İbrahim Türkçüer[1]

[1]Pamukkale University Faculty of Medicine

Murat Seyit / Pamukkale University Faculty of Medicine

Introduction and Purpose: Infective endocarditis (IE) is an infection of the endocardial surface of the heart and is a severe clinical condition associated with high mortality. Intravenous (IV) drug use is a major risk factor for right-sided valve involvement. This case report presents infective endocarditis with tricuspid valve vegetation in a young patient with a history of IV substance use.

Materials and Methods: A 25-year-old man presented to the emergency department with chest pain, shortness of breath, cough, sputum production, and fever for two days. Past medical history was notable for chronic hepatitis C and IV drug use for eight years. It was learned that he had been hospitalized for one week at an addiction treatment center (AMATEM) at an outside facility and was discharged four days prior. Vital signs were: temperature 36.6°C, SpO_2 90%, heart rate 121/min, and blood pressure 109/69 mmHg. On physical examination, breath sounds were normal with no rales or rhonchi; the remainder of the systemic examination was unremarkable. Electrocardiography showed sinus tachycardia. Portable echocardiography demonstrated a left ventricular ejection fraction (LVEF) of 55% and a suspicious finding consistent with a vegetation measuring 23 × 21 mm on the tricuspid valve. Arterial blood gas analysis revealed hypoxemia. Consultations were obtained from pulmonology, cardiology, infectious diseases, and cardiovascular surgery. With a preliminary diagnosis of infective endocarditis, three sets of blood cultures were collected. Empirical antibiotic therapy with vancomycin, ampicillin, and ampicillin–sulbactam was initiated. Intensive care unit follow-up was planned.

Materials and Methods: Right-sided endocarditis is common among IV drug users, and the tricuspid valve is the most frequently affected valve. Large vegetations (> 20 mm) are clinically important due to increased embolic risk. Early empirical antibiotic therapy and a multidisciplinary approach play a critical role in reducing mortality. Infective endocarditis should be considered in IV drug users who present at a young age with pulmonary symptoms.

Keywords: Infective endocarditis, tricuspid valve, intravenous drug use.

Ref No: 5669

Delayed Tension Pneumocephalus Following Craniotomy: A Rare Postoperative Complication

Enes Topaloğlu[1], Özlem Bilir[1]

[1]Recep Tayyip Erdoğan University Training and Research Hospital, Department of Emergency Medicine, Rize, Türkiye

Enes Topaloğlu / Recep Tayyip Erdoğan University Training and Research Hospital, Department of Emergency Medicine, Rize, Türkiye

Introduction and Purpose: Pneumocephalus is a clinical condition characterized by the presence of air in the intracranial spaces or brain parenchyma and most commonly occurs after head trauma or surgical interventions. Most cases are asymptomatic or mildly symptomatic, but rarely progress to tension pneumocephalus with increased intracranial pressure, which can be life-threatening. The aim of this case report is to emphasize the late development of tension pneumocephalus after craniotomy and the importance of diagnostic approach in the emergency department.

Materials and Methods: A 56-year-old man was admitted to the emergency department with complaints of involuntary movements, numbness and weakness in the left leg for about ten days. His past medical history included hypertension, diabetes mellitus and a history of craniotomy for intracranial mass two months ago. The patient also described an intracranial "rippling sensation" during head movements. On physical examination, general condition was good, Glasgow Coma Score was 15 and vital signs were stable. No lateralizing findings were found on neurological examination. Laboratory tests revealed no significant pathology except leukocyte and neutrophil predominance. Non-contrast brain computed tomography showed a craniotomy defect in the right frontal bone and diffuse free air images consistent with pneumocephalus in the subdural space adjacent to this region. No midline shift was found. The patient was hospitalized in the neurosurgery clinic with a prediagnosis of tension pneumocephalus for further evaluation and treatment planning.

Figure 1

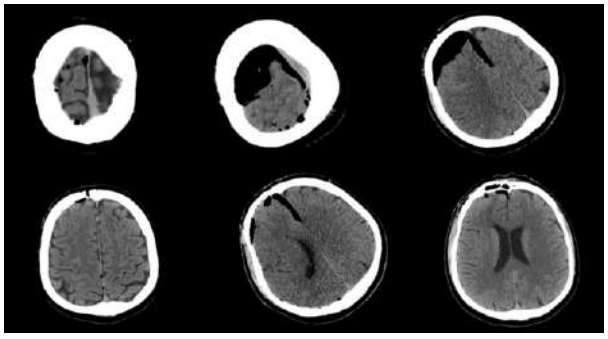

Non-contrast brain CT shows free air consistent with pneumocephalus extending from the right frontal region through the right cerebral hemisphere

Results and Conclusion: Pneumocephalus is an important diagnosis that should be considered in emergency department evaluation, especially in patients with a history of craniotomy or head

trauma. In late-onset cases, symptoms may be nonspecific and the diagnosis may be delayed. Therefore, the possibility of pneumocephalus should be considered in the presence of atypical neurologic complaints in the post-operative period and evaluation with rapid imaging methods should be performed. Early diagnosis and appropriate multidisciplinary approach play a critical role in preventing potentially life-threatening complications.

Keywords: pneumocephalus, craniotomy, tension pneumocephalus

Ref No: 5693

Neurological complications of extreme hyponatremia: a case of seizure and respiratory failure in the emergency department

Mustafa Arar[1], Fatih Cemal Tekin[1], Hatice Yollar[1], Osman Lütfi Demirci[1], Mehmet Gül[1]

[1]Emergency Medicine Department, Konya City Hospital, Türkiye

Hatice Yollar / Emergency Medicine Department, Konya City Hospital, Türkiye

Introduction and Purpose: Hyponatremia is the most frequently encountered electrolyte abnormality in emergency departments. However, cases where the sodium level drops below 100 mEq/L are rare in the literature and typically present with severe neurological complications. In this presentation, we report a case of profoundly severe hyponatremia resulting from thiazide diuretic use and malnutrition, along with the subsequent clinical course.

Materials and Methods: A 51-year-old male patient was brought to our emergency department due to unresponsiveness to his surroundings. His medical history revealed a diagnosis of hypertension, the use of a thiazide-type diuretic, and an active smoking history. Physical examination revealed a blood pressure of 120/80 mmHg, a heart rate of 78 beats/min, a temperature of 36.6°C, and an oxygen saturation (SpO2) of 96%. His Glasgow Coma Scale (GCS) score was 14, and the patient was mildly confused. Laboratory and imaging results: Blood gas analysis revealed a sodium (Na) level of 87 mEq/L, which was confirmed as 90 mEq/L on a follow-up test. Brain CT and Diffusion MRI, performed to investigate the etiology of his altered mental status, revealed no acute pathology. During his clinical course, an infusion of 3% hypertonic saline was initiated under emergency conditions. During the observation period, the patient experienced a generalized tonic-clonic seizure. Due to clinical deterioration, inadequate respiratory effort, and a decline in consciousness (GCS < 8) post-seizure, the patient was intubated. Following a consultation with the internal medicine department, the patient was admitted to the internal medicine intensive care unit for further monitoring and treatment.

Materials and Methods: Profound hyponatremia(< 120 mEq/L) requires emergency intervention due to the risk of cerebral edema and neurological damage. The value of 87 mEq/L observed in this case is one of the lowest sodium levels reported in the literature. Irregular nutrition associated with the patient's occupation (truck driving) and thiazide use were considered the primary contributing factors to the profound depth of this clinical picture. Profound hyponatremia can lead to life-threatening conditions such as seizures and respiratory failure. In at-risk patients who use thiazides and have compromised nutrition, the electrolyte panel must be meticulously evaluated, even if their vital signs are stable.

Keywords: Profound Hyponatremia, Thiazide Diuretics, Confusion

---

Ref No: 5717

Pulmonary embolism

Yunus Emre Ek[1], Ayça ÇALBAY[1]
[1]ATATÜRK ÜNİVERSİTESİ

Yunus Emre Ek / ATATÜRK ÜNİVERSİTESİ

Introduction and Purpose: Pulmonary embolism (PE) is a relatively common cardiovascular emergency. It can cause acute, life-threatening but potentially reversible right ventricular failure due to occlusion of the pulmonary arterial bed. The diagnosis of PE is difficult and may be missed because it does not present with a specific clinical picture.

Materials and Methods: A 75-year-old woman presented to us with sudden dizziness followed by fainting while at home. The patient had a known diagnosis of esophageal ca and had hypotension, tachycardia and hypoxia on admission vitals. There was no pathology on systemic examination, but thoracic imaging revealed bilateral pulmonary embolism. The patient was consulted to the relevant clinic. His treatment was organized by the relevant clinic.

BT

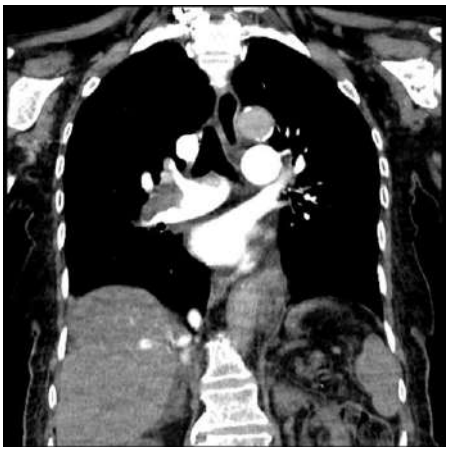

Materials and Methods: Pulmonary embolism should be kept in mind in patients presenting to the emergency department with syncope if the vitals and risk status are compatible.

Keywords: Pulmonary embolism, tachycardia, hypoxia

Ref No: 5721

Hyperosmolar Hyperglycemıc State (Hhs)

Büşra Nur Gülbahar Minisker[1], Murat Seyit[1], Duygu Aras Seyit[2], Mert Özen[1], Alten Oskay[1], Atakan Yılmaz[1]

[1]Pamukkale University Faculty of Medicine
[2]ERPA Saglik Hospital, Denizli

Murat Seyit / Pamukkale University Faculty of Medicine

Introduction and Purpose: Hyperosmolar hyperglycemic state (HHS) is a diabetic emergency that can present with dehydration and altered mental status, particularly in elderly patients with comorbidities. Because it may occur without ketosis or acidosis, it can be overlooked. The mainstays of treatment are fluid resuscitation and insulin; however, initiating insulin in the presence of concomitant hypokalemia may increase the risk of arrhythmias due to insulin-driven intracellular potassium shift.

Materials and Methods: A 76-year-old woman with a history of hypertension, diabetes mellitus, asthma, coronary artery disease, and a permanent pacemaker presented to the

emergency department with dry mouth, loss of appetite, and fluctuating mental status. Her admission blood glucose was 798 mg/dL. The ECG showed a paced rhythm, and the neurological examination was unremarkable. A non-contrast brain CT performed to exclude central nervous system pathology revealed no acute abnormalities. Laboratory tests showed sodium 121 mEq/L, potassium 2.49 mEq/L, serum osmolality 326 mOsm/kg, pH 7.45, bicarbonate (HCO_3^-) 30 mEq/L, and negative ketones. Based on the clinical presentation and biochemical findings, she was diagnosed with hyperosmolar hyperglycemic state (HHS). Fluid resuscitation was initiated. Due to hypokalemia, a central venous catheter was placed and potassium replacement was administered. After the potassium level increased to 3.5 mEq/L, an insulin infusion was started with concurrent potassium supplementation.

Materials and Methods: This case illustrates that HHS in elderly patients with multiple comorbidities may present with nonspecific complaints and neurological symptoms, and can be easily confused with primary neurological conditions. In addition, concomitant hypokalemia (K: 2.49 mEq/L) played a critical role in determining the treatment strategy in our patient. Because insulin promotes an intracellular shift of potassium, early initiation of an insulin infusion in the presence of hypokalemia may predispose to serious complications such as malignant arrhythmias and hemodynamic instability.

Keywords: Hyperosmolar hyperglycemic state, Hypokalemia, Altered mental status.

Ref No: 5731

Acute Appendicitis

Batuhan Özbek[1], Ayça Çalbay[1]

[1]Atatürk Üniversitesi Research Hospital

Batuhan Özbek / Atatürk Üniversitesi Research Hospital

Introduction and Purpose: Appendicitis is inflammation of the appendix. Symptoms commonly include right lower abdominal pain, nausea, vomiting, fever and decreased appetite. However, approximately 40% of people do not have these typical symptoms. Severe complications of a ruptured appendix include widespread, painful inflammation of the inner lining of the abdominal wall and sepsis.

Materials and Methods: A 27-year-old male patient with no known chronic diseases presented to our department with complaints of abdominal pain, dysuria, and vomiting. On admission, his

vital signs were stable. Physical examination revealed tenderness and guarding in the right lower quadrant of the abdomen. Laboratory investigations showed a white blood cell count (WBC) of 13,800/mm³ and neutrophils of 9,890/mm³. Urinalysis demonstrated 65 leukocytes and leukocyte esterase positivity (+1) The patient's Alvarado score was measured as 8.Further imaging with computed tomography (CT) revealed increased wall thickness of the appendix and surrounding fat stranding. The maximal appendiceal diameter was measured at 8.5 mm. Based on these findings, the patient was consulted to the general surgery department and subsequently hospitalized.

Materials and Methods: Although acute appendicitis can sometimes be confused with urinary tract infections, patients presenting with findings suggestive of acute appendicitis should be evaluated using the Alvarado scoring system. In cases with diagnostic uncertainty, advanced imaging modalities should be performed.

Keywords: stomacache, acute appendicitis

Ref No: 5764

Alcohol Withdrawal Syndrome – Delirium Tremens

Taner Küçücük[1], Murat Seyit[1], Mert Özen[1], Alten Oskay[1], Atakan Yılmaz[1], İbrahim Türkçüer[1]

[1]Pamukkale University Faculty of Medicine

Murat Seyit / Pamukkale University Faculty of Medicine

Introduction and Purpose: Delirium tremens is a clinical condition that develops within a few hours to several days after the cessation or reduction of prolonged and heavy alcohol consumption. It is characterized by the presence of at least two of the following symptoms: autonomic hyperactivity, increased hand tremor, insomnia, nausea/vomiting, transient visual, auditory, or tactile hallucinations or illusions, psychomotor agitation, anxiety, and generalized tonic-clonic seizures.

Materials and Methods: A 50-year-old male presented with complaints of altered consciousness, visual hallucinations, and seizures for four days. It was learned that the patient had been receiving active psychotherapy for alcohol cessation, had not consumed alcohol for the past 10 days, and had a history of regular alcohol use for 30 years.Upon arrival at the emergency department, his general condition was moderate. Glasgow Coma Scale (GCS) was 13 (E3M6V4), and he was drowsy. Pupillary light reflexes were bilaterally normal. Neurological

examination was unremarkable, with no lateralizing deficits.Vital signs were as follows: Blood pressure: 117/65 mmHg, Heart rate: 82 beats/min, Temperature: 36.1°C, Respiratory rate: 18/min, Oxygen saturation: 96%.Electrocardiography showed normal sinus rhythm. Blood glucose level was 55 mg/dL. Other laboratory findings were within normal limits. Cranial imaging revealed no acute pathology. As the patient's CIWA-Ar score was high, he was admitted to the intensive care unit for close monitoring and treatment.

Materials and Methods: Delirium tremens should always be considered a medical emergency, as it can be fatal if left untreated. Death usually occurs due to failure of effective thermoregulation, cardiac arrhythmias, worsening alcohol withdrawal–related seizures, and/or exacerbation of pre-existing medical conditions.Such patients must be hospitalized and closely monitored in a psychiatric ward or intensive care unit.

Keywords: Altered consciousness, Alcohol withdrawal syndrome, Delirium tremens

---

Ref No: 5765

BILATERAL FEMUR NECK FRACTURE IN A PATIENT PRESENTING WITH SUDDEN ONSET OF GAIT IMPAIRMENT

Rümeysa düşünceli[1], Nevzat HERGÜL[1], SEVDEGÜL KARADAŞ[1]

[1]Yuzuncu Yil University, Medical School Hospital, Van, Turkey

Nevzat HERGÜL / Yuzuncu Yil University, Medical School Hospital, Van, Turkey

Introduction and Purpose: Bilateral femur neck fracture (BFN) is rarer than unilateral femur neck fracture. The literature reports a limited number of cases, including soldiers and athletes under high physical activity, individuals with seizures such as epilepsy, and elderly or middle-aged patients with metabolic bone disease. Femur fractures are among the leading causes of hospital admissions in the elderly population and have high mortality and morbidity rates. Unlike the younger population, in elderly patients, these fractures can occur even with low-energy traumas or simple rotational movements due to decreased bone quality. In this presentation, we describe a case of a patient presenting with atypical symptoms such as abdominal pain and inability to walk, without a significant history of trauma, and diagnosed with bilateral femur neck fracture.

Materials and Methods: A 75-year-old male patient was brought to the emergency department by his relatives with an inability to walk and abdominal pain upon waking. His medical history

included ischemic stroke, dementia, COPD, and glomus tumor; there was no history of trauma. His medications were Ecopirin Pro 81 mg, Gyrex 50 mg, and Dezira 10 mg.Neurological examination revealed bilateral full upper extremity muscle strength, and bilateral lower extremity muscle strength (3/5) and painful, restricted movement. Other system examinations were normal. Laboratory parameters are presented in Table 1. Radiological imaging revealed bilateral femoral neck fractures. (Figures 1, 2, and 3). After consultation with the orthopedics department, the patient was admitted to the orthopedics ward for surgery.

Figure 1



Right femoral neck fracture

figure 2



Left femoral neck fracture

figure 3

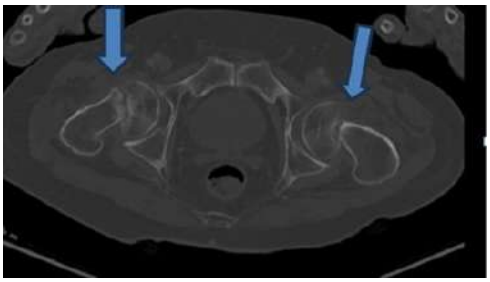

Pelvic CT scan shows bilateral femoral neck fractures

table 1

Parameters	Result	Normal Range
WBC (White Blood Cell) (10^3/uL)	10.96	3.91-10.9
HGB(Hemoglobin) (g/dl)	14.3	13-16.9
PLT(platelet)	200	166-390
C reactive protein (mg/dl)	10.1	0-5
creatinine	0.78	0.72-1.25
Alanine Aminotransferase	21	0-55
Aspartate Aminotransferase	27	5-34
Lactate Dehydrogenase	365	125-220
Troponin I	0.014	0-0.026
Creatine Kinase-MB	44.8	0-25

Blood laboratory parameters.

Results and Conclusion: Because the femoral neck region is poorly supplied with arterial blood, the likelihood of avascular necrosis after these fractures is high. Early intervention is crucial in patients. Patients with advanced age, Alzheimer's disease, dementia, etc., may not be able to provide a history of trauma. If there is no witnessed trauma, relatives may also not provide a history. Patients with pain accompanied by motor weakness should always be evaluated for fracture. In elderly patients with low-energy trauma, unilateral or bilateral femoral fracture should be considered, regardless of the given history. In patients with known or suspected malignancy, pathological fracture should be considered.

Keywords: femoral neck fracture, atypical symptoms, Elderly Patients

Ref No: 5791

Acute Aortic Dissection Mimicking Cerebrovascular Disease

Sait Emre Gödeoğlu[1], Murat Seyit[1], Duygu Aras Seyit[2], Mert Özen[1], Alten Oskay[1], Atakan Yılmaz[1]

[1]Pamukkale University Faculty of Medicine
[2]ERPA Saglik Hospital, Denizli

Murat Seyit / Pamukkale University Faculty of Medicine

Introduction and Purpose: Acute aortic dissection is a rare but highly fatal cardiovascular emergency. Its clinical presentation can resemble several acute conditions, particularly myocardial infarction and cerebrovascular stroke, which may lead to diagnostic delays and inappropriate management. Prompt recognition is essential to reduce morbidity and mortality.

Materials and Methods: A 78-year-old female patient with a known history of hypertension was brought to the emergency department by ambulance with a preliminary diagnosis of cerebrovascular event. She experienced syncope followed by tongue tremor and slurred speech. A detailed history revealed chest pain radiating to the back prior to the syncopal episode.On admission, her Glasgow Coma Scale (GCS) score was 15. Vital signs included blood pressure of 130/80 mmHg and oxygen saturation of 96%. Electrocardiography demonstrated ST-segment depression and T-wave inversion in leads V2–V6. No ST-segment elevation was observed on posterior ECG.Blood pressure measured in the contralateral arm was 80/50 mmHg, revealing a significant inter-arm blood pressure discrepancy. Bedside echocardiography did not show evident wall motion abnormalities. Although the descending thoracic aorta could not be clearly visualized, a dissection flap was detected in the abdominal aorta. Laboratory findings were normal except for elevated lactate levels (3.26 mmol/L).Thoracoabdominal and carotid computed tomography angiography demonstrated a dissection flap extending from the superior thoracic aorta involving the brachiocephalic trunk and right common carotid artery, and extending distally to the right external iliac artery. Diffusion-weighted MRI and cranial CT revealed no evidence of acute cerebral pathology.

Materials and Methods: Acute aortic dissection may mimic myocardial infarction with syncope and chest pain, as well as cerebrovascular stroke with neurological symptoms. A high index of suspicion is crucial in patients presenting with combined neurological and cardiovascular findings to ensure timely diagnosis and life-saving treatment.

Keywords: Acute aortic dissection, Syncope, Cerebrovascular stroke

Ref No: 5806

A KNIFE IN THE HEAD / LIFE CAN SOMETIMES BE LUCKY

murat kurtulmus[1], erdal tekin[1]

[1]atatürk üniversitesi

murat kurtulmus / atatürk üniversitesi

Introduction and Purpose: Penetrating head traumas leave significant damage to brain tissue.penetrating head trauma with a depth of 15 cm. We will examine it .

Materials and Methods: CASE48 years old, male.There are no known chronic diseases.penetrating knife wound to the head after a fight, was brought to our hospital.Vital signs are stable. he has no bleeding. GCS is 15.blood pressure: 140/70, sat:95, pulse:110 There is no neurodeficit . he can speak. he can hear. Visual field testing is normal. Eye movements are normal.Conclusion: Penetrating head traumas are life -threatening injuries. However, sometimes life gives you another chance, and you can continue your life without any lasting effects.

bt 1



bt 2

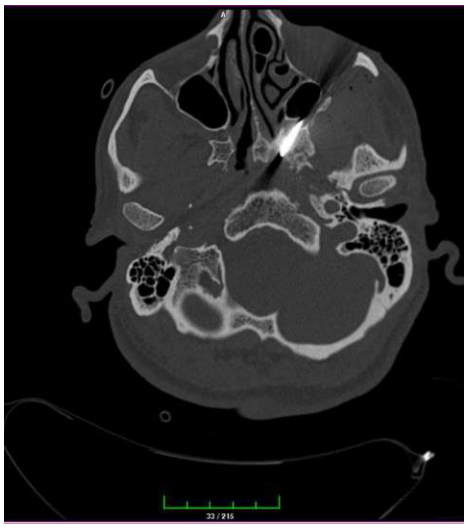

Materials and Methods: he has been operated. he is living.

Keywords: knife, head, luck

Ref No: 5837

Perforated Duodenum: The Board-Like Abdomen

Kadir Eryürük[1], Murat Seyit[1], Mert Özen[1], Alten Oskay[1], Atakan Yılmaz[1], İbrahim Türkçüer[1]

[1]Pamukkale University Faculty of Medicine

Murat Seyit / Pamukkale University Faculty of Medicine

Introduction and Purpose: Sudden epigastric pain is frequently attributed to gastritis or peptic ulcer exacerbation. However, abrupt and severe onset of pain should raise immediate suspicion for gastrointestinal perforation, a life-threatening surgical emergency requiring prompt diagnosis and intervention.

Materials and Methods: A 48-year-old man presented with sudden-onset epigastric pain described as “stabbing.” He had a history of nonsteroidal anti-inflammatory drug (NSAID) use. The pain rapidly progressed to involve the entire abdomen.Vital Signs: Blood pressure was

104/68 mmHg, heart rate 118 beats/min, and body temperature 38.1°C.Physical Examination: Diffuse abdominal tenderness with guarding and rebound was noted. The abdomen appeared rigid, consistent with a classic "board-like" abdomen.Laboratory Findings: Leukocyte count was 18,400/mm³, C-reactive protein was markedly elevated, and serum lactate was 3.8 mmol/L.Imaging: An upright abdominal radiograph demonstrated free air beneath the diaphragm. Computed tomography confirmed perforation of the anterior wall of the duodenum with free intraperitoneal air and fluid.

Materials and Methods: Broad-spectrum intravenous antibiotics were initiated, and emergent surgical consultation was obtained. The patient underwent primary surgical repair. In cases of sudden generalized abdominal pain, perforation must be excluded before attributing symptoms to gastritis. The detection of free intraperitoneal air is often lifesaving.

Keywords: Perforated Duodenum, Surgery, Pain

Ref No: 5840

Rapidly Progressive Encephalopathy Consistent with Creutzfeldt-Jakob Disease: A Case Report

Ayşegül Uygur[1], Mehmet Ulutürk[2]

[1]Yalvaç State Hospital
[2]Burdur State Hospital

Ayşegül Uygur / Yalvaç State Hospital

Introduction and Purpose: Creutzfeldt-Jakob disease (CJD) is a rare prion disorder characterized by rapidly progressive neurodegeneration and high mortality. It belongs to the group of transmissible spongiform encephalopathies and typically affects individuals in the sixth and seventh decades of life. Sporadic CJD accounts for the majority of cases. Clinically, it presents with rapidly progressive dementia, myoclonus, cerebellar ataxia, and psychiatric symptoms. Diagnosis requires a multimodal approach integrating clinical findings, neuroimaging, electroencephalography, and cerebrospinal fluid biomarkers. This report aims to present a case of rapidly progressive neurological deterioration consistent with CJD.

Materials and Methods: 81-year-old male presented to neurology department with progressive memory impairment and disorientation over several months. In the last few days, gait instability and behavioral changes developed. While awaiting diagnostic evaluation, his condition rapidly

deteriorated, leading to immobility and decreased oral intake. He was admitted to the emergency department with loss of consciousness, left hemiparesis, and involuntary movements of the right upper extremity. Brain CT and diffusion-weighted MRI showed no acute pathology, and laboratory tests were unremarkable. Initial electroencephalography (EEG) revealed generalized slowing with focal epileptiform activity. The patient was hospitalized. Cerebrospinal fluid (CSF) analysis excluded infectious causes, and autoimmune encephalitis was ruled out despite empirical steroid treatment. Follow-up MRI demonstrated bilateral cortical hyperintensities consistent with cortical ribboning. Repeat EEG showed worsening encephalopathy, and CSF analysis was positive for 14-3-3 protein. Based on clinical, radiological, and laboratory findings, a diagnosis consistent with CJD was established. During hospitalization, the patient required enteral feeding and developed a urinary tract infection. He was transferred to the intensive care unit due to respiratory failure, where aspiration pneumonia developed. Despite supportive treatment, his condition progressed to multi-organ failure, and he died on day 46.

"Cortical ribboning" appearance of Creutzfeldt-Jakob disease.



Axial diffusion-weighted MRI demonstrates bilateral cortical hyperintensities following the gyral pattern, consistent with the characteristic "cortical ribboning" appearance of Creutzfeldt-Jakob disease. Associated ventricular enlargement suggests concomitant cortical atrophy.

Results and Conclusion: CJD is a rapidly progressive and fatal disease that should be considered in patients with acute neurological deterioration. Early diagnosis is critical and relies on recognizing characteristic clinical features supported by MRI, EEG, and CSF findings. A systematic approach is essential to exclude treatable conditions. No curative treatment exists, timely diagnosis enables appropriate management, prognostic counseling, infection control, and palliative care planning.

Keywords: Creutzfeldt-Jakob disease, Rapidly progressive dementia, Cortical ribboning

Ref No: 5972

Acute Lower Limb Weakness as the İnitial Presentation of Aortic Dissection: A Fatal Case Report

Saffet Güler[1], Murat Seyit[1], Duygu Aras Seyit[2], Atakan Yılmaz[1], Mert Özen[1], Alten Oskay[1]

[1]Pamukkale University Faculty of Medicine
[2]ERPA Saglik Hospital, Denizli

Murat Seyit / Pamukkale University Faculty of Medicine

Introduction and Purpose: Aortic dissection is a life-threatening vascular emergency with variable presentations. While classic symptoms include severe chest, back, or abdominal pain, atypical presentations can lead to delayed diagnosis and increased mortality. This case report aims to highlight an unusual presentation of acute aortic dissection as isolated lower limb weakness and the critical importance of rapid recognition and intervention.Materials and Methods: A 60

Materials and Methods: A 60-year-old male patient with no prior medical history presented to the emergency department with sudden-onset right leg weakness for 30 minutes. He reported no accompanying abdominal, back, or flank pain. On examination, Glasgow Coma Scale was 15, right leg muscle strength 1/5, left leg 5/5, and both upper limbs 5/5. Distal pulses were palpable and symmetrical, and there was no limb asymmetry or temperature difference. Finger-stick blood glucose was 120 mg/dL, and electrocardiography showed normal sinus rhythm. Non-contrast brain computed tomography revealed no hemorrhage. Neurology consultation was requested; however, due to unavailability, diffusion-weighted magnetic resonance imaging (DWI MRI) was planned. MRI was delayed as the patient developed acute abdominal pain. He was urgently returned to the emergency department, and abdominal ultrasonography revealed aortic dissection flap.

Abdominal ultrasonography



Abdominal ultrasonography

Materials and Methods: During intervention, the patient suffered cardiac arrest with electrocardiographic ST-elevation changes. Despite resuscitation attempts, return of spontaneous circulation (ROSC) could not be achieved, and the patient was pronounced deceased. This case emphasizes that aortic dissection can present atypically with isolated limb weakness. Rapid recognition, high clinical suspicion, and prompt imaging are critical, as delays can result in fatal outcomes.

Keywords: Aortic dissection, Acute limb weakness

Ref No: 6041

A RARE CAUSE OF COLONIC DILATATION: OGILVIE SYNDROME

Hasan Altun[1], Yusuf Ziya Taştekin[1], Saygın Çanga[1], Ali Çolak[1], Mehmet Alkan[1], Mustafa Polat[1], Ali Karakuş[1]
[1]HATAY MUSTAFA KEMAL UNIVERSITY FACULTY OF MEDICINE, DEPARTMENT OF EMERGENCY MEDICINE, HATAY, TURKEY

Yusuf Ziya Taştekin / HATAY MUSTAFA KEMAL UNIVERSITY FACULTY OF MEDICINE, DEPARTMENT OF EMERGENCY MEDICINE, HATAY, TURKEY

Introduction and Purpose: Acute colonic pseudo-obstruction (ACPO), also known as Ogilvie syndrome, is a condition characterized by excessive colonic distension without mechanical obstruction. Patients presenting with Ogilvie syndrome have underlying medical and surgical conditions that predispose them to the syndrome.

Materials and Methods: A 67-year-old male patient presented to an external facility 2–3 days ago with complaints of constipation, impaired oral intake, and decreased urine output. He was transferred to our emergency department from the external facility with a preliminary diagnosis of acute kidney injury. The patient has been bedridden for 25 years following the development of paraplegia after a traffic accident. No comorbidities. Glasgow Coma Scale: 15; the patient was cooperative and oriented. Vital signs were recorded as pulse: 116 bpm, respiratory rate: 23 bpm, SpO2: 95–96%, and blood pressure: 90/55 mmHg. On physical examination, the abdomen appeared distended. Diffuse tenderness was present on deep palpation. No guarding or rebound tenderness was observed. The patient exhibited paraplegia. Laboratory tests revealed blood urea nitrogen (BUN) at 98 mg/dL, creatinine at 1.9 mg/dL, and severe metabolic acidosis. This was interpreted as acute kidney injury. Additionally, the patient's total calcium level was 4.8 mg/dL. No other abnormal findings were noted in the blood parameters. A full abdominal CT scan was performed on the patient. The imaging revealed a diameter increase of up to 7 cm at the thickest point of the rectum and colon, along with a distended appearance (Figure 1 and Figure 2). During follow-up, a small amount of gas and stool passage was observed. Oliguria was noted via the urinary catheter. The patient was started on a bicarbonate infusion and intravenous hydration. A consultation with general surgery was requested. General surgery did not consider an urgent surgical intervention due to the absence of mechanical obstruction and complications. The patient was consulted by nephrology. Nephrology planned for hospitalization due to electrolyte imbalance and the need for dialysis. The patient was admitted to the nephrology intensive care unit.

Materials and Methods: Patients who are bedridden for prolonged periods,have recently undergone surgery,are taking opioid or anticholinergic medications,or have electrolyte imbalances are at risk for Ogilvie syndrome, also known as acute colonic pseudo-obstruction.

Keywords: Ogilvie syndrome, distension, obstruction

Ref No: 6046

Acute Ischemic Stroke Due To Left MCA Occlusion: A Case Report In An Elderly Female Patient

Çağdaş Korucu[1], Murat Seyit[1], Duygu Aras Seyit[2], Alten Oskay[1], Atakan Yılmaz[1], Mert Özen[1]
[1]Pamukkale University Faculty of Medicine
[2]ERPA Saglik Hospital, Denizli

Murat Seyit / Pamukkale University Faculty of Medicine

Introduction and Purpose: Acute ischemic stroke is a leading cause of morbidity and mortality in the elderly population. Early recognition and timely reperfusion therapy are critical for favorable neurological outcomes. This poster presents an elderly patient with acute ischemic stroke who was successfully treated with intravenous thrombolytic therapy. Case Presentation: An 85-year-old female patient was brought to the emergency department after being found unresponsive in a corridor following a visit to the restroom at approximately 20:45. Relatives reported no seizure-like activity. The patient arrived at the hospital at 23:00. Her medical history included hypertension, restless leg syndrome, lumbar disc herniation surgery, and an ischemic stroke 1.5 years earlier with full recovery. Medication History: Her regular medications included acetylsalicylic acid 100 mg, clopidogrel 75 mg, betahistine 8 mg, nebivolol 5 mg, proton pump inhibitor, tadalafil, and gabapentin 600 mg. Physical Examination and Vital Signs: On admission, vital signs were as follows: blood pressure 118/87 mmHg, heart rate 130 bpm, respiratory rate 12/min, oxygen saturation 99%, and body temperature 36.5°C. Electrocardiography demonstrated atrial flutter. Neurological Examination: The patient was non-oriented and non-cooperative. She was aphasic and showed no withdrawal response to painful stimuli in the right upper and lower extremities. Imaging Findings: Non-contrast brain computed tomography revealed loss of gray–white matter differentiation in the left frontal lobe, suggestive of an ischemic process. Diffusion-weighted magnetic resonance imaging demonstrated diffusion restriction in the left middle cerebral artery (MCA) territory. Diagnosis and Treatment: The patient was diagnosed with acute ischemic stroke involving the left MCA territory.

Materials and Methods: Intravenous thrombolytic therapy with alteplase (45 mg) was administered within the therapeutic time window. Following treatment, the patient was admitted to the neurology intensive care unit for close monitoring.

Materials and Methods: This case highlights the importance of rapid assessment and timely thrombolytic therapy in elderly patients with acute ischemic stroke. Prompt neuroimaging and interdisciplinary management remain essential for optimizing neurological outcomes.

Keywords: Acute Ischemic Stroke, Thrombolytic Therapy, Middle Cerebral Artery

---

Ref No: 6053

Suspected Leptospirosis in a Patient Presenting with Sepsis, Rhabdomyolysis, and Acute Lower Extremity Weakness

Ozan Deniz Keleş[1], Murat Teker[1], İsa Yıldırım[1], Selçuk Eren Çanakçı[1], Ayhan Aköz[1]

[1]Department of Emergency Medicine, Faculty of Medicine, Aydın Adnan Menderes University, Aydın, Turkey

Ozan Deniz Keleş / Department of Emergency Medicine, Faculty of Medicine, Aydın Adnan Menderes University, Aydın, Turkey

Introduction and Purpose: Leptospirosis is a significant zoonotic infection transmitted through contact with contaminated water and soil, particularly affecting individuals working in rural areas. Its clinical spectrum ranges from mild flu-like symptoms to multi-organ failure. The severe form, characterized by jaundice, thrombocytopenia, and renal failure, is known as Weil's disease. However, some patients may also present with rhabdomyolysis and neurological findings. This report describes an atypical clinical course in a patient with occupational exposure who presented with fever, jaundice, and acute lower extremity weakness.

Materials and Methods: A 50-year-old male farmer presented to the emergency department with a 5-day history of brown watery diarrhea, a fever of 39°C, and a one-day onset of jaundice and leg weakness. Although he could initially walk short distances, his condition progressed within the day to an inability to walk even with support. His medical history revealed no chronic diseases but confirmed contact with animals, working in contaminated soil, and consuming well water. Physical examination revealed icteric sclera. While upper extremity strength was 5/5, lower extremity strength was 3/5 in bilateral hip and knee flexors/extensors, and 2/5 in ankle dorsiflexion and plantar flexion.Brain imaging showed no acute pathology, while thoracic and abdominal imaging revealed only splenomegaly. Laboratory results showed:•ALT: 232 U/L, AST: 573 U/L, CRP: 202 mg/L •Total Bilirubin: 6 mg/dL, Direct Bilirubin: 3.65 mg/dL •LDH: 712 U/L, CK: 8300 U/L, Myoglobin: > 1200 ng/mL •Hemoglobin: 11.3 g/dL, Platelets: 21,000/mm³ Guillain–Barré syndrome was ruled out by neurology. Following an infectious disease consultation, the patient was admitted with preliminary diagnoses of leptospirosis and sepsis.

Results and Conclusion: Leptospirosis is a critical zoonotic infection that can present with fever, jaundice, and multi-organ involvement. Findings such as rhabdomyolysis and severe thrombocytopenia suggest a severe clinical form. In patients with risky exposure histories, considering leptospirosis in the differential diagnosis is vital for early diagnosis and treatment.

Keywords: Leptospirosis, diarrhea, weakness

Ref No: 6064

The Endocrine Face of Palpitations

Kadir Eryürük[1], Murat Seyit[1], Mert Özen[1], Alten Oskay[1], Atakan Yılmaz[1], İbrahim Türkçüer[1]
[1]Pamukkale University Faculty of Medicine
Murat Seyit / Pamukkale University Faculty of Medicine

Introduction and Purpose: Palpitations, tremor, and restlessness in young patients are frequently labeled as anxiety-related disorders. However, thyrotoxicosis—including the spectrum of thyroid storm—may present to the emergency department with prominent cardiovascular and neuropsychiatric manifestations. Early recognition is essential to prevent potentially life-threatening complications.

Materials and Methods: A 29-year-old woman presented with progressively worsening palpitations over one week, accompanied by unintentional weight loss (approximately 3 kg/month), heat intolerance, and irritability. During the previous 24 hours, she had developed increasing chest tightness and dyspnea. She had no psychiatric history. On examination, a fine tremor and warm, moist skin were noted. Mild diffuse thyroid enlargement was palpable in the anterior neck.Vital Signs: Blood pressure was 138/62 mmHg (widened pulse pressure), heart rate 142 beats/min and irregular, respiratory rate 22 breaths/min, oxygen saturation 98% on room air, and temperature 37.9°C.Electrocardiography: Electrocardiogram demonstrated atrial fibrillation with rapid ventricular response.Laboratory Findings: Thyroid-stimulating hormone (TSH) was suppressed at < 0.01 mIU/L. Free thyroxine (fT4) was elevated at 4.2 ng/dL, and free triiodothyronine (fT3) was also elevated. Leukocyte count was 10.4 K/µL, and C-reactive protein was 5 mg/L. Mild elevations in AST and ALT were observed. Troponin was negative, and electrolytes were within normal limits.Imaging: Bedside echocardiography revealed no structural abnormalities and preserved ejection fraction, with mild tachycardia-related diastolic dysfunction.Management: Based on clinical scoring systems, the patient was assessed as moderate risk for impending thyroid storm. Supportive therapy and close cardiac monitoring were initiated. Thromboembolic risk associated with atrial fibrillation was evaluated, and appropriate anticoagulation was planned. Endocrinology consultation was obtained to investigate the underlying etiology, including possible Graves' disease, and to guide definitive therapy.

Materials and Methods: In patients presenting with palpitations and anxiety-like symptoms, associated findings such as weight loss, heat intolerance, tremor, and warm moist skin should prompt thyroid function testing before concluding a psychogenic diagnosis. Thyrotoxicosis may present with atrial fibrillation and significant cardiac complications. Not every palpitation is panic—sometimes the thyroid is the underlying cause.

Keywords: Palpitations, Thyroid-stimulating hormone, Thyrotoxicosis

Ref No: 6069

Spontaneous Subarachnoid Hemorrhage In A Patient With Hypertension

Oğuz Yılmaz[1], Murat Seyit[1], Duygu Aras Seyit[2], Mert Özen[1], Alten Oskay[1], Atakan Yılmaz[1]

[1]Pamukkale University Faculty of Medicine
[2]ERPA Saglik Hospital, Denizli

Murat Seyit / Pamukkale University Faculty of Medicine

Introduction and Purpose: Spontaneous subarachnoid hemorrhage (SAH) is a neurological emergency associated with high morbidity and mortality. Hypertension is a well-known risk factor, and early diagnosis with prompt neuroimaging is essential for appropriate management.

Materials and Methods: A 40-year-old male patient with a known history of hypertension presented to the emergency department with sudden-onset severe headache. The headache was described as abrupt and intense, consistent with a thunderclap pattern. There was no history of trauma, seizure activity, or prior similar episodes. Physical Examination and Vital Signs: On admission, the patient was conscious and oriented. Vital signs revealed elevated blood pressure consistent with his hypertensive history. Neurological examination showed no focal motor deficits. Imaging Findings: Non-contrast brain computed tomography demonstrated diffuse subarachnoid hemorrhage, predominantly involving the basal cisterns. The imaging findings were consistent with spontaneous subarachnoid hemorrhage. Diagnosis and Management: The patient was diagnosed with spontaneous subarachnoid hemorrhage. He was promptly evaluated by the neurosurgery team, and appropriate medical management was initiated, including blood pressure control and neurocritical monitoring. Clinical Course: The patient was admitted to the neurosurgical intensive care unit for close observation and further etiological evaluation.

Materials and Methods: Spontaneous subarachnoid hemorrhage should be considered in patients presenting with sudden severe headache, particularly in those with hypertension. Early neuroimaging and multidisciplinary management are crucial for optimizing clinical outcomes.

Keywords: Subarachnoid Hemorrhage, Hypertension, Thunderclap Headache

Ref No: 6071

A YOUNG WOMAN WITH DIZZINESS

Merve Bulut[1], Ekrem Bulut[1], Mevlana Gül[1]

[1]Atatürk University Faculty of Medicine

Merve Bulut / Atatürk University Faculty of Medicine

Introduction and Purpose: Intracranial masses are relatively rare in young patients and may present with non-specific neurological symptoms. Complaints such as dizziness and extremity numbness can range from benign conditions to serious central nervous system pathologies. Therefore, careful neurological evaluation and appropriate imaging are essential in patients presenting to the emergency department.

Materials and Methods: A 23-year-old female presented to the emergency department with complaints of dizziness and numbness in the left arm and left leg. The symptoms had been present for several days and were progressively worsening.On physical examination, hypoesthesia was noted in the left upper and lower extremities, while motor strength was intact. Vital signs were stable, and other system examinations were unremarkable.Cranial imaging revealed a mass lesion(figure-1,2) in the brain parenchyma with significant surrounding vasogenic edema. The patient was admitted for further evaluation and management.

figure-1 figure-2

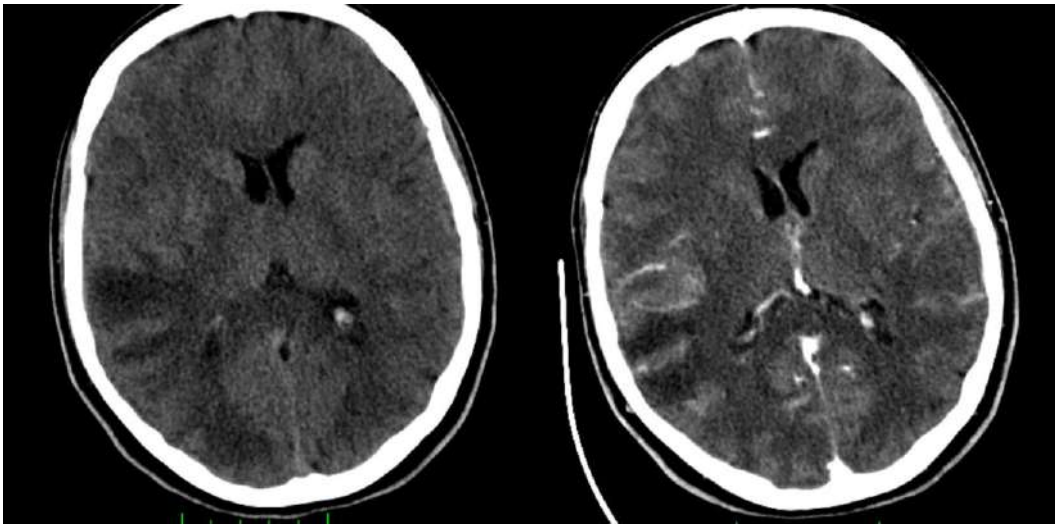

Results and Conclusion: Although rare, intracranial masses should be considered in young patients presenting with dizziness and focal neurological deficits. Early imaging and a multidisciplinary approach are crucial for accurate diagnosis and timely management.

Keywords: Intracranial mass, dizziness, mass lesion

Ref No: 6165

COMMON DISEASES HAVE COMMON COMPLICATIONS

Abdullah Süha Akça[1], Alparslan Altun[1], İbrahim Özlü[1]

[1]Atatürk Üniversitesi Acil Tıp

Abdullah Süha Akça / Atatürk Üniversitesi Acil Tıp

Introduction and Purpose: Cholecystitis refers to inflammation of the gallbladder. Acute cholecystitis most commonly occurs as a complication of gallstone disease and typically develops in patients with a history of symptomatic cholelithiasis. Gallbladder perforation is observed in approximately 10% of cases and is more frequently seen in patients with delayed diagnosis or those who do not respond to initial treatment. Perforation is usually localized and occurs at the fundus of the gallbladder following the development of gangrene. The resulting pericholecystic abscess may be palpable and can be visualized on abdominal computed tomography. Less commonly, free perforation into the peritoneal cavity may occur, leading to generalized peritonitis and is associated with high mortality.

Materials and Methods: A 52-year-old female patient presented to the emergency department with abdominal pain. Her history revealed that the pain had been ongoing for one month, localized to the right upper quadrant, increasing after meals and subsiding after a few hours; however, over the past week, the pain had progressively worsened and persisted. Nausea, vomiting, and fever had developed over the last day. She had no known comorbidities, allergies, or medication use. Vital signs were within normal limits except for a temperature of 37.8°C. On physical examination, there was tenderness and guarding in the right upper quadrant, with a positive Murphy's sign. Initial imaging did not reveal perforation. Laboratory findings were notable for leukocytosis (WBC: 23,600 mcg/L, 84% neutrophils), with no other significant abnormalities. As the pain became diffuse across all abdominal quadrants, contrast-enhanced thoracoabdominal computed tomography was performed, revealing gallbladder wall edema, pericholecystic inflammatory changes, and the presence of air densities within the lumen and surrounding the gallbladder, suggestive of perforation. The patient was evaluated by general surgery and admitted for operative management.

Materials and Methods: Acute cholecystitis is highly prevalent in our population, correlating with the frequent incidental detection of gallstones. In untreated or delayed cases, severe complications such as emphysematous cholecystitis and perforated cholecystitis, both associated with high mortality, may develop. These diagnoses should not be overlooked, particularly in patients presenting with systemic findings and a toxic clinical appearance.

photo1



Keywords: cholecystitis, perforation, gallstone

Ref No: 6271

A Psychiatric Presentation or a Metabolic Emergency? Severe Hypoglycemia Mimicking Acute Psychosis

Enes Akınci[1], Sultan Tuna Akgöl Gür[1]

[1]Atatürk University Research Hospital

Enes Akınci / Atatürk University Research Hospital

Introduction and Purpose: Altered mental status is a frequent presentation in the emergency department and is often attributed to psychiatric disorders, especially in patients presenting with agitation and abnormal behavior. However, metabolic disturbances such as hypoglycemia can present with neuropsychiatric symptoms, leading to potential misdiagnosis and delayed treatment.

Materials and Methods: A 29-year-old male was brought to the emergency department by his family due to sudden behavioral changes, including agitation, incoherent speech, and aggressive behavior. According to his relatives, the patient had been completely normal the previous day. There was no known psychiatric history, substance abuse, or recent illness.On arrival, the patient

was disoriented and uncooperative. Vital signs revealed a blood pressure of 120/80 mmHg, heart rate of 110 beats per minute, and oxygen saturation of 98% on room air. Physical examination was otherwise unremarkable, with no focal neurological deficits. Due to severe agitation, initial consideration was given to an acute psychiatric episode.However, as part of routine emergency evaluation, bedside capillary blood glucose was measured and found to be 38 mg/dL.Based on this finding, the patient was diagnosed with Hypoglycemia, a critical metabolic condition that can present with a wide spectrum of neuropsychiatric symptoms, including confusion, agitation, and even psychosis-like features.The patient was immediately treated with intravenous dextrose. Within minutes, his mental status improved dramatically, and he became fully oriented and cooperative. Upon further questioning, it was revealed that he had skipped meals and had taken an excessive dose of oral antidiabetic medication.

Results and Conclusion: This case highlights the importance of considering organic causes in patients presenting with acute behavioral changes. Hypoglycemia is a reversible but potentially life-threatening condition that can easily be mistaken for psychiatric illness if not promptly recognized.In conclusion, not all agitation is psychiatric in origin. Rapid bedside glucose measurement is a simple yet crucial step in the evaluation of altered mental status. Early identification and treatment of hypoglycemia can be life-saving and prevent unnecessary interventions or misdiagnosis.

Keywords: Hypoglycemia, Acute Psychosis

Ref No: 6274

Aortic dissection mimicking acute stroke: Left carotid involvement detected by ct angiography prior to thrombolysis

Aykut KEMANCI[1]
[1]Tavşanlı Doç. Dr. Mustafa Kalemli Devlet Hastanesi

Aykut KEMANCI / Tavşanlı Doç. Dr. Mustafa Kalemli Devlet Hastanesi

Introduction and Purpose: Acute aortic dissection is a life-threatening condition that may present with neurological deficits when the carotid arteries are involved. Such presentations can closely mimic acute ischemic stroke and may lead to inappropriate thrombolytic therapy if not carefully evaluated.This case highlights the importance of considering aortic dissection in patients presenting with acute neurological symptoms, even when initial neuroimaging findings are unremarkable.

Materials and Methods: A 74-year-old male patient presented to the emergency department with sudden onset of left upper extremity weakness and speech impairment. The patient presented within the first hour of symptom onset. His medical history included coronary artery disease and diabetes mellitus.On admission, the patient was disoriented. Neurological examination revealed impaired speech with meaningless verbal output. GCS score was E4M6V3. Motor examination demonstrated muscle strength of 1/5 in the left upper extremity, while the remaining extremities were normal. A tremor was noted in the right hand.Vital signs were blood pressure 100/60 mmHg, heart rate 60 beats per minute, oxygen saturation 90%, and blood glucose level 255 mg/dL.Non-contrast brain computed tomography and diffusion-weighted magnetic resonance imaging were interpreted as normal.The patient was considered a candidate for intravenous thrombolytic therapy, as he presented within the first hour and no intracranial hemorrhage was detected. To support treatment decision-making and evaluate the need for mechanical thrombectomy, brain and carotid CT angiography was performed. Imaging revealed DeBakey type II (Stanford type A) aortic dissection extending into the left carotid artery.Blood pressure measurements were later found to have been obtained only from the right arm. Thrombolytic therapy was withheld, and the patient was referred for urgent cardiovascular surgical management.

Figure 1. CT angiography demonstrating DeBakey type II (Stanford type A) aortic dissection with extension into the left internal carotid artery (arrow).

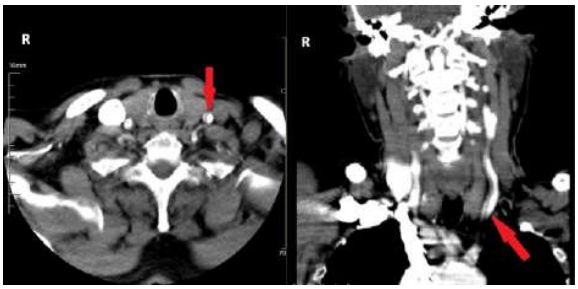

Axial and coronal images show carotid involvement by the dissection process. This finding correlates with the patient’s acute neurological presentation and emphasizes the importance of advanced vascular imaging prior to thrombolytic therapy.

Materials and Methods: Aortic dissection may present with isolated neurological findings and mimic acute ischemic stroke, especially when initial neuroimaging is normal. Normal CT and diffusion MRI do not exclude serious vascular pathology. Advanced imaging such as CT angiography may be essential before thrombolysis in selected patients.Single-arm blood pressure measurement may obscure critical diagnostic findings; therefore, bilateral assessment should be routinely performed. Early recognition of carotid involvement in aortic dissection is essential to prevent inappropriate treatment and potentially fatal complications. Increased clinical awareness may improve diagnostic accuracy and patient outcomes.

Keywords: Aortic Dissection, Stroke Mimic, Carotid Dissection

Ref No: 6307

Spontaneous Rupture of Hepatocellular Carcinoma: A Rare Emergency Department Case

ESMA BULUT[1]
[1]BAYBURT DEVLET HASTANESİ
ESMA BULUT / BAYBURT DEVLET HASTANESİ

Introduction and Purpose: Hepatocellular carcinoma (HCC) is the most common primary liver tumor arising in the setting of chronic liver disease. Spontaneous rupture is rare but life-threatening, causing massive intra-abdominal hemorrhage. It should be considered in the differential diagnosis of sudden abdominal pain and hemodynamic instability, especially in patients without trauma history.

Materials and Methods: A 75-year-old male presented to the emergency department with sudden-onset abdominal pain, dizziness, and syncope. Physical examination revealed cold, pale skin and generalized abdominal tenderness with notable right upper quadrant and epigastric guarding. Vital signs: BP 81/52 mmHg, HR 125 bpm, T 36.5°C, SpO_2 97%. Laboratory studies showed hemoglobin 9.7 g/dL, hematocrit 27%, AST 48 U/L, ALT 70 U/L, INR 2.08, and HBsAg positive. Bedside FAST revealed intra-abdominal free fluid. The patient received intravenous fluids, packed red blood cells, and fresh frozen plasma to stabilize hemodynamics. Contrast-enhanced CT demonstrated a 5.5 cm heterogeneous hypodense lesion in the left liver lobe with extensive intraperitoneal fluid. After consultation with general surgery, the patient underwent urgent laparotomy with packing for hemorrhage control and was transferred to a tertiary oncology center for further management. Subsequent left-lobe hepatic resection was performed, and the patient continued follow-up in the oncology clinic.

ABDOMEN CT

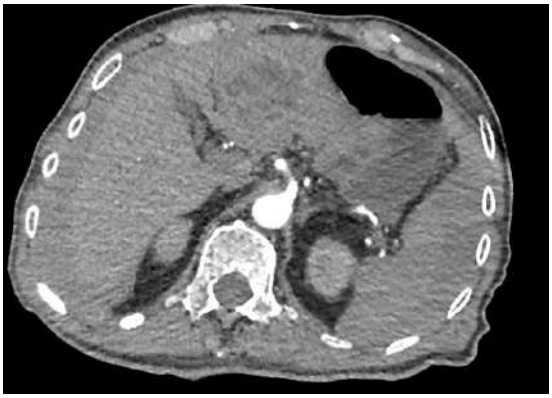

Materials and Methods: Spontaneous rupture of HCC is uncommon but associated with high mortality due to massive hemorrhage. Management options include emergency surgical resection, transarterial embolization (TAE), or delayed resection following stabilization. Early recognition, prompt resuscitation, and timely surgical intervention are critical for reducing mortality. This case highlights the importance of considering ruptured HCC in elderly patients presenting with acute abdomen and hemodynamic instability, even in the absence of trauma.

Keywords: Hepatocellular carcinoma; Spontaneous rupture; Intra-abdominal hemorrhage; Emergency department; Acute abdomen

---

Ref No: 6331

The importance of early TPA treatment

Duygu Aras Seyit[1], Murat Seyit[2]

[1]ERPA Saglik Hospital, Denizli
[2]Pamukkale University Faculty of Medicine

Murat Seyit / Pamukkale University Faculty of Medicine

Introduction and Purpose: Acute ischaemic cerebrovascular disease is a clinical condition caused by a vascular aetiology that leads to sudden focal or global cerebral dysfunction and may result in severe disability or death. In suitable cases, intravenous tissue plasminogen activator (tPA) administered within the first 4.5 hours of symptom onset is both life-saving and reduces the rate of disability. Here, we aimed to illustrate the importance of early presentation by reporting the case of a patient who presented within the first 1.5 hours and achieved a full recovery without sequelae following intravenous tPA treatment.

Materials and Methods: A patient with no known chronic illnesses and not on antiplatelet therapy presented with numbness and weakness on the left side. Diffusion MRI revealed restricted diffusion in the right basal ganglia. With normal blood tests and given that the event had occurred within 1.5 hours, intravenous TPA treatment was administered following the patient's consent. The patient recovered without sequelae and experienced no complications during follow-up.

MRI

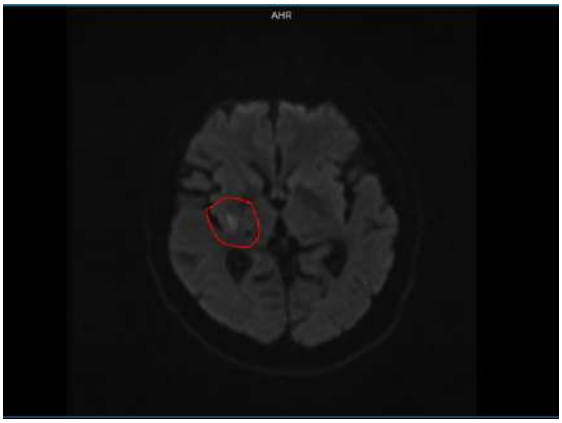

Materials and Methods: Acute cerebrovascular disease is the third leading cause of death worldwide. Disability rates are also high, and intravenous tPA therapy administered within the first 4.5 hours in suitable cases is life-saving. Studies have shown that the earlier the treatment is administered, the higher its efficacy (door-to-needle time).

Keywords: Acute cerebrovascular disease, door-to-needle time, Tpa

---

Ref No: 6369

Anticoagulant Related Bleeding: Hemoptysis

Safa Gödeoğlu[1], Murat Seyit[1], İbrahim Türkçüer[1], Alten Oskay[1], Atakan Yılmaz[1], Mert Özen[1]

[1]Pamukkale University Faculty of Medicine

Safa Gödeoğlu / Pamukkale University Faculty of Medicine

Introduction and Purpose: Warfarin is widely prescribed for anticoagulation, particularly in patients with mechanical heart valve replacement. Although effective, it carries a significant risk of major bleeding complications. Diffuse alveolar hemorrhage is a rare but potentially life-threatening manifestation that may present with hemoptysis and nonspecific respiratory findings, leading to diagnostic challenges in emergency settings. This case report aims to describe a patient with warfarin-associated alveolar hemorrhage accompanied by suspected gastrointestinal bleeding and to highlight the importance of early recognition, prompt anticoagulation reversal, and multidisciplinary management.

Materials and Methods: A 71-year-old male with a medical history of chronic obstructive pulmonary disease (COPD) and heart valve replacement presented to the emergency department with three episodes of acute-onset hemoptysis on the same day, totaling approximately 50 mL. The patient also reported black-colored stools and newly developed ecchymotic skin lesions. He had been taking warfarin 5 mg daily. On admission, vital signs were stable. Physical examination revealed rales in the right middle lung zone, while oropharyngeal and abdominal examinations were unremarkable. Rectal examination showed normal stool staining. Laboratory tests demonstrated anemia, with hemoglobin levels decreasing from 9.8 g/dL to 8.8 g/dL, while platelet count was normal. The international normalized ratio (INR) could not initially be measured. Contrast-enhanced thoracic computed tomography was performed to identify the bleeding source.

Anticoagulant Related Bleeding

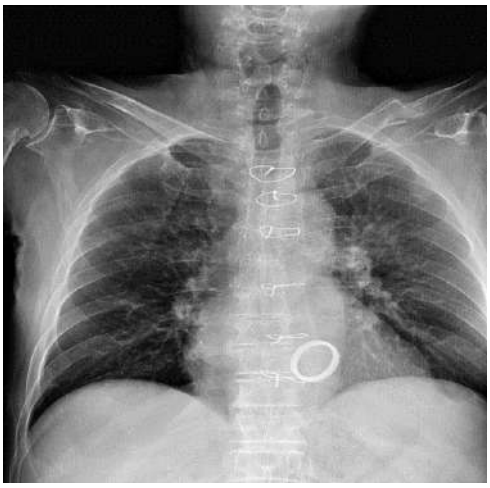



Materials and Methods: Thoracic computed tomography revealed findings consistent with alveolar hemorrhage extending from the hilar region to the subpleural area in the anterior segment of the left upper lobe and the superior lingula. Anticoagulation reversal was initiated with 60 mL of prothrombin complex concentrate, after which the INR decreased to 1.58. No further hemoglobin decline or hemodynamic instability was observed during follow-up. After consultations with pulmonology, thoracic surgery, and gastroenterology, the patient was admitted to the anesthesia intensive care unit for close monitoring and planned endoscopic evaluation. This case emphasizes that alveolar hemorrhage should be considered in anticoagulated patients presenting with hemoptysis and that early anticoagulation reversal with intensive care monitoring is crucial for preventing adverse outcomes.

Keywords: Warfarin, Alveolar hemorrhage, Anticoagulant-related bleeding

---

Ref No: 6396

Pneumothorax Developing After a Fall from Bed

Fazilet Gücüko[1], Murat Seyit[1], Mert Özen[1], Alten Oskay[1], Atakan Yılmaz[1], İbrahim Türkçüer[1]

[1]Pamukkale University Faculty of Medicine

Murat Seyit / Pamukkale University Faculty of Medicine

Introduction and Purpose: Pneumothorax is the presence of air in the pleural cavity. It is divided into two groups as spontaneous and traumatic. When spontaneous pneumothorax occurs in healthy individuals, it is called primary spontaneous pneumothorax; when it occurs in individuals with underlying lung disease, it is called secondary spontaneous pneumothorax. Traumatic pneumothorax is a pneumothorax that occurs as a result of blunt or penetrating trauma.

Materials and Methods: An 85-year-old male patient with a history of heart failure, COPD, and Alzheimer's disease presented to an outside center with complaints of shortness of breath and rib pain after falling to the ground while turning in bed in the morning. The patient was referred to our center from the outside facility with a preliminary diagnosis of pneumothorax. On physical examination, auscultation revealed decreased breath sounds in the right lung, tenderness in the posterior region of the right 5th–6th–7th ribs, and other physical examination findings were evaluated as normal. The patient's vital signs were as follows: Oxygen saturation: 89% (with oxygen support), Pulse: 88, Blood pressure: 120/80, Temperature: 36.4. Imaging of the patient showed loss of aeration consistent with pneumothorax in the right hemithorax, and displaced

fracture lines in the posterior segments of the right 5th–7th ribs were observed. The patient was evaluated by the thoracic surgery department and a 28F chest tube was inserted into the right hemithorax. The patient, in whom marked regression of the pneumothorax was observed on control radiography, was transferred to the intensive care unit.

CT

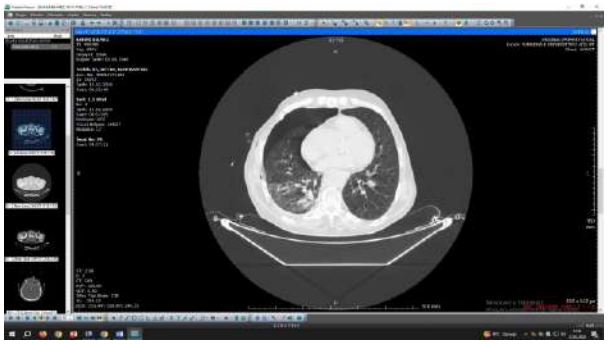

Materials and Methods: Thoracic traumas have an important place among traumas presenting to the emergency department. They may occur as isolated thoracic trauma or together with injuries to other systems and organs. When seen together with injuries to other systems, morbidity and mortality increase. Rapid diagnosis and early treatment should be implemented in the prehospital setting and in emergency departments.

Keywords: Traumatic Pneumothorax, Fall, Elderly

Ref No: 6415

The Great Mimicker: Acute Inferior MI Presenting as Persistent Constipation

Emre Gökçen[1], Mikail Kuşdoğan[1], Levent Albayrak[1], Sevilay Vural[1], Yağmur Koca[1], Faruk Türkmen[1]

[1]Yozgat Bozok University, Faculty Of Medicine, Department Of Emergency Medicine, Yozgat, Turkey.

Sevilay Vural / Yozgat Bozok University, Faculty Of Medicine, Department Of Emergency Medicine, Yozgat, Turkey.

Introduction and Purpose: Inferior myocardial infarction (MI) is typically associated with Right Coronary Artery (RCA) occlusion. Due to the inferior wall's anatomical proximity to the diaphragm and potential for vagal nerve stimulation, patients often present with atypical gastrointestinal symptoms—such as nausea, epigastric pain, or even altered bowel habits like constipation—rather than classic chest pain. These "masked" presentations pose a significant diagnostic challenge in the emergency department (ED), where life-threatening cardiac events can be misinterpreted as benign abdominal issues. In this report, we discuss a geriatric patient presenting with persistent constipation who was subsequently diagnosed with an acute inferior STEMI, highlighting the necessity of clinical vigilance in atypical presentations.

Materials and Methods: A 67-year-old female with a history of Diabetes, Hypertension, and Hyperlipidemia presented to the ED via ambulance with a two-day history of constipation and a transient episode of chest pain. Vital signs were stable; however, physical examination revealed epigastric tenderness and intermittent nausea. Given her cardiovascular risk factors, an ECG was performed, revealing ST-segment elevation consistent with acute Inferior STEMI. Laboratory results confirmed myocardial injury with a Troponin T level of 1243 ng/L. Coronary angiography revealed a dominant RCA with 30% proximal stenosis identified as the culprit lesion, alongside significant LAD disease (40-50% proximal, 90-99% distal) and 30% LCx stenosis. Primary Percutaneous Coronary Intervention (pPCI) was successfully performed on the RCA, and the patient was transferred to the coronary intensive care unit for post-procedural monitoring.

Admission ECG showing characteristic findings of an acute inferior wall myocardial infarction.

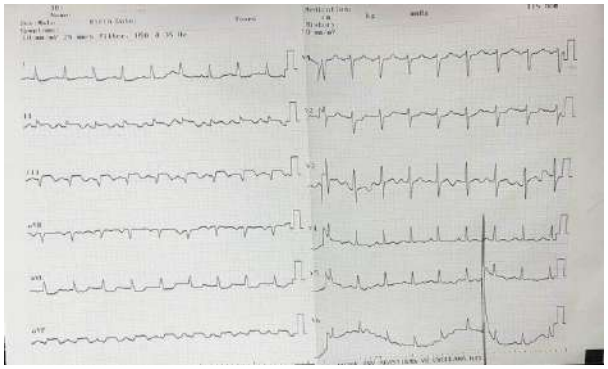

Materials and Methods: This case serves as a critical reminder that myocardial ischemia can manifest with vague features such as constipation. In the high-pressure ED environment, gastrointestinal symptoms in high-risk patients should not be dismissed without excluding cardiac etiologies. Maintaining a low threshold for ECG screening is a fundamental component of emergency triage for geriatric patients to ensure timely reperfusion and improved survival.

Keywords: Clinical Decision Making, Emergency Medicine, Inferior MI

Ref No: 6470

Delayed Diagnosis of İschemic Stroke in a Patient Presenting with Resistant Vertigo

Saffet Güler[1], Murat Seyit[1], Duygu Aras Seyit[2], Mert Özen[1], Alten Oskay[1], Atakan Yılmaz[1]

[1]Pamukkale University Faculty of Medicine
[2]ERPA Saglik Hospital, Denizli

Murat Seyit / Pamukkale University Faculty of Medicine

Introduction and Purpose: Vertigo is a frequent cause of emergency department admissions and may result from benign peripheral vestibular disorders or serious central nervous system pathologies such as stroke. Distinguishing between peripheral and central causes can be challenging, particularly when neurological examination findings are subtle or incomplete. Posterior circulation strokes may present solely with vertigo and are known to be missed on early imaging studies. The aim of this case report is to emphasize the importance of maintaining a high index of suspicion and performing repeat imaging in patients with resistant vertigo and vascular risk factors.

Materials and Methods: A 60-year-old male patient with a known history of hypertension presented to the emergency department with acute-onset dizziness that began at 3 a.m. Vital signs revealed a blood pressure of 180/100 mmHg, oxygen saturation of 98%, body temperature of 36.6°C, and a pulse rate of 90 beats per minute. Physical examination demonstrated horizontal nystagmus. The Head Impulse–Nystagmus–Test of Skew (HINTS) examination could not be completed. The remaining neurological examination was unremarkable. Finger-stick blood glucose level was 120 mg/dL, and electrocardiography showed normal sinus rhythm. Initial brain computed tomography and diffusion-weighted magnetic resonance imaging (MRI) revealed no evidence of hemorrhagic or ischemic cerebrovascular accident.

Diffusion-weighted magnetic resonance imaging

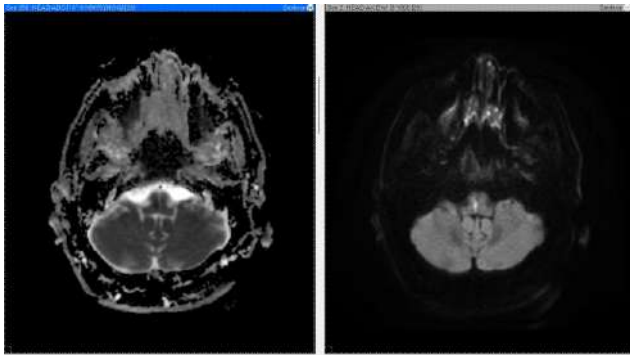

Diffusion-weighted magnetic resonance imaging

Materials and Methods: The patient's symptoms did not improve despite treatment with piracetam and dimenhydrinate. Due to persistent vertigo, an otorhinolaryngology consultation was obtained, and the patient was admitted for further evaluation. A repeat diffusion-weighted MRI performed during hospitalization revealed an ischemic cerebrovascular accident. The patient was subsequently transferred to the neurology department for definitive management. This case highlights that early diffusion-weighted MRI may yield false-negative results in posterior circulation strokes and underscores the necessity of close clinical follow-up and repeat imaging in patients presenting with resistant vertigo and vascular risk factors.

Keywords: Vertigo, Ischemic stroke, Emergency department

Ref No: 6473

Artificial Intelligence in Electrocardiogram Analysis: A Narrative Review of Recent Advances and Emergency Medicine Applications

Zülküf Sergen ÜNLÜ[1]

[1]Mersin City Training and Research Hospital, Department of Emergency Medicine

Zülküf Sergen ÜNLÜ / Mersin City Training and Research Hospital, Department of Emergency Medicine

Introduction and Purpose: Electrocardiogram (ECG) interpretation is central to emergency department (ED) practice, yet misinterpretation rates remain high under time constraints and crowding. Artificial intelligence (AI) and deep learning (DL) have advanced automated ECG analysis considerably. Foundation models — pre-trained on millions of recordings and adaptable to multiple tasks — mark a shift from single-diagnosis classifiers to general-purpose ECG platforms. This narrative review synthesizes these developments with a focus on diagnostic accuracy, clinical outcomes, and applicability to ED workflows.

Materials and Methods: We searched PubMed, Scopus, Google Scholar, and preprint servers (arXiv, medRxiv) for English-language studies published between January 2023 and March 2026. Search terms combined "artificial intelligence," "deep learning," "foundation model," "electrocardiogram," and "emergency department." Studies were included if they reported AI-driven 12-lead ECG interpretation, described publicly available ECG datasets, or presented

clinical validation in acute care or prehospital settings. Foundational earlier studies provided methodological context. A total of 47 publications informed this review.

Conceptual framework for AI-enabled ECG analysis integration into ED workflow

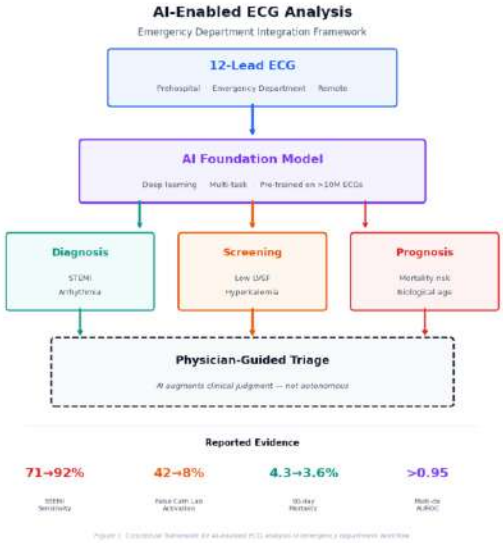

Materials and Methods: Foundation models trained on datasets exceeding 10 million ECGs now achieve an area under the receiver operating characteristic curve (AUROC) above 0.95 across dozens of diagnoses, matching or exceeding specialist-level performance in benchmark evaluations. When deployed clinically, AI-ECG improved ST-elevation myocardial infarction (STEMI) detection sensitivity from 71% to 92% and cut false catheterization laboratory activations from 41.8% to 7.9% in a multicenter registry, while a randomized trial of 15,965 patients linked AI-driven mortality alerts to a reduction in 90-day all-cause death from 4.3% to 3.6%. Applications now extend beyond rhythm analysis: AI-ECG estimates left ventricular ejection fraction (LVEF) with an AUROC of 0.95, detects hyperkalemia from the ECG waveform alone, and derives biological age as a cardiovascular risk marker. Prehospital integration, where AI interprets ambulance-transmitted ECGs before hospital arrival, is an active research area with direct relevance to time-critical diagnoses. In parallel, open-access datasets such as PTB-XL and MIMIC-IV-ECG have enabled independent external validation. For emergency physicians, the principal near-term value lies in accelerating time-sensitive diagnoses such as STEMI, life-threatening arrhythmia, and occult left ventricular dysfunction. These tools hold the greatest promise as decision-support aids in time-pressured triage, not as autonomous diagnosticians.

Summary of key AI-ECG studies and clinical evidence

Study / Platform	Task	Dataset / Setting	Key Finding
ECGFounder (Li et al., 2024)	Multi-label diagnosis (150 labels)	10.7 million ECGs; internal + external validation	AUROC >0.95 for 80/150 diagnoses
ECG-FM (McKeen et al., 2024)	AF detection; few-shot transfer	1.6 million ECGs; PTB-XL external validation	AF AUROC = 0.996; superior in low-data
Queen of Hearts (Smith et al., 2023)	STEMI detection	Multicenter registry; 3 US centers	Sensitivity 71%→92%; false activation 41.8%→7.9%
AI-ECG Mortality RCT (Lin et al., 2024)	Mortality prediction with alerts	RCT; n=15,965; single center	90-day mortality 4.3%→3.6%
AI-LVEF (Attia et al., 2019)	LV ejection fraction estimation	44,959 patients; Mayo Clinic	Reduced EF detection AUROC = 0.95
AI-Hyperkalemia (Galloway et al., 2019)	Hyperkalemia detection from ECG	1.5 million ECGs; Mayo Clinic	K+ ≥5.5 mEq/L AUROC = 0.883
PTB-XL (Wagner et al., 2020)	Open-access benchmark	21,799 12-lead ECGs	Standardized labels; widely used
MIMIC-IV-ECG (Gow et al., 2023)	Large-scale open repository	800,000 ECGs; linked to outcomes	Largest open dataset

AUROC = area under the receiver operating characteristic curve; STEMI = ST-elevation myocardial infarction; LVEF = left ventricular ejection fraction; AF = atrial fibrillation; RCT = randomized controlled trial.

Keywords: artificial intelligence, electrocardiography, foundation model

Ref No: 6475

The Hidden Danger Behind an Innocent Forehead Swelling: Pott's Puffy Tumor

Ömer Faruk Yazıcıoğlu[1], Melih Yüksel[1], Mehmet Oğuzhan Ay[1], Yeşim İşler[1], Umut Ocak[1], Merve Dayı[1], Halil Kaya[1]

[1]University of Health Sciences, Bursa Yuksek Ihtisas Training and Research Hospital, Department of Emergency Medicine, Bursa/Türkiye

Ömer Faruk Yazıcıoğlu / University of Health Sciences, Bursa Yuksek Ihtisas Training and Research Hospital, Department of Emergency Medicine, Bursa/Türkiye

Introduction and Purpose: Although sinusitis is a common reason for emergency department visits, the progression of infection leading to destruction of bony structures and resulting in extracranial or intracranial complications is rare but potentially life-threatening. Pott's Puffy Tumor (PPT) develops when a frontal sinus infection spreads directly or via venous thrombophlebitis to the frontal bone. The diagnosis is typically established by the presence of frontal swelling on physical examination and radiological evidence of bone destruction. In this report, we present a case of PPT developing after frontal sinusitis.

Image 2

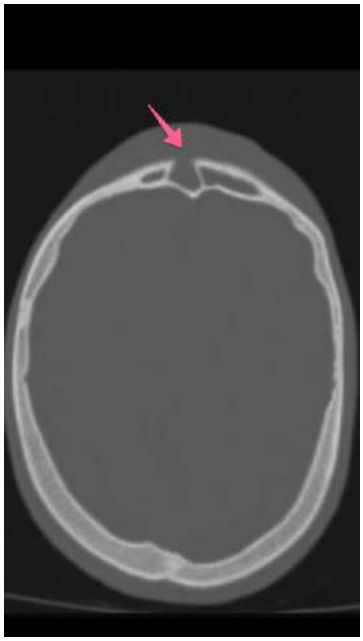

Computed tomography image of the case

Materials and Methods: A 26-year-old male presented to our emergency department with a one-week history of headache and newly developed swelling in the frontal region. He had no known comorbidities. On physical examination, a 3×4 cm non-hyperemic, non-fluctuant swelling was observed in the frontal area (Image 1). Otolaryngological examination revealed bilateral nasal polypoid lesions and purulent discharge. The patient's vital signs were stable, and neurological examination was unremarkable (GCS: 15). Laboratory investigations showed no significant abnormalities. Maxillofacial computed tomography demonstrated loss of aeration in all sinuses (pansinusitis) and marked destruction of the anterior wall of the frontal sinus (Image 2). Emergency surgery was recommended, and a Neurosurgery consultation was planned; however, the patient and his relative declined surgical intervention and refused treatment.

Image 1



Image of the forehead area of the case

Materials and Methods: PPT may initially present with a simple headache but can progress to a life-threatening condition. In our case, the frontal swelling detected on physical examination and the bone destruction observed on imaging were key indicators of complicated pansinusitis. The gold standard treatment consists of broad-spectrum antibiotic therapy and surgical drainage. However, when a patient refuses treatment, thorough documentation of the associated risks is crucial from a medico-legal perspective. In conclusion, in cases of sinusitis presenting with frontal swelling, bone destruction and intracranial extension must be carefully excluded.

Keywords: Emergency Department, Pott's Puffy Tumor, Frontal Sinus Destruction

Ref No: 6493

Lithium Intoxication

Neslihan Sağlam[1], Murat Seyit[1], Mert Özen[1], Alten Oskay[1], Atakan Yılmaz[1], İbrahim Türkçüer[1]
[1]Pamukkale University Faculty of Medicine

Murat Seyit / Pamukkale University Faculty of Medicine

Introduction and Purpose: Lithium is a commonly used agent in the treatment of bipolar disorder and has a narrow therapeutic range, making toxicity a frequent concern in emergency settings. Most cases of lithium toxicity encountered in the emergency department are not due to acute overdose but rather result from impaired renal excretion in patients on chronic therapy In addition, commonly prescribed medications such as nonsteroidal anti-inflammatory drugs (NSAIDs), angiotensin-converting enzyme inhibitors (ACE inhibitors), angiotensin II receptor blockers (ARBs), and diuretics can reduce lithium clearance and increase toxicity risk. The aim of this study is to present a case of lithium intoxication presenting with neurological symptoms in the emergency department.

Materials and Methods: A 76-year-old female patient with a history of bipolar disorder on chronic lithium therapy was admitted to the emergency department with complaints of fluctuating consciousness, psychomotor slowing, unsteady gait, tremor in the upper extremities, and speech disturbance for one week. On admission, her vital signs were stable and her Glasgow Coma Scale score was 14 (E4M6V4). Neurological examination revealed speech impairment without any lateralizing deficits. Brain computed tomography and diffusion magnetic resonance imaging showed no acute pathology. Laboratory evaluation revealed a serum lithium level of 2.58 mmol/L. The patient was diagnosed with lithium intoxication and intravenous hydration was initiated. After nephrology consultation, the patient underwent hemodialysis. Following dialysis, the serum lithium level decreased to 0.81 mmol/L. However, due to persistent neurological symptoms, the patient was admitted to the internal medicine intensive care unit for further management and monitoring.

Materials and Methods: Lithium toxicity is an important clinical condition in the emergency department, and serum lithium levels do not always correlate with clinical findings.Therefore, lithium toxicity should always be considered in patients using lithium who present with acute changes in mental status, tremor, gait disturbance, or speech impairment. Clinical evaluation should not rely solely on serum lithium levels but should be guided by the patient's overall clinical condition. Awareness of risk factors, early recognition, and appropriate management are crucial. Patients should be educated to discontinue lithium during dehydration, consult healthcare professionals before starting new medications, and seek immediate medical attention if early signs of toxicity occur.

Keywords: Lithium intoxication, neurological symptoms, hemodialysis

---

Ref No: 6537

Subarachnoid Hemorrhage: "The Worst Headache of My Life"

Mert Can Yılmaz[1], Murat Seyit[1], Duygu Aras Seyit[2], Alten Oskay[1], Atakan Yılmaz[1], Mert Özen[1]

[1]Pamukkale University Faculty of Medicine
[2]ERPA Saglik Hospital, Denizli

Murat Seyit / Pamukkale University Faculty of Medicine

Introduction and Purpose: Headache is one of the most common reasons for emergency department visits. Even in patients with a prior history of migraine, a sudden-onset headache reaching maximal intensity within seconds (thunderclap headache) is a red flag for subarachnoid hemorrhage (SAH). Early non-contrast computed tomography (CT) may occasionally be normal; therefore, sustained clinical suspicion is essential.

Materials and Methods: A 39-year-old woman presented with an abrupt, severe headache described as "a sledgehammer striking the back of my neck." The pain was accompanied by nausea and photophobia. Although she had a prior diagnosis of migraine, she emphasized that this episode was distinctly different and the most severe headache she had ever experienced. She was conscious but visibly distressed. Vital Signs: Blood pressure was 168/94 mmHg, heart rate 104 beats/min, oxygen saturation 99% on room air, and temperature 36.5°C. Physical Examination: Neurological examination revealed mild neck stiffness. No focal neurological deficits were detected. Laboratory Findings: Leukocyte count was 12.1 K/µL, and C-reactive protein was 3 mg/L. Coagulation parameters were within normal limits. Troponin levels were negative. Imaging: A non-contrast cranial CT performed within the first four hours of symptom onset demonstrated findings consistent with subarachnoid hemorrhage. Management: Neurosurgical consultation was obtained immediately, and the patient was admitted to the intensive care unit. Blood pressure was carefully controlled to reduce the risk of rebleeding while maintaining adequate cerebral perfusion.

Materials and Methods: A prior history of migraine does not provide reassurance in the setting of sudden, severe headache. Thunderclap headache and meningeal signs should prompt urgent evaluation for subarachnoid hemorrhage, even if early imaging is initially unremarkable. Early recognition and timely intervention significantly reduce neurological morbidity and mortality.

Keywords: Subarachnoid hemorrhage, intracranial aneurysm, headache disorders

Ref No: 6562

Hypotension As An Initial Presentation Of Sepsis

Mustafa Erkam Dut[1], Murat Seyit[1], Duygu Aras Seyit[2], Mert Özen[1], Alten Oskay[1], Atakan Yılmaz[1]

[1]Pamukkale University Faculty of Medicine
[2]ERPA Saglik Hospital, Denizli

Murat Seyit / Pamukkale University Faculty of Medicine

Introduction and Purpose: Sepsis is a life-threatening organ dysfunction caused by a dysregulated host response to infection. Hypotension may represent early septic shock and requires rapid recognition and intervention in the emergency department.

Materials and Methods: A 67-year-old male presented to the emergency department with complaints of dysuria and visible hematuria. He had a history of post-traumatic urethral stricture but no other chronic medical illnesses. On arrival, he appeared somnolent and lethargic. Vital signs revealed hypotension, while heart rhythm was normal sinus on ECG. Physical examination showed no abdominal guarding or rebound tenderness. Rectal examination was unremarkable. Initial laboratory evaluation demonstrated elevated inflammatory markers (CRP 51 mg/L) and significantly increased procalcitonin (90 ng/mL), suggestive of severe bacterial infection. Serum creatinine was mildly elevated at 1.27 mg/dL, indicating possible early renal involvement. Despite intravenous fluid resuscitation, hypotension persisted, raising suspicion for septic shock. Cranial imaging was performed due to altered mental status and revealed no acute intracranial pathology. Given persistent hemodynamic instability and laboratory findings, a diagnosis of sepsis of probable urinary origin was considered.

Procalciton

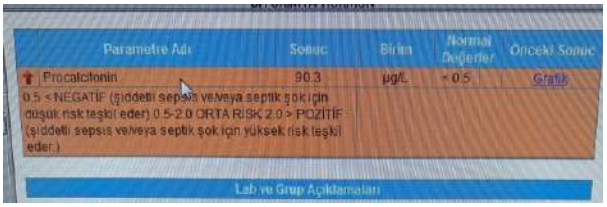

Procalciton

Materials and Methods: Blood cultures were obtained prior to initiation of broad-spectrum intravenous antibiotics. The patient was admitted for close hemodynamic monitoring and further management. This case illustrates that sepsis should be strongly considered in elderly patients presenting with unexplained hypotension and altered consciousness.

Keywords: Sepsis, Septic shock, Hypotension

Ref No: 6608

Proximal Femoral Physeal Injury After Skiing Trauma in an Adolescent: An Emergency Department Case Report

Hatice Merve Yüksel[1] [1]Kayseri State Hospital

Hatice Merve Yüksel / Kayseri State Hospital

Introduction and Purpose: Background: Proximal femoral fractures in children are rare injuries, accounting for approximately 1% of all pediatric fractures, but they are associated with serious complications such as avascular necrosis, growth disturbances, and malunion. Early diagnosis in the emergency department is essential, especially in adolescents presenting with hip pain after trauma, as delayed recognition may increase the risk of complications.

Materials and Methods: Case Presentation: A 14-year-old male presented to the emergency department after a skiing accident resulting in a fall. The patient complained of left hip and groin pain and difficulty bearing weight.Physical examination revealed tenderness over the proximal lateral region of the left femur. Pain increased with weight bearing and during hip movement. Other compression tests were negative and no neurovascular deficit was detected.Pelvic radiography suggested a possible abnormality in the proximal femoral physis near the greater trochanter region. To further evaluate the suspected injury, computed tomography (CT) imaging was performed.CT imaging demonstrated findings compatible with a proximal femoral physeal injury, raising suspicion of a fracture involving the growth plate.The patient was managed conservatively in the emergency department with bed rest, non-weight-bearing instructions, and analgesic therapy. He was discharged with recommendations for orthopedic outpatient follow-up and reassessment, with the possibility of surgical planning depending on subsequent evaluation.Discussion: Pediatric proximal femoral injuries are uncommon but clinically significant because of the risk of complications such as avascular necrosis and growth plate disturbances. Diagnosis may be challenging in emergency settings because initial radiographs

can appear subtle or inconclusive. In suspicious cases, advanced imaging such as CT or MRI is recommended to better characterize the fracture pattern and guide management.Early recognition in the emergency department allows appropriate immobilization, orthopedic consultation, and timely management, which are essential to reduce long-term morbidity.Conclusion: Proximal femoral physeal injuries should be considered in adolescents presenting with hip pain after trauma, even when initial radiographs are inconclusive. Emergency physicians should maintain a high index of suspicion and utilize advanced imaging when necessary to avoid delayed diagnosis and potential complications.

Figure 1. Pelvic radiograph demonstrating suspected irregularity at the proximal femoral physis of the left hip.



Figure 2. Computed tomography image showing findings compatible with proximal femoral physeal injury.



Keywords: Proximal femoral physeal injury, Adolescent trauma, Hip pain

Ref No: 6711

Ocular Trauma Presentations to a Tertiary Emergency Department: Demographic Characteristics, Injury Mechanisms, and Clinical Outcomes

Hasret Demir[1], Behcet Al[1]

[1]Istanbul Medeniyet Uiversity

Hasret Demir / Istanbul Medeniyet Uiversity

Introduction and Purpose: Objective:This study aimed to evaluate the demographic characteristics, etiological factors, associated injuries, and clinical outcomes of patients presenting to a tertiary emergency department with ocular trauma.

Table 1. Demographic characteristics, trauma mechanisms, and physical examination findings of patients with ocular trauma

Variable	All patients (N=6557) / N (%)
Sex	
Male	5598 (85.4)
Female	959 (14.6)
Age (years)	
0-9	187 (2.9)
10-19	597 (9.1)
20-39	3467 (52.9)
40-59	1879 (28.7)
60-80	427 (6.5)
GCS	
15	6546 (99.8)

13-15	5 (0.1)
10-13	1 (0.01)
8-10	0 (0)
<8	5 (0.1)
Trauma mechanism	
Ocular foreign body	5832 (88.9)
Fall	342 (5.2)
Blunt trauma	227 (3.5)
Traffic accident	71 (1.1)
Penetrating or sharp object injury	47 (0.7)
Chemical injury	29 (0.4)
Unknown mechanism	8 (0.1)
Burn	1 (0.01)
Identified findings	
No finding	30 (0.5)
Any finding	6527 (99.5)
Corneal abrasion	2023 (30.9)
Conjunctival hyperemia	1679 (25.6)
Epithelial injury	1391 (21.2)
Subconjunctival hemorrhage	851 (13)
Periorbital edema	388 (5.9)

Eyelid incision	63 (1)
Eyelid laceration	51 (0.8)
Chemosis	30 (0.5)
Full-thickness eyelid laceration	23 (0.4)
Corneal punctate epitheliopathy	16 (0.2)
Hyphema	6 (0.1)
Gaze limitation	3 (0.04)
Kor Full-thickness corneal laceration	2 (0.03)
Lens dislocation	1 (0.01)

Table 1. Demographic characteristics, trauma mechanisms, and physical examination findings of patients with ocular trauma

Table 2. Radiological findings, associated injuries, surgical interventions, and clinical outcomes

Variables	**All patients (N=6557) / N (%)**
Images	
No CT performed	5990 (91.4)
Radiological Findings Detected in the Eye	567 (8.6)
No pathological finding	378 (5.8)
Orbital floor fracture	88 (1.3)
Orbital lateral wall fracture	49 (0.7)
Orbital medial wall fracture	26 (0.4)

Orbital roof fracture	21 (0.3)
Globe perforation	4 (0.1)
Lens dislocation	1 (0.01)
Associated injuries in adjacent regions	
No associated injury	6289 (95.9)
Any associated injury	268 (4.1)
Nasal bone fracture	97 (1.5)
Maxillary fracture	88 (1.3)
Zygomatic fracture	32 (0.5)
Cranial fracture	32 (0.5)
Facial laceration	19 (0.3)
Surgical intervention	
Surgery performed	98 (1.5)
No surgery	6459 (98.5)
Outcome	
Discharge from ED	6421 (97.9)
Hospital admission	136 (2.1)
-ICU Admission	10 (0.2)
-Ward admission	126 (1.9)
Ophthalmology ward	48 (0.7)
Admission to other clinics	78 (1.2)

Table 2. Radiological findings, associated injuries, surgical interventions, and clinical outcomes

Table 3. Trauma mechanisms according to sex

Mechanism	**Male (N=5598) /** N (%)	**Female (N=959)** / N (%)	**P value**
Ocular foreign body	5083 (90.8)	749 (78.1)	**<0.001**
Falls	216 (3.9)	126 (13.1)	**<0.001**
Blunt trauma	191 (3.4)	36 (3.8)	0.592
Traffic accidents	52 (0.9)	19 (2)	**0.004**
Penetrating or sharp object injury	30 (0.5)	17 (1.8)	**<0.001**
Chemical injuries	18 (0.3)	11 (1.1)	**0.002**
Unknown mechanism	7 (0.1)	1 (0.1)	1
Burns	1 (0.01)	0 (0)	-

Table 3. Trauma mechanisms according to sex

Materials and Methods: This retrospective observational study included 6,557 patients who presented to the Emergency Department of Prof. Dr. Suleyman Yalcin City Hospital with ocular trauma between 2022 and 2025. Demographic data, trauma mechanisms, physical examination findings, associated injuries, need for surgical intervention, and clinical outcomes were evaluated. Categorical variables were analyzed using the chi-square test, while Student's t-test and the Mann–Whitney U test were used for continuous variables

Materials and Methods: Of the patients, 85.4% (n=5,598) were male, and 52.9% were aged between 20 and 39 years. The most common reason for presentation was ocular foreign body injury (88.9%), and the most frequent physical examination finding was corneal abrasion (30.9%). Computed tomography was performed in 8.6% of cases. No injuries accompanying ocular trauma were identified in 95.9% of patients, and 1.5% required surgical intervention. Overall, 97.9% of patients were discharged from the emergency department. Ocular foreign body injury ($p < 0.001$), falls ($p < 0.001$), traffic accidents ($p=0.004$), penetrating or sharp object injuries ($p < 0.001$), and chemical injuries ($p=0.002$) were more frequent in males. Female sex ($p < 0.001$), age over 60 years ($p < 0.001$), Glasgow Coma Scale score below 13 ($p < 0.001$), and the presence of associated injuries ($p < 0.001$) were associated with increased surgical

intervention. Female sex ($p < 0.001$), age under 9 years ($p < 0.001$) and over 60 years ($p < 0.001$), Glasgow Coma Scale score ≤13, presentation due to falls ($p < 0.001$) or traffic accidents ($p < 0.001$), and the presence of orbital or extraocular bone fractures ($p < 0.001$) were associated with higher hospitalization rates.Conclusion:Ocular trauma predominantly affected young males and was most commonly caused by foreign bodies. Corneal abrasion was the most frequent finding. Most cases involved isolated ocular trauma, did not require computed tomography, and were discharged from the emergency department. Female sex, pediatric and geriatric age groups, low GCS, and trauma related to falls or traffic accidents were associated with increased surgical intervention and hospitalization.

Keywords: Eye, injuries, mechanism0

Ref No: 6715

Pulmonary embolism presenting as acute coronary syndrome mimic in a young patient

Erdem Zeki Karabulut[1], Mevlana Gül[1], İbrahim Köroğlu Kılıç[1]
[1]Ataturk University
Erdem Zeki Karabulut / Ataturk University

Introduction and Purpose: Pulmonary embolism (PE) is a potentially fatal condition with variable clinical presentation. In rare cases, it may mimic acute coronary syndrome (ACS), especially when presenting with chest pain and elevated cardiac biomarkers, leading to diagnostic confusion.

Materials and Methods: A 26-year-old previously healthy male presented with acute-onset retrosternal chest pain. The pain was non-radiating and not associated with dyspnea or syncope. Vital signs were stable. Electrocardiography (ECG) revealed nonspecific ST-segment changes, and initial high-sensitivity troponin was mildly elevated. Based on these findings, ACS was initially suspected. However, the absence of cardiovascular risk factors and persistent symptoms prompted further evaluation. D-dimer level was significantly elevated (2.1 µg/mL). Computed tomography pulmonary angiography (CTPA) revealed segmental pulmonary embolism in the right lower lobe. Lower extremity Doppler ultrasonography did not demonstrate deep vein thrombosis.

Materials and Methods: Anticoagulation therapy was initiated with rapid clinical improvement. This case demonstrates that PE can mimic ACS, even in young patients without risk factors. Mild troponin elevation may result from right ventricular strain rather than myocardial infarction. Clinicians should consider PE in the differential diagnosis of chest pain with inconclusive findings to avoid misdiagnosis and inappropriate management.

Keywords: Pulmonary embolism, chest pain, acute coronary syndrome

Ref No: 6756

Traumatic Aortic Dissection

Berk Oral[1], Ali Gür[1]

[1]Atatürk University

Berk Oral / Atatürk University

Introduction and Purpose: Traumatic aortic dissection is a rare but highly lethal injury, most often caused by high velocity blunt trauma such as motor vehicle accidents or falls from height. It occurs when the intimal layer of the aorta tears, allowing blood to track between layers of the vessel wall. This can rapidly progress to rupture if not recognized and treated. Early detection and intervention are critical for survival.

Materials and Methods: A 35 year old male was brought to the emergency department after a high speed motor vehicle collision. On arrival, he was hypotensive and tachycardic, with chest pain and shortness of breath. Physical examination revealed diminished breath sounds on the left side and chest wall ecchymosis. CT angiography confirmed traumatic dissection of the ascenden aorta with rib fractures, pneumothorax, and pneumomediastinum. The patient was immediately stabilized with intravenous fluids and blood products, and vascular surgery was consulted. He underwent urgent endovascular stent graft placement to seal the dissection and restore aortic integrity.

Materials and Methods: Traumatic aortic dissection should be suspected in patients with high energy blunt chest trauma, especially when imaging shows mediastinal widening. Early diagnosis with CT angiography and rapid surgical or endovascular repair are lifesaving. Maintaining a high index of suspicion in trauma cases is essential, as delayed recognition often leads to progression to rupture and fatal outcomes.

BT image



Keywords: trauma, aort dissection

Ref No: 6803

PROGRESSION FROM CONJUNCTIVITIS TO PERIORBITAL CELLULITIS UNRESPONSIVE TO NETILMICIN SULFATE TREATMENT: A CASE REPORT

ALARA NERGİZ SOSLU[1], ZEYNEP ÇAKIR[1]

[1]ATATURK UNIVERSITY FACULTY OF MEDICINE, DEPARTMENT OF EMERGENCY MEDICINE

ALARA NERGİZ SOSLU / ATATURK UNIVERSITY FACULTY OF MEDICINE, DEPARTMENT OF EMERGENCY MEDICINE

Introduction and Purpose: Acute conjunctivitis is a common, usually self-limiting pathology encountered in emergency departments. However, in cases where clinical improvement cannot be achieved despite appropriate treatment, spread of infection to surrounding tissues may occur. Periorbital cellulitis is an infection of the eyelid and surrounding soft tissues, which may require careful clinical follow-up and hospitalization due to the risk of progression to sight-threatening orbital cellulitis.

Materials and Methods: A 30-year-old male patient presented to our emergency department with complaints of swelling, increased temperature, and hardness in the periorbital region. From the patient's history, it was learned that he had applied to another center a week ago with a complaint of itching in the right eye and was prescribed eye drops containing netilmicin sulfate. It was observed that the patient, whose symptoms did not regress despite one week of regular treatment, developed edema and erythema around the right eye.On emergency department

examination, significant tenderness and induration were detected in the right periorbital area. The patient was consulted with the ophthalmology department. As a result of the evaluation, the patient was diagnosed with periorbital cellulitis and was admitted to the ophthalmology ward for intravenous antibiotic treatment and close clinical monitoring.

PERIORBITAL CELLULITIS



PERIORBITAL CELLULITIS



Materials and Methods: In patients started on treatment with a preliminary diagnosis of conjunctivitis, caution should be exercised regarding complications if the symptoms do not regress or if local infection findings (increased heat, hardness, edema) increase. The management of such cases in the emergency department should include rapid consultation and, if necessary, hospitalization to prevent the progression of the infection to deep tissues.

Keywords: periorbital cellulitis, preseptal cellulitis, conjunctivitis

Ref No: 6936

Flail Chest

Murat GÜR[1]

[1]Flail Chest

Murat GÜR / Flail Chest

Introduction and Purpose: Introduction: Flail chest, also known as 'flail chest', refers to blunt chest trauma. This type of chest injury, characterized by fractures in two or more adjacent ribs, occurs particularly after high-energy trauma such as severe traffic accidents, falls, or collisions.Purpose : Flail chest develops after severe injuries, especially sudden trauma, but affects the entire chest. Therefore, early treatment is extremely important because untreated sailing chest can lead to life-threatening problems such as lung contusion, pneumothorax, hemothorax, and shock.

flail chest



flail chest

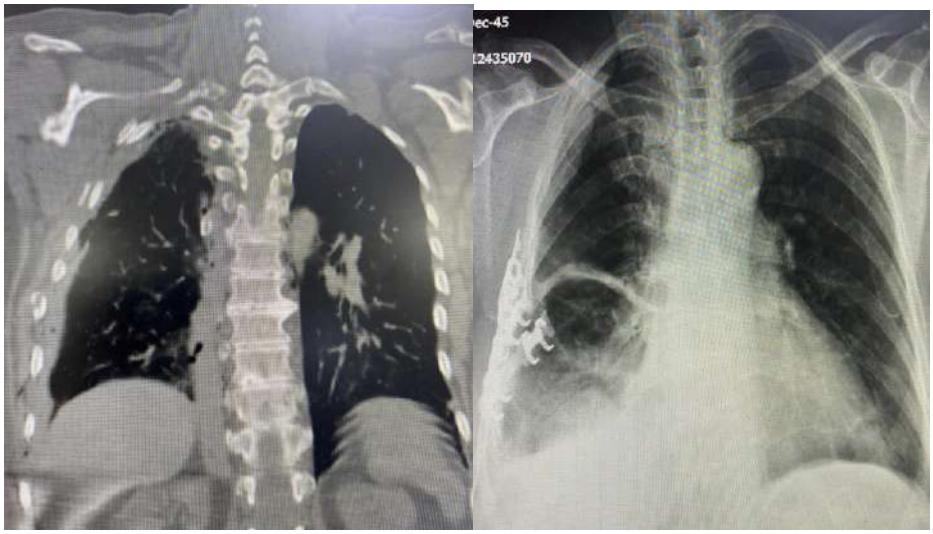

flail chest

Materials and Methods: Case: A 79-year-old female patient was brought to the emergency department by ambulance after a non-vehicular traffic accident. Her medical history included hypertension and rheumatoid arthritis. Blood pressure measured at presentation was 110/50, respiratory rate: 18, saturation: 95, conscious, general condition fair. Abdominal examination was unremarkable, nm: normal, ss: rales present in right lung sounds. The aim of this study is to emphasize that early and supportive treatment is extremely important in cases where flail chest is detected. Otherwise, more serious problems that cause life-threatening complications may arise, and if treatment is delayed, cases may result in death. Imaging performed on our patient revealed multiple rib fractures and accompanying hemothorax in the right hemithorax.Following this, the patient was referred to thoracic surgery and intensive care, and admitted to intensive care for further examination and treatment.

Results and Conclusion: Discussion: As is well known, flail chest cases are easily recognizable by paradoxical chest movements. Approximately 5 to 15 percent of chest wall injuries develop into flail chest. This disease, characterized by the chest wall moving inward during inhalation and outward during exhalation, can be detected by symptoms such as respiratory distress. In some patients, this disease can be diagnosed by advanced imaging tests even without these symptoms. Indeed, in our case, although paradoxical breathing had not yet developed, the diagnosis was made by imaging and clinical examination.Conclusion: Patients with flail chest are at high risk of developing life-threatening complications such as pneumothorax, hemothorax, and shock. Protecting the airway is crucial in the initial intervention.Chest stabilization, early diagnosis, and early intervention are of vital importance in these patients.

Keywords: pneumothorax, hemothorax, flail chest

Ref No: 6955

Infective Endocarditis

Büşra Nur Gülbahar Minisker[1], Murat Seyit[1], Atakan Yılmaz[1], Mert Özen[1], Alten Oskay[1], İbrahim Türkçüer[1]

[1]Pamukkale University Faculty of Medicine

Murat Seyit / Pamukkale University Faculty of Medicine

Introduction and Purpose: Infective endocarditis (IE) is an infection of the endocardial surface. In patients who use intravenous drugs, it may involve the right-sided heart valves (most commonly the tricuspid valve) and present with symptoms resembling septic pulmonary emboli or pneumonia. Early diagnosis—supported by blood cultures, echocardiography, and a multidisciplinary approach—is critical for reducing mortality and complications.

Materials and Methods: A 25-year-old man presented to the emergency department with a 2-day history of chest pain, shortness of breath, cough, sputum production, and fever. His past medical history was notable for hepatitis C. Vital signs were as follows: temperature 36.6°C, SpO_2 90% on room air, heart rate 121 bpm, and blood pressure 109/69 mmHg. On physical examination, lung auscultation and the remaining systemic examination were unremarkable. Further history revealed intravenous drug use for 8 years, a 1-week admission to an addiction treatment center and discharge 4 days prior. ECG findings were consistent with sinus tachycardia. Transthoracic echocardiography showed a suspicious appearance on the tricuspid valve consistent with a vegetation measuring approximately 23 × 21 mm (LVEF 55%).

Materials and Methods: In a young patient with intravenous drug use, “pneumonia-like” symptoms may mask infective endocarditis (IE). In this case, the presence of hypoxemia and tachycardia together with suspected tricuspid vegetation strengthened the likelihood of IE. An appropriate approach includes obtaining three sets of blood cultures from separate venipuncture sites, initiating empiric broad-spectrum antibiotic therapy in consultation with infectious diseases, and early coordination with units such as cardiovascular surgery and the intensive care unit. Early multidisciplinary management is effective in reducing the risk of embolic complications, sepsis, and mortality.

Keywords: Infective endocarditis, Vegetation, Septic emboli

Ref No: 6974

Protein-losing enteropathy presenting with edema and diarrhea in the emergency department

İbrahim köroğlu Kılıç[1], Zeynep Gökcan çakır[1]

[1]Atatürk üniversitesi

İbrahim köroğlu Kılıç / Atatürk üniversitesi

Introduction and Purpose: Protein-losing enteropathy (PLE) is a rare and often underdiagnosed condition characterized by excessive loss of plasma proteins into the gastrointestinal tract. It may present with nonspecific symptoms in the emergency department (ED).

Materials and Methods: A 24-year-old male presented to the ED with a 3-week history of diarrhea, abdominal pain, and bilateral leg swelling. Physical examination revealed pretibial edema (++). Laboratory analysis showed hypoalbuminemia (2.1 g/dL). Abdominal computed tomography (CT) was unremarkable. Stool alpha-1 antitrypsin clearance was elevated.

Materials and Methods: A 24-year-old male presented to the ED with a 3-week history of diarrhea, abdominal pain, and bilateral leg swelling. Physical examination revealed pretibial edema (++). Laboratory analysis showed hypoalbuminemia (2.1 g/dL). Abdominal computed tomography (CT) was unremarkable. Stool alpha-1 antitrypsin clearance was elevated.

Keywords: Protein-losing enteropathy, edema, diarrhea

Ref No: 6977

Semaglutide-Associated Euglycemic Ketoacidosis in a Young Woman: A Case Report

ESMA BULUT[1]

[1]BAYBURT DEVLET HASTANESİ

ESMA BULUT / BAYBURT DEVLET HASTANESİ

Introduction and Purpose: Euglycemic ketoacidosis (EKA) is characterized by high anion gap metabolic acidosis with elevated serum ketones, occurring in the presence of normal or mildly

elevated blood glucose. Although typically seen in diabetic patients due to absolute or relative insulin deficiency, it may also occur in non-diabetic individuals with risk factors such as fasting, vomiting, excessive alcohol use, or pregnancy. Semaglutide, a glucagon-like peptide-1 (GLP-1) receptor agonist, is widely used for type 2 diabetes and weight management. While generally safe, gastrointestinal side effects including nausea and vomiting are common, and cases of semaglutide-associated EKA have been reported.

Materials and Methods: A 25-year-old woman presented with severe nausea and vomiting for 2 days. Symptoms began shortly after initiating semaglutide. She had no history of trauma, smoking, or alcohol use, and her medical history included asthma and obesity. Medications included semaglutide and a salbutamol inhaler. On examination: temperature 36.5°C, blood pressure 101/72 mmHg, heart rate 120 bpm, O_2 saturation 97%, and an unremarkable abdominal exam. Laboratory results revealed pH 7.1, HCO_3 9 mmol/L, glucose 86 mg/dL, and serum ketones 3+. Liver and renal function tests were normal. ECG showed sinus tachycardia without other abnormalities. Chest and abdominal X-rays were normal. The patient received hydration and symptomatic treatment and was admitted to the intensive care unit with a presumptive diagnosis of EKA. Contrast-enhanced abdominal imaging showed no additional pathology. By day 4, her symptoms fully resolved, and she was referred to endocrinology for further evaluation and follow-up.

Materials and Methods: Semaglutide delays gastric emptying, increases insulin sensitivity, reduces glucagon secretion, and decreases caloric intake. The proposed mechanism for EKA involves reduced insulin levels and increased glucagon, leading to fasting-like ketoacidosis, enhanced lipolysis, and ketone production, resulting in high anion gap metabolic acidosis. Early recognition of EKA is critical for effective management, which includes glucose-containing fluids and correction of electrolyte abnormalities. This case highlights the importance of maintaining high clinical suspicion for semaglutide-associated EKA, especially as GLP-1 receptor agonist use for weight loss becomes more widespread.

Keywords: Semaglutide; Euglycemic Ketoacidosis; GLP-1 Receptor Agonist

---

Ref No: 6981

INFECTION-RELATED NEUTROPENIA

Erdal Tekin[1], Hakan Alp[1], Fatih Fırat[1]
[1]Erzurum Atatürk Üniversitesi Araştırma Hastanesi

Hakan Alp / Erzurum Atatürk Üniversitesi Araştırma Hastanesi

Introduction and Purpose: Infection-related neutropenia is a condition where the number of white blood cells called neutrophils in the blood falls below normal levels due to an infection. Neutrophils are essential and vital cells that help the immune system fight against infections.

Materials and Methods: A 63-year-old male patient presented with complaints of malaise and fatigue lasting for 1 week. He has a history of surgery for a brain tumor 25 years ago and is not currently receiving active treatment. He was hospitalized in the Psychiatry clinic for psychosis 2 weeks ago and was discharged 1 week ago. He has no additional chronic illnesses. When the medical history was deepened, it was learned that the patient's cough complaints, which had been present for 1 month, increased in the last week. He has no additional complaints. Upon arrival, other than SPO2:85 and Fever:37.5, his vitals were unremarkable. Oropharynx was natural. Rhonchi and wheezing were present in the basal areas of the lung sounds. In the patient's chest X-ray, scattered pneumonic infiltrations were observed. In the obtained laboratory tests, the blood gas showed so2:85 and pao2:47. CRP: 177. In the hemogram, WBC: 0.67, Neutrophil: 30, Platelet and Hemoglobin were normal, and an increased lymphocyte percentage was observed. Supportive treatment was initiated. The patient was consulted with the Chest Diseases clinic with a pre-diagnosis of Pneumonia and the Internal Medicine clinic with a pre-diagnosis of Neutropenia. In the patient's peripheral smear, atypical lymphocytes thought to be secondary to infection were observed. The patient, whose pneumonia treatment was arranged by the Chest Diseases clinic, was admitted to the Internal Medicine clinic.

Materials and Methods: In patients presenting with complaints of malaise and fatigue, it is necessary to perform a detailed investigation, especially regarding an infective focus. It should not be forgotten that, although rare, infections can cause neutropenia.

Keywords: Pneumonia, neutropenia, cough.

Ref No: 7004

The critical role of EEG in differentiating encephalitis from prolonged postictal state

Mustafa Çiftçi, Abdülaziz Doğan, Muhammed Sadettin İpek, Emin Fatih Vişneci, Mehmet Gül

[1]Emergency Medicine Department, Konya City Hospital, Türkiye

Abdülaziz Doğan / Emergency Medicine Department, Konya City Hospital, Türkiye

Introduction and Purpose: The postictal state is a period of transient neurophysiological dysfunction following an epileptic seizure, lasting until the patient returns to their baseline

neurological status. While it typically resolves within minutes, it can persist for hours or even days in some cases. This prolonged state can clinically mimic acute neurological emergencies such as encephalitis, nonconvulsive status epilepticus, and metabolic encephalopathy. In this report, we aim to present a case initially managed as encephalitis but ultimately diagnosed as a prolonged postictal state utilizing an electroencephalogram (EEG).

Materials and Methods: An 18-year-old female with no known comorbidities or routine medication use presented to the emergency department (ED) with altered mental status and nonsensical speech. The history obtained from relatives revealed that just prior to admission, she experienced a seizure lasting several seconds, characterized by foaming at the mouth, left-sided body contractions, and upward eye deviation. Additionally, she had a one-week history of intermittent fever and diarrhea. Following normal laboratory results and cranial neuroimaging, a lumbar puncture (LP) was performed. The patient was admitted to the neurology intensive care unit (ICU) with preliminary diagnoses of viral and autoimmune encephalitis.

Materials and Methods: Results and Conclusion: In the ICU, cerebrospinal fluid (CSF) analysis was expanded. The CSF cultures and autoimmune encephalitis panel results showed no pathological findings to support encephalitis. Subsequent EEG evaluations confirmed that her prolonged altered mental status was due to an extended postictal state. The patient was successfully treated with antiepileptic medication and discharged. In conclusion, in patients presenting with prolonged altered mental status, nonconvulsive status epilepticus must be definitively excluded. This case demonstrates that a prolonged postictal state can clinically mimic encephalitis. In patients with prolonged post-seizure consciousness disorders, metabolic causes, infections, encephalitis, and nonconvulsive status epilepticus must be carefully excluded.

Keywords: Prolonged postictal state, encephalitis, electroencephalogram

---

Ref No: 7032

Synthetic Cannabinoid (Bonzai)-Induced Acute Coronary Vasospasm and ST-Elevation Myocardial Infarction (STEMI)

ŞAFAK ÇOMURLU[1]

[1]ATATURK UNIVERSTY

ŞAFAK ÇOMURLU / ATATURK UNIVERSTY

Introduction and Purpose: Introduction: Synthetic cannabinoids (SCs) are prevalent drugs of abuse that remain undetected in standard urine toxicology screens and can lead to severe cardiovascular adverse effects. The incidence of acute myocardial infarction (AMI) secondary to SC use is rising among young individuals without atherosclerotic risk factors. This report presents the case of a young patient who presented with a clinical picture of STEMI shortly after SC use.

Materials and Methods: Case Presentation: A 22-year-old male patient was brought to the emergency department (ED) with severe retrosternal chest pain and diaphoresis that began following substance use (Bonzai). His medical history was negative for any chronic diseases. The initial electrocardiogram (ECG) revealed 4 mm ST-segment elevations in the inferior leads (II, III, aVF) with reciprocal depressions. The patient was transferred to the catheterization laboratory for primary percutaneous coronary intervention (PCI). Coronary angiography demonstrated no evidence of thrombus or atherosclerotic plaque; however, severe diffuse vasospasm was observed in the right coronary artery (RCA). The spasm resolved following the administration of intracoronary nitroglycerin, and the ST segments returned to the isoelectric baseline.Discussion: SCs induce a massive sympathetic discharge, tachycardia, hypertension, and coronary vasospasm by overstimulating CB1 receptors in the myocardium. Similar to cocaine toxicity, the use of beta-blockers is contraindicated in these patients, as it leads to unopposed alpha-adrenergic activity, which can exacerbate coronary spasm (coronary steal phenomenon). In the ED management of these cases, benzodiazepines (for sedation and dampening the sympathetic surge) and nitrates constitute the first-line treatment.

Materials and Methods: Conclusion: The use of synthetic cannabinoids and other sympathomimetic agents must be thoroughly investigated in young patients presenting with acute coronary syndrome in the absence of classical risk factors. The avoidance of beta-blockers is one of the most critical decision points for the emergency physician in managing these cases.

Keywords: Synthetic Cannabinoids, Coronary Vasospasm, Drug-Induced Myocardial Infarction

---

Ref No: 7091

Intrathoracic Stomach (Giant Hiatal Hernia) Presenting with Upper Gastrointestinal Bleeding and Aspiration Pneumonia: A Case Report

Cengiz Turan[1], Ertan Sönmez[1], Murtaza Kaya[1], Harun Yıldırım[1], Ali Halıcı[1], Abdil Coşkun[1]

[1]Kutahya Health Sciences University

Cengiz Turan / Kutahya Health Sciences University

Introduction and Purpose: Hiatal hernias are common conditions; however, giant hiatal hernias associated with an intrathoracic stomach are rare. In these patients, serious complications such as gastric retention, upper gastrointestinal bleeding, recurrent vomiting, and aspiration pneumonia may occur. In addition, mediastinal compression may lead to acute respiratory failure and altered consciousness. In this report, we present a case of a giant hiatal hernia presenting with upper gastrointestinal bleeding and aspiration pneumonia.

Thoracic CT scan shows giant hiatal hernia

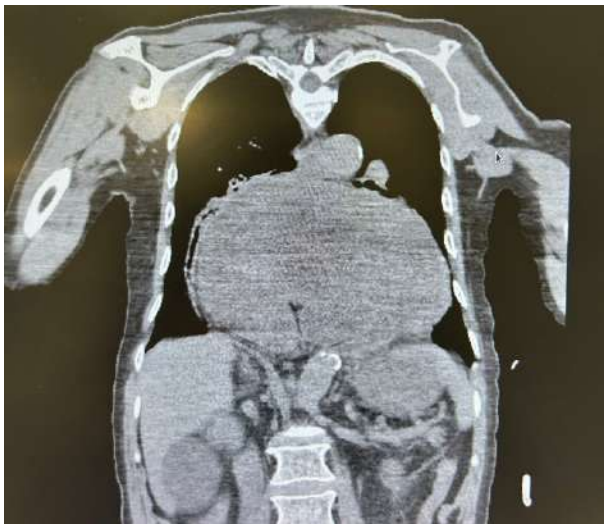

Materials and Methods: A 77-year-old male presented to the emergency department with hematemesis and repeated coffee-ground vomiting. On initial evaluation, the patient was tachycardic, and laboratory findings revealed decreased hemoglobin levels and significantly elevated lactate.Thoracic computed tomography demonstrated a giant hiatal hernia containing the stomach, consistent with an intrathoracic stomach. The same imaging also showed pulmonary infiltrates compatible with aspiration pneumonia. Proton pump inhibitor therapy and intravenous fluid resuscitation were initiated with a preliminary diagnosis of upper gastrointestinal bleeding. Oxygen therapy and supportive treatment were provided for aspiration pneumonia. With a preliminary diagnosis of upper gastrointestinal bleeding, the patient was referred for endoscopy. During the procedure, sudden clinical deterioration occurred, and the patient was transferred back to the emergency department. On reassessment, the patient had impaired consciousness (GCS: 8) and significant respiratory distress.Rapid sequence intubation was performed, and endotracheal intubation was achieved, after which the patient was placed on mechanical ventilation. The patient was admitted to the intensive care unit for further

management and close monitoring.It was later learned that the patient underwent surgical treatment following the intensive care unit course.

Figure 2. Air-fluid level in intrathoracic giant hiatal hernia



Aspiration pneumonia in the right lung



Materials and Methods: Giant hiatal hernia should be considered, although rare, in patients presenting with upper gastrointestinal bleeding and aspiration pneumonia. Mediastinal compression and aspiration due to an intrathoracic stomach may lead to acute respiratory failure and altered consciousness. Therefore, rapid evaluation and advanced airway management in the emergency department are of critical importance.

Keywords: hiatal hernia, upper gastrointestinal bleeding, aspiration pneumonia

Ref No: 7137

THE FATAL CAUSE BEHIND ATYPICAL ABDOMINAL PAIN: AORTIC DISSECTION

Erdal Tekin[1], Hakan Alp[1], Onur Murat Atmaca[1]

[1]Erzurum Atatürk Üniversitesi Araştırma Hastanesi

Erdal Tekin / Erzurum Atatürk Üniversitesi Araştırma Hastanesi

Introduction and Purpose: Aortic Dissection is a serious and life-threatening condition where a tear in the inner layer of the aorta causes blood to leak and separate the layers of the vessel wall.

Materials and Methods: A 62-year-old male patient presented with a complaint of abdominal pain for the last 3 days. He has a known diagnosis of HT (Hypertension). Additionally, he does not report diarrhea, constipation, nausea, or vomiting. When the medical history was deepened, the patient stated that the pain started in the chest area and radiated downwards. In the patient's admission vitals, blood pressure was 160/100; there was no obvious blood pressure difference between both arms, and other vitals were natural. Bilateral extremity pulses were equal and open. Physical examination of the abdomen revealed tenderness mostly in the upper quadrants and epigastric region; no defense or rebound was present. The ECG was in normal sinus rhythm with no acute pathology. There were no specific findings in the patient's blood tests. On X-rays, there were no findings other than prominence in the aortic arch. A dissection line extending from the aortic arch to the right iliac artery was observed on the computed tomography scan. A brevibloc infusion was started to maintain the patient's blood pressure at the desired level. The patient was consulted with Cardiovascular Surgery and admitted.

Abdominal CT scan images



Abdominal CT scan images

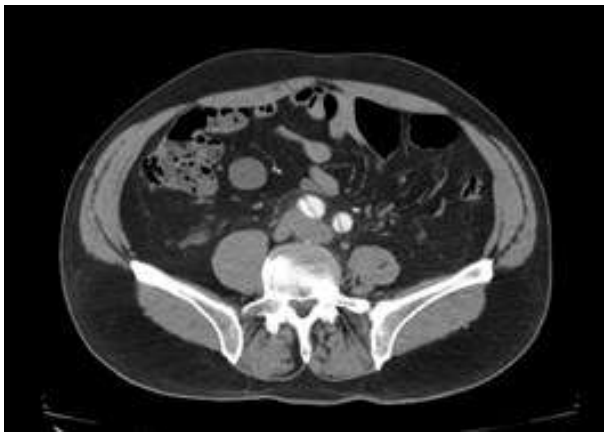

Materials and Methods: In patients presenting with abdominal pain, even if there is no blood pressure difference and the patient is not agitated, deepening the medical history and questioning the onset and progression of the pain is important for the early detection of a fatal diagnosis such as aortic dissection.

Keywords: Aortic dissection, abdominal pain

Ref No: 7180

How Reliable Is Bedside Ultrasonography in a Case of Acute Pancreatitis?

Sait Emre Aydaç[1], Murat Seyit[1], Mert Özen[1], Alten Oskay[1], Atakan Yılmaz[1], İbrahim Türkçüer[1]

[1]Pamukkale University Faculty of Medicine

Murat Seyit / Pamukkale University Faculty of Medicine

Introduction and Purpose: Abdominal pain secondary to acute pancreatitis constitutes a significant proportion of emergency department admissions. Diagnosis is based on clinical history, physical examination, laboratory findings, and imaging studies. The most common etiology is biliary in origin, and differentiation from cholecystitis or choledocholithiasis may be challenging. Although pain classically radiates in a belt-like pattern, some patients present with persistent epigastric pain. Because the pancreas is a retroperitoneal organ, computed tomography (CT) is considered the gold standard imaging modality.

Materials and Methods: A 46-year-old male with no known medical history presented to the emergency department with upper abdominal pain. His general condition was good (GCS: 15). Vital signs were: blood pressure 140/90 mmHg, heart rate 86 beats per minute, and oxygen saturation 97%.Physical examination revealed tenderness in the upper abdomen, more pronounced in the epigastric region with guarding. Electrocardiography demonstrated normal sinus rhythm.Bedside ultrasonography showed normal gallbladder size with a wall thickness of 1.93 mm. No pericholecystic fluid or intrahepatic bile duct dilation was observed, and the sonographic Murphy sign was negative. When the probe was positioned over the epigastric region, the patient's pain increased. No abdominal aortic dissection or aneurysm was detected. Although the pancreas could not be clearly visualized, increased diffuse echogenicity was noted.Laboratory findings revealed leukocytosis (WBC: 17.46 K/µL, neutrophils: 80.9%), elevated lipase (88.2 U/L; normal range 13–60 U/L), and elevated C-reactive protein (71.49 mg/dL). Other laboratory parameters were within normal limits.Contrast-enhanced CT demonstrated normal liver contour and size without focal lesions. The gallbladder and biliary ducts were normal. The pancreatic corpus was enlarged with decreased parenchymal density consistent with edema. Peripancreatic heterogeneity, free fluid, and associated lymphadenopathy were present. These findings were consistent with acute pancreatitis.

Materials and Methods: Acute pancreatitis may not always present with laboratory findings strongly suggestive of the diagnosis and may therefore be overlooked in the emergency setting. Although CT remains the gold standard imaging modality, bedside ultrasonography can facilitate early clinical suspicion and contribute to prompt diagnosis under emergency department conditions.

Keywords: Acute pancreatitis, Ultrasonography, Emergency Medicine

---

Ref No: 7181

Role of Eosinophils in Chronic Airway Diseases: A Clinical Perspective

Burcu Yormaz[1]

[1]selcuk University Medicine Faculty Department Of Chest Disease,Konya,Turkıye

Burcu Yormaz / Selcuk University Medicine Faculty Department Of Chest Disease,Konya,Turkıye

Introduction and Purpose: Eosinophilic inflammation plays a central role in chronic airway diseases such as asthma and chronic obstructive pulmonary disease (COPD). Blood eosinophil

count has emerged as a practical biomarker for guiding treatment decisions. This study aims to evaluate the clinical relevance of eosinophils in disease management.

Materials and Methods: A literature review was conducted focusing on studies evaluating eosinophil counts in predicting exacerbations and response to therapies, including inhaled corticosteroids and biologics. Associations between eosinophil levels and clinical outcomes were analyzed

Results and Conclusion: Higher eosinophil counts were associated with increased exacerbation risk but also predicted better response to corticosteroid therapy. Eosinophil-guided treatment strategies improved disease control and reduced exacerbation frequency. This biomarker is easily accessible and cost-effective for routine use.In conclusion, eosinophils represent a valuable tool in personalized management of chronic airway diseases. Incorporating eosinophil counts into clinical decision-making can enhance treatment efficacy and patient outcomes.

Keywords: Eosinophils; Asthma; COPD

Ref No: 7242

Disseminated Intravascular Coagulation

Neslihan Sağlam[1], Murat Seyit[1], Atakan Yılmaz[1], Mert Özen[1], Alten Oskay[1], İbrahim Türkçüer[1]

[1]Pamukkale University Faculty of Medicine

Murat Seyit / Pamukkale University Faculty of Medicine

Introduction and Purpose: Disseminated intravascular coagulation (DIC) is a syndrome characterized by disruption of hemostatic balance and widespread activation of intravascular coagulation due to various underlying causes. Intravascular fibrin clots may lead to occlusion in small and medium-sized vessels, resulting in impaired organ perfusion and potentially multiorgan failure. Another consequence of this process is severe bleeding due to the consumption of coagulation factors and platelets. Cutaneous manifestations are observed in approximately two-thirds of DIC patients. These findings range from small petechiae to widespread ecchymoses, ischemic skin necrosis, and hemorrhagic bullae. Skin necrosis may progress to symmetrical peripheral gangrene. Although not always identified, DIC is typically secondary to an underlying condition, most commonly infections, hematological malignancies, and solid tumors. In this report, we present a patient with a known malignancy who was diagnosed with DIC.

Materials and Methods: A 75-year-old female patient presented to the emergency department with ecchymosis on both toes. Arterial and venous Doppler ultrasonography of the lower extremities revealed no pathological findings. The patient had a known diagnosis of uterine malignancy and was under oncology follow-up. Laboratory findings showed a platelet count of 10 K/µL, D-dimer level of 35.2 mg/dL, fibrinogen level of 99.3 mg/dL, and prothrombin time of 25 seconds, with a calculated DIC score of 10. Hematology consultation suggested DIC secondary to underlying malignancy and possible infection. Following transfusion of 2 units of platelets, replacement therapy with 2×5 units of cryoprecipitate and 1×3 units of fresh frozen plasma was administered, and piperacillin-tazobactam was initiated for suspected infection. After replacement therapy, the platelet count increased to 67 K/µL, and the patient was admitted to the internal medicine intensive care unit for further monitoring and treatment.

.



Materials and Methods: In this case, we aimed to emphasize that DIC should be considered in patients with malignancy presenting to the emergency department with bleeding manifestations and abnormalities in platelet count and coagulation parameters. Early recognition and appropriate management of DIC are crucial in reducing morbidity and mortality.

Keywords: Disseminated intravascular coagulation, malignancy, skin lesions

Ref No: 7270

Acute polyneuropathies

Duygu Aras Seyit[1], Murat Seyit[2]

[1]ERPA Saglik Hospital, Denizli
[2]Pamukkale University Faculty of Medicine

Murat Seyit / Pamukkale University Faculty of Medicine

Introduction and Purpose: Acute polyneuropathies are a condition characterised by a sudden-onset, symmetrical, progressive weakness, which can occur in all age groups and is preceded by a history of events such as a respiratory tract infection, gastroenteritis or vaccination within the preceding 1–4 weeks. The most common type is Guillain-Barré syndrome. Although typically characterised by weakness that begins in the legs and progresses gradually, in some patients, involvement may be limited to the facial muscles and the bulbar region.Here, we report a case presenting with bulbar involvement—manifesting as difficulty swallowing, nasal speech and difficulty closing the eyes—without any complaints of weakness.

Materials and Methods: A 20-year-old female patient presented with complaints of impaired speech, difficulty swallowing and an inability to close her eyes, which had begun four days previously. The patient's vital signs were stable; on neurological examination, she exhibited nasal speech and weakness in the eye muscles. The patient, in whom the gag reflex could not be elicited, had no muscle weakness and the DTRs were normal. The patient's brain MRI was normal, and no findings suggestive of polyneuropathy were detected on EMG. The patient was admitted with a diagnosis of acute polyneuropathy with bulbar involvement, and further diagnostic investigations were carried out; IVIG treatment was initiated.

Materials and Methods: Although acute polyneuropathies frequently present with weakness in walking, in 5% of cases they may present solely with bulbar involvement. In patients with newly-onset speech impairment and dysphagia, acute polyneuropathies with bulbar involvement must always be considered.

Keywords: Acute polyneuropathies

Ref No: 7300

End-of-life decision-making in emergency medicine: Recognizing non-beneficial treatment and communicating goals of care

Mustafa Altay[1]

[1]Giresun education and research hospital

Mustafa Altay / Giresun education and research hospital

Introduction and Purpose: Emergency departments frequently serve as the first point of contact for patients with advanced or irreversible disease. Emergency physicians must often make rapid decisions regarding life-sustaining treatment in the absence of prior medical information or documented patient preferences. In these situations, the risk of providing non-beneficial interventions is significant. The purpose of this work is to explore the challenges of recognizing medical futility and conducting effective goals-of-care discussions in emergency and critical care settings.

Materials and Methods: This work presents a clinical perspective based on commonly encountered emergency department scenarios and current international recommendations regarding end-of-life care. Representative cases such as advanced chronic illness, irreversible deterioration, and refractory resuscitation were analyzed to identify key decision points where treatment escalation may no longer provide meaningful patient benefit. Communication approaches used during time-limited discussions with patients and families were also examined.

Results and Conclusion: Emergency physicians frequently encounter situations in which aggressive interventions may prolong physiologic survival without improving meaningful outcomes. Recognizing non-beneficial treatment and aligning care with patient values are essential components of ethical emergency care. Structured communication strategies and increased awareness of clinician moral distress may improve both patient-centered care and physician well-being. End-of-life decision-making should therefore be considered a core competency in emergency medicine practice.

Keywords: Emergency medicine; End-of-life care; Medical futility;

Ref No: 7329

Massive Pulmonary Embolism Presenting as Refractory Supraventricular Tachycardia in a Young Male; a case report

Meryem Keçelioğlu[1], Murat Seyit[1], Mert Özen[1], Alten Oskay[1], Atakan Yılmaz[1], İbrahim Türkçüer[1]

[1]Pamukkale University Faculty of Medicine

Murat Seyit / Pamukkale University Faculty of Medicine

Introduction and Purpose: Pulmonary embolism (PE) is a potentially fatal condition with a wide spectrum of clinical presentations. In young patients, atypical findings such as supraventricular tachycardia and syncope may delay diagnosis. Early bedside assessment and prompt imaging are critical for timely management.

Materials and Methods: A 26-year-old male presented after a syncopal episode at home. He was initially evaluated in another emergency department, where electrocardiography revealed supraventricular tachycardia (SVT). Due to failure to achieve rate control, the patient was referred to our center.The patient reported progressive exertional dyspnea over the preceding week. There was a family history of cardiac disease. On admission, vital signs were as follows: blood pressure 163/83 mmHg, heart rate 142 beats/min, respiratory rate 24/min, oxygen saturation 90% on room air, and body temperature 36.3°C.Physical examination revealed bilaterally decreased breath sounds. Given persistent tachycardia and hypoxemia, bedside point-of-care ultrasound was performed, demonstrating interventricular septal flattening (D-sign) and right-sided cardiac chamber dilation, suggestive of acute right ventricular strain.Based on these findings, the patient underwent urgent computed tomography pulmonary angiography, which revealed bilateral emboli involving the main pulmonary arteries. Pulmonology was consulted, and intravenous thrombolytic therapy was initiated. The patient was subsequently admitted to the pulmonary intensive care unit with the diagnosis of massive pulmonary embolism.

CT Scan

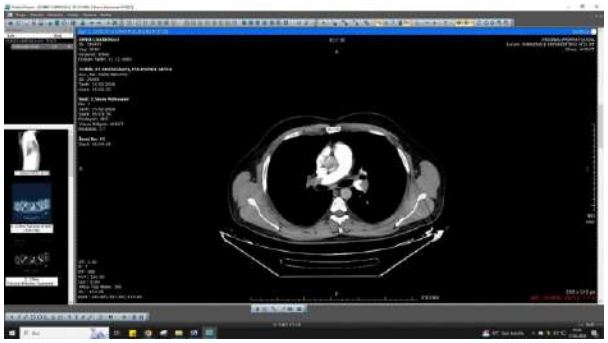

Materials and Methods: This case emphasizes that pulmonary embolism should be considered in young patients presenting with syncope, refractory tachyarrhythmia, and unexplained dyspnea. Bedside ultrasound can provide rapid and crucial diagnostic clues, facilitating early imaging and life-saving treatment. Reliance solely on electrocardiographic findings may delay diagnosis in atypical presentations.

Keywords: Pulmonary embolism, Supraventricular tachycardia, Point-of-care ultrasound

---

Ref No: 7341

A Case of Perianal Necrotizing Fasciitis Extending to the Pelvic Cavity in an Elderly Patient

alparslan altun[1], ali gür[1]

[1]Atatürk University Hospital Department of Emergency Medicine

alparslan altun / Atatürk University Hospital Department of Emergency Medicine

Introduction and Purpose: Necrotizing fasciitis is a life-threatening infection characterized by rapidly progressive necrosis of the soft tissues and fascia, which can follow a fulminant course if not treated appropriately. Although multiple microorganisms may be responsible (Group A Streptococcus, Clostridium perfringens, Bacteroides fragilis), the most common causative agent is Group A Streptococcus. The most frequently involved sites are the perineal and inguinal regions.

Materials and Methods: A 79-year-old male patient presented with complaints of anal pain and constipation persisting for one week. His medical history was significant for hypertension and diabetes mellitus. Vital signs were as follows: blood pressure 155/80 mmHg, oxygen saturation

94%, heart rate 76 beats/min, and body temperature 37.2°C. Rectal digital examination revealed tenderness and induration in the anal region. Laboratory investigations demonstrated leukocytosis with neutrophil predominance and elevated C-reactive protein levels. A mild increase in serum creatinine levels was also observed. On imaging studies, contrast-enhanced computed tomography revealed increased density and the presence of air densities in the perianal region. A loculated collection measuring approximately 8 cm, containing air densities, was identified extending along the left endopelvic fascia into the abdominal cavity, reaching the left anterolateral aspect of the bladder. The patient was consulted to the general surgery department for further evaluation and management.

Materials and Methods: Early diagnosis is the most critical factor in the management of necrotizing fasciitis. Diagnosis is primarily based on clinical findings, and the most crucial aspect is the clinician's suspicion of the disease. As demonstrated in this case, early recognition and appropriate management of necrotizing fasciitis, particularly in elderly and comorbid patients, are of vital importance and can be life-saving.

Keywords: Necrotizing fasciitis, Elderly Patient

Ref No: 7355

MYOCARDİAL İNFARCTİON AFTER AN ANAPHYLACTİC REACTİON

İzel HÜZMELİ ÖNCÜ[1], Saygın ÇANGA[1], Firas Arda Dönmez[1], Yusuf Ziya Taştekin[1], Mustafa POLAT[1], Ali KARAKUŞ[1]

[1]Hatay Mustafa Kemal University, Faculty of Medicine, Department of Emergency Medicine, Hatay, Türkiye

Yusuf Ziya Taştekin / Hatay Mustafa Kemal University, Faculty of Medicine, Department of Emergency Medicine, Hatay, Türkiye

Introduction and Purpose: The occurrence of acute coronary syndrome in the setting of conditions associated with mast cell activation is referred to as Kounis syndrome. Because Kounis syndrome is very rare, recognizing and diagnosing it is important.

Materials and Methods: A 67-year-old woman presented with vomiting (one episode), pruritus, flushing, and chills that had started 30 minutes prior to arrival. She had no known chronic disease or history of allergy. She was in good general condition and fully conscious. Physical examination revealed diffuse petechial erythema over the body. There was tenderness in the

epigastric region. On respiratory examination, bilateral basal crackles were heard. Her blood pressure was 170/90 mmHg, oxygen saturation was 94% on room air, and pulse rate was 86 beats/min. Cardiac examination showed a regular rhythm without additional sounds or murmurs.The patient received 0.5 mg intramuscular adrenaline, 80 mg intravenous methylprednisolone, and intravenous antihistamine therapy. The initial ECG showed sinus rhythm with a heart rate of 85 beats/min and no pathological findings. Laboratory tests including complete blood count, biochemistry, and troponin were obtained in the emergency department. Initial troponin was 0.06 ng/mL (0–0.045), creatinine 1.27 mg/dL (0.5–1.1), BUN 20 mg/dL, and leukocyte count 16,600/µL. Repeat troponin at 2 hours remained 0.06 ng/mL with no ECG changes.At the 4th hour of follow-up, troponin increased to 19.89 ng/mL. Although she had no chest pain, minimal ST-segment depression and T-wave inversion developed in leads V1–V2–V3 on ECG. Given the clinical findings, cardiology was consulted for acute coronary syndrome. Transthoracic echocardiography demonstrated left ventricular segmental wall motion abnormality with severe hypokinesia of the inferior and posterior walls, an ejection fraction of 40%, eccentric mild (grade 1) mitral regurgitation, and an ascending aortic aneurysm (4.0 cm).Coronary angiography revealed significant multivessel coronary artery disease: left coronary angiography showed 70% stenosis in the LMCA,90% distal stenosis,90% stenosis in the LAD,95% stenosis at the level of D2,80% proximal stenosis in D2,and 90% proximal stenosis in the circumflex artery.Coronary artery bypass grafting (CABG) was planned.

Materials and Methods: Kounis syndrome, also known as allergic angina,is an acute coronary syndrome caused by coronary vasospasm secondary to a hypersensitivity reaction.Because it is rare, it is often underdiagnosed.

Keywords: Kounis syndrome, Allergic acute coronary syndrome, Anaphylaxis

---

Ref No: 7371

Baker's Cysts Ruptured

Fazilet Gücüko[1], Murat Seyit[1], Atakan Yılmaz[1], Mert Özen[1], Alten Oskay[1], İbrahim Türkçüer[1]

[1]Pamukkale University Faculty of Medicine

Murat Seyit / Pamukkale University Faculty of Medicine

Introduction and Purpose: Baker's cysts are often detected incidentally during imaging of the knee performed for other reasons. When rupture occurs, the clinical presentation may be acute,

and in such cases the primary differential diagnosis is deep vein thrombosis (DVT). A chronic or subacute presentation may manifest as a popliteal fossa mass, calf swelling, or pain.

Materials and Methods: A 46-year-old male patient presented with right calf pain and swelling for one week. He had a known history of diabetes mellitus. There was no recent history of surgery, immobilization, prolonged travel, or hospitalization. He had no personal or family history of deep vein thrombosis. On physical examination, the circumference of the right calf was increased compared to the left. There was no temperature difference between the extremities. Peripheral pulses were palpable and equal in all four extremities. Homans' sign was negative. Vital signs were stable, and the ECG showed normal sinus rhythm.Deep vein thrombosis was initially considered. Bedside ultrasonography performed by our team revealed no evidence of DVT. However, ultrasonography performed by the radiology department demonstrated a ruptured Baker's cyst. The patient was consulted with the Orthopedics Department. The Orthopedics team recommended extremity elevation, cold application, bed rest, and outpatient follow-up.

Materials and Methods: The prompt and effective use of ultrasound plays a crucial role in diagnosing and treating Baker's cyst and its associated complications. Ruptured cysts can lead to complications such as compartment syndrome, necessitating immediate intervention. Patients with a ruptured Baker's cyst should be closely monitored and followed-up to detect and manage potential complications.

Keywords: Baker's cyst, Calf Pain, Ruptured Cysts.

Ref No: 7390

Acute Esophageal Food İmpaction And Secondary Hypertensive Response İn An Elderly Patient: A Case Report

Mehmet Akif Ersoy, Mehmet Kasa, Emrullah Atçı, Mine Kayacı Yıldız, Mehmet Gül

[1]Emergency Medicine Department, Konya City Hospital, Türkiye

Mehmet Akif Ersoy / Emergency Medicine Department, Konya City Hospital, Türkiye

Introduction and Purpose: Esophageal foreign bodies constitute a significant portion of gastrointestinal (GI) emergencies presenting to the emergency department (ED). Esophageal food bolus impaction is particularly common in the elderly population, frequently occurring secondary to underlying esophageal pathologies such as strictures, Schatzki rings, or motility disorders. The impaction of small-grain foods, such as rice, combined with continuous salivary secretion, can lead to complete esophageal obstruction and a high risk of aspiration. This report aims to present the clinical management of an elderly patient who presented with acute dysphagia and a secondary hypertensive crisis following rice impaction.

Materials and Methods: A 75-year-old female patient presented to the ED with the sudden onset of a foreign body sensation in the throat, acute dysphagia, and hypersalivation that developed during dinner. Physical examination revealed mild respiratory distress due to the persistent choking sensation. Her initial vital signs were notable for significant hypertension (blood pressure [BP]: 170/108 mmHg). This acute hypertensive episode was clinically evaluated as a secondary stress response triggered by the pain and anxiety of the esophageal obstruction. To rule out esophageal perforation, erect chest and abdominal radiographs were performed, showing no evidence of pneumomediastinum. Due to her inability to swallow oral secretions, an urgent gastroenterology consultation was requested, and a diagnostic and therapeutic upper GI endoscopy was planned.

Materials and Methods: Results and Conclusion:During the endoscopy, an impacted food bolus consisting of a compacted mass of rice was identified and successfully removed from the mid-to-lower esophageal sphincter region. Following successful disimpaction, the patient's symptoms and hypertensive crisis completely resolved. In conclusion, in elderly patients presenting with acute dysphagia due to food impaction, urgent endoscopic intervention must not be delayed in order to eliminate the high risk of aspiration pneumonia. Furthermore, the distress of acute obstruction can trigger severe secondary physiological responses, such as hypertensive crises, which typically resolve once the primary cause is relieved. The esophageal mucosa must be carefully evaluated post-procedure to identify underlying pathologies to prevent recurrences.

Keywords: Esophageal food impaction, dysphagia, hypertensive crisis

Ref No: 7411

Eruzum Atatürk Üniversitesi Tıp Fakültesi Acil Tıp Anabilim Dalı

Erdal Tekin[1], Hakan Alp[1]

[1]Analysis of Patients Presenting with Dizziness to the Emergency Department

Erdal Tekin / Analysis of Patients Presenting with Dizziness to the Emergency Department

Introduction and Purpose: Objective: Dizziness is characterized by sensations such as lightheadedness, difficulty maintaining balance, swaying, a feeling of self or environmental rotation, and faintness. In this study, patients presenting to the emergency department with complaints of dizziness were categorized into peripheral and central vertigo groups. The study aimed to compare the sociodemographic characteristics, presenting complaints, physical examination findings, imaging results, and vestibular assessment tests between these groups.

Materials and Methods: Methods: A total of 65 patients (n=45 peripheral, n=20 central) who presented to the emergency department with dizziness were included in the study. Patients' age, gender, and vital signs were recorded alongside nystagmus characteristics, HINTS (Head Impulse, Nystagmus, Test of Skew) findings, Dix-Hallpike test results, and the presence of neurological deficits. Computed tomography (CT) and magnetic resonance imaging (MRI) findings were compared for diagnostic accuracy. Statistical analysis of the obtained data was performed across the groups.Results: The mean age of the participants was 47.42 ± 9.8 years, with a higher age observed in the central group ($p=0.068$). No statistically significant difference was found between the groups regarding vital signs such as blood pressure, pulse, and oxygen saturation ($p > 0.05$). Clinical evaluation revealed that nausea was significantly more prevalent in the peripheral group ($p=0.035$). While the presence of vertical nystagmus (60%) and neurological deficits (70%) had high specificity for the diagnosis of central vertigo ($p < 0.001$), the Head Impulse Test was one of the strongest indicators for differentiating the central group from the peripheral group ($p < 0.001$). The Dix-Hallpike test was found positive in 71.1% of the peripheral group.

Materials and Methods: Conclusion: It was concluded that HINTS examination findings, nystagmus characterization, and neurological examination findings are the parameters with the highest diagnostic accuracy in the management of patients with dizziness in the emergency department. Particularly in the presence of a normal head impulse test and accompanying neurological deficits, diffusion-weighted MRI must be planned even if the initial CT scan is normal.

Keywords: vertigo, ischemic stroke, HINTS test

Ref No: 7428

Brainstem Hemorrhage Presenting With Acute Hemiparesis in a Previously Healthy 42-Year-Old Male; a case report

Meryem Keçelioğlu[1], Murat Seyit[1], Duygu Aras Seyit[2], Atakan Yılmaz[1], Mert Özen[1], Alten Oskay[1]

[1]Pamukkale University Faculty of Medicine
[2]ERPA Saglik Hospital, Denizli

Murat Seyit / Pamukkale University Faculty of Medicine

Introduction and Purpose: Brainstem hemorrhage is an uncommon but potentially life-threatening cause of acute focal neurological deficit. Although spontaneous intracerebral hemorrhage is more frequent in elderly hypertensive patients, it may also occur in younger individuals without known comorbidities. Early recognition and prompt neuroimaging are essential for appropriate management.

Materials and Methods: A 42-year-old male with no known medical history presented to the emergency department with sudden onset left-sided weakness and facial asymmetry that began at approximately 5:00 AM. The day prior to admission, he reported experiencing a stressful event.On arrival, the patient was somnolent with a Glasgow Coma Scale score of E3M6V2. Capillary blood glucose was 92 mg/dL. Vital signs were stable: blood pressure 135/78 mmHg, heart rate 60 beats/min, respiratory rate 21/min, temperature 36.4°C, and oxygen saturation 98% on room air.Neurological examination revealed left-sided hemiparesis with muscle strength graded 2/5, left nasolabial fold flattening, and a positive Babinski sign on the left.Urgent neuroimaging demonstrated a hemorrhagic lesion involving the mesencephalon and brainstem. A mass-like appearance was noted in the same region, raising suspicion for an underlying structural lesion. Neurosurgery was consulted immediately. Follow-up imaging showed no progression of the hemorrhage. The patient was admitted to the neurosurgery service for close monitoring and further evaluation.

Materials and Methods: This case highlights that brainstem hemorrhage can occur in young patients without known risk factors and may mimic acute ischemic stroke at presentation. Prompt neurological assessment and early imaging are crucial in differentiating hemorrhagic from ischemic etiologies. Additionally, the presence of a mass-like appearance should raise suspicion for an underlying structural pathology and warrants comprehensive evaluation.

Keywords: Brainstem hemorrhage; Acute hemiparesis; Intracerebral hemorrhage

Ref No: 7452

Pathological fracture associated with a distal tibial bone cyst in an adolescent

Hakan Ateş[1], Mine Kayacı Yıldız[1], Enes Eler, Berke Yıldırım[1], Mehmet Gül[1]
[1]Emergency Medicine Department, Konya City Hospital, Türkiye

Hakan Ateş / Emergency Medicine Department, Konya City Hospital, Türkiye

Introduction and Purpose: Unicameral bone cysts (UBC) are fluid-filled, usually unilocular, benign intramedullary bone lesions. They are most commonly observed in the proximal humerus and femur, while tibial localization is reported less frequently in the literature. These lesions are generally asymptomatic and are often diagnosed following a pathological fracture after minor trauma. In this report, we aimed to present a case of a pathological fracture associated with a distal tibial bone cyst in an adolescent patient who presented to the emergency department (ED) after a low-energy trauma, and to discuss the diagnostic process.

Materials and Methods: A 17-year-old male patient presented to the ED with pain and an inability to bear weight on the right ankle following a low-energy inversion injury caused by an ankle sprain. Physical examination revealed localized tenderness over the distal tibia and minimal soft tissue swelling. Neurovascular examination was normal. Direct radiographs demonstrated a well-defined, expansile lytic lesion in the distal tibial metaphysis with cortical thinning and a pathological fracture line extending through the lesion. The findings were considered compatible with a benign bone cyst. The “fallen fragment sign,” which is typically described for UBCs, was not observed on imaging.

Materials and Methods: Results and Conclusion:The patient was consulted with the orthopedics department. The affected extremity was immobilized with a short leg splint, and strict non-weight-bearing was recommended. Magnetic resonance imaging (MRI) was planned for further evaluation of the lesion, and the patient was referred for outpatient follow-up. In adolescent patients, the presence of fractures following low-energy trauma should prompt an immediate investigation for underlying pathological bone lesions. Even in cases that appear to be simple ankle sprains, the possibility of a pathological fracture should not be overlooked. Early recognition of these lesions by emergency physicians is crucial for appropriate referral and management.

Keywords: Bone cyst, pathological fracture, sports injury

Ref No: 7472

The Effectiveness of Hemodiafiltration in Crush Syndrome and Pneumosepsis Following Physical Assault: A Case Report

Hakkı Yüce[1], Ramazan Köylü[1], Hasan Yıldız[1], Mustafa Gülpembe[1], Mehmet Gül[1]

[1]Emergency Medicine Department, Konya City Hospital, Türkiye

Hasan Yıldız / Emergency Medicine Department, Konya City Hospital, Türkiye

Introduction and Purpose: : Crush syndrome is a life-threatening condition characterized by acute kidney injury (AKI) due to massive rhabdomyolysis and myoglobinuria, with high mortality rates. In cases complicated by sepsis and fluid overload, conventional dialysis methods may be insufficient. In this report, we aim to present the critical role of continuous venovenous hemodiafiltration (CVVHDF) in volume management and metabolic stabilization in a severe crush syndrome case following physical assault and prolonged dehydration.

Materials and Methods: A 33-year-old male patient was brought to our emergency department after being assaulted and left without food and water for two days. Physical examination revealed confusion, fever (38.7°C), and widespread body trauma. Laboratory findings showed creatinine 3.28 milligrams per deciliter (mg/dL), creatine kinase (CK) 56,810 units per liter (U/L), and myoglobin 2800 nanograms per milliliter (ng/mL). The patient was admitted to the intensive care unit with diagnoses of right lower lobe pneumonia and stage 3 AKI. Despite aggressive fluid resuscitation, anuria and severe pulmonary edema (fluid overload) developed.

Materials and Methods: Results and Conclusion: CVVHDF was initiated instead of conventional dialysis, achieving effective volume control via ultrafiltration and successful uremic clearance. By the 5th day of treatment, renal functions normalized, and the patient was transferred to the ward. In cases of traumatic rhabdomyolysis complicated by sepsis, fluid management is challenging due to capillary leak syndrome. In such complex cases, hemodiafiltration provides superiority over standard dialysis methods by enabling the removal of high molecular weight myoglobin and precise volume control.

Keywords: Crush syndrome, acute kidney injury, hemodiafiltration

Ref No: 7593

Methanol Intoxication

Sabri Furkan Bulca[1], Murat Seyit[1], Mert Özen[1], Alten Oskay[1], Atakan Yılmaz[1], İbrahim Türkçüer[1]

[1]Pamukkale University Faculty of Medicine

Murat Seyit / Pamukkale University Faculty of Medicine

Introduction and Purpose: Methanol intoxication is a medical emergency characterized by high anion gap metabolic acidosis and visual symptoms, and delayed diagnosis may result in permanent neurological damage and death. In the emergency department, the presence of increased anion gap metabolic acidosis is a key diagnostic clue.

Materials and Methods: A 42-year-old man presented approximately 12 hours after ingesting "homemade alcohol" with blurred vision, dizziness, and nausea. Vital signs were: blood pressure 110/65 mmHg, heart rate 102/min, respiratory rate 28/min (Kussmaul breathing), temperature 36.6°C, and SpO_2 97%. Arterial blood gas analysis revealed pH 7.06 and HCO_3 6 mmol/L. Laboratory evaluation showed a markedly elevated anion gap and an increased osmolar gap (difference between measured serum osmolality and calculated osmolarity). Concomitant ethanol level was low/negative. The clinical presentation and laboratory findings were considered consistent with methanol intoxication. First-line management includes 100% oxygen, correction of acidosis, administration of an antidote (fomepizole or ethanol), and planning hemodialysis when indicated.

Materials and Methods: This case demonstrates that toxic alcohol poisoning should be suspected early in the presence of severe acidosis accompanied by visual symptoms, and that rapid organization of antidote therapy and dialysis is critical. Even when the history is unclear, toxic alcohol intoxications—especially methanol—should be promptly ruled out in patients with high anion gap metabolic acidosis and an increased osmolar gap. Early antidote administration and hemodialysis in appropriate patients can accelerate metabolic recovery and reduce the risk of neurological sequelae and mortality.

Keywords: Methanol, anion gap, metabolic acidosis.

Ref No: 7596

Acute Non-Specific Abdominal Pain in the Emergency Department: A Case of Atypical Mesenteric Ischemia

MURTEZA ZAFER[1]

[1]ATATÜRK ÜNİVERSİTESİ EĞİTİM VE ARAŞTIRMA HASTANESİ

MURTEZA ZAFER / ATATÜRK ÜNİVERSİTESİ EĞİTİM VE ARAŞTIRMA HASTANESİ

Introduction and Purpose: IntroductionMesenteric ischemia is a rare but potentially fatal condition in the emergency setting. Early diagnosis is critical, yet it is often delayed due to non-specific clinical presentation. Here, we present a patient initially evaluated for benign abdominal pain, later diagnosed with mesenteric ischemia through imaging.

Materials and Methods: Case PresentationA 65-year-old male presented to the emergency department with sudden, diffuse abdominal pain. The pain was described as severe and disproportionate to physical examination findings.His medical history included hypertension and atrial fibrillation, with irregular use of anticoagulation therapy.On physical examination, the abdomen was soft with no guarding or rebound tenderness. Vital signs were within normal limits.Laboratory results showed:•White blood cell count: 15,000/mm³•Lactate: 3.2 mmol/L•CRP: mildly elevatedInitially considered as non-specific abdominal pain, a contrast-enhanced CT angiography was performed due to clinical suspicion, revealing thromboembolism of the superior mesenteric artery.The patient was immediately consulted by general surgery and taken to the operating room.Mesenteric ischemia can be challenging to diagnose early because physical exam findings may be minimal. One of the most important clinical clues is “pain out of proportion” to examination.Risk factors include:•Atrial fibrillation•Advanced age•Vascular diseaseEarly lactate levels may be normal and should not be solely relied upon to rule out the diagnosis. Contrast-enhanced CT angiography remains the most reliable diagnostic tool.

Materials and Methods: ConclusionEmergency clinicians should consider mesenteric ischemia in patients presenting with non-specific abdominal pain, especially when risk factors are present. Prompt diagnosis and intervention significantly reduce mortality.

Keywords: Acute Mesenteric Ischemia

Ref No: 7605

When history ıs missing: a warfarin-related catastrophic ıntracerebral hemorrhage and the critical role of e-nabız

Nevzat HERGÜL[1], Mehmet ÇABUK[1], Mehmet Reşit ÖNCÜ[1]

[1]Van Yüzüncü Yıl University Faculty of Medicine

Nevzat HERGÜL / Van Yüzüncü Yıl University Faculty of Medicine

Introduction and Purpose: Warfarin is widely used for the prevention of thromboembolic events, particularly in patients with mechanical heart valves; however, excessive anticoagulation significantly increases the risk of intracerebral hemorrhage (ICH), which is associated with high mortality. Although rapid diagnosis is essential in emergency settings, this process may be considerably complicated in the absence of patient history. In such situations, access to electronic health records becomes critically important. In this report, we aimed to present a case of warfarin-associated intracerebral hemorrhage diagnosed without anamnesis and to emphasize the essential role of e-Nabız in emergency clinical decision-making.

Materials and Methods: A 48-year-old male patient was found unconscious in his vehicle and brought to the emergency department. No relatives or accompanying individuals were present, and therefore anamnesis could not be obtained. In addition, the patient's electronic health records (e-Nabız) were inaccessible at the time of admission, further limiting access to prior medical history and medication use. On initial evaluation, the patient had a Glasgow Coma Scale score of 4–5, blood pressure of 190/90 mmHg, oxygen saturation of 85%, and anisocoria with a dilated right pupil unresponsive to light. Due to respiratory insufficiency and decreased level of consciousness, the patient was intubated and mechanically ventilated. Cranial computed tomography revealed a large intraparenchymal hemorrhage originating from the right basal ganglia, with intraventricular extension and significant midline shift (Figure 1).

Figure 1



Non-contrast brain computed tomography showing a large right basal ganglia intraparenchymal hemorrhage with intraventricular extension and significant midline shift.

Materials and Methods: Laboratory evaluation demonstrated severe coagulopathy, with an international normalized ratio (INR) of 8.0 and prolonged activated partial thromboplastin time. Other laboratory parameters are summarized in Table 1. In the absence of anamnesis, the diagnostic process relied entirely on objective findings, including imaging and laboratory results, with markedly elevated INR serving as the primary diagnostic clue. The patient received intravenous vitamin K and prothrombin complex concentrate for rapid reversal of anticoagulation, resulting in a significant decrease in INR levels. Following multidisciplinary evaluation, neurosurgical intervention was planned, and the patient was admitted for further management. The inaccessibility of e-Nabız in this case limited early recognition of anticoagulant use; immediate access to electronic health records could have enabled faster identification of the underlying condition and more rapid initiation of targeted treatment.

table 1

Parameter	Result	Reference Range
WBC	20.21 ×10⁹/L	4–10×10⁹/L
Hemoglobin	15.8 g/dL	13-17 g/dL
Platelet	407 ×10⁹/L	150–400×10⁹/L
CRP	6.5	0-5
Creatinine	0.83	0.6-1.2
Troponine I	0.01 ng/mL	<0.04
INR	8	0.8-1.2
aPTT	71 s	25-35 s

Keywords: Warfarin overdose, emergency diagnosis, e-Nabız

Ref No: 7669

PONTINE INFARCTION PRESENTING WITH ISOLATED PERIORAL NUMBNESS: A CASE REPORT

ALARA NERGİZ SOSLU[1], ZEYNEP ÇAKIR[1]

[1]ATATURK UNIVERSITY FACULTY OF MEDICINE, DEPARTMENT OF EMERGENCY MEDICINE

ALARA NERGİZ SOSLU / ATATURK UNIVERSITY FACULTY OF MEDICINE, DEPARTMENT OF EMERGENCY MEDICINE

Introduction and Purpose: Isolated sensory symptoms are clinical presentations that can often be attributed to benign causes in emergency department visits but can sometimes be the only sign of life-threatening cerebrovascular accidents (CVA). Especially in patients with high vascular risk factors, the mild nature of focal neurological findings can be misleading. Brainstem infarcts can cause specific sensory or motor deficits even in very small areas due to their anatomical location.

Materials and Methods: A 62-year-old female patient presented to our emergency department with a sudden onset of numbness on the left corner of her lip. The patient's medical history included hypertension, hyperlipidemia, coronary artery disease, and hypothyroidism; it was learned that she regularly used 100 mg of acetylsalicylic acid daily.In the detailed neurological examination, no additional motor or sensory deficits were found except for minimal hypoesthesia on the left corner of the lip. Cranial nerve examinations were normal, and cerebellar tests were skillful. Biochemical blood tests and cranial computed tomography (CT) performed at admission were evaluated as normal. Considering the patient's vascular risk factors and the sudden onset of the symptom, Diffusion-Weighted MRI (DWI) was performed, which revealed signal restriction consistent with acute infarction in the pons. The patient was consulted with the neurology department and admitted to the ward for further evaluation and treatment.

Materials and Methods: This case reminds us that minor symptoms such as "isolated numbness" can be a sign of acute ischemic stroke localized in the brainstem, especially in high-risk patient groups. It should be noted that brain CT is insufficient in showing brainstem ischemia in emergency department conditions, and diffusion MRI should not be avoided when there is clinical suspicion.

Keywords: perioral numbness, pontine enfarction, cerebrovascular accident

Ref No: 7697

Acute clonazepam intoxication managed without flumazenil in a patient with a history of seizures: Case report

Egemen Tavrak[1]

[1]Oltu State Hospital, Erzurum, Turkey

Egemen Tavrak / Oltu State Hospital, Erzurum, Turkey

Introduction and Purpose: Clonazepam is a long-acting benzodiazepine that enhances gamma-aminobutyric acid (GABA-A) receptor activity, leading to central nervous system depression and sedative effects. Benzodiazepine intoxications generally follow a benign course in cases of isolated ingestion; however, the decision to administer flumazenil remains controversial, particularly in patients with a history of seizures. This case report aims to present the conservative management of acute clonazepam ingestion without flumazenil in a patient with a seizure history.

Materials and Methods: A psychiatric follow-up patient with a history of cerebrovascular accident and post-stroke seizures was brought to the emergency department after ingesting 5 mL of clonazepam oral drops (2.5 mg/mL), corresponding to a total dose of 12.5 mg. The intention of ingestion (suicidal versus accidental) was unclear. On admission, vital signs were stable (blood pressure 120/80 mmHg, heart rate 60/min, respiratory rate 15/min, oxygen saturation 97%). The Glasgow Coma Scale score was 14, with somnolence present but without respiratory depression, and orientation was preserved. Laboratory tests and electrocardiography were within normal limits. No evidence of co-ingestion or trauma was identified. The National Poison Information Center recommended 40 hours of observation.

Materials and Methods: The patient remained hemodynamically stable throughout the observation period and did not develop respiratory depression. Due to the history of seizures and possible chronic benzodiazepine exposure, flumazenil was withheld because of the risk of precipitating seizures. The patient was transferred to a center with intensive care and psychiatric facilities. At the referral center, the patient was monitored for two days with supportive treatment only and was discharged without any acute complications.This case demonstrates that supportive management may be sufficient in stable benzodiazepine monointoxication and supports the selective use of flumazenil in patients with epileptogenic risk factors.

Keywords: Benzodiazepine intoxication, Clonazepam, flumazenil

Ref No: 7758

A Case Report : Cerebral Venous Sinus Thrombosis

Ümit Yaşar Can[1]
[1]Niğde Ömer Halisdemir Training And Research Hospital, Department Of Emergency Medicine,

Introduction and Purpose: Cerebral venous sinus thrombosis (CVST) is a rare but potentially life-threatening neurological emergency resulting from thrombosis of the cerebral venous sinuses. Although less common than arterial stroke, it predominantly affects young adults and women. Clinical presentation is often nonspecific, with headache being the most frequent symptom, which may lead to delayed diagnosis in the emergency department. Importantly, non-contrast computed tomography (CT), commonly used as the initial imaging modality, may be normal in a substantial proportion of cases.

Materials and Methods: Case Presentation A 32-year-old female presented to the emergency department with a 3-day history of progressively worsening diffuse headache accompanied by mild nausea. Over the preceding 24 hours, photophobia had developed. The patient described the pain as persistent and unresponsive to simple analgesics. She had no known chronic medical conditions; however, she reported active smoking and a 6-month history of oral contraceptive use.On admission, vital signs were stable (blood pressure: 130/85 mmHg, heart rate: 88 beats/min, temperature: 37.2°C, oxygen saturation: 98%). The patient appeared uncomfortable but was fully conscious and oriented. Neurological examination revealed a Glasgow Coma Scale score of 15, isocoric and reactive pupils, intact cranial nerve function, and no focal motor or sensory deficits. Mild neck stiffness was noted.Laboratory investigations, including complete blood count and biochemical parameters, were within normal limits, except for a mildly elevated C-reactive protein level (12 mg/L). Initial non-contrast brain CT showed no acute abnormalities. However, due to persistent symptoms and the presence of risk factors, contrast-enhanced CT was performed. This revealed filling defects in the superior sagittal sinus and left transverse sinus, consistent with CVST, demonstrating the characteristic “empty delta sign.”The patient was admitted to the neurology department, and anticoagulation therapy with low-molecular-weight heparin was initiated.

Materials and Methods: Conclusion : CVST should be considered in the differential diagnosis of patients presenting with persistent headache, particularly in young individuals with risk factors such as oral contraceptive use, even when initial non-contrast CT findings are unremarkable. This case highlights the limitations of non-contrast CT and underscores the critical role of clinical suspicion in guiding further diagnostic evaluation.

Keywords: Cerebral Venous Sinus Thrombosis, Headache, Oral Contraceptives

Ref No: 7770

Self-Harm by Neck Lacerations and Rodenticide Ingestion Leading to Bilateral Pneumothorax: A Case Report

Saffet Güler[1], Murat Seyit[1], Atakan Yılmaz[1], Mert Özen[1], Alten Oskay[1], İbrahim Türkçüer[1]

[1]Pamukkale University Faculty of Medicine

Murat Seyit / Pamukkale University Faculty of Medicine

Introduction and Purpose: Self-inflicted injuries combined with ingestion of toxic substances pose a complex challenge in emergency medicine. Neck lacerations may compromise airway and major vessels, while rodenticide ingestion can cause coagulopathy and systemic toxicity. Bilateral pneumothorax from neck trauma is extremely rare. This case report aims to highlight the multidisciplinary management and clinical vigilance required in patients presenting with combined self-harm injuries.

Materials and Methods: A 23-year-old male patient presented with self-inflicted cuts to his neck from a wine bottle and ingestion of rodent poison (Tibtrap, containing difenacoum, a vitamin K antagonist with 4-hydroxycoumarin). On examination, his Glasgow Coma Scale score was 15, and he was confused. Numerous cuts were found on the neck (~5 cm), the anterior chest (two superficial cuts, each 1 cm), and both elbows (2 cuts, 4-5 cm). Vital signs were stable, distal pulses were palpable, and there was no asymmetry or cold extremities. Contrast-enhanced thoracic computed tomography revealed bilateral pneumothorax. Bilateral chest tubes were inserted. Neck CT showed patency of the bilateral common, external, and internal carotid arteries. The cuts were sutured by an ENT specialist. Since no zinc phosphide was detected in the ingested rodent poison, respiratory isolation was not required. Due to exposure to Difenacoum, three days of intensive care monitoring was recommended..

Cuts on the neck



Cuts on the neck

Bilateral pneumothorax

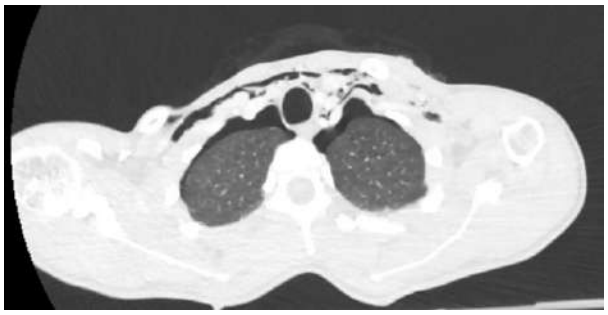

Bilateral pneumothorax

Materials and Methods: The patient was admitted to anesthesia-intensive care unit from the emergency department for close monitoring and supportive management. This case demonstrates that complex self-harm injuries with chemical ingestion require multidisciplinary coordination, careful airway and vascular assessment, thoracic management, and toxicology monitoring. Early intervention and intensive care follow-up are critical to prevent potentially fatal outcomes.

Keywords: Rodenticide ingestion, Bilateral pneumothorax, Multidisciplinary management

Ref No: 7813

Emergency Diagnosis of DeBakey Type I Aortic Dissection Using Bedside Echocardiography and Detailed Physical Examination: A Case Report

Mehmet Alkan[1], Ali Ezer[1], Taner Fuygunoğlu[1], Yusuf Ziya Taştekin[1], Hakan Ercan[1], Hagop Hovig Garibian[1], Mustafa Polat[1], Ali Karakuş[1]
[1]Hatay Mustafa Kemal University Tayfur Ata Sökmen Faculty of Medicine Department of Emergency Medicine

Yusuf Ziya Taştekin / Hatay Mustafa Kemal University Tayfur Ata Sökmen Faculty of Medicine Department of Emergency Medicine

Introduction and Purpose: Aortic dissection occurs when a tear in the intimal layer allows blood to enter the medial layer of the aortic wall, separating the intimal and adventitial layers. Although CT angiography is considered the gold standard for diagnosis, detailed physical examination and echocardiography (ECHO) can assist in the diagnosis, particularly in emergency settings and in hemodynamically unstable patients.

Materials and Methods: A 53-year-old male patient was brought to our emergency department by ambulance (112 emergency medical service) with complaints of chest pain, followed by a fall and trauma to his left leg, accompanied by pain. The patient had no known medical history.On admission, the patient's Glasgow Coma Scale (GCS) score was 15. Neurological examination was normal. The abdomen was soft and non-tender. Breath sounds were equal and normal bilaterally. However, the patient was agitated and in severe pain.On physical examination, the left femoral pulse was absent in the lower extremity. The patient appeared cyanotic and tachypneic. Shortly after arrival, the patient developed altered consciousness, and he was transferred to the resuscitation room and intubated.Due to the absence of the left femoral pulse, emergency bedside echocardiography was performed. Echocardiographic evaluation revealed a dissection flap at the level of the ascending aorta, aortic arch, and abdominal aorta.The patient was consulted with the Cardiovascular Surgery Department. Because the patient was hemodynamically unstable, CT angiography could not be performed. Based on bedside physical examination and emergency echocardiographic findings, the patient was diagnosed with DeBakey Type I aortic dissection.The patient was subsequently admitted to the Cardiovascular Surgery Department for further management.

Materials and Methods: The use of echocardiography in emergency settings, together with a detailed physical examination, facilitates the rapid diagnosis of life-threatening conditions and helps prevent unnecessary diagnostic requests and time loss. Clinical experience combined with the effective use of bedside ECHO can significantly reduce the time required for patients to access definitive treatment.

Keywords: DeBakey Type I Aortic Dissection, Echocardiography, Physical Examination

Ref No: 7834

Non-Traumatic Femoral Neck Stress Fracture: A Case Report

Seyyid Rasim Yanmaz[1], Hilal Yağar[1]

[1]Niğde Ömer Halisdemir Eğitim ve Araştırma Hastanesi

Seyyid Rasim Yanmaz / Niğde Ömer Halisdemir Eğitim ve Araştırma Hastanesi

Introduction and Purpose: Femoral neck stress fractures (FNSFs) are uncommon injuries, accounting for approximately 1% to 7.2% of all stress fractures in otherwise healthy individuals, with femoral neck involvement reported in nearly 11% of cases. They are increasingly recognized as-an important cause of hip pain in physically active individuals and are more frequently observed in runners, endurance athletes, military personnel, and patients with metabolic abnormalities. These fractures are typically classified as fatigue fractures caused by repetitive abnormal loading on normal bone. Clinically, patients usually present with insidious onset groin or hip pain that worsens with activity and weight-bearing and improves with rest. Based on anatomical location and biomechanical characteristics, FNSFs are categorized into compression-sided and tension-sided lesions.

Materials and Methods: A 35-year-old male physician working in the emergency department presented with a two-week history of left hip pain and limping. He reported prolonged standing hours and frequent overnight shifts due to occupational demands. There was no history of trauma, smoking, corticosteroid use, or known metabolic disease. His medical history was notable for prior bone marrow edema syndrome of the contralateral hip. Initial plain radiographs and laboratory investigations revealed no acute pathology. Magnetic resonance imaging demonstrated an incomplete tension-sided stress fracture extending to the superolateral aspect of the left femoral neck, accompanied by surrounding bone marrow edema. The patient was hospitalized and underwent prophylactic percutaneous fixation under fluoroscopic guidance using two parallel cannulated screws. No postoperative neurovascular complications occurred. Early postoperative follow-up showed marked pain relief. The patient was mobilized without weight-bearing for six weeks. Subsequent clinical and radiographic evaluations demonstrated maintained screw position without fracture progression or displacement.

CX preop



MRI fracture

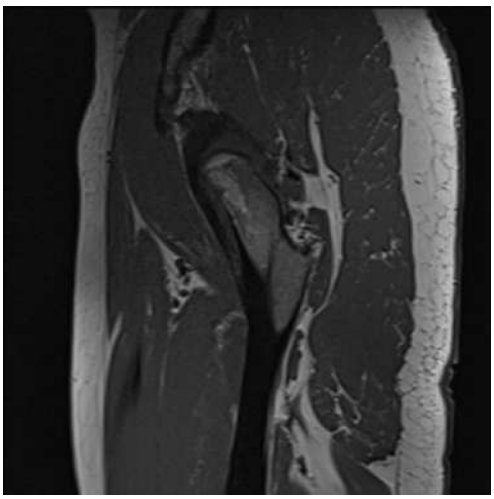

MRI edema

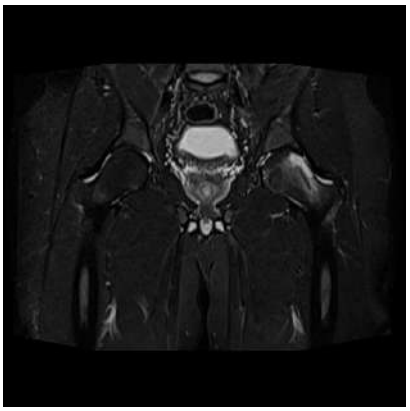

CX PostOp



Materials and Methods: This case highlights the diagnostic challenge of FNSFs, particularly in-young adults without overt trauma and with initially normal radiographs. Repetitive occupational mechanical loading was considered the likely etiological factor in this patient. MRI played a decisive role in establishing the diagnosis. Given the biomechanical instability and high displacement risk associated with incomplete tension-sided femoral neck stress fractures, prophylactic surgical fixation was considered the most appropriate treatment strategy. Early recognition and timely intervention are essential to prevent catastrophic complications such as displacement and avascular necrosis of the femoral head.

Keywords: Femoral neck stress fracture, Stress fracture, Internal fixation

Ref No: 7859

Analysis of Patients Presenting with Dizziness to the Emergency Department

Erdal Tekin[1], Hakan Alp[1]

[1]Erzurum Atatürk Üniversitesi Tıp Fakültesi Acil Tıp Anabilim Dalı

Erdal Tekin / Erzurum Atatürk Üniversitesi Tıp Fakültesi Acil Tıp Anabilim Dalı

Introduction and Purpose: Objective: Dizziness is characterized by sensations such as lightheadedness, difficulty maintaining balance, swaying, a feeling of self or environmental rotation, and faintness. In this study, patients presenting to the emergency department with complaints of dizziness were categorized into peripheral and central vertigo groups. The study aimed to compare the sociodemographic characteristics, presenting complaints, physical examination findings, imaging results, and vestibular assessment tests between these groups.

Materials and Methods: Methods: A total of 65 patients (n=45 peripheral, n=20 central) who presented to the emergency department with dizziness were included in the study. Patients' age, gender, and vital signs were recorded alongside nystagmus characteristics, HINTS (Head Impulse, Nystagmus, Test of Skew) findings, Dix-Hallpike test results, and the presence of neurological deficits. Computed tomography (CT) and magnetic resonance imaging (MRI) findings were compared for diagnostic accuracy. Statistical analysis of the obtained data was performed across the groups.Results: The mean age of the participants was 47.42 ± 9.8 years, with a higher age observed in the central group ($p=0.068$). No statistically significant difference was found between the groups regarding vital signs such as blood pressure, pulse, and oxygen saturation ($p > 0.05$). Clinical evaluation revealed that nausea was significantly more prevalent in the peripheral group ($p=0.035$). While the presence of vertical nystagmus (60%) and neurological deficits (70%) had high specificity for the diagnosis of central vertigo ($p < 0.001$), the Head Impulse Test was one of the strongest indicators for differentiating the central group from the peripheral group ($p < 0.001$). The Dix-Hallpike test was found positive in 71.1% of the peripheral group.

Materials and Methods: Conclusion: It was concluded that HINTS examination findings, nystagmus characterization, and neurological examination findings are the parameters with the highest diagnostic accuracy in the management of patients with dizziness in the emergency department. Particularly in the presence of a normal head impulse test and accompanying neurological deficits, diffusion-weighted MRI must be planned even if the initial CT scan is normal.

Keywords: vertigo, ischemic stroke, HINTS test

Ref No: 7863

Testicular Torsion

Hatice Simge Acun[1], Murat Seyit[1], Atakan Yılmaz[1], Mert Özen[1], Alten Oskay[1], İbrahim Türkçüer[1]

[1]Pamukkale University Faculty of Medicine

Murat Seyit / Pamukkale University Faculty of Medicine

Introduction and Purpose: Testicular torsion is a urological emergency caused by the twisting of the spermatic cord, leading to compromised blood flow to the testis. It most commonly occurs in adolescents and young adults and typically presents with sudden-onset scrotal pain. Delay in diagnosis and management may result in irreversible ischemic damage and testicular loss. Early recognition and prompt surgical intervention are crucial to preserve testicular viability. This case report aims to present a 25-year-old male patient who developed acute testicular torsion during physical activity, emphasizing the importance of rapid clinical assessment and timely surgical management.

Materials and Methods: A 25-year-old male with no significant past medical history presented to the emergency department with sudden-onset severe right scrotal pain that developed while playing football. The pain began abruptly during a recreational match and was associated with nausea but no vomiting or fever. He denied any history of trauma, urinary symptoms, or previous similar episodes. On admission, vital signs were blood pressure 120/75 mmHg, heart rate 102 beats/min, oxygen saturation 98% on room air, and body temperature 36.8°C. Physical examination revealed a high-riding, tender right testis with scrotal swelling and an absent cremasteric reflex on the affected side. Laboratory findings were unremarkable. Scrotal Doppler ultrasonography demonstrated absent blood flow to the right testis, consistent with testicular torsion. Following urgent urology consultation, the patient was taken to the operating room for emergency surgical exploration. Intraoperative findings confirmed torsion of the right spermatic cord. Detorsion was performed, and testicular viability was assessed. After restoration of blood flow, bilateral orchiopexy was completed to prevent recurrence. The patient showed clinical improvement postoperatively and was discharged in stable condition.

Scrotal Doppler ultrasonography 1

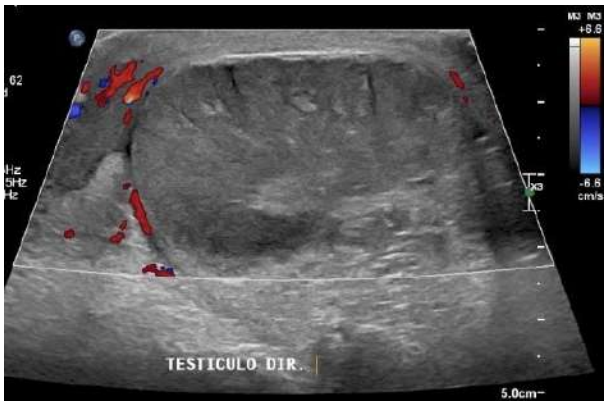

Scrotal Doppler ultrasonography 2

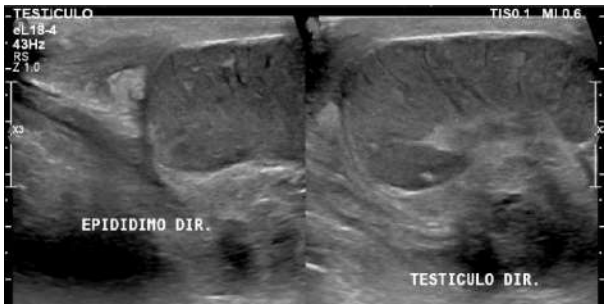

Scrotal Doppler ultrasonography 3

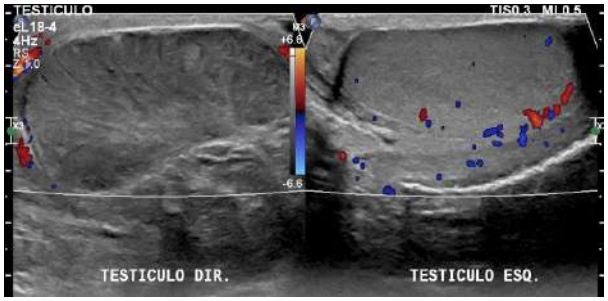

Materials and Methods: This case highlights that testicular torsion should be promptly considered in young males presenting with acute scrotal pain, particularly following physical activity, and that immediate surgical intervention is essential to preserve testicular function and prevent irreversible complications.

Keywords: Testicular torsion, Acute scrotum, Orchiopexy

Ref No: 7889

Case Report: Generalized Subcutaneous Emphysema and Pneumomediastinum in a Young Adult

Murat Seyit[1], Mert Özen[1], Alten Oskay[1], Atakan Yılmaz[1], İbrahim Türkçüer[1]

[1]Pamukkale University Faculty of Medicine

Murat Seyit / Pamukkale University Faculty of Medicine

Introduction and Purpose: neumomediastinum is a critical clinical condition typically associated with trauma. Its spontaneous occurrence, independent of traumatic injury, is relatively rare. We aimed to present this case alongside radiological findings to emphasize the diagnostic approach to spontaneous occurrences.

Materials and Methods: A 23-year-old female patient presented to the emergency department with sudden-onset severe chest pain, dyspnea, and swelling in the neck region. While there was no history of trauma, the patient reported a severe coughing fit immediately preceding the onset of symptoms. She had no prior diagnosis of asthma or chronic lung disease.Clinical Findings: The patient's vital signs were stable (BP: 110/70 mmHg, HR: 92 bpm, SpO2: 94%). Physical examination revealed significant subcutaneous crepitus (resembling the sound of walking on snow) upon palpation of the neck, anterior chest wall, and bilateral axillary regions. On auscultation, heart sounds appeared distant, and a crunching sound synchronized with the heartbeat (Hamman's sign) was detected.Radiological Evaluation: Non-contrast Thoracic Computed Tomography (CT) demonstrated extensive subcutaneous emphysema extending from the cervical region to the upper abdominal segments, dissecting through the pectoral muscles and intercostal spaces. Free air was identified in the mediastinal space surrounding the trachea and major vascular structures (pneumomediastinum). No significant pneumothorax, esophageal perforation, or parenchymal pathology was observed.Discussion and Management: The patient was admitted with a diagnosis of subcutaneous emphysema secondary to primary spontaneous pneumomediastinum (SPM). This phenomenon is generally explained by the Macklin Effect, where alveolar rupture allows air to leak along the peribronchovascular sheaths into the mediastinum and subsequently into soft tissues. Management included bed rest, high-flow oxygen therapy (to accelerate air resorption), and analgesia. Following clinical regression of the emphysema without further complications, the patient was discharged with outpatient follow-up recommendations.

CT Scan


SENA HALAT
ID: 1084293
Yaş: 023Y
Cinsiyet: Kadın
Doğum Tarihi: 30.09.2002
Tetkik: BT, BOYUN, KONTRASTSIZ BT, BOYUN, KONTRASTSIZ
Acc. No: HGM19829002
ID: 21829
Tarih: 30.12.2025
Saat: 21:20:39
Seri: 2.5mm STND
No: 2
Tarih: 30.12.2025
Saat: 21:21:18
Pozisyon: HFS
Vücut Bölgesi: NECK
Modalite: CT
İmaj No: 1
Saat: 21:21:29
ORIGINAL\PRIMARY\AXIAL
Kurum: PAMUKKALE UNIVERSITESI ACIL BT
Cihaz: ACILCT
ST: 2.50
E: 18
ET: 800
KVP: 120.00
GDT: 0.00
XRay Tüp Akımı: 355
SL: -266.75
POS:-100.00\-73.80\-266.75
512 x 512 px

.

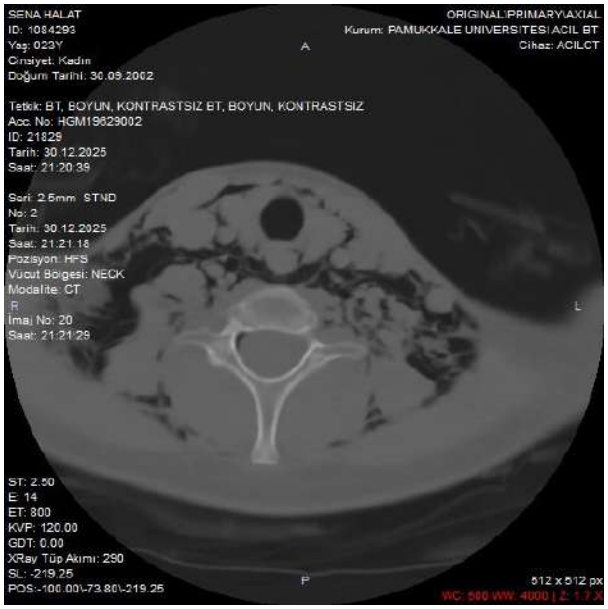
SENA HALAT
ID: 1084293
Yaş: 023Y
Cinsiyet: Kadın
Doğum Tarihi: 30.09.2002
Tetkik: BT, BOYUN, KONTRASTSIZ BT, BOYUN, KONTRASTSIZ
Acc. No: HGM19829002
ID: 21829
Tarih: 30.12.2025
Saat: 21:20:39
Seri: 2.5mm STND
No: 2
Tarih: 30.12.2025
Saat: 21:21:18
Pozisyon: HFS
Vücut Bölgesi: NECK
Modalite: CT
İmaj No: 20
Saat: 21:21:29
ORIGINAL\PRIMARY\AXIAL
Kurum: PAMUKKALE UNIVERSITESI ACIL BT
Cihaz: ACILCT
ST: 2.50
E: 14
ET: 800
KVP: 120.00
GDT: 0.00
XRay Tüp Akımı: 290
SL: -219.25
POS:-100.00\-73.80\-219.25
512 x 512 px

.

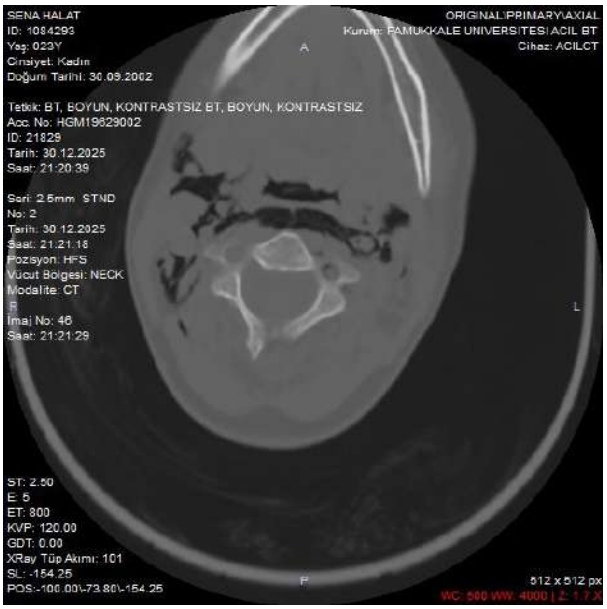

.



Materials and Methods: This case serves as a reminder that subcutaneous emphysema and pneumomediastinum should be considered in the differential diagnosis of non-traumatic chest pain, even in young and otherwise healthy patients.

Keywords: Macklin Effect, Hamman's sign, Primary spontaneous pneumomediastinum

Ref No: 7982

Cavitary lesion

Yusuf Burak Eker[1], Zeynep Çakır[1], Enes Yılmaz[1]

[1]Atatürk Üniversitesi Tıp Fakültesi Acil Tıp Anabilim Dalı

Yusuf Burak Eker / Atatürk Üniversitesi Tıp Fakültesi Acil Tıp Anabilim Dalı

Introduction and Purpose: Respiratory tract infections can vary from simple colds to severe pneumonia and constitute a majority of emergency department visits in Turkey. Patients with pneumonia typically present with symptoms such as productive cough lasting 1-2 days, shortness of breath, fever, fatigue, and decreased oral intake.

Materials and Methods: A 32-year-old male patient presented with a complaint of non-productive cough persisting for a month. Besides known diabetes, the patient had no other underlying conditions, and his overall condition was good with normal vital signs. Lung auscultation revealed rales and rhonchi in the middle-lower zones of both lungs (Figure 1). Advanced imaging was performed for the patient with severe pneumonic involvement, revealing cavitary lesions (Figure 2).

Figure 1 Figure 2



Materials and Methods: Even though the symptoms in patients presenting to the emergency department might suggest a simple upper respiratory tract infection, it is important not to avoid listening to lung sounds and performing necessary imaging in appropriate cases.

Keywords: Pneumonia, Cavitary lesion

Ref No: 7996

Pituitary macroadenom

Duygu Aras Seyit[1], Murat Seyit[2]

[1]ERPA Saglik Hospital, Denizli
[2]Pamukkale University Faculty of Medicine

Murat Seyit / Pamukkale University Faculty of Medicine

Introduction and Purpose: Pituitary macroadenomas are tumours that develop in the pituitary gland, measuring more than 10 mm in diameter, and are generally benign. Macroadenomas cause visual disturbances, headaches and hypopituitarism by exerting pressure on surrounding structures. Visual impairment arising from the suprasellar extension of a pituitary adenoma is observed in approximately 40–60% of patients. Cranial nerve palsies may also accompany the effects of compression. We present the case of a patient who presented with sudden-onset ptosis of the left eyelid, diplopia and headache; imaging revealed a pituitary macroadenoma extending into the cavernous sinus, and the patient was referred for surgery.

Materials and Methods: A 48-year-old male patient presented with complaints of sudden-onset drooping of the left eyelid, double vision and headache one week prior. The patient, who was morbidly obese, had no chronic conditions other than hypertension. Blood tests revealed no abnormalities; however, a contrast-enhanced brain MRI performed to assess cranial pathologies identified a pituitary macroadenoma invading the cavernous sinus. A 22 mm macroadenoma was identified on the contrast-enhanced pituitary MRI. The patient, whose brain MRI angiography was normal, was assessed by the endocrinology and neurosurgery teams. The patient, who was prescribed hormone therapy, was referred for surgery.

MRI

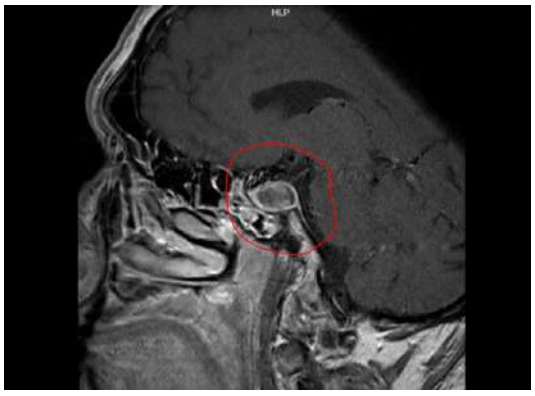

Materials and Methods: Pituitary macroadenomas are lesions originating from the sellar region, measuring more than 10 mm in size and exhibiting extrasellar extension. The most common symptoms are headache, visual disturbances and hypopituitarism due to mass effect. However, 15–20% of these cases are detected incidentally, with no clinical symptoms present. Although headaches are present in the majority of cases, they may also lead to symptoms such as hormonal imbalances, nausea and vomiting, and visual disturbances. Occasionally, haemorrhage within the lesion may occur, leading to more acute symptoms. Macroadenomas may invade the cavernous sinus and affect other cranial nerves, particularly the oculomotor nerve (IV), as well as the V and VI nerves. Acute visual symptoms are urgent, and the patient should be referred for surgery.

Keywords: Pituitary macroadenom, headache, visual disturbances

---

Ref No: 8032

CLINICAL AND ETIOLOGICAL PROFILE OF TRAUMATIC BRAIN INJURY IN THE EMERGENCY DEPARTMENT, INSTITUTE OF EMERGENCY MEDICINE, 2024

Raed Habach[1], Artemie Pelevaniuc[2], Rodica Galbur[2], Tatiana Malacinschi-Codreanu[1]

[1]State University of Medicine and Pharmacy Nicolae Testemițanu
[2]Emergency Medicine Institute

Raed Habach / State University of Medicine and Pharmacy Nicolae Testemițanu

Introduction and Purpose: Traumatic brain injury (TBI) is a common and complex pathology in emergency practice, significantly impacting the functional and socio-economic status of adult patients. Early intervention is essential to reduce complications and neurological sequelae. To evaluate the clinical and demographic characteristics, etiological factors, injury severity, and diagnostic and treatment strategies applied in the Emergency Department (ED) of the Institute of Emergency Medicine (IEM) in adults with TBI.

Materials and Methods: A prospective descriptive study was conducted on a cohort of 72 adult patients with TBI who presented to the ED of IEM between January 1 and December 31, 2024. Clinical, demographic, etiological parameters, imaging results, and clinical evolution were analyzed.In 2024, 72 adult TBI cases were registered: 27 patients (37,5%) were treated in the red zone (severe TBI), and 45 (62,5%) in the yellow zone (moderate and mild forms). The gender distribution was 66% men (n=48) and 34% women (n=24), with a statistically significant difference ($p < 0,05$). The overall mean age was $53 \pm 18,3$ years, with significant differences between men ($48 \pm 16,7$ years) and women ($56 \pm 19,1$ years) ($p=0,03$). Predominant age groups

were 30-50 years (40%) and > 60 years (35%). The main etiological factors were accidental falls (38,9%), road traffic accidents (27,8%), and physical assaults (18,1%). A significant correlation was found between etiology and TBI severity ($p < 0.01$). Mild forms accounted for 77,8%, moderate 12,5%, and severe 9,7%. Chronic comorbidities were common: hypertension (60%), obesity (45%), and cardiovascular diseases (30%) ($p < 0,001$). All patients underwent clinical and imaging investigations (cranial CT), with intracranial lesions identified in 51%. Emergency neurosurgical intervention was required in 13,9% of cases, mainly in severe TBI (71%). The average hospital stay was $7,5 \pm 3$ days, extending to 12 ± 2 days in complicated cases ($p < 0,05$). Neurological disabilities post-TBI were observed in 35% of patients with moderate and severe forms.

Materials and Methods: Conclusions. Mild TBI predominates, but a significant proportion of moderate and severe forms are associated with major etiological factors. Age, sex, and etiology influence the severity and post-traumatic evolution. Integrated management in the ED, standardized protocols, and specialized rehabilitation are crucial for reducing disabilities and optimizing care for adult TBI patients.

Keywords: traumatic brain injury, emergency department, severity

---

Ref No: 8052

Peripheral nerve palsy or stroke?

Murat Kurtulmuş[1], Erdal Tekin[1]

[1]Atatürk Üniversitesi

Murat Kurtulmuş / Atatürk Üniversitesi

Introduction and Purpose: Aneurysms are balloon-like bulges that form as a result of weakening of the blood vessel wall. They may not cause any symptoms for years, but they can also present with serious intracranial hemorrhages.In this case, we will examine a patient who presented with numbness only on the left side of their face.

Materials and Methods: Case.55 years old, male.No chronic diseasesVital signs: blood pressure: 140/80, heart rate: 95, pulse: 85GKS 15. No findings on the other side.The patient describes numbness only on the left side of their face. However, examination reveals a mild motor deficit, whether central or peripheral.The patient's initial CT scan showed no major vessel occlusion. However, an appearance consistent with an aneurysm was observed in the left central

artery (MCA). Diffusion MRI showed no acute ischemic changes. The patient was referred to the neurosurgery clinic and underwent surgery.

bt1



bt2

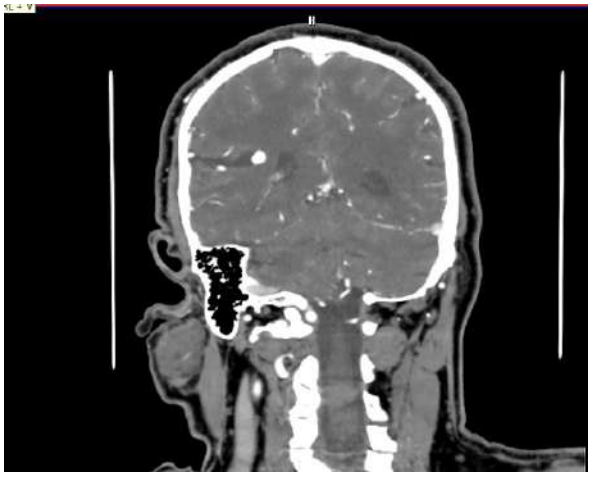

Materials and Methods: Conclusion:Aneurysms can sometimes cause non-specific symptoms.

Keywords: svo, aneurysm, no spesific symtom

Ref No: 8090

Abstract language cannot be updated after the abstract is created.

Emre GÖK[1], Yasin YILDIZ[1], Fadime ÖZYİĞİT GÖK[1], Mesut YILDIZ[1], Mehmet GÜL[1]

[1]Emergency Medicine Department, Konya City Hospital, Türkiye

Emre Gök / Emergency Medicine Department, Konya City Hospital, Türkiye

Introduction and Purpose: Title: Severe valproic acid toxicity following polypharmacy: clinical evaluation of extracorporeal elimination indication and L-carnitine therapy Authors & Affiliations:Emre Gök (1) (Presenting Author), Yasin Yıldız (1), Fadime Özyiğit Gök (1), Mesut Yıldız (1), Mehmet Gül (1)(1) Emergency Medicine Department, Konya City Hospital, Konya, Türkiye Contact: emre_gok_93@hotmail.com Introduction and Aim: Valproic acid (VPA) overdose may present with central nervous system (CNS) depression, metabolic acidosis, and hyperammonemia, potentially leading to a life-threatening clinical condition. In cases associated with polypharmacy, the clinical course may be more severe. In this context, evaluating the indication for extracorporeal elimination together with clinical and biochemical parameters is of critical importance.

Materials and Methods: Materials and Methods: A 23-year-old female was brought to the emergency department (ED) by relatives due to loss of consciousness following intentional high-dose drug ingestion. Serum VPA level was measured as 123.4 milligrams per liter (mg/L), and metabolic acidosis was detected. The patient was intubated and admitted to the intensive care unit (ICU). Gastric lavage and activated charcoal were administered for decontamination, and intravenous L-carnitine therapy was initiated.

Materials and Methods: Results and Conclusion: The need for extracorporeal elimination was evaluated; however, hemodialysis was not performed due to clinical stability. The patient was extubated on day 5 and discharged on day 10. In VPA toxicity, the decision for extracorporeal treatment should not be based solely on serum levels. Clinical presentation and metabolic parameters must be evaluated together, and L-carnitine represents an important supportive treatment option in cases of severe neurological depression. A multidisciplinary approach is essential in polypharmacy-related VPA overdose cases.

Keywords: Valproic acid intoxication, L-carnitine, extracorporeal treatment

Ref No: 8105

Spontaneous Pneumothorax

Egenur Yılmaz[1], Murat Seyit[1], Atakan Yılmaz[1], Mert Özen[1], Alten Oskay[1], İbrahim Türkçüer[1]

[1]Pamukkale University Faculty of Medicine

Murat Seyit / Pamukkale University Faculty of Medicine

Introduction and Purpose: Spontaneous pneumothorax is characterized by the accumulation of air in the pleural space without a history of trauma and commonly presents with sudden-onset chest pain and dyspnea. Management depends on the size of the pneumothorax and the patient's clinical condition. Large pneumothoraces frequently require tube thoracostomy. However, in patients planned for referral to a tertiary center, the risk of clinical deterioration during interhospital transfer should be considered.

Materials and Methods: A 51-year-old male patient presented to an external emergency department with sudden-onset sharp right-sided chest pain radiating to the back. Physical examination and radiological evaluation revealed a large right-sided pneumothorax. Due to the size of the pneumothorax and the anticipated need for tube thoracostomy, the patient was referred to our center with thoracic surgery capability.Prior to transfer, needle thoracostomy was performed to maintain clinical stability and to prevent potential progression to tension pneumothorax. The patient was transported via emergency medical services. Upon admission to our center, he was hemodynamically stable. Follow-up imaging demonstrated marked regression of the pneumothorax compared with the initial evaluation. Owing to clinical stability and radiological improvement, emergency tube thoracostomy was not required, and the patient was managed conservatively.

Pre-transfer imaging

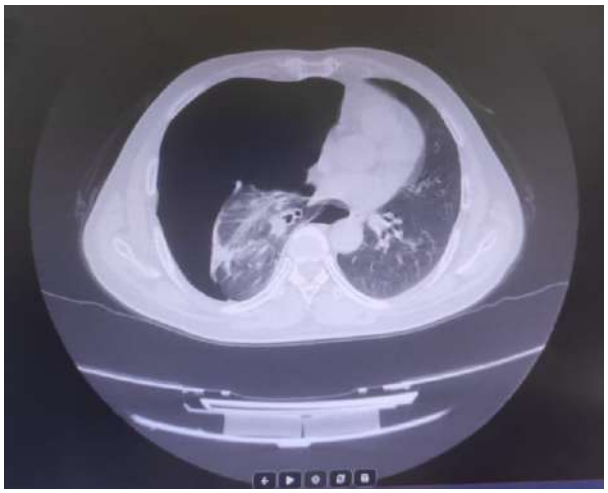

Post-needle thoracostomy imaging

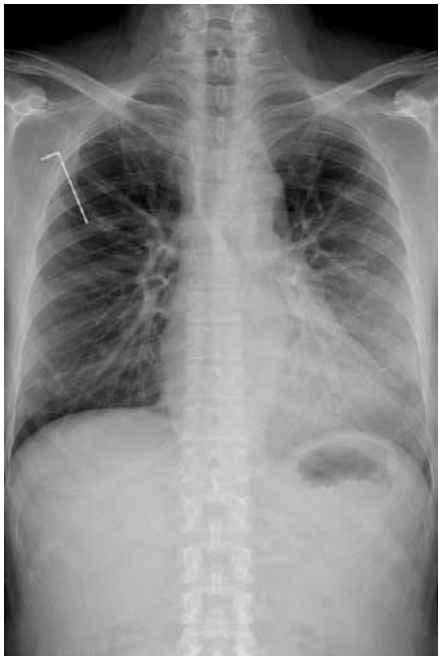

Materials and Methods: This case suggests that pre-transfer needle thoracostomy in patients with large spontaneous pneumothorax may provide effective clinical stabilization, contribute to significant reduction in pneumothorax size, and facilitate safe interhospital transport. With appropriate patient selection, early decompression may eliminate the need for urgent tube thoracostomy in selected cases.

Keywords: Spontaneous pneumothorax, Needle thoracostomy, İnterhospital transfer

Ref No: 8109

Pericarditis in a Patient with Type 1 Diabetes Mellitus

Sait Emre Aydaç[1], Murat Seyit[1], Alten Oskay[1], Atakan Yılmaz[1], Mert Özen[1], İbrahim Türkçüer[1]

[1]Pamukkale University Faculty of Medicine

Murat Seyit / Pamukkale University Faculty of Medicine

Introduction and Purpose: Chest pain is one of the most common reasons for presentation to the emergency department. Increased public awareness often leads patients to associate any chest pain with myocardial infarction, resulting in frequent emergency visits even for mild or atypical symptoms. This contributes to emergency department overcrowding and requires careful clinical evaluation to differentiate life-threatening conditions from benign causes.

Materials and Methods: A 23-year-old male with a known history of Type 1 diabetes mellitus presented to the emergency department with chest pain. His general condition was good, and no additional symptoms were reported. The pain was mild and non-exertional. There was no history of substance abuse or rheumatic fever.Vital signs were as follows: blood pressure 125/76 mmHg, oxygen saturation 96%, heart rate 76 beats per minute, and body temperature 36.7°C. Electrocardiography showed normal sinus rhythm. Laboratory evaluation revealed negative infectious markers. Serial troponin levels were 27–25 ng/L (0–1 hour), without significant dynamic change. Other laboratory findings were within normal limits. No recurrent chest pain was observed during follow-up.Transthoracic echocardiography demonstrated normal cardiac wall motion without structural abnormalities or vegetations. Minimal pericardial effusion was detected in the posterolateral region. The patient was admitted to the cardiology department with a preliminary diagnosis of pericarditis for further evaluation and management.

Materials and Methods: The classic clinical features of pericarditis may not be present in every patient. Particular caution is warranted in individuals with potential immune compromise, such as those with diabetes mellitus. While excluding myocardial infarction is essential in patients presenting with chest pain, ruling out pericarditis is equally important to prevent complications such as cardiac tamponade. Early diagnosis and appropriate monitoring are therefore critical.

Keywords: Pericarditis, Pericardial effusion, Echocardiography

Ref No: 8120

SJS/TEN Overlap: Drug-Associated Epidermal Detachment in a 56-Year-Old Woman

Murat Can Tahta[1], Murat Seyit[1], Atakan Yılmaz[1], Mert Özen[1], Alten Oskay[1], İbrahim Türkçüer[1]

[1]Pamukkale University Faculty of Medicine

Murat Seyit / Pamukkale University Faculty of Medicine

Introduction and Purpose: Stevens-Johnson syndrome (SJS) and toxic epidermal necrolysis (TEN) are rare but potentially fatal mucocutaneous drug reactions characterized by blistering and epidermal detachment. Classification is based on detached body surface area (< 10% SJS, 10-30% overlap, > 30% TEN). Early recognition in the emergency department and prompt withdrawal of suspected drugs are crucial.

Materials and Methods: A 56-year-old woman with hypertension presented with a 3-4 day history of diffuse rash. Rash began the morning after receiving Arveles (dexketoprofen) and Metpamid (metoclopramide) injections four days earlier. She had been treated symptomatically at an outside ED; admitted briefly with presumed pneumonia (CRP 211) and received moxifloxacin, paracetamol, inhalers, and acetylcysteine. Due to rapid progression she was transferred. On arrival: BP 129/72 mmHg, HR 118 bpm, RR 16/min, temperature 37 °C, glucose 121 mg/dL. Examination showed painful blanching erythematous maculopapular lesions involving ~60% of body surface area (including palms/soles). Nikolsky-positive epidermal detachment was present on both forearms and upper back (~18%). Oral mucosal erosions and conjunctival erythema were noted; no genital involvement. Labs: urea 69 mg/dL, creatinine 1.34 mg/dL (BUN 32). After Dermatology/Infectious Diseases/Ophthalmology consultations, SJS/TEN overlap was considered and the patient was admitted to the anesthesia ICU for supportive care.

ED Approach

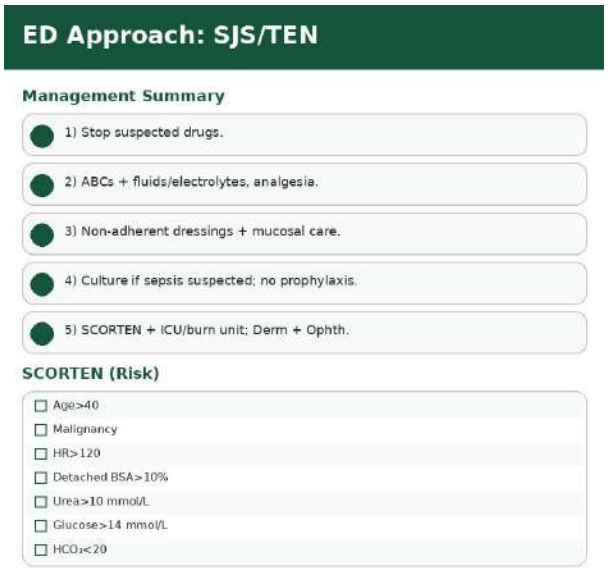



Materials and Methods: This case highlights the need to promptly recognize SJS/TEN in the ED when there is recent medication exposure, rapidly progressive painful rash, mucosal involvement, and Nikolsky positivity. Key management principles include immediate withdrawal of suspected drugs, fluid/electrolyte replacement and analgesia, non-adherent dressings with skin/mucosal care, close monitoring for infection/sepsis, and early multidisciplinary care (Dermatology, Ophthalmology, ICU/burn unit). SCORTEN-based risk stratification can support early disposition and management planning.

Keywords: Stevens-Johnson syndrome, toxic epidermal necrolysis, emergency department

Ref No: 8128

Complete AV Block in an Elderly Patient Presenting to the Emergency Department with Dizziness and Hypotension

Murat Can Tahta[1], Murat Seyit[1], Mert Özen[1], Alten Oskay[1], Atakan Yılmaz[1], İbrahim Türkçüer[1]

[1]Pamukkale University Faculty of Medicine

Murat Seyit / Pamukkale University Faculty of Medicine

Introduction and Purpose: Complete atrioventricular (AV) block is a high-risk bradyarrhythmia in older adults, often presenting with dizziness, syncope, and hypotension. Emergency care focuses on rapid recognition of instability, evaluation of reversible causes, and timely initiation of pacing and supportive therapy.

Materials and Methods: An 85-year-old woman presented with progressively worsening dizziness for 3 weeks and marked fatigue over the last 1–2 days. Past history included arrhythmia, hypertension, chronic kidney disease, and osteoporosis; she was on multiple medications, including a beta-blocker and antiarrhythmic therapy. On arrival her blood pressure was 85/62 mmHg, SpO_2 94%, temperature 36.4 °C, and heart rate fluctuated between 35–57 bpm. Neurologic examination was normal; bibasilar crackles were noted. A 12-lead ECG demonstrated a high-grade conduction disorder consistent with AV dissociation. Laboratory/arterial blood gas analysis suggested concomitant hyperkalemia and metabolic acidosis. Given symptomatic bradycardia and hemodynamic compromise, cardiology consultation was obtained.

ECG



Symptomatic bradycardia

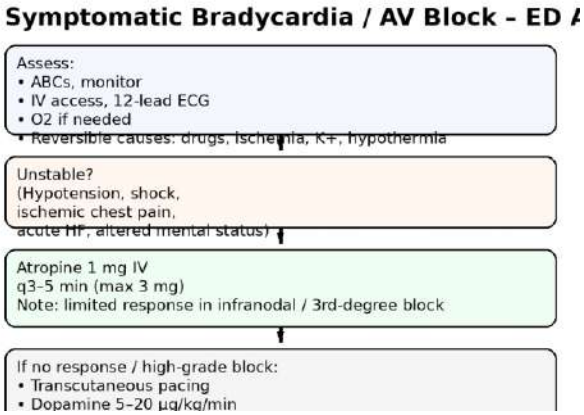

Materials and Methods: The patient was taken for temporary pacemaker implantation due to suspected complete AV block. This case highlights that dizziness in elderly patients—especially those on rate-limiting drugs—may reflect a life-threatening conduction problem. Early ECG acquisition is essential, and coexisting electrolyte disturbances (notably hyperkalemia) may influence both diagnosis and management. An algorithmic ED approach (atropine trial, transcutaneous pacing, and/or vasopressor infusion) can be lifesaving while definitive pacing is arranged.

Keywords: Complete AV block, Symptomatic bradycardia, Temporary pacing

---

Ref No: 8247

Management of Low-Risk Pulmonary Embolism

Ekrem Bulut[1], Merve Bulut[1], Ayça Çalbay[1]

[1]AtatÜrk University Faculty of Medicine

Ekrem Bulut / AtatÜrk University Faculty of Medicine

Introduction and Purpose: Pulmonary embolism (PE) is a potentially fatal diagnosis that should not be missed in young patients presenting to the emergency department with pleuritic chest pain. In low-risk cases, the PERC rule is considered the gold standard for avoiding unnecessary testing. However, in emergency practice, physician clinical suspicion (gestalt) may sometimes outweigh scoring systems. We present a young patient diagnosed with PE based on

clinical suspicion despite a negative PERC rule and safely discharged with outpatient management.

Materials and Methods: A 23-year-old previously healthy man presented with sudden-onset pleuritic chest pain. Vital signs (BP 120/75 mmHg, HR 82 bpm, RR 16/min, SpO_2 98%) and physical examination were unremarkable. The modified Wells score indicated low risk, and all eight PERC criteria were negative. Despite guidelines not recommending further testing, strong clinical suspicion due to atypical pleuritic pain prompted D-dimer testing, which was positive. CT pulmonary angiography revealed filling defects in the segmental branches of the right lower lobe consistent with PE(Figure-1). Focused bedside echocardiography (POCUS) showed no right ventricular strain, and cardiac troponin was negative. The simplified PESI (sPESI) score was 0, classifying the patient as low-risk PE. The patient was discharged with subcutaneous enoxaparin sodium and appropriate follow-up and return precautions.

Figure-1

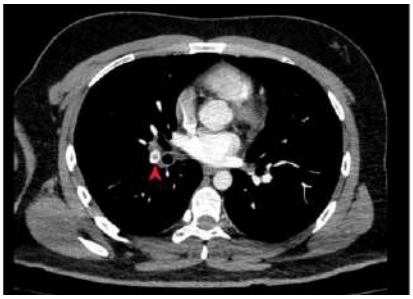

Materials and Methods: Although Tintinalli and Rosen's guidelines do not recommend routine D-dimer testing in PERC-negative patients, UpToDate emphasizes the importance of clinical gestalt. In this case, clinical suspicion enabled a life-saving diagnosis. Current ESC and CHEST guidelines support outpatient anticoagulation for hemodynamically stable patients with sPESI=0 and no evidence of right ventricular dysfunction or myocardial injury. This case highlights that scoring systems should not fully replace clinical judgment. After bedside echocardiography and biomarker-based risk stratification, outpatient management of selected low-risk PE patients represents a safe strategy without increasing morbidity.

Keywords: Pulmonary Embolism, PERC score, young patient

Ref No: 8337

Foreign body in trachea

yusuf burak eker[1], ali gür[1], muhammed cengizhan durmuş[1]

[1]Atatürk üniversitesi tıp fakültesi acil tıp anabilim dalı

yusuf burak eker / Atatürk üniversitesi tıp fakültesi acil tıp anabilim dalı

Introduction and Purpose: Foreign bodies in the respiratory tract can partially or completely obstruct the passage of airways. Removing the foreign body can lead to a dramatic relief in the patient's clinical condition.

Materials and Methods: A 40-year-old female patient presented to the emergency department with sudden throat pain while attempting to speak, forgetting that she had a needle in her mouth while tying her headscarf. The patient's vital signs were normal, and a lateral X-ray taken at an external facility showed a foreign body in the epiglottis (Figure 1). The X-rays were repeated upon referral to our department, and it was determined from the anterior-posterior (AP) X-ray that the foreign body was not in the epiglottis but rather on the patient's headscarf (Figure 2).

Figure 1



Figure 2



Materials and Methods: In cases involving foreign body investigation, X-rays should be taken in at least two directions to accurately determine the location of the foreign body.

Keywords: Foreign body in trachea, 2 view chest X-ray

Ref No: 8340

Does every acute appendicitis require surgery?

İbrahim Halil Öcal[1]

[1]Adıyaman Training and Research Hospital

İbrahim Halil Öcal / Adıyaman Training and Research Hospital

Introduction and Purpose: Acute appendicitis has traditionally been managed with appendectomy; however, the role of antibiotic therapy in uncomplicated cases has gained increasing attention. This study aimed to evaluate whether all cases of acute appendicitis require surgical intervention based on current evidence.

Materials and Methods: This study is a literature-based analysis of randomized controlled trials and meta-analyses comparing surgical and non-operative management in acute appendicitis. High-quality studies, particularly the APPAC and CODA trials, were reviewed.

Results and Conclusion: In the APPAC trial, approximately 73% of patients treated with antibiotics did not require surgery within the first year, while the five-year recurrence rate reached 39.1%. The complication rate was higher in the surgical group (24.4% vs. 6.5%).In the CODA trial, 29% of patients receiving antibiotics required appendectomy within 90 days. This rate increased to 41% in patients with an appendicolith and remained approximately 25% in those without.Recent meta-analyses indicate that the one-year success rate of antibiotic therapy is approximately 70–75%, compared to over 95% for surgery. The presence of an appendicolith is a major predictor of treatment failure.In conclusion, not all cases of acute appendicitis require surgery. Non-operative management may be a reasonable alternative in carefully selected patients with uncomplicated appendicitis. However, due to higher recurrence rates and increased failure risk—especially in the presence of an appendicolith—surgical treatment remains the more definitive and reliable option. Treatment decisions should be individualized.

Figure 1. Management strategies for acute appendicitis: surgery versus non-operative treatment.



Keywords: Acute appendicitis, Appendectomy, Antibiotic therapy

Ref No: 8358

From chest trauma to Ewing sarcoma

Erhan Şahin[1], Abdullah Süha Akça[1], İbrahim Özlü[1]

[1]atatürk Üniversitesi Acil Tıp

Erhan Şahin / Atatürk Üniversitesi Acil Tıp

Introduction and Purpose: Ewing's sarcoma is a rare and aggressive tumor that arises in bones and soft tissues. It is typically seen during childhood and adolescence. It is commonly found in the chest cavity, pelvis, long bones, and spine. In many cases, it is incidentally detected during radiological imaging following trauma.

Materials and Methods: A 14-year-old male patient presented to the emergency department with severe chest pain following trauma. Physical examination revealed tenderness in the left chest wall. A chest X-ray and thoracic CT scan, performed due to the trauma history, revealed a solid mass lesion in the left ribs. The patient was referred to oncology, and subsequent follow-up biopsies confirmed the diagnosis of Ewing's sarcoma.

Materials and Methods: Ewing's sarcoma is a tumor that can be successfully managed with chemotherapy and surgical treatment when diagnosed early. This case emphasizes that a simple trauma complaint can lead to a serious diagnosis and that malignancy should be ruled out in patients with persistent pain after trauma. Tumors located in the chest wall have a better prognosis with early diagnosis and a multidisciplinary approach.

photo1



photo2



Keywords: trauma, cancer, ewing sarcoma

Ref No: 8419

Multiple Aortic Pathologies Detected After Elevated D-Dimer in a Patient with Unexplained Dyspnea: A Case Report from the Emergency Department

Hagop Hovıg GARIBIAN[1], Yusuf Ziya TAŞTEKİN[1], Taner FUYGUNOĞLU[1], Mustafa POLAT[1], Ali KARAKUŞ[1]

[1]Hatay Mustafa Kemal University Emergency Medicine Department

Yusuf Ziya TAŞTEKİN / Hatay Mustafa Kemal University Emergency Medicine Department

Introduction and Purpose: IntroductionDyspnea is one of the most common reasons for presentation to the emergency department and may originate from pulmonary, cardiac, or vascular causes. When the initial evaluation does not reveal a clear pulmonary or cardiac etiology, the differential diagnosis should be broadened. D-dimer is a sensitive but nonspecific biomarker used in the evaluation of thrombotic and vascular diseases. Elevated D-dimer levels may prompt advanced imaging studies and occasionally lead to the detection of unexpected but clinically significant vascular pathologies.

Materials and Methods: Case PresentationA 77-year-old female presented to the emergency department with complaints of cough, dyspnea, and headache. Her past medical history included

diabetes mellitus, hypertension, and asthma. Vital signs at presentation were blood pressure 170/93 mmHg, heart rate 80 beats/min, and oxygen saturation 96% on room air. Peripheral pulse examination was normal.The clinical probability of pulmonary embolism was assessed and the patient was considered low risk according to the Wells score, and PERC criteria were not fulfilled. Since no clear pulmonary or cardiac pathology explaining the dyspnea was identified, D-dimer testing was performed and was found to be elevated.Thoracic and abdominal CT angiography revealed a fusiform aneurysmal dilatation of the ascending aorta measuring approximately 57 mm. The abdominal aorta was of normal caliber but intraluminal thrombus formation was detected. In addition, a hypodense lesion measuring approximately 1.5 × 2.5 cm was observed in the pulmonary apex, reported as compatible with pulmonary thrombus.The patient was consulted with cardiovascular surgery and admitted for further evaluation and management.

Materials and Methods: In patients presenting to the emergency department with unexplained dyspnea and elevated D-dimer levels, vascular pathologies should be considered. Advanced imaging may reveal life-threatening aortic diseases that require prompt evaluation.

Keywords: Aortic aneurysm, aortic thrombosis, D-dimer

Ref No: 8429

A FRAGILE ORGAN UNDER IMPACT

Nisa Mındız[1], İBRAHİM ÖZLÜ[1], MUHAMMED CENGİZHAN DURMUŞ[1]

[1]ATATÜRK UNIVERSITY EMERGENCY DEPARTMENT

Nisa Mındız / ATATÜRK UNIVERSITY EMERGENCY DEPARTMENT

Introduction and Purpose: Renal injuries constitute a significant portion of blunt abdominal trauma, particularly in the pediatric population. Motor vehicle accidents are among the most common causes. Renal lacerations may present with a wide spectrum of clinical findings depending on the severity of trauma, and early diagnosis along with appropriate management is crucial to prevent complications.

Materials and Methods: An 11-year-old male patient was brought to the emergency department following an in-vehicle traffic accident. On admission, the Glasgow Coma Scale (GCS) score was 9. Vital signs revealed a blood pressure of 108/64 mmHg and a pulse rate of 121 beats/min.On physical examination, abdominal tenderness was present without rebound or

guarding. Hyperemia was observed in the left flank region.Abdominal computed tomography (CT) imaging was performed for diagnostic evaluation. CT findings revealed a full-thickness laceration in the mid-zone of the left kidney accompanied by an intraparenchymal hematoma. Additionally, a perirenal hematoma measuring approximately 18 mm in thickness was observed surrounding the laceration.The patient was consulted with the pediatric surgery department and was admitted for further monitoring and management.

PHOTO1

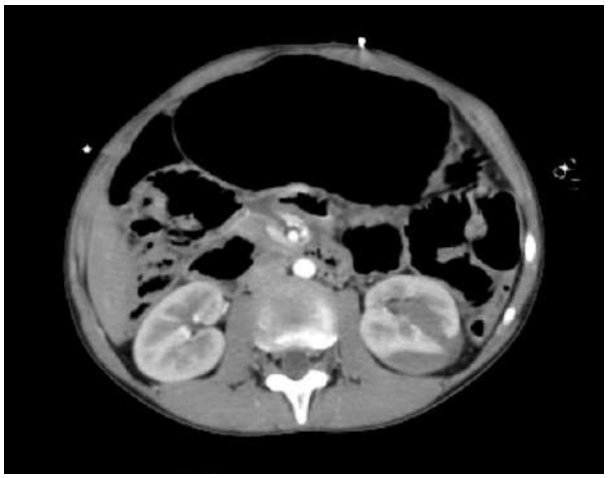

Materials and Methods: Renal trauma in pediatric patients most commonly occurs due to blunt mechanisms, with motor vehicle accidents being the leading cause. Children are more susceptible to renal injuries due to less protective perirenal fat and relatively less developed abdominal musculature compared to adults.Computed tomography is the gold standard imaging modality for evaluating renal injuries. It provides detailed information regarding the extent of laceration, presence of hematoma, and associated injuries.In hemodynamically stable patients, conservative management is the preferred approach, and close clinical monitoring is essential. However, surgical intervention may be required in cases of hemodynamic instability or ongoing bleeding.

Keywords: Renal laceration, perirenal hematoma, pediatric trauma

Ref No: 8431

Cause of a generalised tonic-clonic seizure: Substance withdrawal syndrome

Duygu Aras Seyit[1], Murat Seyit[2]

[1]ERPA Saglik Hospital, Denizli
[2]Pamukkale University Faculty of Medicine

Murat Seyit / Pamukkale University Faculty of Medicine

Introduction and Purpose: Substance withdrawal syndrome refers to the physical and psychological symptoms that arise when the body is deprived of substances to which it has become accustomed to the extent of dependence, following the abrupt cessation of those substances. This report describes a case in which a generalised tonic-clonic seizure developed following the abrupt cessation of the substance used (cocaine).

Materials and Methods: A 36-year-old male patient, with no known chronic illnesses, presented with a generalised tonic-clonic seizure. Blood tests revealed mildly elevated levels of ALT, AST and GGT. The patient had no fever, and a brain MRI scan revealed no acute pathology. A history taken from the patient's family indicated that he had been using the substance for approximately 10 years but had not used it for the past week. Following brain MRI venography (venous thrombosis?) and MR angiography (aneurysm?), both of which were normal, and a lumbar puncture revealing no abnormalities, a symptomatic epileptic seizure associated with sudden substance withdrawal was suspected. No further seizures were observed during follow-up after medical treatment was initiated. The patient was referred to the psychiatry department.

Materials and Methods: A symptomatic epileptic seizure is a seizure that develops as a result of acute damage or disease affecting the brain, such as a stroke, head injury, abrupt discontinuation of medication, infection or metabolic disorders. In a patient presenting to A&E for the first time with an epileptic seizure, blood counts, electrolytes, and liver and kidney function tests should be performed to determine the aetiology, whilst brain MRI, MR venography and MR angiography should be carried out to assess for cranial pathologies. During a detailed medical history, the patient's medication history, chronic conditions, history of infection and substance use must also be thoroughly investigated. Substance use should be explored in detail, particularly in the younger population. In patients where investigations reveal no abnormalities and a symptomatic seizure is suspected based on the medical history, antiepileptic treatment should be initiated, and treatment targeting the underlying aetiology must also be added.

Keywords: Epileptic seizure, MR, Substance use

Ref No: 8475

Massive Pulmonary Embolism Mimicking Acute Coronary Syndrome: A Case Report

Sait Emre Aydaç[1], Murat Seyit[1], Atakan Yılmaz[1], Mert Özen[1], Alten Oskay[1], İbrahim Türkçüer[1]

[1]Pamukkale University Faculty of Medicine

Murat Seyit / Pamukkale University Faculty of Medicine

Introduction and Purpose: Pulmonary embolism (PE) is a potentially life-threatening condition with a broad clinical spectrum ranging from mild symptoms to hemodynamic instability and shock. Due to its nonspecific presentation, PE may mimic acute coronary syndrome (ACS), leading to diagnostic challenges. Early recognition is essential, particularly in massive or submassive cases.

Materials and Methods: A 53-year-old male with a history of intestinal cancer presented to the emergency department with acute chest pain and a preliminary diagnosis of ACS. On admission, his vital signs were: GCS 15, heart rate 137 bpm, blood pressure 110/70 mmHg, oxygen saturation 95%, and respiratory rate 28/min. ECG showed sinus tachycardia.Bedside transthoracic echocardiography revealed dilated right-sided cardiac chambers and a septal D-sign, indicating right ventricular pressure overload. Arterial blood gas analysis demonstrated respiratory alkalosis with hypoxemia (pH 7.47, PO_2 67.1 mmHg, PCO_2 22.9 mmHg). Troponin levels were elevated (53–124 ng/L within 1 hour). Other laboratory findings were unremarkable.CT pulmonary angiography confirmed embolic filling defects extending from the distal pulmonary trunk into the main, lobar, and segmental pulmonary arteries. No parenchymal consolidation was observed.

Materials and Methods: This case emphasizes the importance of considering PE in the differential diagnosis of chest pain, especially in patients with malignancy. Bedside echocardiography plays a critical role in early risk stratification. Prompt diagnosis and appropriate management are essential to prevent hemodynamic deterioration and potential cardiac arrest.

Keywords: Echocardiography, Massive Pulmonery Embolism, Septum D sign

Ref No: 8481

Infective Endocarditis In A Patient With Familial Mediterranean Fever

Tuba Nur Vural[1], Murat Seyit[1], Atakan Yılmaz[1], Mert Özen[1], Alten Oskay[1], İbrahim Türkçüer[1]

[1]Pamukkale University Faculty of Medicine

Murat Seyit / Pamukkale University Faculty of Medicine

Introduction and Purpose: Infective endocarditis (IE) is a serious cardiac condition characterized by infection of the endocardial surface, most commonly involving the heart valves. Early diagnosis using echocardiography is critical to prevent severe complications.

Materials and Methods: A 21-year-old female patient with a known history of Familial Mediterranean Fever (FMF) presented to the emergency department with a two-day history of chest pain. She was receiving colchicine therapy regularly. The chest pain was described as a burning sensation. Physical Examination and Vital Signs: On admission, vital signs were within normal limits. Cardiovascular and respiratory examinations were unremarkable. Electrocardiographic and Echocardiographic Findings: Electrocardiography demonstrated normal sinus rhythm. Transthoracic echocardiography performed by the cardiology team revealed valvular vegetation, findings suggestive of infective endocarditis. Diagnosis and Management: Based on echocardiographic findings, the patient was diagnosed with probable infective endocarditis. She was admitted to the cardiology service for further evaluation, including blood cultures and initiation of appropriate intravenous antibiotic therapy.

Materials and Methods: Infective endocarditis should be considered in young patients presenting with unexplained chest pain when echocardiographic evidence of vegetation is detected. Early cardiology consultation and inpatient management are essential to prevent complications.

Keywords: Infective Endocarditis, Vegetation, Familial Mediterranean Fever

Ref No: 8489

Anaphylaxis After Antibiotic Administration (With Biphasic Reaction)

Sabri Furkan Bulca[1], Murat Seyit[1], Atakan Yılmaz[1], Mert Özen[1], Alten Oskay[1], İbrahim Türkçüer[1]

[1]Pamukkale University Faculty of Medicine

Murat Seyit / Pamukkale University Faculty of Medicine

Introduction and Purpose: Anaphylaxis is a systemic hypersensitivity reaction that can progress within minutes to life-threatening airway edema and circulatory collapse. The most critical treatment is prompt intramuscular administration of adrenaline (epinephrine).

Materials and Methods: A 35-year-old woman presented to the emergency department with widespread urticaria, a sensation of throat fullness, shortness of breath, and dizziness occurring within 5 minutes after intravenous antibiotic administration for a presumed urinary tract infection. Vital signs were: blood pressure 80/45 mmHg, heart rate 132/min, respiratory rate 30/min, and SpO_2 90%. Auscultation revealed diffuse wheezing. Based on the clinical presentation, anaphylaxis was rapidly diagnosed. The patient was treated with 0.5 mg IM adrenaline (epinephrine), high-flow oxygen, crystalloid fluid resuscitation, an H1 antihistamine, and systemic corticosteroids; nebulized salbutamol was administered for bronchospasm. Following treatment, her hemodynamics stabilized and symptoms improved. While the patient was being observed for a possible biphasic reaction, recurrent widespread urticaria and dyspnea developed at the 8th hour, consistent with biphasic anaphylaxis. After re-evaluation, medical therapy was adjusted, and she was admitted to the dermatology ward for close monitoring.

Materials and Methods: This case highlights the importance of early recognition of anaphylaxis in the setting of hypotension and bronchospasm after medication administration, prioritization of adrenaline as first-line therapy, and adequate observation for biphasic reactions. Because biphasic anaphylaxis may recur hours after the initial response, close monitoring and reassessment in the emergency department are essential. In cases accompanied by hypotension and respiratory symptoms, the risk of recurrence may be higher; therefore, the observation period should be extended and hospital admission should be considered if clinical deterioration occurs.

Keywords: Anaphylaxis, biphasic reaction, antibiotic.

Ref No: 8561

INFERIOR VENA CAVA DUPLICATION: A RARE CONGENITAL ANOMALY ASSOCIATED WITH VENOUS THROMBOEMBOLISM

Yusuf Ziya TAŞTEKİN[1], Saygın ÇANGA[1], İsmet ALTUĞ[1], Ali Utku EŞKİ[1], İzel HÜZMELİ ÖNCÜ[1], Hasan ALTUN[1], Mehmet HATUN[1], Mustafa POLAT[1], Ali KARAKUŞ[1]

[1]Hatay Mustafa Kemal University, Faculty of Medicine, Department of Emergency Medicine, Hatay, Turkey

Yusuf Ziya TAŞTEKİN / Hatay Mustafa Kemal University, Faculty of Medicine, Department of Emergency Medicine, Hatay, Turkey

Introduction and Purpose: INTRODUCTIONInferior vena cava (IVC) anomalies are rare congenital venous variations and are often detected incidentally because they are asymptomatic in most cases. In this case report, we aim to discuss the radiological clues and critical points in clinical management of this rare congenital anomaly, using the example of a patient presenting with venous thromboembolism in whom IVC duplication was detected on imaging, supported by the literature.

Materials and Methods: CASE REPORT A 45-year-old male patient presented to the emergency department with a complaint of abdominal pain that had persisted for two days and worsened on the day of presentation. The patient had no known chronic illnesses, was not on regular medication, and had no significant risk factors for venous thromboembolism. Physical examination revealed epigastric tenderness. Vital signs were stable: blood pressure 120/80 mmHg, heart rate 100 bpm, and temperature 36.6 °C. Laboratory findings showed Hb 10.1 g/dL, AST/ALT 112/133 U/L, INR 1.43, aPTT 68.3 sec, and D-dimer 2564.A contrast-enhanced chest-abdominal CT scan performed with a preliminary diagnosis of venous thromboembolism and portal vein thrombosis revealed duplication of the inferior vena cava (IVC) starting at the suprarenal level, portal vein dilation, and widespread free fluid in the abdomen (FIGURE 1-FIGURE 2). Hepatobiliary Doppler ultrasound revealed the absence of flow in the intrahepatic veins, the right common femoral vein, and the splenic vein, consistent with thrombosis/stasis. Transthoracic echocardiography revealed a left ventricular ejection fraction of 30%, global hypokinesis, mild mitral and moderate tricuspid regurgitation, and microthrombi in the right cardiac chambers. Anticoagulation therapy with enoxaparin was initiated. During clinical follow-up, improvement in the patient's symptoms was observed, and the patient was admitted to the intensive care unit for monitoring. Further investigations were planned to investigate the etiology, focusing on thrombophilia and autoimmune causes.

Materials and Methods: CONCLUSIONAlthough inferior vena cava duplication is often an asymptomatic congenital venous variation detected incidentally, it can lead to clinically significant outcomes regarding thromboembolic diseases and interventional procedures. Especially in patients presenting with deep vein thrombosis or pulmonary embolism, a detailed evaluation of venous anatomy using contrast-enhanced cross-sectional imaging is of critical importance for preventing misdiagnosis and determining an appropriate treatment strategy.

Keywords: Inferior vena cava duplication, venous thromboembolism, deep vein thrombosis

---

Ref No: 8587

Young Male With Chest Pain: Pneumomediastinum

Sabri Furkan Bulca[1], Murat Seyit[1], Mert Özen[1], Alten Oskay[1], Atakan Yılmaz[1], İbrahim Türkçüer[1]

[1]Pamukkale University Faculty of Medicine

Murat Seyit / Pamukkale University Faculty of Medicine

Introduction and Purpose: Spontaneous pneumomediastinum (SPM) is more common in young males and follows a benign course in most cases. It may occur after Valsalva maneuvers that increase intrathoracic pressure—such as weightlifting—leading to alveolar rupture and air dissection into the mediastinum. The most common presenting symptom is sudden-onset retrosternal chest pain, and subcutaneous emphysema may be detected on physical examination. In cases where mediastinal free air is identified, life-threatening causes—especially esophageal perforation—must be excluded.

Materials and Methods: An 18-year-old male presented with sudden-onset, stabbing retrosternal chest pain that began during lunch. He had no comorbidities and was not taking any regular medications. On arrival, vital signs were stable (BP 147/90 mmHg, HR 87/min, RR 20/min, temperature 36.5°C, SpO_2 98%). He was alert and cooperative. Physical examination revealed subcutaneous crepitus in the clavicular region; the remainder of the examination was unremarkable. Electrocardiography showed normal sinus rhythm. Posteroanterior chest radiography demonstrated findings consistent with free air in the mediastinal region. Chest computed tomography confirmed mediastinal free air, and the patient was diagnosed with pneumomediastinum.

X-Ray

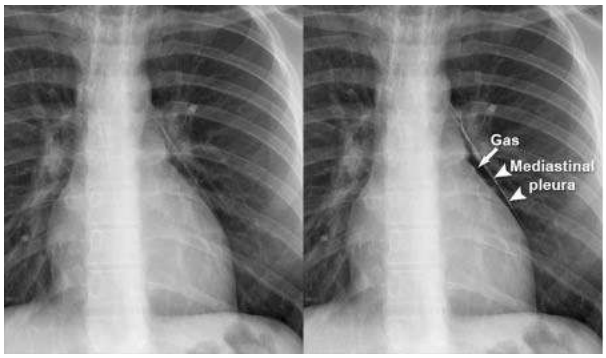

Materials and Methods: SPM should be considered in the differential diagnosis of young adults presenting with sudden-onset chest pain, particularly after activities that increase intrathoracic pressure. Prognosis is generally favorable in clinically stable patients, and conservative management is often sufficient; however, life-threatening conditions such as Boerhaave syndrome, pneumothorax, pulmonary embolism, and acute coronary syndrome must be definitively excluded.

Keywords: Spontaneous pneumomediastinum, chest pain

Ref No: 8612

Emergency Department Atypical Appendicitis: Diagnostic Pitfalls and a Case Report

Mustafa AYAN[1]

[1]Sivas Numune Hospital

Mustafa AYAN / Sivas Numune Hospital

Introduction and Purpose: Acute appendicitis is one of the most common surgical emergencies in both children and adults, with an annual incidence of 100–223 per 100,000 people and a lifetime risk of approximately 7–8%. The typical presentation involves pain that starts around the navel and localises to the right lower quadrant, accompanied by loss of appetite, fever, and nausea or vomiting. However, advanced age, female gender, pregnancy and anatomical variations such as malrotation may cause the appendix to be located atypically, complicating diagnosis and increasing the risk of missed cases in the emergency department. This presentation describes a patient with right upper quadrant pain and normal hepatobiliary ultrasonography, in

whom subhepatic appendicitis was diagnosed by contrast-enhanced CT, and is discussed in the context of the literature.

Materials and Methods: A patient presented with right upper quadrant pain and tenderness that had started the previous day. Physical examination revealed marked tenderness, guarding and rebound in the same area. Laboratory tests showed a white blood cell count of 17,000/mm³ and a C-reactive protein level of 182 mg/L. Hepatobiliary ultrasonography was reported as normal, with no findings suggestive of cholecystitis. Intravenous contrast-enhanced abdominal CT subsequently demonstrated an appendix measuring approximately 12 mm in diameter with surrounding inflammatory changes extending to the subhepatic region, and the patient underwent emergency appendectomy after referral to general surgery.

Subhepatik apandisit



subhepatic appendicitis



Results and Conclusion: The patient was discharged without complications during postoperative follow-up. Reported complications of delayed diagnosis of subhepatic appendicitis include adhesions (43%), perforation (32%) and subhepatic abscess (28%), which are associated with increased mortality and morbidity. Although rare, subhepatic appendicitis represents an important diagnostic pitfall in patients presenting with right upper quadrant pain and a normal hepatobiliary ultrasound, for whom early contrast-enhanced CT and prompt surgical consultation are critical for optimising prognosis. This case aims to raise awareness among clinicians of appendicitis with atypical localisation and challenging diagnosis.

Keywords: atypical appendicitis, subhepatic appendicitis, acute abdomen

Ref No: 8674

A Rare Syndrome in Persistent Abdominal Pain: Median Arcuate Ligament Syndrome

Alparslan Altun / Atatürk University Hospital Department Of Emergency Medicine

Introduction and Purpose: Median Arcuate Ligament Syndrome (MALS) is a rare clinical condition caused by external compression of the celiac artery by the median arcuate ligament. It typically presents with postprandial abdominal pain, weight loss, nausea, and vomiting. Due to the nonspecific nature of symptoms, diagnosis is often delayed and requires a high index of clinical suspicion along with appropriate imaging modalities.

Materials and Methods: A 53-year-old male patient presented with abdominal pain that had been increasing განსაკუთრებით after meals for approximately three months. The pain was localized to the epigastric region and was accompanied by nausea and loss of appetite. The patient also reported unintentional weight loss during this period.On physical examination, epigastric tenderness was noted, with no signs of peritonitis. Laboratory findings were within normal limits.Contrast-enhanced computed tomography (CT) angiography revealed focal narrowing in the proximal celiac artery with a characteristic “hooked” appearance, suggestive of compression by the median arcuate ligament.Based on the clinical and radiological findings, the patient was diagnosed with Median Arcuate Ligament Syndrome and referred for surgical evaluation.

CT

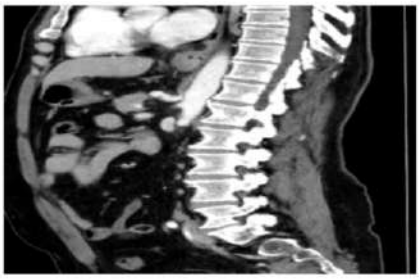

Materials and Methods: Median Arcuate Ligament Syndrome is a rare but important cause of chronic abdominal pain. It should be considered in the differential diagnosis, especially in younger patients presenting with postprandial pain and weight loss. CT angiography and Doppler ultrasonography play a critical role in diagnosis. Early diagnosis and appropriate treatment can lead to significant improvement in symptoms.

Keywords: Median Arcuate Ligament Syndrome, Persistent Abdominal Pain

Ref No: 8690

A Hidden Danger in the Emergency Department: SGLT2 Inhibitor-Induced Euglycemic Diabetic Ketoacidosis

Mikail Kuşdoğan[1], Emre Gökçen[1], Levent Albayrak[1], Sevilay Vural[1], Faruk Türkmen[1], Yağmur Koca[1]
[1]Yozgat Bozok University, Department Of Emergency Medicine, Yozgat, Turkey.
Emre Gökçen / Yozgat Bozok University, Department Of Emergency Medicine, Yozgat, Turkey.

Introduction and Purpose: Euglycemic Diabetic Ketoacidosis (EDKA) is a life-threatening emergency characterized by metabolic acidosis with an increased anion gap and ketosis, despite normal or mildly elevated blood glucose levels. The underlying pathophysiology involves relative insulin deficiency and glucagon excess. While the use of Sodium-Glucose Cotransporter-2 (SGLT2) inhibitors is a primary driver for the rising incidence of EDKA, other triggers include pregnancy, prolonged fasting, ketogenic diets, and surgical stress. The absence of marked hyperglycemia often leads to diagnostic delays in emergency departments. This case highlights a patient using SGLT2 inhibitors to emphasize the importance of clinical suspicion in normoglycemic presentations.

Materials and Methods: A 47-year-old male presented to the emergency department with a 3-day history of severe fatigue, anorexia, nausea, and diffuse abdominal pain. His medical history revealed the recent addition of an SGLT2 inhibitor to his Type 2 Diabetes treatment regimen. Vital signs were: temperature 36.5°C, blood pressure 115/75 mmHg, heart rate 112 bpm, and O_2 saturation 98%. Physical examination revealed dry oral mucosa, decreased skin turgor, and diffuse abdominal tenderness.Laboratory investigations revealed a venous blood gas with a pH of 7.17, HCO3 of 8.2 mmol/L, base excess of -17 mmol/L, and PCO_2 of 24.5 mmHg, while biochemical analysis showed a serum glucose level of 118 mg/dL and urinalysis detected 4+ ketones. Despite a blood glucose level significantly below the typical 250 mg/dL threshold, the presence of profound metabolic acidosis and heavy ketonuria confirmed the diagnosis of EDKA. Management was immediately initiated with aggressive fluid resuscitation, intravenous insulin infusion, and concurrent 5% dextrose to prevent hypoglycemia. The patient was admitted to the intensive care unit for continued monitoring and therapy.

Materials and Methods: In patients presenting with non-specific symptoms like nausea and abdominal pain, near-normal glucose levels can mislead clinicians away from a DKA diagnosis. However, in those using SGLT2 inhibitors or facing physiological stressors, EDKA must be considered regardless of glycemic status. Calculating the anion gap and checking for ketones is vital for early diagnosis and life-saving intervention.

Keywords: Euglycemic Diabetic Ketoacidosis, SGLT2 inhibitors, Emergency Medicine

Ref No: 8696

An Unexpected Complication After Pneumonia: Acute Hypoxic Hepatitis And Renal Failure Triggered By Hypoxemia

Julide Gurbuz[1], Omer Faruk Cakiroglu[2], Bahadir Taslidere[1], Basar Cander[1]

[1]Bezmialem Vakif University, Department of Emergency Medicine, Istanbul, Turkey
[2]Dr Lütfi Kırdar Kartal Training and Research Hospital, Department of Emergency Medicine, Istanbul, Turkey

Omer Faruk Cakiroglu / Dr Lütfi Kırdar Kartal Training and Research Hospital, Department of Emergency Medicine, Istanbul, Turkey

Introduction and Purpose: Hypoxic hepatitis (HH), traditionally known as "shock liver," is characterized by a rapid and massive increase in serum liver enzymes, particularly aspartate aminotransferase (AST), due to an imbalance between hepatic oxygen supply and demand. While usually associated with circulatory collapse or septic shock, isolated respiratory failure is a rare etiology. This case aims to highlight the development of HH secondary to severe pneumonia-related hypoxemia without overt systemic shock.

Materials and Methods: Case: A female patient in her early 70s presented to the Emergency Department (ED) with weakness and abdominal pain. Physical examination revealed a blood pressure of 110/70 mmHg and bilateral rhonchi. Laboratory tests showed significantly elevated liver enzymes: AST 4864 U/L, alanine aminotransferase (ALT) 3093 U/L, and lactate dehydrogenase (LDH) 4395 U/L. Computed Tomography (CT) of the thorax confirmed patchy pneumonic infiltration. Viral serologies and acetaminophen toxicity were excluded.

Table 1: Daily Follow-up of Laboratory Values

Test*	28/02	01/03	02/03	03/03	04/03	05/03	07/03	08/03	10/03
Urea (mg/dL)	73	114	166	183	216	252	233	202	117
Creatinine (mg/dL)	1,59	2,26	2,90	3,67	4,50	5,65	4,96	4,45	2,16
eGFR	41	21	15	12	9	8	8	14	22
AST (U/L)	4864	4097	968	251	64	104	-	23	-
ALT (U/L)	3093	2522	1429	889	507	309	-	103	-
White Blood Cell (WBC)	15,47	10,52	15,21	16,05	16,76	14,57	-	10,93	9,68
Haemoglobin (HGB)	13,4	9,1	10,3	11,0	10,3	9,2	-	9,0	9,2
Platelet (PLT)	294	244	256	266	309	252	-	184	200
CRP (mg/L)	351,4	279,4	156,8	78,2	55,8	36,1	-	27,9	-
Sodium (mmol/L)	144	139	133	133	137	138	142	146	148
Potassium (mmol/L)	5,97	4,59	3,62	3,78	3,72	3,80	3,61	3,64	3,59
Glucose (mg/dL)	136	-	-	161	-	104	-	112	86
Anti-Smooth Muscle Antibody (ASMA)	NEGATİF Titre								
Liver-Kidney Microsomal Antibody (IFA)	NEGATİF Titre								

*(For parameters measured multiple times a day, only the highest value is included in the table. Dates are presented in short format (DD/MM))

Materials and Methods: Results and Conclusion: The patient was admitted to the intensive care unit (ICU) for pneumonia and secondary acute kidney injury (AKI). Under non-invasive mechanical ventilation (NIMV) support, oxygenation was optimized. Echocardiography (EKO) showed a normal ejection fraction (EF) of 60%. Following treatment, liver enzymes regressed by over 50% within 72 hours, consistent with the characteristic recovery of HH. The patient was successfully discharged after clinical stabilization. In conclusion, clinicians should consider HH in patients with severe pneumonia and unexplained transaminase elevation, even in the absence of circulatory failure. This awareness is vital to avoid unnecessary invasive procedures and ensure appropriate management.

Keywords: Hypoxic hepatitis, Pneumonia, Acute kidney injury

Ref No: 8713

Acute Pancreatitis

Yunus Emre Ek[1], Ayça ÇALBAY[1]
[1]ATATÜRK ÜNİVERSİTESİ.

Yunus Emre Ek / ATATÜRK ÜNİVERSİTESİ.

Introduction and Purpose: In 80–90% of cases of acute pancreatitis, the two principal etiological factors are gallstones and excessive alcohol consumption. The majority of chronic pancreatitis cases are attributable to alcohol dependence. Gallstone-induced pancreatitis is more frequently observed in women aged 50 years and older. Approximately 10–20% of pancreatitis cases arise from other etiologies, including exposure to certain chemicals, hereditary disorders, medications, pancreatic or intestinal abnormalities, and hyperlipidemia.

Materials and Methods: An 82-year-old female patient presented to our department with the complaint of abdominal pain. On admission, her vital signs were stable. Physical examination revealed diffuse abdominal tenderness, while the examination of other systems was unremarkable. Laboratory investigations, including a complete blood count and biochemical tests, were ordered. Laboratory results showed amylase of 1500 U/L and lipase of 2100 U/L. With a preliminary diagnosis of acute pancreatitis, an abdominal computed tomography (CT) scan was performed. Imaging revealed a 60 mm infrarenal abdominal aortic aneurysm causing compression of the head of the pancreas. The patient was subsequently admitted to the cardiovascular surgery department.

CT



Materials and Methods: In patients presenting with abdominal pain, abdominal aortic aneurysm should be considered among the important emergency diagnoses. Additionally, pancreatitis secondary to compressive effects should also be taken into account.

Keywords: acute pancreatitis, abdominal aortic aneurysm

Ref No: 8719

Forgetfulness lasting 10 days: Brain tumour

Duygu Aras Seyit[1], Murat Seyit[2]
[1]ERPA Saglik Hospital, Denizli
[2]Pamukkale University Faculty of Medicine
Murat Seyit / Pamukkale University Faculty of Medicine

Introduction and Purpose: Brain tumours may present with acute-onset symptoms, or with subacute-onset, non-specific findings. In cases presenting with persistent headaches, slowly developing unilateral muscle weakness, epileptic seizures, new-onset and progressively worsening memory loss, or impaired cognition, it is essential to consider the possibility of space-occupying lesions in the brain. The case described here involves a patient who has experienced forgetfulness for the past 10 days, along with prolonged response times and impaired cognition, and in whom a tumour was detected on brain MRI.

Materials and Methods: A 74-year-old male patient with a history of coronary bypass surgery and diabetes mellitus presented with complaints of forgetfulness, which had been noticed by his relatives 10 days prior. The patient also reported difficulty finding words, and his neurological examination revealed prolonged response times. There was no evidence of muscle weakness. With normal blood tests and a contrast-enhanced brain MRI revealing a space-occupying lesion, the patient was referred to neurosurgery for surgery.

MRI

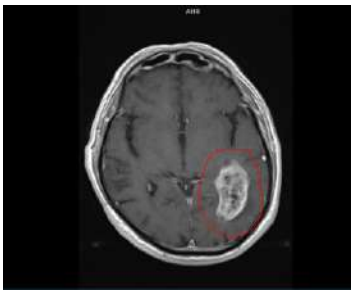

Materials and Methods: Brain tumours constitute a group of conditions that are relatively rare in clinical practice. Whilst some may be benign, others can be highly aggressive. Clinical symptoms vary considerably and can encompass a wide range of manifestations, including headache, nausea and vomiting, visual disturbances, epileptic seizures, memory loss, weakness in the arms and legs, and loss of balance. Surgery is usually required for treatment. Brain tumours must always be considered in cases where symptoms present acutely or subacutely.

Keywords: Brain tumour

Ref No: 8833

Approach to Acute Coronary Syndrome

Yasin Bülbüloğlu[1]

[1]SANLIURFA BALIKLIGOL STATE HOSPITAL

Yasin Bülbüloğlu / SANLIURFA BALIKLIGOL STATE HOSPITAL

Introduction and Purpose: Emergency management of a penetrating injury. A 40-year-old male patient with no known comorbidities or prior surgical history was brought to the emergency department by ambulance (EMS) following a penetrating injury to his right foot. The patient reportedly kicked a modem at home during an argument with his son, and the modem's antenna rod transfixed (pierced through) his foot.

Materials and Methods: •Vital Signs: Blood Pressure: 128/75 mmHg, Heart Rate: 73 bpm, Respiratory Rate: 23 breaths/min, Temperature: 36.5°C, SpO_2: 95%.•Physical Examination: The antenna rod is present in the right foot. Distal circulation in the toes is intact (natural). No sensory loss was noted. There is a localized limitation of extension in the 3rd digit (toe).•Imaging: Direct radiography (X-ray) revealed no bone damage (fracture). The antenna rod was visualized in situ.

Initial presentation of the foot:



Foot X-ray 1



Foot X-ray 2



Foot after foreign body removal



Results and Conclusion: A partial injury to the extensor tendon was identified, and an orthopedic consultation was requested. The orthopedic surgeon removed the antenna rod and performed primary suturing of the wound site to achieve hemostatic stabilization (bleeding control). Admission to the orthopedic department was recommended for definitive tendon repair. However, the patient refused the hospitalization and departed from the emergency department after signing a Refusal of Treatment (AMA - Against Medical Advice) form.

Keywords: Extension, Tendon, Penetrating

Ref No: 8836

Post-Cardiac Injury Syndrome

Sabri Furkan Bulca[1], Murat Seyit[1], Mert Özen[1], Alten Oskay[1], Atakan Yılmaz[1], İbrahim Türkçüer[1]
[1]Pamukkale University Faculty of Medicine
Murat Seyit / Pamukkale University Faculty of Medicine

Introduction and Purpose: Post-cardiac injury syndrome (PCIS) is an immune-mediated inflammatory condition that develops after myocardial or pericardial injury and may occur following cardiac surgery, myocardial infarction, or trauma. It typically presents with pleuritic/retrosternal chest pain, dyspnea, and fever, and may be accompanied by pericarditis findings and pericardial and/or pleural effusion. In patients presenting with chest pain and fever after cardiac surgery, PCIS should be considered in the differential diagnosis alongside other life-threatening conditions.

Materials and Methods: A 61-year-old man presented to the emergency department with a 1-day history of fever, chills/rigors, abdominal pain, and stabbing retrosternal chest pain. His medical history included obesity, diabetes mellitus, and coronary artery disease. Approximately three months earlier, he had undergone aortic valve replacement and coronary artery bypass grafting. On admission, vital signs were: blood pressure 120/70 mmHg, heart rate 92/min, respiratory rate 18/min, temperature 37.7°C, and SpO_2 96%. Physical examination revealed normal breath sounds, mild tenderness in the upper abdominal quadrants, and no cardiac murmurs on auscultation. The patient underwent electrocardiography, chest CT, chest and abdominal CT, and transthoracic echocardiography. Acute coronary syndrome (ACS), pulmonary embolism (PE), pneumonia, and heart failure were excluded in the differential diagnosis. With echocardiographic findings consistent with pericarditis, and based on clinical presentation and recent surgical history, PCIS was suspected and the patient was admitted to the cardiology ward.

Materials and Methods: PCIS is a clinical entity that can present with fever and chest pain in the postoperative period and may follow a course characterized by pericarditis/pleuritis and effusions. A high index of clinical suspicion is essential, and potentially life-threatening conditions—particularly ACS, PE, pneumonia, and decompensated heart failure—must be carefully ruled out. Treatment includes nonsteroidal anti-inflammatory drugs (NSAIDs), colchicine, and corticosteroids when necessary; pericardiocentesis is indicated if cardiac tamponade develops. PCIS should be kept in mind when chest pain and fever occur after cardiac surgery, and appropriate anti-inflammatory therapy should be initiated without delay.

Keywords: Post-cardiac injury syndrome, Dressler syndrome, pericarditis.

Ref No: 8919

TRAPPED AIR, RISING DANGER

Nisa Mındız[1], İBRAHİM ÖZLÜ[1], MERVE BULUT[1]

[1]ATATÜRK UNIVERSITY EMERGENCY DEPARTMENT

Nisa Mındız / ATATÜRK UNIVERSITY EMERGENCY DEPARTMENT

Introduction and Purpose: Pneumocephalus is a clinical condition characterized by the presence of air within the intracranial cavity. It most commonly occurs following head trauma and neurosurgical interventions. Although many cases remain asymptomatic, it can lead to life-threatening complications, particularly when tension pneumocephalus develops. Early diagnosis and appropriate management in the emergency department are crucial to reducing morbidity and mortality.

Materials and Methods: A 21-year-old male patient was brought to the emergency department following an in-vehicle traffic accident.On admission, the patient's Glasgow Coma Scale (GCS) score was 6. Vital signs revealed a pulse rate of 105 beats/min and a blood pressure of 97/61 mmHg.On physical examination, the pupils were mid-dilated and reactive to light bilaterally (IR: ++/++). There was left periorbital edema and hyperemia, along with multiple dermabrasions on various parts of the face.Due to the low GCS score, the patient was intubated. Cranial computed tomography (CT) imaging was performed for diagnostic evaluation. Imaging findings revealed a skull base fracture, pneumocephalus, nasal bone fracture, and bilateral orbital fractures.The patient was consulted with the neurosurgery department and admitted for further monitoring and management.

PHOTO 1

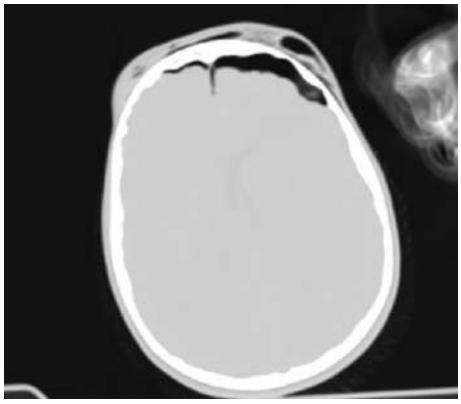

Materials and Methods: Pneumocephalus most commonly develops secondary to traumatic causes and is closely associated with skull base fractures. Following trauma, a communication between the intracranial cavity and the external environment allows air to enter the cranial space.While most cases of pneumocephalus can be managed conservatively, some patients may develop tension pneumocephalus, which can lead to increased intracranial pressure and neurological deterioration. This condition requires urgent intervention.Computed tomography is the gold standard imaging modality for the diagnosis of pneumocephalus and can detect even small amounts of intracranial air with high sensitivity. Therefore, early CT evaluation is essential in patients with head trauma.

Keywords: Pneumocephalus, head trauma, skull base fracture

Ref No: 8940

Rupture Hemorrhagic Ovarian Cyst

Hatice Simge Acun[1], Murat Seyit[1], Atakan Yılmaz[1], Mert Özen[1], Alten Oskay[1], İbrahim Türkçüer[1]

[1]Pamukkale University Faculty of Medicine

Murat Seyit / Pamukkale University Faculty of Medicine

Introduction and Purpose: Ovarian rupture is an acute gynecological emergency that may occur secondary to functional ovarian cysts and can lead to intra-abdominal bleeding and hemodynamic instability. It is most commonly seen in women of reproductive age and typically presents with sudden-onset lower abdominal pain. Although many cases are self-limiting, delayed diagnosis may result in significant hemoperitoneum requiring urgent surgical intervention. This case report aims to present a 30-year-old female patient diagnosed with ovarian rupture, emphasizing the importance of early clinical suspicion, prompt imaging, and timely management to prevent potentially life-threatening complications.

Materials and Methods: A 30-year-old female (G1P1) with no significant past medical history presented to the emergency department with sudden-onset right lower quadrant abdominal pain that began several hours prior to admission. The pain was sharp in character, progressively worsening, and associated with nausea, without vomiting or fever. She reported regular menstrual cycles and denied recent trauma. There was no suspicion of current pregnancy. On admission, vital signs were blood pressure 100/65 mmHg, heart rate 108 beats/min, oxygen saturation 99% on room air, and body temperature 36.6°C. Physical examination revealed

tenderness and mild guarding in the right lower quadrant. Laboratory analysis demonstrated hemoglobin of 11.2 g/dL, mild leukocytosis (white blood cell count 12,400/mm³), and a negative serum β-human chorionic gonadotropin (β-hCG) level. Transvaginal ultrasonography revealed free fluid in the pelvis and a collapsed cystic lesion in the right ovary, suggestive of ovarian rupture. Due to ongoing abdominal pain and decreasing hemoglobin levels on serial measurements, the patient was closely monitored and intravenous fluid resuscitation was initiated. Contrast-enhanced abdominal computed tomography confirmed moderate hemoperitoneum and findings consistent with a ruptured right ovarian cyst. After consultation with the gynecology department, the patient underwent emergency laparoscopic intervention. Intraoperative findings revealed active bleeding from a ruptured ovarian cyst, which was successfully controlled. The patient showed clinical improvement postoperatively and was discharged in stable condition.

Transvaginal ultrasonography



CT Scan



Materials and Methods: This case highlights that ovarian rupture should be considered in reproductive-age women presenting with acute lower abdominal pain, and that early imaging and timely surgical management are crucial in preventing serious complications related to intra-abdominal bleeding.

Keywords: Ovarian rupture, Hemoperitoneum, Acute abdomen

Ref No: 8951

The Great Impersonator: A Young Woman's Diagnostic Shift from Stroke to Multiple Sclerosis

Kevser Yıldırım[1], Murat Seyit[1], Duygu Aras Seyit[2], Mert Özen[1], Alten Oskay[1]

[1]Pamukkale University Faculty of Medicine
[2]ERPA Saglik Hospital, Denizli

Murat Seyit / Pamukkale University Faculty of Medicine

Introduction and Purpose: A 25-year-old female presented to the emergency department with a sudden onset of left-sided arm weakness that had developed over the course of several hours. Due to the acute nature of the focal neurological deficit, a cerebrovascular accident (CVA) was immediately suspected. Emergency stroke protocols were initiated to rule out ischemic or hemorrhagic events in a young adult.

Materials and Methods: Upon admission, the patient's vital signs were stable: blood pressure 115/75 mmHg, heart rate 72 bpm, respiratory rate 14/min, and temperature 36.7°C. Physical examination confirmed 4/5 motor strength in the left upper extremity. Notably, the examination also revealed hyperreflexia in the affected limb and a positive Babinski sign on the left side, which pointed toward an upper motor neuron lesion. Initial laboratory tests, including coagulation profiles and complete blood count, were unremarkable. A non-contrast cranial CT scan showed no evidence of acute infarction or intracranial hemorrhage. Given the discrepancy between the patient's age and the clinical suspicion of a stroke, an urgent brain MRI was performed. The MRI revealed several high-signal periventricular and juxtacortical lesions on T2-weighted and FLAIR sequences, some of which showed gadolinium enhancement.

Materials and Methods: The presence of demyelinating lesions dispersed in space and time led to a diagnostic shift from a vascular event to Multiple Sclerosis (MS). The patient was subsequently admitted to the neurology department for high-dose pulse steroid therapy and

further diagnostic investigations, including cerebrospinal fluid analysis. This case serves as a critical reminder that in young patients, focal neurological deficits can mimic stroke, and Multiple Sclerosis should be considered early in the differential diagnosis to ensure timely and appropriate specialized care.

Keywords: Multiple Sclerosis, Stroke Mimic, Demyelinating Disease.

Ref No: 8985

SILENT COLLAPSE: FULMINANT HEPATITIS

Erdal Tekin[1], Hakan Alp[1], Erdem Zeki Karabulut[1]

[1]Erzurum Atatürk Üniversitesi Araştırma Hastanesi

Hakan Alp / Erzurum Atatürk Üniversitesi Araştırma Hastanesi

Introduction and Purpose: Fulminant hepatitis is a severe clinical condition characterized by the sudden and rapid development of severe liver failure. It usually manifests within days or weeks and leads to severe loss of liver function along with consciousness changes (encephalopathy).

Materials and Methods: A 55-year-old male patient presented with complaints of abdominal pain, stomach pain, and nausea that started today. The patient was recently diagnosed with non-small cell lung cancer, but treatment has not yet been initiated. The patient does not report diarrhea or constipation. When the medical history was deepened, it was learned that the patient recently consumed an herb, the identity of which he did not know. In the patient's admission vitals, there were no remarkable findings other than a pulse of 110. The patient's ECG showed no findings except for sinus tachycardia. Abdominal examination revealed tenderness in the epigastric region and upper quadrants; defense and rebound were negative. Murphy's sign was negative. Bilateral costovertebral angle tenderness was negative. There were no specific findings in the patient's X-rays. In the laboratory tests: ALT: 2180, AST: 941, GGT: 218, ALP: 142, LDH: 1798, GLUCOSE: 410, NA: 120, CL: 87, CRP: 207, INR: 1.62, and a metabolic acidosis was present with a pH: 7.31 in the blood gas. Supportive treatment was initiated for the patient. During follow-up, the patient's state of consciousness began to decline. Hepatobiliary USG showed a slight increase in gallbladder wall thickness and mild edema in the gallbladder bed (acute cholecystitis?); Portal Venous Doppler USG showed flow encoded in segmentary branches of the portal vein, but flow could not be encoded at the level of the hilum and

confluence (portal vein thrombus?). The patient was admitted to the Gastroenterology clinic with a diagnosis of Fulminant Hepatitis.

Results and Conclusion: In patients presenting with abdominal pain, questioning the history of using a different medication or consuming a different herb or mixture is crucial for the early detection of a diagnosis of fulminant hepatitis, which can be rapidly progressive and fatal.

Keywords: Abdominal pain, Fulminant hepatitis, Nausea and Vomiting

---

Ref No: 9044

Attitudes of emergency healthcare workers on electric vehicle accidents

Uğur KAYHAN[1], Zafer LİMAN[2], Şerife ÖZDİNÇ[3], İbrahim KILIÇ[4], Cengiz DURMUŞ[5]

[1]Faculty of Medicine, Department of Forensic Medicine, Afyonkarahisar Health Sciences University, Afyonkarahisar, Turkey
[2]Faculty of Medicine, Department of Forensic Medicine, Karabuk University, Karabuk, Turkey
[3]Faculty of Medicine, Department of Emergency Medicine, Afyonkarahisar Health Sciences University, Afyonkarahisar, Turkey
[4]Faculty of Veterinary Medicine, Department of Biostatistics, Afyon Kocatepe University, Afyonkarahisar, Turkey
[5]Ambulance Service, Konya Provincial Directorate of Health, Konya, Turkey

Şerife ÖZDİNÇ / Faculty of Medicine, Department of Emergency Medicine, Afyonkarahisar Health Sciences University, Afyonkarahisar, Turkey

Introduction and Purpose: This study aimed to determine the cognitive, affective, and behavioral attitudes of healthcare professionals involved in the initial intervention, treatment, and reporting of electric vehicle accidents (EVAs) and to compare these attitudes on the basis of their individual characteristics.

Materials and Methods: A descriptive cross-sectional design was used. The sample consisted of 402 healthcare professionals in Türkiye. Data were collected through a questionnaire that included demographic questions and the Electric Vehicle Accident Attitude Scale, a 27-item instrument newly developed by Kayhan et al. Attitudes were measured in cognitive, emotional, and behavioral dimensions. Descriptive statistics (frequency, percentage, mean, and standard deviation) were used along with t-tests, ANOVA, and MANOVA to compare attitudes according

to personal and professional variables. Cluster analysis was used to group participants according to their attitudes towards EVA.

Results and Conclusion: Results: The participants demonstrated moderate overall attitudes toward EVAs. While cognitive and affective attitudes were low, behavioral attitudes were relatively high. No significant differences were found profession, marital status, age, or years of experience ($p > 0.05$); however, attitudes varied significantly by work unit and gender ($p < 0.05$). Compared with dispatch and emergency department staff, ambulance teams had more favorable behavioral ($M = 3.77$) and overall ($M = 3.15$) attitudes. Conclusions: EVAs pose unique risks due to their battery structure and limited control, distinguishing them from conventional vehicle incidents. Knowledge gaps and emotional hesitation among healthcare workers highlight the need for targeted training programs that extend beyond healthcare providers to include other frontline responders, such as firefighters and traffic police. In addition, forensic specialists involved in injury assessment and cause-ofdeath determination should receive EVA-specific awareness training to enhance their preparedness for such cases. Furthermore, the implementation of structured EVA, specific training programs, shaped by the attitudes identified in this study, may not only improve the quality of emergency care but also serve a preventive function in potential future legal risks related to patient care.

Keywords: Electric vehicle accidents, Attitude scale, Healthcare workers

---

Ref No: 9055

Altered mental status

Merve Bulut[1], Ekrem Bulut[1], Mevlana Gül[1]

[1]Atatürk University Faculty of Medicine

Merve Bulut / Atatürk University Faculty of Medicine

Introduction and Purpose: Altered mental status is a high-risk presentation in the emergency department, often indicating severe underlying pathology. Brainstem hemorrhages, particularly pontine hemorrhage, are associated with poor prognosis and rapid neurological deterioration. Concurrent life-threatening arrhythmias such as ventricular tachycardia (VT) further complicate management and require immediate intervention.

Materials and Methods: A 50-year-old female was brought to the emergency department with complaints of general deterioration and acute onset decreased level of consciousness.On arrival,

the patient was unresponsive with a Glasgow Coma Scale (GCS) score of 7 (E2V2M3). Vital signs revealed hypotension and tachycardia. Continuous cardiac monitoring showed monomorphic ventricular tachycardia.Due to hemodynamic instability, synchronized cardioversion was performed, resulting in restoration of sinus rhythm. Following stabilization, further evaluation of the altered mental status was pursued.Neurological examination revealed no purposeful response to stimuli, and brainstem reflexes were diminished.A non-contrast brain computed tomography (CT) scan demonstrated a hyperdense hemorrhagic lesion localized in the pons, consistent with acute pontine hemorrhage.The patient was intubated for airway protection and admitted to the intensive care unit. Neurology and neurosurgery consultations were obtained, and supportive management was initiated.

Materials and Methods: This case emphasizes the need for simultaneous and systematic evaluation of critically ill patients in the emergency department. The coexistence of ventricular tachycardia and pontine hemorrhage represents a rare but life-threatening scenario. Prompt recognition, early resuscitation, and multidisciplinary management are essential to improve patient outcomes.

Keywords: Altered mental status, pontine hemorrhage, ventricular tachycardia

---

Ref No: 9109

Pregnant Patients Presenting to the Emergency Department with Flank Pain Should Be Evaluated for Hydronephrosis Using Bedside Ultrasonography

Fırat Okta[1], Murat Seyit[1], Mert Özen[1], Alten Oskay[1], Atakan Yılmaz[1], İbrahim Türkçüer[1]

[1]Pamukkale University Faculty of Medicine

Murat Seyit / Pamukkale University Faculty of Medicine

Introduction and Purpose: Hydronephrosis in pregnancy is a phenomenon known for 200 years and is considered physiological in asymptomatic patients. The physiological and anatomical changes that occur during pregnancy to support fetal growth and prepare the mother for delivery also affect the ureters and bladder. This involvement leads to asymptomatic hydronephrosis in approximately 90% of pregnant women. Symptomatic hydronephrosis is observed in 3% of pregnant women. When accompanied by infection, symptomatic hydronephrosis increases the risk of preterm delivery, fetal loss, and cesarean section. Pregnant patients with symptomatic hydronephrosis most commonly present to emergency departments, and management is complex, requiring a multidisciplinary approach.

Materials and Methods: A 21-year-old woman at 27 weeks' gestation presented to the emergency department with low back and right flank pain. She had no known chronic disease. Her obstetric history was gravida 4, para 2, abortus 1. She had a history of urinary tract infection but no history of urinary calculi.On physical examination, tenderness was detected in the suprapubic region, right lower quadrant, and right costovertebral angle. The patient's vital signs are presented in Table 1, and laboratory findings in Table 2. Bedside ultrasonography demonstrated dilatation of the right renal pelvicalyceal system. Formal ultrasonographic evaluation reported "dilatation of the right pelvicalyceal system and blunting of the calyceal structures (grade 2–3hydroureteronephrosis), right renal pelvis anteroposterior diameter 17 mm, dilatation in the proximal ureteral segment, no definite calculus detected."In the emergency department, 2×500mg paracetamol, 1×10mg metoclopramide, and intravenous hydration at 100cc/hour were administered. The patient was consulted to the urology department and admitted with a plan for stent placement due to hydronephrosis. However, as her pain regressed the following day, she left the hospital after signing a treatment refusal form of her own volition.Presentation of pregnant women to the emergency department with flank pain is common and is most frequently related to hydronephrosis. Management of symptomatic hydronephrosis is challenging from both obstetric and urological perspectives due to pregnancy-related limitations in intervention and potential complications.

Bedside Ultrasonography (US) of the Patient

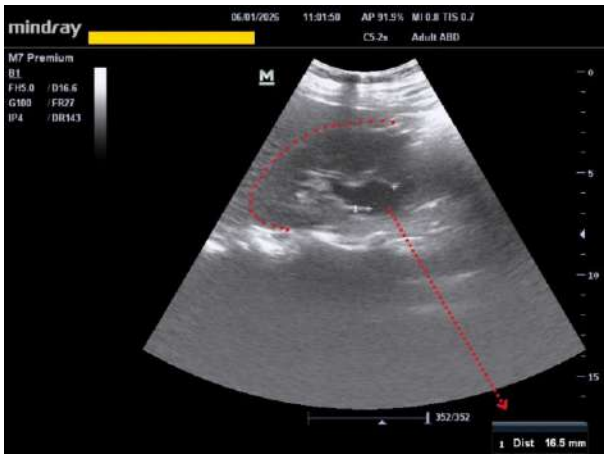

Table 1. Patient Vital Signs

Blood Pressure	Heart Rate	Temperature	Oxygen Saturation	Respiratory Rate
115/70 mmHg	110 beats/min	36,1 °C	100 %	16 breaths/min

Table 2. Patient Laboratory Findings

Complete Blood Count (CBC)						
	WBC	NEU	LYM	HGB	HCT	PLT
	12.36 K/µL	79.3%	14.9%	10.4 g/dL	29.8%	129 × 10³/µL
Fully Automated Urinalysis						
	Nitrite	Urine leukocytes	Urine-HGB	Microscopic erythrocyte count	Microscopic leukocyte count	Microscopic bacteria
	Positive	+++	+++	116	842	Abundant
Biochemistry						
	Glucose	Creatinine	BUN	Total bilirubin	CRP	β-hCG
	85 mg/dL	0.46 mg/dL	5 mg/dL	0,4 mg/dL	16,84 mg/L	14,632 IU/L

Materials and Methods: In pregnant patients presenting with flank pain to the emergency department, symptomatic hydronephrosis should be considered, and routine use of USG should be adopted to expedite diagnosis.

Keywords: Pregnancy, Hydronephrosis, Ultrasonography

Ref No: 9120

Hyperkalemia-Induced Refractory Bradycardia Requiring External Pacing In A Hemodialysis Patient

Sarah SABBAGH SHARIF[1], Bahadır TAŞLIDERE[1], Başar CANDER[1]

[1]Bezmialem university hospital

Sarah SABBAGH SHARIF / Bezmialem university hospital

Introduction and Purpose: Hyperkalemia is a potentially fatal electrolyte disturbance frequently encountered in emergency departments, particularly in patients with end-stage renal disease (ESRD). Although it is classically associated with peaked T waves and QRS widening, it may also present with less typical findings such as severe bradyarrhythmia. We present a case of hyperkalemia manifesting with profound refractory bradycardia requiring advanced management.

Materials and Methods: A 41-year-old male with a history of familial Mediterranean fever (FMF)-associated AA amyloidosis and ESRD on regular hemodialysis was brought to the emergency department due to general deterioration. On arrival, he was hypotensive and had marked bradycardia (heart rate: 28/min). Electrocardiography showed significant bradycardia with intermittent pauses. Laboratory findings revealed severe hyperkalemia (potassium: 8.62 mmol/L) and elevated creatinine (7.92 mg/dL). Arterial blood gas analysis confirmed hyperkalemia with associated metabolic acidosis.

Materials and Methods: Initial management included atropine, intravenous calcium gluconate, insulin with dextrose, and inhaled beta-agonists. As the bradycardia persisted and the patient remained hemodynamically unstable, transcutaneous pacing was initiated as a temporizing measure. Urgent hemodialysis was subsequently performed, leading to a rapid decrease in potassium levels (to 5.39 mmol/L) and clinical improvement, with restoration of sinus rhythm and hemodynamic stability. This case highlights that hyperkalemia may present with severe bradycardia, conduction disturbances, and hemodynamic instability which can rapidly progress to life-threatening complications. Early recognition and prompt treatment are essential. While pacing may be required in unstable patients, definitive management depends on rapid potassium correction, particularly through dialysis in ESRD patients.

Keywords: Hyperkalemia, Transcutaneous pacing, Bradycardia

Ref No: 9132

THE STONE OBSTRUCTING THE DUCT

yusuf burak eker[1], sultan tuna akgöl gür[1], erhan şahin[1]

[1]Atatürk üniversitesi tıp fakültesi acil tıp anabilim dalı

yusuf burak eker / Atatürk üniversitesi tıp fakültesi acil tıp anabilim dalı

Introduction and Purpose: Acute, unifocal salivary gland swelling is most commonly caused by obstruction, with sialolithiasis (salivary stones) frequently cited as the primary etiology. Ductal strictures, occurring either independently or in conjunction with stones, are also frequent causes of obstruction. Other common causes of acute unifocal swelling include bacterial infection and inflammation following external beam radiation. The underlying cause—whether obstruction, bacterial infection, or post-radiation effects—can generally be determined through clinical history and physical examination. Treatment strategies vary significantly depending on the identified cause.

Materials and Methods: A 32-year-old male presented to our emergency department with a several-day history of left-sided cheek pain, which intensified particularly after meals (postprandial), and swelling that had developed over the last 24 hours. No accompanying fever, chills, rigors, diaphoresis, or sore throat were reported. The patient had no known comorbidities or regular medication use, and his vital signs were within normal limits.Physical examination revealed tenderness over the left parotid gland. Detailed clinical history indicated that these symptoms recurred periodically and were occasionally accompanied by fever, halitosis, and intraoral discharge near the left cheek area. While the initial differential diagnoses included parotid abscess or stricture, a computed tomography (CT) scan was performed, which identified a stone in the left Stensen's duct.

figure

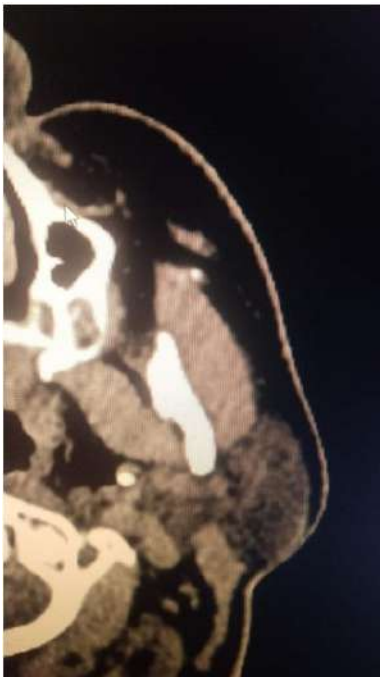

Materials and Methods: Since suppurative parotitis can spread to the deep fascial spaces of the head and neck and may become life-threatening, initial management often requires inpatient treatment. However, in cases like ours, where the sialadenitis is not complicated by an abscess, management with non-steroidal anti-inflammatory drugs (NSAIDs) and outpatient follow-up is appropriate. It is of critical importance in emergency departments to educate the patient regarding the clinical progression and the warning signs of potential abscess formation.

Keywords: Sialolithiasis, Stensen's duct, Parotitis

Ref No: 9212

Extensive intracranial hemorrhage and brain death following intravenous alteplase therapy: A case report

Türkan Yıldız[1], Gizem Çakan[1]

[1]Niğde Ömer Halisdemir University Training and Research Hospital, Department of Emergency Medicine

Türkan Yıldız / Niğde Ömer Halisdemir University Training and Research Hospital, Department of Emergency Medicine

Introduction and Purpose: Intravenous alteplase (rt-PA) remains the gold standard reperfusion therapy for acute ischemic stroke within the therapeutic window. However, symptomatic intracranial hemorrhage (sICH) is the most catastrophic complication of this treatment. This report aims to present a rare and dramatic case of extensive multi-compartmental hemorrhage and subsequent brain death occurring during alteplase infusion.

acute ischemic infarction

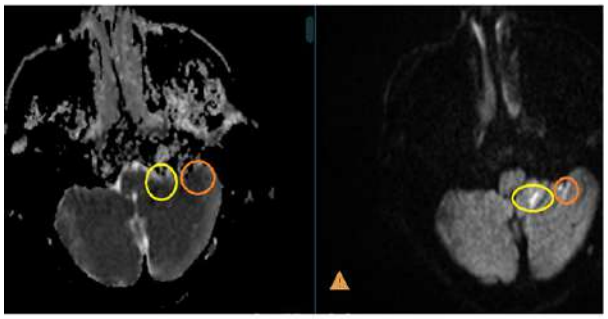

acute hemorrhage

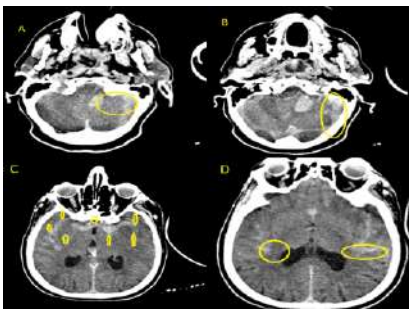

Materials and Methods: A patient diagnosed with acute ischemic stroke was treated with the standard dose of 0.9 mg/kg intravenous alteplase. Clinical monitoring was performed throughout the infusion. Following a sudden neurological decline, emergent cranial computed tomography (CT) was performed, and the patient's clinical progression was followed in the intensive care unit (ICU).

Results and Conclusion: During the alteplase infusion, the patient experienced sudden respiratory arrest and neurological deterioration. Cranial CT revealed extensive intracranial hemorrhage, including posterior fossa intraparenchymal hemorrhage, subarachnoid hemorrhage, and intraventricular hemorrhage. Although spontaneous circulation was restored via cardiopulmonary resuscitation, the patient's neurological status progressed to an irreversible state. The patient was subsequently diagnosed with brain death in the ICU. This case underscores that dramatic clinical progression is possible, especially with posterior circulation involvement, and highlights the vital importance of immediate clinical evaluation at the first sign of deterioration during thrombolytic therapy.

Keywords: Acute ischemic stroke, Alteplase, Symptomatic intracranial hemorrhage

---

Ref No: 9262

Acute cerebellar infarction masked by hypothermia in a 95-year-old Alzheimer's patient: a case report

Mustafa Selçuk Solak[1], Abidin Baran[1], Hakkı Yüce[1], Mine Kayacı Yıldız[1], Mehmet Gül[1]
[1]Emergency Medicine Department, Konya City Hospital, Türkiye

Mine Kayacı Yıldız / Emergency Medicine Department, Konya City Hospital, Türkiye

Introduction and Purpose: : In the geriatric population, acute stroke symptoms can be masked by dementia and accompanying metabolic conditions. This report presents the diagnostic process of an acute cerebellar infarction identified in a 95-year-old patient who was found alone at home and brought to the emergency department (ED) with profound hypothermia.

Materials and Methods: A 95-year-old female patient with a known history of Alzheimer's disease and hypertension was brought to our ED after being found unresponsive at home, where she had been alone for approximately 14 hours. Upon physical examination, the patient was hypothermic, bradycardic (heart rate: 39/min), and hypertensive (blood pressure: 182/121 mmHg), with no response to verbal stimuli. An electrocardiogram (ECG) revealed atrial fibrillation (AF) with a slow ventricular response. Laboratory tests showed elevated troponin T

(36.6 ng/L) and glucose (217 mg/dL) levels. While the cranial computed tomography (CT) showed no acute pathology, the diffusion-weighted magnetic resonance imaging (MRI) identified millimetric acute diffusion restriction (acute infarction) in the cerebellar hemisphere and a punctate lesion in the left occipital lobe.

Materials and Methods: Results and Conclusion: Following consultations with neurology and cardiology, the patient was admitted for appropriate treatment and monitoring. In very elderly patients presenting with hypothermia, bradycardia, and altered consciousness, the clinical picture should not be attributed solely to environmental factors. The presence of AF significantly increases the risk of cerebral infarction, even if the lesions are millimetric in size. In cases where the neurological examination is limited, as in this instance, diffusion MRI is the gold standard for detecting silent infarctions

Keywords: Geriatric stroke, hypothermia, cerebellar infarction

---

Ref No: 9276

Misleading Flu-Like Symptoms Revealing Carbon Monoxide Poisoning From A Faulty Natural-Gas Boiler: The Value Of Detailed Anamnesis

Ömer Babaoğlu[1], Murat Seyit[1], Atakan Yılmaz[1], Mert Özen[1], Alten Oskay[1], İbrahim Türkçüer[1]

[1]Pamukkale University Faculty of Medicine

Murat Seyit / Pamukkale University Faculty of Medicine

Introduction and Purpose: Carbon monoxide (CO) is a colorless and odorless gas produced by incomplete combustion and remains an important cause of accidental poisoning worldwide. Early symptoms such as headache, dizziness, nausea, and sore throat are nonspecific and often resemble viral infections, which may lead to delayed diagnosis.We present a case in which persistent and detailed anamnesis revealed a shared environmental exposure, leading to the diagnosis of carbon monoxide poisoning. This report highlights the critical role of thorough history-taking in patients presenting with vague flu-like symptoms.

Materials and Methods: A 45-year-old woman presented to the emergency department one hour after the onset of headache, dizziness, sore throat, and nausea. On admission, vital signs were blood pressure 141/74 mmHg, heart rate 117/min, respiratory rate 16/min, and temperature 36.2 °C. Physical examination and electrocardiography were unremarkable except for sinus tachycardia.Although initial evaluation did not suggest a clear infectious or toxic cause, further

detailed questioning revealed that her husband and son were experiencing similar symptoms. The family lived in a poorly ventilated apartment and used a natural-gas boiler that had recently been serviced by an unlicensed technician. Arterial blood gas analysis demonstrated a carboxyhemoglobin (CO-Hb) level of 8.9%.As the patient's CO-Hb level was below hyperbaric treatment thresholds, she was treated with normobaric 100% oxygen via a non-rebreather mask and intravenous fluids.

Materials and Methods: The patient's symptoms improved rapidly after oxygen therapy. CO-Hb levels decreased to 7.4% at one hour and to 3.1% at three hours. She was discharged after six hours of observation with stable vital signs and received counseling regarding proper ventilation, regular maintenance of gas appliances, and installation of carbon monoxide detectors.This case underscores the pivotal role of detailed anamnesis in patients presenting with nonspecific flu-like symptoms. Recognition of concurrent symptoms among household members was the key factor leading to suspicion of carbon monoxide poisoning and timely treatment. Emergency physicians should maintain a high index of suspicion and routinely explore environmental exposures, particularly when multiple occupants are affected.

Algorithm for Using Hyperbaric Oxygen

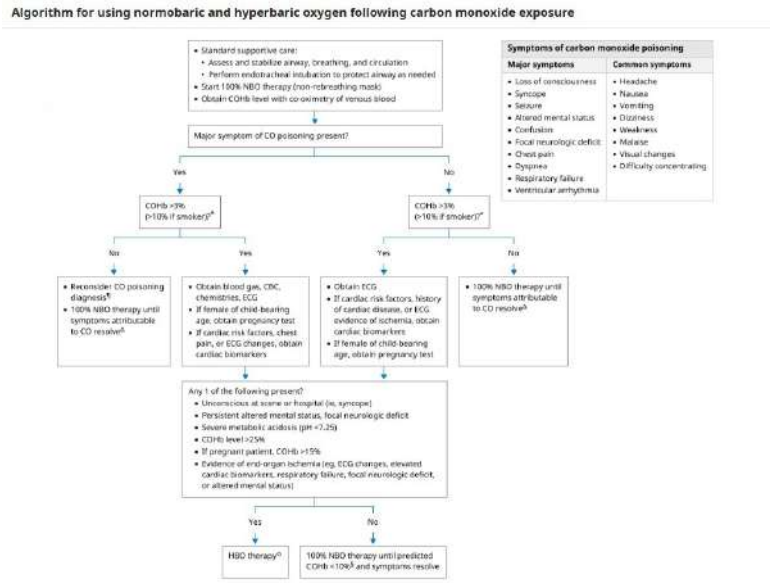

Keywords: Carbon monoxide poisoning, Flu-like symptoms, Detailed anamnesis

Ref No: 9292

Hematochezia, Shock, and a Hyperosmolar State in an Elderly Patient on Anticoagulation

Sabri Furkan Bulca[1], Murat Seyit[1], Mert Özen[1], Alten Oskay[1], Atakan Yılmaz[1], İbrahim Türkçüer[1]

[1]Pamukkale University Faculty of Medicine

Murat Seyit / Pamukkale University Faculty of Medicine

Introduction and Purpose: In elderly patients, anticoagulant use in combination with cardiovascular and metabolic comorbidities increases the risk of bleeding, organ dysfunction, and hemodynamic instability. In this population, shock etiology often cannot be attributed to a single cause; hemorrhagic/hypovolemic, septic, and cardiogenic components may coexist. Therefore, diagnostic evaluation and life-saving interventions should be performed in parallel.

Materials and Methods: An 84-year-old woman with a history of diabetes mellitus, atrial fibrillation (AF), and ischemic cerebrovascular disease presented to the emergency department with 4 days of bloody stools, vomiting, and 2 days of altered mental status. She had been taking rivaroxaban regularly. On arrival, vital signs were: blood pressure 80/50 mmHg, heart rate 176/min (consistent with AF with rapid ventricular response), respiratory rate 28/min, and SpO_2 94%. Neurological assessment revealed a Glasgow Coma Scale (GCS) score of 8. Point-of-care glucose measurement showed marked hyperglycemia. Due to impaired consciousness and risk of respiratory failure, the airway was secured with rapid sequence intubation (ketamine + rocuronium). A norepinephrine infusion was initiated for hypotension. Because of hemodynamically unstable AF with rapid ventricular response, synchronized cardioversion at 200 J was performed. Simultaneously, fluid resuscitation, proton pump inhibitor therapy, and central venous catheterization were carried out. Laboratory evaluation demonstrated hyperglycemia, hyponatremia, hypokalemia, uremia, and elevated inflammatory/infectious markers. The clinical and laboratory findings were considered consistent with anticoagulant-associated gastrointestinal bleeding, hyperosmolar hyperglycemic state, urosepsis, acute kidney injury, and consequent mixed septic and hypovolemic shock. Sepsis management was initiated. Renal replacement therapy was provided. The patient was transferred to the intensive care unit for ongoing organ support and monitoring.

Biochemical parameters

eGFR CKD-EPI	19	ml/dk	> 90		38 / 42
Glukoz	987	mg/dL	82	115	104 / 102
Numune iki Kere Çalışılmıştır.					
Üre	260	mg/dL	16.6	48.5	63 / 61
Kreatinin	2.32	mg/dL	0.66	0.99	1.29 / 1.19
BUN	121	mg/dL	8	23	29 / 29
Sodyum (Na)	108	mmol/L	136	145	137 / 135
Numune iki Kere Çalışılmıştır.					
Potasyum (K)	2.8	mmol/L	3.5	5.1	3.6 / 4.17
Klor (Cl)	63	mmol/L	98	107	90 / 99
Bilirubin (Total)	1.22	mg/dL	<= 1.2		0.93
Bilirubin (Direkt)	0.63	mg/dL	<= 0.3		0.23
Bilirubin (İndirekt)	0.59	mg/dL	<= 0.9		0.7
Total Protein	52.70	g/L	66	87	62.9 / 63.23
Albumin	31.88	g/L	35	52	38.4 / 38.4
AST (Aspartat Transaminaz)	38	U/L	< 32		39 / 97
ALT (Alanin Aminotransferaz)	19	U/L	< 33		89 / 111
ALP (Alkalen Fosfataz)	229	U/L	35	104	108
LDH (Laktik Dehidrogenaz)	392	U/L	135	214	419
GGT (Gamma Glutamil Transferaz)	16	U/L	6	42	32
Ürik Asit	13.5	mg/dL	2.4	5.7	8.6 / 8.5
Kalsiyum (Ca)	8.56	mg/dL	8.8	10.2	9.24 / 9.21
Magnezyum (Mg)	2.91	mg/dL	1.6	2.4	1.53 / 1.8
CRP	313.84	mg/L	< 5		24.36 / 7.8
Amilaz	1185	U/L	28	100	33
Lipaz	66.8	U/L	13	60	36.8
Düzeltilmiş Kalsiyum	9.21		8.8	10.2	9.37 / 9.34

Materials and Methods: Anticoagulant use in elderly, comorbid patients increases the risk of hemodynamic instability and mortality, particularly when accompanied by cardiovascular and metabolic disease. Clinicians should consider multifactorial shock and simultaneously evaluate potential infectious, cardiogenic, and hemorrhagic causes, alongside early airway control, vasopressor support, and a multidisciplinary approach. Monitoring goal-directed resuscitation with dynamic parameters may help determine prognosis in the early phase.

Keywords: Urosepsis, gastrointestinal bleeding, multifactorial shock

---

Ref No: 9316

SPONTANEOUS URETERAL RUPTURE IN THE ABSENCE OF TRAUMA: A RARE CASE REPORT:

Gamze Aykaç[1], Saliha Köse[1], Atakan Aladağ[1], Yusuf Ziya Taştekin[1], Mustafa Polat[1], Ali Karakuş[1]

[1]Hatay Mustafa Kemal University Emergency Medicine Department

Yusuf Ziya Taştekin / Hatay Mustafa Kemal University Emergency Medicine Department

Introduction and Purpose: Spontaneous ureteral rupture is a rare condition characterized by the extravasation of urine from the ureter without trauma or iatrogenic intervention.We present the case of a 63-year-old male patient who presented to the emergency department with right lower quadrant pain and right flank pain,and in whom spontaneous ureteral rupture was diagnosed by contrast-enhanced computed tomography

Materials and Methods: A 63-year-old male patient presented to the emergency department with a two-day history of right lower quadrant and right flank pain.The patient had no history of trauma. His medical history revealed a previous episode of renal stone passage.Physical examination revealed tenderness in the right lower quadrant. Guarding and rebound tenderness were not observed. Right costovertebral angle tenderness was present.Laboratory tests revealed a glomerular filtration rate (GFR) of 67.95 mL/min, creatinine of 1.2 mg/dL, blood urea nitrogen (BUN) of 16.6 mg/dL, and C-reactive protein (CRP) of 28 mg/dL.The patient's other biochemical parameters, complete blood count, blood gas analysis, and urinalysis were within normal limits.The patient underwent contrast-enhanced abdominal computed tomography (CT).CT imaging revealed contrast extravasation extending from the upper third of the right proximal ureter into the perirenal space and the anterior pararenal space. In addition, a fluid collection reaching approximately 6 mm in thickness at its widest point was observed between the Gerota and Zuckerkandl fasciae.Diagnostic ureterorenoscopy and endoscopic retrograde pyelography were performed, followed by placement of a double-J ureteral stent. Following the procedure, a marked reduction in the patient's pain was observed.On the sixth hospital day, follow-up biochemical tests revealed a glomerular filtration rate (GFR) of 99.82 mL/min, a creatinine level of 0.79 mg/dL, and a blood urea nitrogen (BUN) level of 11 mg/dL. Following improvement in clinical and laboratory parameters, the patient's double-J ureteral stent was removed. Subsequent evaluations showed that the patient was in good general condition.The patient was discharged with appropriate recommendations.

Materials and Methods: Spontaneous ureteral rupture is a rare but important urological emergency that should be considered in the differential diagnosis of patients presenting with acute abdominal pain. Contrast-enhanced computed tomography plays a critical role in early diagnosis. In most cases, successful outcomes can be achieved with minimally invasive treatment methods

Keywords: Spontaneous ureteral rupture, ureteral stone, contrast-enhanced computed tomography

---

Ref No: 9336

The Importance of Electrolyte Monitoring in Hyperemesis Gravidarum: A Case of Severe Hypernatremia

Rıdvan Tuncer[1], Ayşe Işık[1], Ümmü Öksüz Apıdan[1], Yasin Yıldız[1], Mehmet Gül[1]

[1]Emergency Medicine Department, Konya City Hospital, Türkiye

Rıdvan Tuncer / Emergency Medicine Department, Konya City Hospital, Türkiye

Introduction and Purpose: Nausea and vomiting during pregnancy are common physiological conditions, particularly in the first trimester. However, when this condition progresses and leads to fluid and electrolyte imbalances, it is referred to as hyperemesis gravidarum. Hyperemesis gravidarum is characterized by weight loss, dehydration, ketonuria, and electrolyte disturbances.Hypernatremia is defined as a serum sodium level above 145 mEq/L and typically develops as a result of water loss or inadequate intake. Although severe hypernatremia is rare during pregnancy, it is an important clinical condition that can lead to both maternal and fetal complications.

Materials and Methods: CaseA 26-year-old woman at 8 weeks of gestation presented to our emergency department with complaints of nausea and vomiting. Her vital signs were as follows: blood pressure 110/70 mmHg, heart rate 94 beats/min, and oxygen saturation 94% on room air. Urine output was present, and renal function tests were within normal limits. The Glasgow Coma Scale (GCS) score was 15; she was conscious, oriented, and cooperative. The oropharynx and mucous membranes were dry. The patient reported that she had been vomiting everything she ingested, including water, for the past 20 days. Her serum sodium concentration was found to be 172 mEq/L. Hypovolemic hypernatremia was considered, and the patient was admitted to the nephrology ward for further management and treatment.

Results and Conclusion: Although hyperemesis gravidarum is common in early pregnancy, it can lead to serious complications. Electrolyte imbalances should be carefully evaluated in pregnant patients with a history of prolonged vomiting. Hypernatremia is a rare but potentially life-threatening complication. Early diagnosis, appropriate fluid therapy, and a multidisciplinary approach can help prevent maternal and fetal complications.

Keywords: Hypernatremia, Hypovolemia, Hyperemesis gravidarum

Ref No: 9343

Renal Colic or Aortic Dissection: The Changing Face of Pain

Mert Can Yılmaz[1], Murat Seyit[1], Mert Özen[1], Alten Oskay[1], Atakan Yılmaz[1], İbrahim Türkçüer[1]

[1]Pamukkale University Faculty of Medicine

Murat Seyit / Pamukkale University Faculty of Medicine

Introduction and Purpose: Flank pain in the emergency department is most commonly attributed to urinary tract pathology, particularly urolithiasis. However, subtle accompanying

findings may reveal life-threatening alternative diagnoses. Recognizing these clues is critical to prevent diagnostic delay.

Materials and Methods: A 54-year-old male presented with sudden-onset left flank pain accompanied by nausea. He described the pain as "stabbing," radiating within the first 20 minutes to the epigastrium and back. His medical history was significant for hypertension with poor medication adherence. Initial evaluation favored renal colic, and analgesic therapy was administered. Although the pain partially subsided, it maintained a migratory character. Vital Signs and Physical Examination: Blood pressure was 178/96 mmHg in the right arm and 154/88 mmHg in the left arm. Heart rate was 112 beats/min, SpO_2 98%, and temperature 36.7°C. Peripheral pulses were asymmetric, and a newly suspected 2/6 diastolic murmur was noted on auscultation. Laboratory Findings: Hemoglobin was 14.6 g/dL, leukocyte count 12.8 K/µL, and creatinine 1.3 mg/dL. Troponin-I levels showed a borderline rise (0.02 → 0.03 ng/mL). D-dimer was elevated at 2.9 mg/L, and lactate was 2.4 mmol/L. Urinalysis revealed no significant hematuria. Imaging: Ultrasonography demonstrated no hydronephrosis. Given the inter-arm blood pressure discrepancy, migratory pain pattern, and elevated D-dimer, computed tomography angiography was performed. Imaging revealed a Stanford Type A aortic dissection originating in the ascending aorta and extending to the aortic arch, with evidence of compression at the left renal artery orifice. Heart rate and blood pressure were controlled with esmolol infusion (target heart rate < 60 beats/min). Cardiovascular surgery consultation was obtained, and the patient underwent emergent surgical intervention.

Materials and Methods: In patients presenting with flank pain, absence of hematuria, migratory pain characteristics, and/or inter-arm blood pressure discrepancy should prompt consideration of aortic dissection. Small clinical clues may uncover a life-threatening diagnosis. Early suspicion saves lives

Keywords: Aortic dissection, hypertension, flank pain

Ref No: 9359

BACK PAIN IS NOT ALWAYS BENIGN: RUPTURED ABDOMINAL AORTIC ANEURYSM

Erdal Tekin[1], Hakan ALP[1], Muhammed Emin Akgün[1]

[1]Erzurum Atatürk Üniversitesi Araştırma Hastanesi

Hakan ALP / Erzurum Atatürk Üniversitesi Araştırma Hastanesi

Introduction and Purpose: An abdominal aortic aneurysm (AAA) is defined as a dilation of the aorta exceeding 50% of its normal diameter. In cases of rupture or leakage, pain often radiates to the back and may be mistaken for mechanical low back pain. In elderly patients presenting to the emergency department with acute back pain, vascular emergencies should not be overlooked.

Materials and Methods: A 68-year-old male patient presented with sudden-onset severe back pain radiating to the left leg. His medical history included hypertension (HT), chronic obstructive pulmonary disease (COPD), and lumbar disc herniation. He had multiple previous emergency visits for back pain.Vital signs on admission:Blood pressure: 90/60 mmHgOther parameters within normal limitsAbdominal examination:Pulsatile mass in the umbilical regionNo tenderness, guarding, or reboundNeurological examination:Positive straight leg raise (SLR) test on the left sideFemoral pulses were weakLaboratory and imaging studies:Electrocardiogram (ECG): Normal sinus rhythmLaboratory tests: UnremarkablePlain radiographs: No significant findingsInitially, a recurrence of lumbar disc herniation was suspected, and analgesics were planned. However, persistent hypotension and weak femoral pulses prompted abdominal CT, which revealed a 7.5 cm abdominal aortic aneurysm with free fluid consistent with rupture. The patient was admitted to the Cardiovascular Surgery department with a diagnosis of ruptured abdominal aortic aneurysm.

Materials and Methods: Acute-onset back pain in elderly patients with vascular risk factors may indicate a serious vascular emergency such as AAA rupture. Careful assessment of vital signs, especially blood pressure and pulses, is critical for timely diagnosis and management.

Keywords: Back Pain, Aortic Aneurysm, Rupture

Ref No: 9383

Rectal Foreign Body in the Emergency Department: A Case Report

Neslihan Sağlam[1], Murat Seyit[1], Alten Oskay[1], Atakan Yılmaz[1], Mert Özen[1], İbrahim Türkçüer[1]

[1]Pamukkale University Faculty of Medicine

Murat Seyit / Pamukkale University Faculty of Medicine

Introduction and Purpose: Rectal foreign bodies are rare but clinically significant conditions encountered in emergency departments and may lead to serious complications. The most common causes include sexual insertion, psychiatric conditions, and trauma. However, in rare cases, they may also result from inappropriate attempts to relieve constipation.Recent literature

indicates an increase in such presentations. Rectal foreign bodies can lead to complications such as obstruction, mucosal injury, perforation, and sepsis; therefore, early diagnosis and appropriate management are crucial. The aim of this study is to present a case of rectal foreign body associated with constipation and to evaluate it in light of the current literature.

Materials and Methods: A 71-year-old male patient presented to the emergency department with a complaint of a rectal foreign body. According to the patient's history, he had been experiencing constipation for 3–4 days and attempted to remove fecal impaction using a table leg at home.On physical examination, the abdomen was soft with no tenderness, guarding, or rebound. On digital rectal examination, a blunt-ended foreign body was palpated approximately 5 cm proximal to the anal canal. Chest radiography and upright abdominal radiography showed no evidence of perforation. The patient was consulted with general surgery and was admitted to the surgical ward with a plan for operative management.

CT Scan



CT Scan



Materials and Methods: Rectal foreign bodies are more commonly observed in male patients and in the middle-to-elderly age group. Although the most frequent cause reported in the literature is sexual insertion, cases related to inappropriate interventions for constipation, as in this case, are rare but clinically significant. A detailed history and physical examination are essential for diagnosis. Plain radiographs play a key role in determining the location of the foreign body and evaluating the presence of perforation. The management strategy depends on the size and location of the foreign body. Distally located objects may be removed transanally, whereas proximally located or complicated cases may require endoscopic or surgical intervention.

Keywords: Rectal foreign body, constipation, surgery

Ref No: 9408

The lipemic trap: recognizing pseudohyponatremia and masked pancreatitis in a patient with severe hypothyroidism

Hüseyin Özenç[1], Fatih Cemal Tekin[1], Furkan Tayiz[1], Ayla Mollaoğlu[1], Mehmet Gül[1]

[1]Emergency Medicine Department, Konya City Hospital, Türkiye

Fatih Cemal Tekin / Emergency Medicine Department, Konya City Hospital, Türkiye

Introduction and Purpose: Hypertriglyceridemia is the third most common cause in the etiology of acute pancreatitis, following gallstones and alcohol. Profound hypothyroidism can disrupt lipid metabolism, leading to massive hypertriglyceridemia and, in rare instances, acute pancreatitis. These clinical presentations may be accompanied by severe interference in laboratory measurements and pseudohyponatremia.

Materials and Methods: A 36-year-old male patient with a known history of hypothyroidism, non-alcoholic steatohepatitis (NASH), and hyperlipidemia presented to the emergency department with a two-day history of epigastric pain radiating to the back. Laboratory tests revealed severe lipemia; the patient's triglyceride level was measured at 7369 mg/dL, and the TSH level was 171 mU/L. In the initial analysis, sodium was reported as 110 mmol/L (pseudohyponatremia). Although an initial false negativity was observed in amylase (127 U/L) and lipase (387 U/L) levels due to lipemic interference, repeat tests using the plasma exchange method revealed elevations consistent with acute pancreatitis. The patient was admitted with diagnoses of massive hypertriglyceridemia secondary to hypothyroidism and acute pancreatitis, and was monitored with plans for thyroid replacement therapy and plasmapheresis.

Materials and Methods: This case highlights both the pathophysiological clinical course of massive hypertriglyceridemia and its diagnostic challenges at the laboratory level. In our case, the pancreatic enzyme levels, which initially appeared sub-diagnostic, exceeded diagnostic thresholds once the interference was managed at the laboratory level. The profound hyponatremia of 110 mmol/L detected in the patient's initial tests, which was inconsistent with blood gas data, is a classic presentation of pseudohyponatremia caused by massive lipid molecules constricting the volume of the plasma water phase. Uncontrolled hypothyroidism can be the primary trigger for life-threatening massive hyperlipidemia and pancreatitis. Electrolyte imbalances and low enzyme levels detected in lipemic samples must be carefully interpreted by the clinician, keeping potential laboratory interferences in mind.

Keywords: Hypertriglyceridemia, Acute pancreatitis, Pseudohyponatremia

---

Ref No: 9472

Steroid treatment for alopecia: development of cushing's syndrome during recovery - A clinical case report

ÖMER FARUK ÇAKIROĞLU[1], ŞEYMA NUR ÇALIŞIR[2], EMRE KALKAN[2], BAHADIR TAŞLIDERE[2]

[1]KARTAL LÜTFİ KIRDAR ŞEHİR HASTANESİ
[2]BEZMİALEM VAKIF ÜNİVERSİTESİ HASTANESİ

ÖMER FARUK ÇAKIROĞLU / KARTAL LÜTFİ KIRDAR ŞEHİR HASTANESİ

Introduction and Purpose: Cushing’s syndrome is associated with prolonged glucocorticoid use and presents with obesity, glucose intolerance, moon face, skin thinning, hypertension, muscle weakness, and purple striae. Dermal atrophy leads to striae on typical regions. Excess glucocorticoids may impair cognition, described as “steroid dementia” (1,2). Corticosteroid use increases myopathy risk (2). The main treatment is steroid discontinuation, with favorable recovery. This case highlights the need for careful monitoring (3).

Materials and Methods: A 20-year-old male patient presented to the emergency department with nausea, back pain,confusion, tremors, and the appearance of pink-purple lesions on his body. The patient's historyrevealed that he had started taking 64 milligrams of methylprednisolone 13 months ago, basedon his own decision after researching online for the treatment of autoimmune total alopecia,and had reduced the dose to 16 milligrams after two weeks. He had continued this dose for 13months. During this period, the patient experienced hair

regrowth, weight gain, and thedevelopment of lesions, which he attributed to weight gain. Over the past week, he developedmuscle weakness, difficulty maintaining balance without using both hands for support whilesitting, occasional memory problems, and bone pain. Before seeking medical attention, herecognized these symptoms as related to steroid use and reduced the dose to 4 milligrams.Subsequently, he experienced cognitive decline and speech difficulties.On physical examination, widespread striae were observed on the arms, legs, abdomen, andchest, along with abdominal fat accumulation, buffalo hump, and bruising scattered throughoutthe body. Vital Signs: Blood pressure: 142/98 mmHg, heart rate: 120 bpm, pulse SpO2: 97%,fingerstick blood glucose: 85 mg/dL. Laboratory Results: Urea: 43 mg/dL, BUN: 20 mg/dL,eGFR: 111 mL/min/1.73m², LDH: 529 U/L, AST: 36 U/L, ALT: 50 U/L, Ca^{2+}: 10.1 mg/dL, Na^{+}:139 mmol/L, Potassium: 3.47 mmol/L. There were no pathological findings in the hemogram.The diagnosis of iatrogenic Cushing's syndrome was considered, and the patient was referredto endocrinology and metabolic diseases. His methylprednisolone dose was adjusted to 8milligrams, and he was scheduled for follow-up at the endocrinology outpatient clinic. Thiscase underscores the serious complications that can arise from steroid use. To minimize the sideeffects of corticosteroid therapy, individualized treatment protocols should be developed.Patient education and multidisciplinary follow-up are crucial in preventing such complications(Image 1,2).

Figure 1. Pink-purple lesions on the dorsal region



Figure 1. Pink-purple lesions on the dorsal region

gure 1. Pink-purple lesions on the dorsal region Click here to access/download;Figure (300 dpi and editable format);Figure 1. Pink-purple lesions on the dorsal region.jpg Figure 2. Pink-purple lesions on the lower extremities



Keywords: CUSHING, STEROID, STRIA

Ref No: 9590

Ethylene Glycol Intoxication

Sabri Furkan Bulca[1], Murat Seyit[1], Alten Oskay[1], Atakan Yılmaz[1], Mert Özen[1], İbrahim Türkçüer[1]

[1]Pamukkale University Faculty of Medicine

Murat Seyit / Pamukkale University Faculty of Medicine

Introduction and Purpose: Ethylene glycol intoxication is a medical emergency that may occur after ingestion of industrial products such as antifreeze and can lead to severe morbidity and mortality if diagnosis is delayed. It typically presents with high anion gap metabolic acidosis, an elevated osmolar gap in the early phase, hypocalcemia, calcium oxalate crystals, and acute kidney injury. In the emergency department, toxic alcohol ingestion should always be considered in the differential diagnosis in the presence of severe acidosis.

Materials and Methods: A 32-year-old woman presented to the emergency department with dizziness, nausea/vomiting, fluctuating level of consciousness, and shortness of breath approximately 2–3 hours after mistakenly drinking a liquid from a water bottle taken from the trunk in a dimly lit shopping mall parking lot, assuming it was water. Further history revealed

that the liquid in the bottle was antifreeze (ethylene glycol) carried for vehicle use. Vital signs were: blood pressure 118/70 mmHg, heart rate 110/min, respiratory rate 30/min, temperature 36.7°C, and SpO_2 96%. Arterial blood gas analysis showed pH 7.08 and HCO_3 7 mmol/L. Laboratory evaluation demonstrated a markedly increased anion gap, an elevated osmolar gap, and low serum calcium; urinalysis revealed calcium oxalate crystals. The clinical presentation and laboratory findings were considered consistent with ethylene glycol intoxication. Management included 100% oxygen, treatment of acidosis, initiation of an alcohol dehydrogenase inhibitor (fomepizole/ethanol), thiamine and pyridoxinesupplementation, and planning hemodialysis in the setting of severe acidosis/organ dysfunction; the patient was admitted to the intensive care unit.

Materials and Methods: This case highlights that ethylene glycol and other toxic alcohol intoxications should be rapidly ruled out in patients with the combination of high anion gap metabolic acidosis and an elevated osmolar gap. Early antidote administration and hemodialysis in appropriate patients can accelerate metabolic recovery and reduce the risk of neurological sequelae and renal injury. In addition, to prevent similar exposures, toxic liquids such as antifreeze should not be stored in beverage containers such as water bottles, and patients/families should be educated regarding safe storage practices.

Keywords: Ethylene glycol, antifreeze, metabolic acidosis.

Ref No: 9591

Diabetic Ketoacidosis Due To Insulin Non-Adherence In Type 1 Diabetes

Oğuz Yılmaz[1], Murat Seyit[1], Alten Oskay[1], Atakan Yılmaz[1], Mert Özen[1], İbrahim Türkçüer[1]

[1]Pamukkale University Faculty of Medicine

Murat Seyit / Pamukkale University Faculty of Medicine

Introduction and Purpose: Diabetic ketoacidosis (DKA) is a serious and potentially life-threatening acute complication of type 1 diabetes mellitus. Insulin omission is one of the most common precipitating factors. Early recognition and prompt metabolic management are essential.

Materials and Methods: A 25-year-old female patient with a known history of type 1 diabetes mellitus presented to the emergency department with abdominal pain, nausea, and vomiting. She reported missing her insulin doses for several days prior to admission. Physical Examination and

Vital Signs: On admission, the patient was alert. Capillary blood glucose level was measured at 500 mg/dL. Laboratory Findings: Urinalysis revealed ketone positivity at 2+. The laboratory findings were consistent with diabetic ketoacidosis. Diagnosis and Treatment: Based on hyperglycemia, ketonuria, and clinical presentation, the patient was diagnosed with diabetic ketoacidosis. Standard DKA treatment protocol was initiated, including intravenous insulin and fluid replacement. Clinical Course: The patient was admitted to the endocrinology service for close monitoring and continued treatment.

Materials and Methods: Diabetic ketoacidosis should be considered in young patients with type 1 diabetes presenting with gastrointestinal symptoms, particularly in the context of insulin non-adherence. Patient education and adherence to insulin therapy are critical in preventing recurrence.

Keywords: Diabetic Ketoacidosis, Type 1 Diabetes Mellitus, Insulin Non-Adherence

---

Ref No: 9620

Early Diagnosis of Pediatric Odontogenic Mandibular Infection Using Point-of-Care Ultrasonography in the Emergency Department: A Case Report

AHMET DURSUN DEMİR[1], ESRA AKYÜZ ÖZKAN[2]

[1]Department of Emergency Medicine, Ondokuz Mayıs University Faculty of Medicine, Samsun, Türkiye
[2]Department of Pediatrics, Ondokuz Mayıs University Faculty of Medicine, Samsun, Türkiye

AHMET DURSUN DEMİR / Department of Emergency Medicine, Ondokuz Mayıs University Faculty of Medicine, Samsun, Türkiye

Introduction and Purpose: Odontogenic mandibular infections in the pediatric population are relatively uncommon but carry a significant risk of progression to deep neck space infections. Early identification of abscess formation is critical for determining appropriate management strategies. Ultrasonography, particularly point-of-care ultrasonography (POCUS), offers a rapid, radiation-free, and bedside imaging modality that is especially advantageous in pediatric patients.

Materials and Methods: A previously healthy 12-year-old male presented to the emergency department with a one-day history of progressively increasing pain and swelling in the right mandibular region. Physical examination revealed hyperemia, localized warmth, and tenderness

over the anterior ramus of the mandible, accompanied by a 4×4 cm swelling and restricted mouth opening suggestive of early trismus. Vital signs were stable, with a blood pressure of 90/50 mmHg, heart rate of 92 bpm, respiratory rate of 18 breaths/min, and body temperature of 37.1°C.Laboratory investigations demonstrated leukocytosis (14.58 $\times 10^3/\mu L$), neutrophilia (13.1 $\times 10^3/\mu L$), and elevated C-reactive protein levels (32 mg/L). Bedside ultrasonographic evaluation revealed inflammatory thickening of the skin and subcutaneous tissues in the mandibular region, along with a hypoechoic fluid collection approximately 4 mm in depth adjacent to the muscle planes. These findings were consistent with an odontogenic soft tissue infection with early abscess formation.Following consultation with the otorhinolaryngology department, hospitalization and intravenous antibiotic therapy were recommended. However, the patient and his legal guardian declined admission. Consequently, oral antibiotic therapy covering aerobic and anaerobic pathogens (amoxicillin-clavulanate and metronidazole) was initiated, and the patient was discharged with close follow-up instructions.

FIGURE 1



FIGURE 2

Materials and Methods: This case highlights that pediatric odontogenic mandibular infections may initially present with limited clinical findings despite their potential for serious complications. Point-of-care ultrasonography is a rapid and reliable diagnostic tool for early detection of fluid collections and can significantly aid clinical decision-making in the emergency department.

Keywords: Odontogenic infection, Ultrasonography, Pediatric infection

Ref No: 9646

Ondansetron-induced extrapyramidal-like symptoms in a young female: a case study from the emergency department

Selva Poçan[1], Abidin Baran[1], Mustafa Arar[1], Ayla Mollaoğlu[1], Mehmet Gül[1]

[1]Emergency Medicine Department, Konya City Hospital, Türkiye

Ayla Mollaoğlu / Emergency Medicine Department, Konya City Hospital, Türkiye

Introduction and Purpose: Dysmenorrhea is a common condition among women of reproductive age and is predominantly managed with nonsteroidal anti-inflammatory drugs. However, medication-induced neurological adverse effects may rarely develop during the course of treatment. In this report, the clinical course of acute neurological symptoms that manifested following the treatment of dysmenorrhea is presented.

Materials and Methods: A 24-year-old female patient presented to a district state hospital complaining of severe dysmenorrhea that developed during intercity travel. The patient was administered intramuscular tramadol and ondansetron. Following the medication administration, she developed tremors, muscle spasms, and blurred vision. Consequently, the patient was referred to our center for further evaluation. Upon presentation, her body temperature was 37°C, pupils were mydriatic, and the neurological examination was unremarkable. Laboratory findings revealed no abnormalities, and central nervous system imaging was evaluated as normal. The patient was admitted to the level 2 intensive care unit for observation and treatment. Ophthalmology and neurology consultations were obtained. As no acute pathology was detected during follow-up and her symptoms significantly regressed, the patient was discharged with appropriate recommendations.

Materials and Methods: Although medications utilized in the treatment of dysmenorrhea are generally safe, they may rarely precipitate central nervous system adverse effects. The symptoms of tremors, muscle spasms, and blurred vision observed in this case appear consistent with an adverse drug reaction. Extrapyramidal reactions and neurological symptoms are rarely reported secondary to ondansetron use. Rapid systemic absorption following intramuscular administration, individual susceptibility, and potential drug interactions may play a role in the manifestation of such reactions. This case highlights the transient neurological adverse effects that can arise from medications used in the treatment of dysmenorrhea. Adverse drug reactions should be considered in the differential diagnosis once severe underlying pathologies have been excluded.

Keywords: Dysmenorrhea, ondansetron, acute neurological symptom

Ref No: 9736

Necrotizing Fasciitis

Egenur Yılmaz[1], Murat Seyit[1], Atakan Yılmaz[1], Mert Özen[1], Alten Oskay[1], İbrahim Türkçüer[1]

[1]Pamukkale University Faculty of Medicine

Murat Seyit / Pamukkale University Faculty of Medicine

Introduction and Purpose: Necrotizing fasciitis is a rapidly progressive and potentially fatal soft tissue infection characterized by fascial necrosis and systemic toxicity. Mortality remains high, particularly in cases with delayed diagnosis. Early recognition, prompt surgical intervention, and aggressive medical management are essential for survival.We present a case of post-traumatic necrotizing fasciitis associated with extensive subcutaneous air on imaging and progression to sepsis, emphasizing the importance of early diagnosis and multidisciplinary management.

Materials and Methods: A 39-year-old male presented with a progressively worsening wound on the medial aspect of the right upper arm extending toward the axilla, one week after a fall.Physical examination revealed diffuse edema and marked tenderness of the right upper extremity. A foul-smelling, necrotic, exudative wound was observed in the medial upper arm. Tenderness was also present over the right hemithorax and right upper abdominal quadrant. Peripheral pulses were palpable.Plain radiography demonstrated subcutaneous air in the right axillary region and hemithorax. Thoracoabdominal computed tomography revealed extensive subcutaneous edema and widespread air densities along the right hemithorax and abdominal wall. Doppler ultrasonography of the right upper extremity showed preserved arterial and venous flow.Laboratory findings showed leukocytosis (12,000/mm^3), elevated C-reactive protein (318 mg/L), and markedly increased procalcitonin (31 ng/mL), consistent with severe systemic inflammation and sepsis. Renal and hepatic function tests were within normal limits.Broad-spectrum intravenous antibiotics and aggressive fluid resuscitation were initiated immediately. Multidisciplinary consultations were obtained, and urgent surgical debridement was performed. Postoperative intensive care monitoring was planned.

X-ray

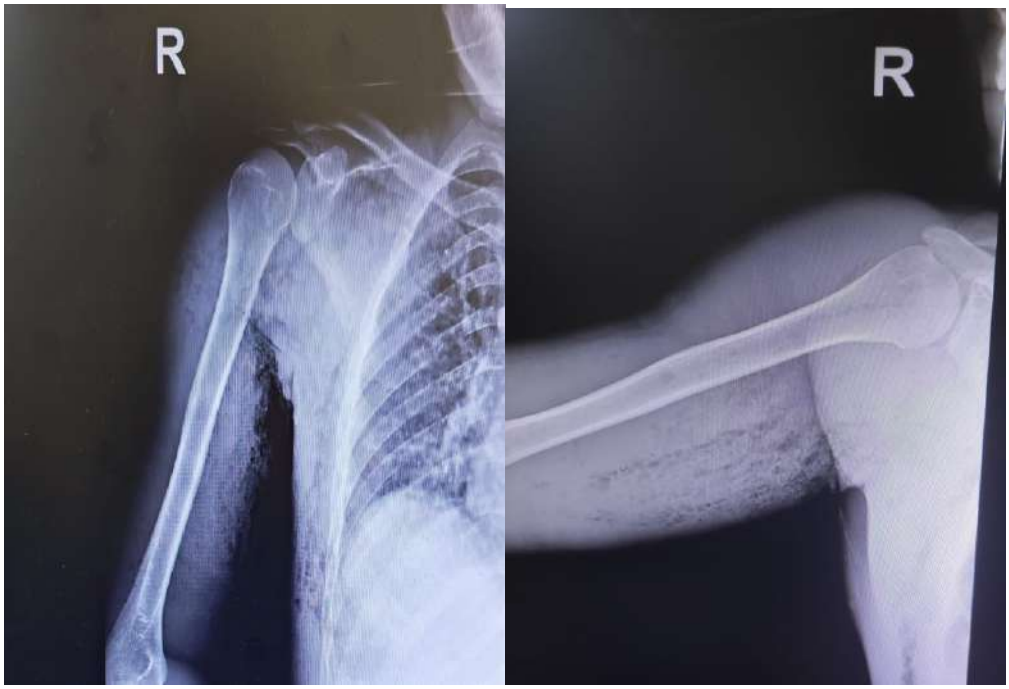

X-ray 2

CT



Materials and Methods: Necrotizing fasciitis is a life-threatening infection that can rapidly progress to sepsis and systemic complications. In this case, markedly elevated procalcitonin levels and extensive radiological soft tissue air prompted early surgical intervention.Early diagnosis, immediate antibiotic therapy, aggressive resuscitation, and timely surgical debridement are critical to reducing mortality. A coordinated multidisciplinary approach and structured postoperative intensive care follow-up are indispensable for optimal patient outcomes.

Keywords: Necrotizing fasciitis, Sepsis, Multidisciplinary management

Ref No: 9748

DISTAL MIGRATION OF A DOUBLE J URETERAL STENT

alparslan altun[1], ali gür[1]

[1]Atatürk University Hospital Department of Emergency Medicine

alparslan altun / Atatürk University Hospital Department of Emergency Medicine

Introduction and Purpose: Double J (DJ) ureteral stents are commonly used medical devices for the management of ureteral obstruction, urolithiasis, and postoperative drainage. Although generally considered safe, complications such as infection, encrustation, fracture, and stent migration may occur. Stent migration is a rare but clinically significant complication that requires early diagnosis and appropriate management.

Materials and Methods: A 35-year-old female patient was discharged after placement of a DJ stent due to a ureteral stone detected during evaluation for left flank pain one week prior. The patient presented to the emergency department with complaints of difficulty in urination, lower urinary tract symptoms, and a sensation of discomfort in the urethral region.On physical examination, suprapubic tenderness was noted, and the patient was afebrile. Laboratory findings revealed mild leukocytosis. Urinalysis showed microscopic hematuria and positive leukocyte esterase.

figure 1 figure 2





Materials and Methods: Although rare, DJ stent migration is an important complication that can lead to significant symptoms in patients. Appropriate stent length selection, correct placement technique, and adherence to follow-up protocols are critical in preventing such complications. Stent migration should always be considered in patients presenting with lower urinary tract symptoms who have recently undergone DJ stent placement.

Keywords: DOUBLE J URETERAL STENT, MIGRATION

Ref No: 9753

Delayed Traumatic Pericardial Tamponade Following Blunt Thoracic Trauma: The Role of Point-of-Care Ultrasound (POCUS)

ŞAFAK ÇOMURLU / ATATURK UNIVERSTY

Introduction and Purpose: Introduction: Cardiac rupture or pericardial injuries secondary to blunt thoracic trauma are generally fatal at the scene of the incident. However, minor venous or pericardial lacerations may present to the emergency department (ED) hours or days post-trauma with a clinical picture of delayed cardiac tamponade. This report highlights the life-saving role of point-of-care ultrasound (POCUS) in a patient presenting with delayed cardiac tamponade following a minor motor vehicle collision.

Materials and Methods: Case Presentation: A 60-year-old male patient presented to the ED with progressive dyspnea, palpitations, and fatigue three days after a motor vehicle collision (low-speed impact). Medical history revealed that the patient had been evaluated on the day of the accident and discharged with unremarkable clinical findings. Physical examination revealed a blood pressure of 80/50 mmHg, a heart rate of 115 beats per minute, and jugular venous distention (JVD). A POCUS E-FAST (Extended Focused Assessment with Sonography for Trauma) examination performed in the ED demonstrated a massive pericardial effusion accompanied by right ventricular diastolic collapse. Emergent pericardiocentesis was performed, yielding 350 mL of hemorrhagic fluid. Following hemodynamic stabilization, the patient was transferred to the cardiovascular surgery (CVS) operating room for definitive surgical repair.Discussion: Delayed tamponade following blunt trauma is an insidious clinical entity that must not be overlooked in the ED. As noted in Rosen's Emergency Medicine, Beck's triad (hypotension, jugular venous distention, and muffled heart sounds) is fully present in only a small minority of patients. In this context, physician-performed POCUS enables a rapid diagnosis within seconds, dramatically reducing mortality rates. The underlying mechanism of delayed presentation is typically a slow exudation from a minor myocardial contusion or the displacement of a clot previously sealing a laceration.

Materials and Methods: Conclusion: Delayed cardiac tamponade should be considered in the differential diagnosis of patients presenting with unexplained hypotension, tachycardia, or dyspnea and a history of blunt thoracic trauma, even if several days have elapsed since the incident. POCUS serves as the gold standard diagnostic modality in the emergency department management of such patients.

Keywords: Cardiac Tamponade, Point-of-Care Ultrasound (POCUS), Pericardiocentesis

Ref No: 9773

Aortic Dissection Mimicking Acute Stroke: Left Carotid Involvement Detected by CT Angiography Prior to Thrombolytic

Aykut KEMANCI[1]

[1]Tavşanlı Doç. Dr. Mustafa Kalemli Devlet Hastanesi

Aykut KEMANCI / Tavşanlı Doç. Dr. Mustafa Kalemli Devlet Hastanesi

Introduction and Purpose: Acute aortic dissection is a life-threatening condition that may present with neurological deficits when the carotid arteries are involved. Such presentations can closely mimic acute ischemic stroke and may lead to inappropriate thrombolytic therapy if not carefully evaluated.This case highlights the importance of considering aortic dissection in patients presenting with acute neurological symptoms, even when initial neuroimaging findings are unremarkable.

Materials and Methods: A 74-year-old male patient presented to the emergency department with sudden onset of left upper extremity weakness and speech impairment. The patient presented within the first hour of symptom onset. His medical history included coronary artery disease and diabetes mellitus. On admission, the patient was disoriented. Neurological examination revealed impaired speech with meaningless verbal output. GCS score was E4M6V3. Motor examination demonstrated muscle strength of 1/5 in the left upper extremity, while the remaining extremities were normal. A tremor was noted in the right hand.Vital signs were blood pressure 100/60 mmHg, heart rate 60 beats per minute, oxygen saturation 90%, and blood glucose level 255 mg/dL. Non-contrast brain computed tomography and diffusion-weighted magnetic resonance imaging were interpreted as normal.The patient was considered a candidate for intravenous thrombolytic therapy, as he presented within the first hour and no intracranial hemorrhage was detected. To support treatment decision-making and evaluate the need for mechanical thrombectomy, brain and carotid CT angiography was performed. Imaging revealed DeBakey type II (Stanford type A) aortic dissection extending into the left carotid artery.Blood pressure measurements were later found to have been obtained only from the right arm. Thrombolytic therapy was withheld, and the patient was referred for urgent cardiovascular surgical management.

Figure 1. CT angiography demonstrating DeBakey type II (Stanford type A) aortic dissection with extension into the left internal carotid artery (arrow).

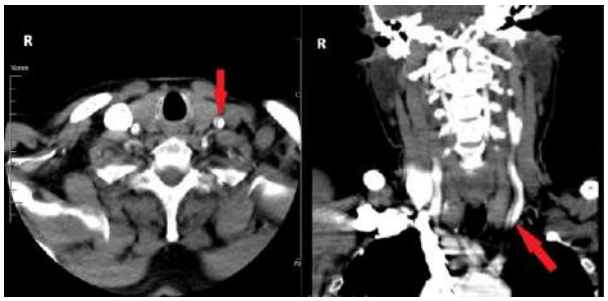

Axial and coronal images show carotid involvement by the dissection process. This finding correlates with the patient's acute neurological presentation and emphasizes the importance of advanced vascular imaging prior to thrombolytic therapy.

Materials and Methods: Aortic dissection may present with isolated neurological findings and mimic acute ischemic stroke, especially when initial neuroimaging is normal. Normal CT and diffusion MRI do not exclude serious vascular pathology. Advanced imaging such as CT angiography may be essential before thrombolytic in selected patients.Single-arm blood pressure measurement may obscure critical diagnostic findings; therefore, bilateral assessment should be routinely performed. Early recognition of carotid involvement in aortic dissection is essential to prevent inappropriate treatment and potentially fatal complications. Increased clinical awareness may improve diagnostic accuracy and patient outcomes.

Keywords: Aortic Dissection, Carotid Dissection, Stroke Mimic

---

Ref No: 9863

The Brotherhood Of Pulmonary Embolism And Deep Vein Thrombosis

Dilara Dikici[1], Murat Seyit[1], Mert Özen[1], Alten Oskay[1], Atakan Yılmaz[1], İbrahim Türkçüer[1]

[1]Pamukkale University Faculty of Medicine

Murat Seyit / Pamukkale University Faculty of Medicine

Introduction and Purpose: Pulmonary embolism (PE) and deep vein thrombosis (DVT) are closely related conditions that together constitute venous thromboembolism (VTE). DVT is the most common source of PE, occurring when thrombi formed in deep veins embolize to the pulmonary arteries. PE can cause significant morbidity and mortality, particularly in elderly

patients, and may present with atypical symptoms such as syncope or hypoxia rather than classic chest pain.

Materials and Methods: An 82-year-old female with a history of hypertension, diabetes mellitus, thyroid disease, and prior stroke presented with acute onset decreased consciousness and dyspnea. During prehospital transfer, a transient decline in Glasgow Coma Scale and oxygen saturation was noted. On admission, the patient was alert (GCS 15) with normal lung auscultation. Physical examination revealed unilateral right lower extremity swelling and circumference difference, raising suspicion for DVT. Brain computed tomography showed no acute pathology. Due to suspected VTE, computed tomography pulmonary angiography was performed and demonstrated filling defects in the right pulmonary artery segmental branches, consistent with pulmonary embolism. Lower extremity venous Doppler ultrasonography confirmed DVT. The patient was admitted for anticoagulation therapy and close monitoring following multidisciplinary evaluation.

Materials and Methods: This case highlights that PE and DVT may present with atypical symptoms such as syncope and hypoxia, especially in elderly patients. Careful physical examination and timely imaging are essential for early diagnosis. Prompt recognition and treatment of VTE are critical to reducing morbidity and mortality.

Keywords: Pulmonary embolism, deep vein thrombosis, venous thromboembolism

---

Ref No: 9866

A rare entity: Stump appendicitis

Rabia ÇELİKÖZ[1], Mehmet Soyugüzel[2], Mustafa Cihat ÇELİKÖZ[3]

[1]Department of Radiology, Afyonkarahisar State Hospital, Afyonkarahisar, Türkiye
[2]Department of Emergency Medicine, Afyonkarahisar Health Sciences University, Afyonkarahisar, Türkiye
[3]Department of Family Medicine, Afyonkarahisar Health Sciences University, Afyonkarahisar, Türkiye

Mehmet Soyugüzel / Department of Emergency Medicine, Afyonkarahisar Health Sciences University, Afyonkarahisar, Türkiye

Introduction and Purpose: Stump appendicitis is a rare clinical entity, occurring in approximately 1/50,000 cases following an appendectomy. The diagnosis may be overlooked in patients presenting with right lower quadrant pain who have a prior history of appendectomy.

Materials and Methods: A 43-year-old male patient presented with abdominal pain that had started diffusely around the periumbilical region two days prior, subsequently increasing in intensity and localizing to the right lower quadrant. Physical examination revealed defense and rebound tenderness in the right lower quadrant. Laboratory findings showed leukocytosis and elevated C-reactive protein (CRP) levels. Given the patient's history of appendectomy 11 months ago, a contrast-enhanced abdominal CT was performed due to clinical suspicion of diverticulitis. The CT scan revealed a short-segment thick-walled loop originating from the cecum in the right lower quadrant, accompanied by extensive pericecal inflammatory fat stranding. The patient's pre-appendectomy CT scans were also reviewed, showing a distended, thick-walled appendix with an appendicolith at its base in the same anatomical location. No diverticula were observed at this level. Based on these findings, which were consistent with stump appendicitis, the patient was referred to the General Surgery department. Intraoperatively, recurrent appendicitis at the site of the appendectomy stump was confirmed.

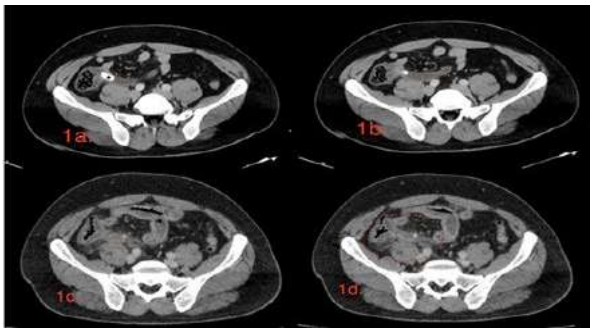

Figure 1

Figure 1a and 1b: CT scan of the initial appendicitis 11 months ago. A fluid-distended appendix (orange arrows), 14 mm in diameter, originating from the cecum and featuring an appendicolith (black asterisk) in its proximal segment. Figure 1c and 1d: Current images of stump appendicitis. Compared to the previous examination, a shorter, distended appendix (orange arrows) is observed at the site of the former appendectomy, accompanied by extensive pericecal inflammatory fat stranding (Figure 1d, circled area).

Results and Conclusion: Diagnosis of stump appendicitis is often delayed, which can lead to high morbidity rates. Therefore, clinical suspicion is paramount; necessary radiological imaging should be utilized for early diagnosis, and surgical intervention should be planned under optimal conditions.

Keywords: Acute abdomen, CT, stump appendicitis

Ref No: 9876

Masked Diabetic Ketoacidosis in a Young Adult Presenting with Nausea, Vomiting, and Weakness in the Emergency Department

MURTEZA ZAFER[1]

[1]ATATÜRK ÜNİVERSİTESİ EĞİTİM VE ARAŞTIRMA HASTANESİ

MURTEZA ZAFER / ATATÜRK ÜNİVERSİTESİ EĞİTİM VE ARAŞTIRMA HASTANESİ

Introduction and Purpose: Diabetic ketoacidosis (DKA) is a life-threatening metabolic emergency, typically seen in patients with known diabetes. However, in some cases, previously undiagnosed patients may present with non-specific gastrointestinal symptoms, which can mimic viral infections or other benign conditions.Early recognition and prompt intervention are crucial to prevent morbidity and mortality.

Materials and Methods: Case PresentationA 32-year-old male presented to the emergency department with two days of nausea, vomiting, and generalized weakness. He also reported mild fatigue over the past week, but he had no known history of diabetes.Physical examination:•Blood pressure: 90/60 mmHg•Heart rate: 115 bpm•Patient appeared lethargic but orientedLaboratory findings:•Blood glucose: 380 mg/dL•Sodium: 132 mmol/L•Potassium: 5.5 mmol/L•Serum ketones: strongly positive•Arterial blood gas: pH 7.18, bicarbonate 12 mmol/LInitially, his symptoms were thought to be viral gastroenteritis. However, persistent hypotension, severe hyperglycemia, metabolic acidosis, and positive ketones raised suspicion for DKA.The patient was immediately started on intravenous fluids, insulin infusion, and electrolyte replacement. Internal medicine consultation was obtained. His condition improved rapidly, confirming the diagnosis of DKA in a previously undiagnosed diabetic patient.—DiscussionDKA can sometimes present with non-specific gastrointestinal symptoms, particularly in patients without a prior diagnosis of diabetes. Key points for the emergency department include:•Dehydration and vomiting disproportionate to the apparent illness•Hyperglycemia with metabolic acidosis•Positive serum or urine ketonesEarly recognition and rapid initiation of fluid resuscitation, insulin therapy, and electrolyte correction are life-saving. Internal medicine consultation can help guide ongoing management.

Materials and Methods: ConclusionIn young adults presenting with nausea, vomiting, and weakness, DKA should be considered even if diabetes is previously undiagnosed. Rapid diagnosis, urgent treatment, and internal medicine involvement can significantly reduce morbidity and prevent life-threatening complications.

Keywords: Diabetic Ketoacidosis

Ref No: 9883

Masked Tachycardia: Pulmonary Embolism in a Patient with Cervical Cancer

Kevser Yıldırım[1], Murat Seyit[1], Atakan Yılmaz[1], Mert Özen[1], Alten Oskay[1], İbrahim Türkçüer[1]
[1]Pamukkale University Faculty of Medicine
Murat Seyit / Pamukkale University Faculty of Medicine

Introduction and Purpose: Malignancy and radiotherapy treatment trigger a hypercoagulable state, significantly increasing the risk of venous thromboembolism. However, the clinical presentation may not always follow the typical course of dyspnea or pleuritic chest pain, which can lead to diagnostic delays. This case report presents a patient with cervical cancer who sought medical attention for transient symptoms and exhibited critical clinical parameters despite a subjective report of recovery.

Materials and Methods: A female patient with a known history of hypertension and cervical cancer, currently undergoing active radiotherapy, presented to the emergency department with sudden-onset presyncope and generalized weakness. Although the patient stated that her symptoms had improved during the triage evaluation, physical examination revealed significant sinus tachycardia (124 bpm) and borderline blood pressure (100/60 mmHg). Peripheral oxygen saturation was 97%, and no tachypnea was observed. In the absence of deep vein thrombosis (DVT) findings or a prior history of thromboembolism, the isolated tachycardia was evaluated as a clinical sign of cardiac strain, considering the patient's high risk factors.

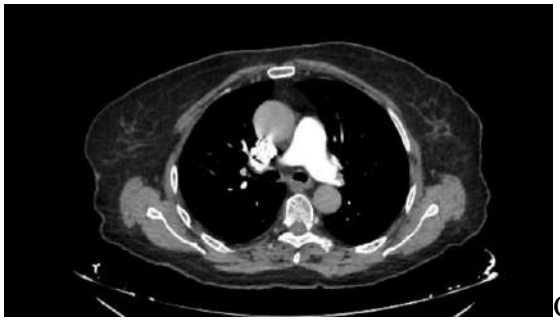
Ct

Materials and Methods: Subsequent advanced radiological imaging confirmed the diagnosis of submassive pulmonary embolism despite the absence of typical symptoms. This case emphasizes that in oncology patients, unexplained isolated tachycardia should never be overlooked, even if the patient reports feeling well. It highlights the vital importance of maintaining a high index of clinical suspicion for pulmonary embolism in malignancy patients presenting with non-specific neurological symptoms such as presyncope.

Keywords: Pulmonary Embolism, Cervical Cancer, Tachycardia.

Ref No: 9926

Right Heart Thrombus Associated with Pulmonary Embolism

Fırat Okta[1], Murat Seyit[1], Mert Özen[1], Alten Oskay[1], Atakan Yılmaz[1], İbrahim Türkçüer[1]

[1]Pamukkale University Faculty of Medicine

Murat Seyit / Pamukkale University Faculty of Medicine

Introduction and Purpose: Pulmonary embolism is defined as occlusion of the pulmonary arterial bed by materials such as thrombus, air, or fat originating elsewhere in the body. After myocardial infarction and stroke, it is the third most common acute cardiovascular syndrome worldwide.

Materials and Methods: In PE, pathophysiological events can be categorized into three main groups: impaired gas exchange, cardiovascular alterations, and infarction. The severity of these processes is directly proportional to the extent of cross-sectional obstruction of the pulmonary arterial bed. Right heart thrombus accompanies PE in 8.1% of cases. Mortality is higher in PE cases accompanied by right heart thrombus.This case report aims to emphasize the importance of right-sided intracardiac thrombi that may be present in patients with PE.A 57-year-old woman was referred to the emergency department after being found desaturated and tachypneic during a follow-up visit at the hematology outpatient clinic. She had a history of splenectomy due to hereditary spherocytosis and was receiving intermittent erythrocyte suspension transfusions. Because she had received an erythrocyte suspension transfusion one day prior to presentation, her respiratory symptoms were initially attributed to volume overload.On physical examination, the skin was icteric and the abdomen participated in respiration. Following detection of a suspicious image in the right ventricle on bedside ultrasonography, computed tomography was performed to evaluate for pulmonary embolism.CT revealed filling defects in the lobar and segmental branches distal to the right main pulmonary artery, hypodense areas in the right ventricle, and centrally distributed ground-glass density with peripheral nodular infiltrative lesions in the right lung; findings were considered consistent with pulmonary infarction. The patient was consulted with pulmonology, cardiology, and cardiovascular surgery.In the emergency department, oxygen at 2–4 liters/minute via nasal cannula and low molecular weight heparin were initiated; the patient was admitted to the pulmonology intensive care unit. Treatment has been ongoing in the pulmonology intensive care unit on day 12 of hospitalization.

Bedside Ultrasonography (US) of the Patient

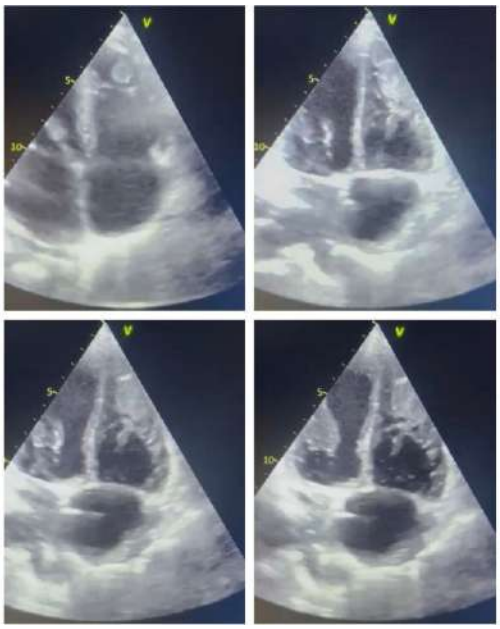

Patient Vital Signs

Blood Pressure	Heart Rate	Temperature	Oxygen Saturation	Respiratory Rate
111/74 mmHg	77 beats/min	36.4 °C	88 %	24 breaths/min

Table 2. Patient Laboratory Findings

Complete Blood Count (CBC)						
	WBC	NEU	LYM	HGB	HCT	PLT
	12.36 K/µL	79.3%	14.9%	10.4 g/dL	29.8%	129 × 10^3/µL
Arterial Blood Gas (ABG)						
	pH	$PaCO_2$	PaO_2	Lactate	Oxygen Saturation	HCO_3
	7,466	38,3 mmHg	48,6 mmHg	1,95 mmol/L	82,6 %	27 mmol/L
Biochemistry						
	Glucose	Creatinine	BUN	Total bilirubin	CRP	D-Dimer
	220 mg/dL	0.47 mg/dL	23 mg/dL	5,06 mg/dL	35,63 mg/L	3,24 mg/L FEU

Materials and Methods: There is no established consensus or guideline for the treatment of PE accompanied by right heart thrombus. Therefore, patients with PE and right heart thrombus should be managed with a multidisciplinary approach.

Keywords: Pulmonary embolism, Right heart thrombus, Cardiovascular syndromes

---

Ref No: 9939

A Rare Etiology in Acute Abdomen

Sabri Furkan Bulca[1], Murat Seyit[1], Mert Özen[1], Alten Oskay[1], Atakan Yılmaz[1], İbrahim Türkçüer[1]
[1]Pamukkale University Faculty of Medicine
Murat Seyit / Pamukkale University Faculty of Medicine

Introduction and Purpose: Gastrointestinal (GI) perforations are among the major causes of acute abdomen and carry a high risk of mortality. In this case, a duodenal perforation developing after oral ingestion of a hyperosmolar enema formulated for rectal use is presented. The case highlights that medication misuse can lead to rare but serious complications.

Materials and Methods: A 68-year-old man presented with abdominal pain. His medical history included mental retardation and schizophrenia. It was learned that, due to constipation for the past three days, he had orally ingested a rectal enema obtained from a pharmacy. His vital signs were relatively stable (blood pressure 116/72 mmHg, heart rate 80/min, SpO_2 93%). On physical examination, abdominal guarding and rebound tenderness were present, with a rigid “board-like” abdomen. Abdominal computed tomography (CT) demonstrated diffuse free air and free fluid. An irregularity on the medial wall of the first portion of the duodenum consistent with perforation was detected. Emergency surgery was recommended. A nasogastric tube and urinary catheter were placed, and cross-matching and blood preparation were performed.

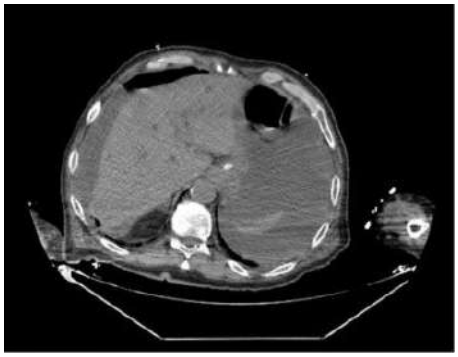
CT Scan

Materials and Methods: Rectal enema solutions are typically hyperosmolar (e.g., sodium phosphate, sorbitol). After oral ingestion, chemical irritation and erosion of the upper gastrointestinal mucosa may occur. The hyperosmolar effect can draw fluid into the intestinal lumen, causing sudden distension and predisposing weakened segments to perforation. The risk of medication misuse is increased in elderly and psychiatric patients. Perforation may develop even when initial clinical findings appear stable. CT is the most sensitive diagnostic modality. Early surgical intervention reduces mortality. Oral ingestion of rectal enemas is rare but may result in severe gastrointestinal complications. In acute abdomen, obtaining a detailed history is vital.

Keywords: Duodenal perforation, enema toxicity, acute abdomen.

Ref No: 9943

DEATH = AORTIC DISSECTION

erhan şahin[1], abdullah süha akça[1], ibrahim özlü[1]

[1]atatürk üniversitesi acil tıp

erhan şahin / atatürk üniversitesi acil tıp

Introduction and Purpose: Acute aortic dissection is a vascular condition that is difficult to diagnose and is associated with high in-hospital mortality even when promptly identified. It is defined as the separation of the intimal layer from the medial layer of the aortic wall following a tear between these layers, allowing blood to track distally along the vessel. Mortality in aortic dissection most commonly results from rupture of a proximal dissection into the pericardium leading to cardiac tamponade, hemorrhage into the pleural cavity, involvement of the aortic valve annulus causing severe aortic regurgitation, or occlusion of the coronary artery ostia leading to myocardial infarction.

Materials and Methods: A 55-year-old male patient with a history of aortic valve replacement and ongoing anticoagulation therapy with warfarin presented to the emergency department with sudden-onset, tearing chest pain radiating to the back and lower back. On admission, vital signs were as follows: right arm blood pressure 140/85 mmHg, left arm blood pressure 100/60 mmHg, heart rate 96 beats per minute, oxygen saturation 96% on room air, and body temperature 36.7°C. Physical examination revealed equal and palpable pulses in all four extremities, with otherwise unremarkable systemic findings. The patient was assessed using the Aortic Dissection Detection Risk Score (ADD-RS) and was found to be high risk. Emergency contrast-enhanced

computed tomography confirmed the diagnosis of aortic dissection, and the patient was urgently taken to surgery by the cardiovascular surgery team.

Materials and Methods: Given the high mortality risk associated with acute aortic dissection, a high index of clinical suspicion is essential to avoid missed or delayed diagnosis. In patients presenting with chest pain and known risk factors such as prior aortic surgery or valve replacement, aortic dissection should be considered among the leading differential diagnoses.

photo1



Keywords: dissection, death, urgent

Ref No: 9955

CARDIAC OR ABDOMINAL? THE INSIDIOUS IMITATOR OF ELEVATION OF TROPONINS: ACUTE PANCREATITIS

Erdal Tekin[1], Hakan Alp[1], Şafak Çomurlu[1]

[1]Erzurum Atatürk Üniversitesi Araştırma Hastanesi

Hakan Alp / Erzurum Atatürk Üniversitesi Araştırma Hastanesi

Introduction and Purpose: Acute Pancreatitis (AP) is an inflammatory condition of the pancreas characterized by an acute onset. The pancreas is an organ responsible for producing digestive enzymes and hormones such as insulin. In acute pancreatitis, these enzymes become activated prematurely within the pancreatic tissue rather than the intestines, leading to autodigestion of the organ and triggering a severe systemic inflammatory response.

Materials and Methods: A 58-year-old female patient presented with complaints of nausea, vomiting, and stomach and abdominal pain radiating to the back for 2 days. The patient has a history of coronary angioplasty/stent, AF (Atrial Fibrillation), and heart valve replacement. There were no specific findings in the admission vital signs. There was no blood pressure difference between both arms. The patient's ECG was in AF rhythm, with no acute pathology. Physical examination of the abdomen revealed tenderness in the epigastric region and upper quadrants. There was no defense or rebound. Bilateral costovertebral angle tenderness was negative.In the patient's blood tests: total bilirubin: 2.98, direct bilirubin: 1.82, ALT: 317, AST: 485, GGT: 251, LDH: 713, ALP: 289, amylase: 2527, lipase: 2380, troponin: 874 (1st-hour control troponin: 948), INR: 2.09 (patient using coumadin). No acute pathological changes were observed in the patient's follow-up ECGs. Supportive treatment was initiated. An abdominal tomography scan showed gallstones in the gallbladder and stranding in the peripancreatic and periduodenal fatty planes, reported as acute pancreatitis? Due to the epigastric pain and troponin elevations, the patient was consulted with the cardiology clinic with a pre-diagnosis of NSTEMI? After cardiology did not consider ACS, the patient was admitted to the Gastroenterology clinic with the diagnosis of Acute Pancreatitis.

Materials and Methods: ACS should always be kept in mind, especially in patients presenting with epigastric pain. In patients with troponin elevation, ACS and secondary causes that can lead to this should also be considered.

Keywords: Acute Pancreatitis, Abdominal Pain, Troponin

Ref No: 9971

Acute Cerebrovascular Event Following Trauma

Murat Can Tahta[1], Murat Seyit[1], Duygu Aras Seyit[2], Mert Özen[1], Alten Oskay[1], Atakan Yılmaz[1]

[1]Pamukkale University Faculty of Medicine
[2]ERPA Saglik Hospital, Denizli

Murat Seyit / Pamukkale University Faculty of Medicine

Introduction and Purpose: Although uncommon in young adults, acute ischemic stroke may occur after trauma and its symptoms can be mistakenly attributed to the injury itself. Repeated neurological assessment and early imaging are key to timely diagnosis in trauma patients.

Materials and Methods: A 19-year-old male was referred after a motorcycle crash due to dysarthria and right-sided weakness. On arrival, blood pressure was 186/96 mmHg, heart rate 92 bpm, SpO_2 97% (room air), and temperature 36.1 °C. He was alert (GCS 15) with a right temporal abrasion; no clear focal deficit was found, though mild right-sided weakness was suspected. During observation, intermittent speech disturbance and urinary hesitancy/incontinence were reported, prompting diffusion-weighted MRI. DWI/ADC demonstrated diffusion restriction consistent with an acute ischemic infarct extending from the left lentiform nucleus to the body of the caudate nucleus.

MRI

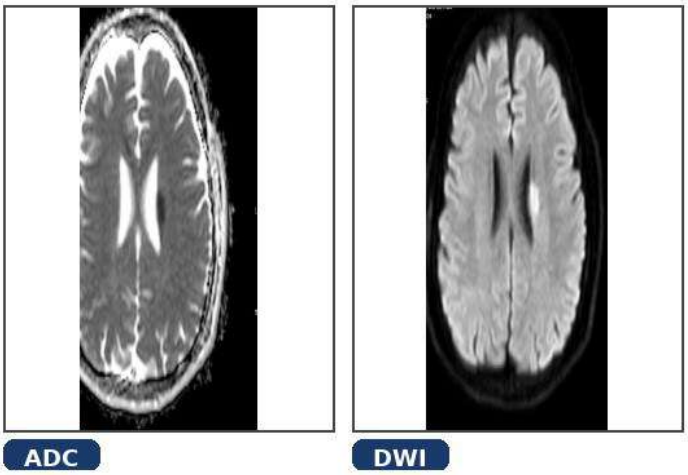

Diffusion MRI (anonymized images)

Materials and Methods: In trauma patients, transient or fluctuating neurological complaints should trigger repeated examination and consideration of stroke in the differential diagnosis. Early recognition enables rapid initiation of a stroke pathway and may reduce morbidity.

Keywords: Trauma, acute ischemic stroke, diffusion MRI

Ref No: 9973

Pulmonary Embolism: Afebrile "Silent" Hypoxia

Kadir Eryürük[1], Murat Seyit[1], Alten Oskay[1], Atakan Yılmaz[1], Mert Özen[1], İbrahim Türkçüer[1]
[1]Pamukkale University Faculty of Medicine

Murat Seyit / Pamukkale University Faculty of Medicine

Introduction and Purpose: Dyspnea and pleuritic chest pain are frequently attributed to pneumonia in the emergency setting. However, pulmonary embolism (PE) may present without fever, productive cough, or prominent auscultatory findings. The combination of minimal physical findings with disproportionate hypoxia and identifiable risk factors is often the key to diagnosis.

Materials and Methods: A 44-year-old woman presented with progressively worsening dyspnea and right-sided flank pain over two days. She denied cough, sputum production, or fever. Her history was notable for lower extremity immobilization with a leg cast for the past three weeks due to an ankle fracture. She was a non-smoker. On examination, lung auscultation revealed no significant abnormalities, yet the patient was visibly dyspneic even while speaking.Vital Signs: Blood pressure was 126/78 mmHg, heart rate 118 beats/min, respiratory rate 26 breaths/min, oxygen saturation 90% on room air, and temperature 36.7°C.Laboratory Findings: D-dimer was elevated at 3.6 mg/L. Troponin-I was mildly elevated at 0.06 ng/mL, and B-type natriuretic peptide (BNP) was 420 pg/mL. Arterial blood gas analysis demonstrated respiratory alkalosis (pH 7.47, pCO_2 30 mmHg) with hypoxemia. Leukocyte count (9.8 K/µL) and C-reactive protein (4 mg/L) were not significantly elevated.Imaging: Chest radiography showed no consolidation. Bedside echocardiography suggested right ventricular dilation with reduced tricuspid annular plane systolic excursion (TAPSE), consistent with right ventricular strain. Computed tomography pulmonary angiography revealed thrombus in the right main pulmonary artery and segmental branches, along with a peripheral wedge-shaped opacity compatible with pulmonary infarction.

Materials and Methods: As the patient was hemodynamically stable, therapeutic anticoagulation was initiated along with supplemental oxygen. She was admitted for risk stratification and monitoring. Given the clear provoking factor of immobilization, anticoagulation duration and deep vein thrombosis prophylaxis were planned accordingly. In patients with immobilization, tachycardia, and unexplained hypoxia, PE must be excluded even in the absence of fever or significant auscultatory findings. Silent hypoxia should raise immediate suspicion for pulmonary embolism.

Keywords: Hypoxia, Dyspnea, Pulmonary embolism

Ref No: 9997

Acute hepatocellular injury induced by herbal supplements: a case report of Boswellia Serrata and Bromelain-related hepatotoxicity

Cumali Deligöz[1], Fatih Cemal Tekin[1], Hakkı Yüce[1], Osman Lütfi Demirci[1], Mehmet Gül[1]

[1]Emergency Medicine Department, Konya City Hospital, Türkiye

Fatih Cemal Tekin / Emergency Medicine Department, Konya City Hospital, Türkiye

Introduction and Purpose: Drug-Induced Liver Injury (DILI) is one of the significant causes of acute hepatitis presentations, and its incidence is increasing, particularly with the widespread use of herbal and "naturally" marketed products. Although these products are generally considered safe, they can lead to hepatotoxicity.

Materials and Methods: A patient who presented to an outside facility with a two-day history of abdominal pain was referred to our emergency department for further evaluation after laboratory tests revealed elevated liver enzymes and hyperbilirubinemia. Upon evaluation in the emergency department, the patient's general condition was good, and vital signs were stable. Physical examination revealed a soft abdomen with no significant tenderness or guarding. A detailed anamnesis revealed that the patient had been regularly using frankincense (Boswellia serrata), bromelain, and collagen for approximately 25 days due to infection and edema. Admission laboratory values were AST 926 U/L, ALT 959 U/L, and total bilirubin 1.8 mg/dL. Although imaging revealed gallstones in the gallbladder, there were no evident signs of obstruction. A rapid decline in liver enzymes was observed during follow-up. Despite plans for further investigation, the patient left the hospital against medical advice.

Materials and Methods: The most notable finding in this case is the presentation of hepatocellular injury accompanied by marked transaminase elevation. AST and ALT values reaching levels of 900 U/L suggest conditions such as acute hepatitis, ischemic hepatitis, or drug-induced liver injury. Acute viral hepatitis, autoimmune hepatitis, and biliary obstruction should primarily be considered in the differential diagnosis. However, the absence of evident biliary obstruction on imaging and the rapid regression of bilirubin levels make obstructive pathologies less likely. Although the presence of gallstones without significant choledochal obstruction suggests the possibility of a passed stone, the degree of transaminase elevation is insufficient to explain this diagnosis alone. Herbal supplements should not be considered innocent and must be questioned in the etiology of acute hepatocellular injury. DILI should be kept in mind as an important diagnosis in patients with compatible clinical and laboratory findings.

Keywords: Drug-induced liver injury, herbal products, hepatotoxicit